

Correlation between twin-block therapy effects and lip position cephalometrically

Mohamed E. Amer¹, Abbadi ElKadi², Mohamed Nadim³

¹(Orthodontic department, Faculty of Dentistry/ Zagazig University, Egypt)

²(Orthodontic department, Faculty of Dentistry/ King Salman International University, Egypt)

³(Orthodontic department, Faculty of Dentistry/ Suez-Canal University, Egypt)

Abstract:

Introduction: The study was conducted to evaluate the effect of Twin-block appliance cephalometrically and to provide an insight into cephalometric variables that may contribute for final lip position outcome in treated growing Class II malocclusion patients with mandibular deficiency.

Material and Methods: Fourteen patients (9 males, 5 females; mean age, 11.4 ± 2 years) with skeletal class II mandibular deficiency were treated using Twin-block appliance to enhance mandibular growth. The pre-treatment photographs and cephalometric radiographs were obtained for every patient at the beginning of treatment (T0). All patients were treated and followed up for 9 months and then new records were obtained. Lip position changes was evaluated from the lateral cephalogram.

Results: Twin-block treated patients showed a significant effect on upper lip to E-line, UI\SN, SNA, ANB. The upper lip was retracted 1.8 mm to E-line while the lower lip retracted 0.78 mm to E-line. Upper lip position in relation to E-line was positively correlated with ANB angle and with Lower lip position in relation to Ricket's E-line.

Conclusion: Twin-block has a positive effect on the facial esthetic which could be explained by the significant retraction of upper lip in relation to E-line.

Key Word: lip position; twin-block; cephalometric changes

Date of Submission: 02-05-2022

Date of Acceptance: 14-05-2022

I. Introduction

Improvement of facial esthetics is one of the most important objectives after orthodontic treatment. Facial esthetics rely mainly on the soft tissue position and texture. Lip position is one of the most important soft tissue factors affecting facial esthetics. Meanwhile, lip position is hugely affected by underlying tooth movement and bony changes during growth and functional appliances therapy. Lip position could be justified directly by several parameters from lateral cephalogram.

The class II malocclusion is one of the most prevalent malocclusions in mixed and permanent dentitions. This malocclusion has several adverse facial characteristics such as increased facial convexity, incompetent lip, retruded chin, decreased naso-labial angle and deep mentolabial sulcus. This could have a deleterious effect on psychological and social status of growing children. The modern trend in medical and dental treatment is to evaluate the treatment outcome esthetically.

The aim of the current study is to evaluate the effect of Twin-block appliance cephalometrically and to correlate these effects with the upper and lower lip position in treated growing Class II malocclusion patients with mandibular deficiency.

II. Material And Methods

Study design & sample size: This study was a one-group pretest–posttest study. Ethical approval was obtained from the Research Ethics Committee, Faculty of Dentistry, Suez Canal University, Ismailia, Egypt.

Inclusion criteria:

1. Subjects ranging in age between 9.5 to 14 years old.
 2. Skeletal Class II cases where ANB angle is greater than 5° with mandibular deficiency that the SNB angle is less than 76° .
 3. Growing patients with cervical vertebrae maturation stage at CS3 or CS4.
-

Cephalometric analysis: Lateral cephalograms were obtained for every patient before the beginning of treatment (T0) and after 9 months from beginning of treatment (T1). All cephalometric films were taken by the same machine (Sirona ORTHOPHOS XG 5 DS/Ceph). Cephalometric tracing was done on the digital cephalogram with Dolphin imaging software version 11.5.04.36 premium. cephalometric tracings and measurements were completed by two investigators and mean value was used. Cervical vertebrae maturation was assessed to ensure that patients still at CS3 or CS4 stage. The assessment was done following Baccetti et al. guidelines.⁽¹⁾ The cephalometric measurements used in the current study are shown in table 1 and figure 1. The position of the lip was measured in relation to Rickett's E-line. The E-line connects the pronasale-peak of the nose (Prn) and soft tissue pogonion (S-Pog). The distance from most prominent point of upper and lower lips to the E-line was measured at T0 & T1 Figure (2,3). Changes were statistically analyzed.

Table 1: Skeletal and dental cephalometric measurements used in the current study

Measurement	Description
SNA angle	Angle formed by the intersection of the line nasion- point A with the SN line
SNB angle	Angle formed by the intersection of the line nasion-point B with the SN line
ANB angle	The included angle between Point A, nasion, and Point B
U1 / SN	Angle formed by the intersection of the long axis of the upper central incisor and the SN line
L1 / Mp	Angle formed by the intersection of the long axis of the lower central incisor and mandibular plane from gonion to menton.

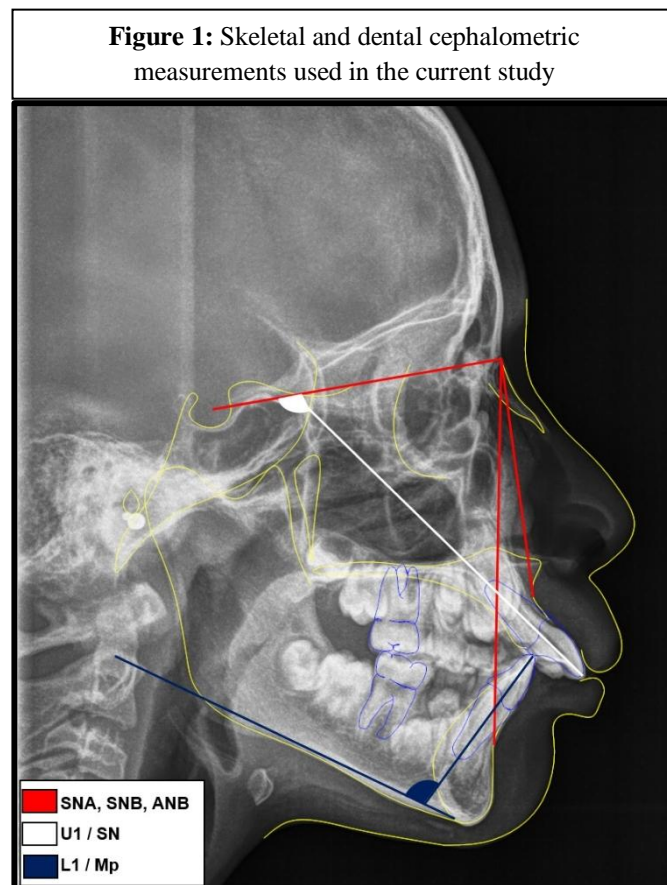


Figure 2: upper and lower lip position in relation to E-line pre-treatment

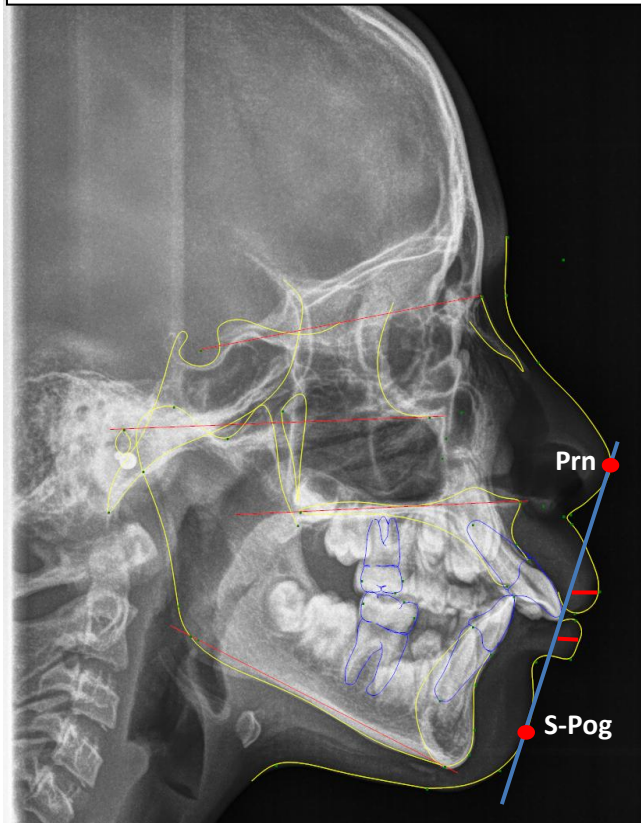
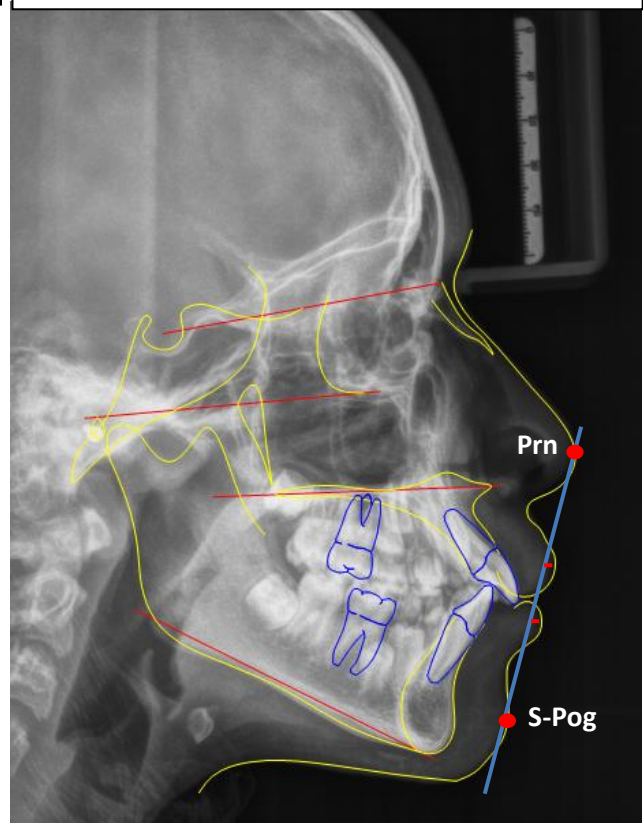


Figure 3: upper and lower lip position in relation to E-line post-treatment



Statistical analysis

Data presented as mean, standard deviation (SD). Data explored for normality using Kolmogorov-Smirnov and Shapiro-Wilk tests. Data showed normal distribution. Paired Sample t-test used for comparison between tested groups. The significance level was set at $P < 0.05$. Pearson correlation used for correlation. Statistical analysis was performed with IBM® SPSS® (SPSS Inc., IBM Corporation, Armonk, NY, USA) Statistics Version 26 for Windows.

III. Result

Cephalometric changes with twin-block therapy

The analyzed data of Twin-block treated patients showed a significant effect on upper lip to E-line, UI\SN, SNA, ANB. On the other hand, there were no significant effects on the lower lip position in relation to Rickett's E-line ($p > 0.05$). Table 2

Correlation between lip position and cephalometric changes after Twin-block therapy

Data analysis revealed a positive correlation between the change in upper and lower lip positions in relation to each other. On the other hand, no correlation between upper or lower lip position with other cephalometric changes with Twin-block therapy except for the ANB which was positively correlated with upper lip position. Table 3

Table 2: Effect of Twin-block on cephalometric measurements

	T0		T1		Paired difference					t	p-value
	Mean	SD	Mean	SD	Mean	SD	SD	95% Confidence Interval of the Difference			
								Lower	Upper		
Upper lip to E-line	2.8	2.1	0.9	2.5	-1.88	2.14	0.57	-2.37	0.10	-1.97	0.049*
Lower lip to E-line	3.2	2.4	2.4	3.0	-0.78	2.15	0.57	-2.03	0.46	-1.36	0.196
UI\SN	109.43	4.51	103.95	6.72	-5.48	4.75	1.27	-8.22	-2.74	-4.32	0.001*
L1\MP	99.06	6.05	100.01	6.86	0.95	4.62	1.23	-1.72	3.62	0.77	0.455
SNA	81.28	4.26	79.69	3.47	-1.59	2.32	0.62	-2.93	-0.25	-2.56	0.024*
SNB	73.08	3.46	74.01	3.72	0.94	2.07	0.55	-0.26	2.13	1.69	0.114
ANB	7.83	1.46	5.69	1.65	-2.14	1.54	0.41	-3.02	-1.25	-5.20	<0.001*

*Significant

Table 3: correlation between lip position and cephalometric changes

		Upper lip to E-line	Lower lip to E-line	UI\SN	L1\MP	SNA	SNB	ANB
Upper lip to E-line	Pearson correlation	1	0.676	0.047	-0.082	0.377	-0.038	0.640
	P-Value		0.008*	0.874	0.780	0.184	0.898	0.014*
Lower lip to E-line	Pearson correlation	0.676	1	0.159	0.170	0.258	0.067	0.242
	P-Value	0.008*		0.587	0.560	0.373	0.821	0.404

*Significant

IV. Discussion

Functional appliances treatment has a great effect on skeletal, dental as long as the soft tissue profile convexity of treated patients⁽²⁾. One of the major concerns for functional appliance treatment is the treatment timing. Baccetti et al.⁽³⁾ has reported that the optimum treatment timing for Twin-block therapy of Class II malocclusion appears to be during or slightly after the onset of the pubertal peak of mandibular growth (between CS3 and CS4).

Regarding the maxillary and mandibular position in relation to the cranial base, Twin-block functional treatment significantly affected maxilla measured by SNA angle. This could be attributed to the appliance's distal reciprocal force exerted on the maxilla (headgear effect). Although controversial outcomes are reported regarding this issue, the current findings are in accordance with several studies⁽⁴⁻⁷⁾. However, the current findings are incompatible with those of Jena et al.⁽⁸⁾ and Saikoski et al.⁽⁹⁾. A high significant change in the ANB angle ($p < 0.001$) was seen in all cases. Most studies that examined the effect of twin-block therapy found the same results⁽¹⁰⁻¹²⁾, explaining the tremendous change of the facial profile in all treated subjects.

Regarding the dentoalveolar effect of the twin-block therapy, there was a significant decrease in the inclination of the maxillary incisors in the current study. Again this could be attributed to the headgear effect of the incorporated labial arch in the twin-block appliance. On the other hand, no significant effect was found on mandibular incisors' inclination. These findings were in accordance with studies reported by Trenouth et al.⁽⁷⁾ and Koretsi et al.⁽¹³⁾

One of the main factors affecting soft tissue profile is the lip position. The assessment of lip position was done using rickett's E-line which is a line drawn from the tip of the nose to the soft tissue pogonion. Rickett's E-line is one of the most frequent parameters to evaluate the soft tissue profile and lip position.⁽¹⁴⁾

Lip position could be affected by Orthodontic treatment specially in premolar extraction cases. It was found that the upper lip retracted 3.4 mm to the E-line, and the lower lip retracted 3.6 mm to the E-line following the extraction of 4 premolars.⁽¹⁵⁾ another study recommended that mandibular incisors are the only

hard tissue variable that could be used as a predictor to explain lip response after orthodontic treatment⁽¹⁶⁾. On the other hand, another study found that maxillary incisor retraction caused upper lip retraction, increased lower lip length⁽¹⁷⁾.

In the current study the upper lip position was significantly changed. The upper lip was retracted 1.8 mm to E-line while the lower lip retracted 0.78 mm to E-line. Similarly Quintão et al found a significant change in upper lip inclination and position due to upper incisor retroclination⁽¹¹⁾. On the other hand, McDonagh et al found that the upper lip landmarks did not show any statistically significant change after twin-block functional treatment⁽¹⁸⁾.

Several studies found positive correlation between incisal movement and lip position in orthodontic cases required 4 premolars extraction.⁽¹⁹⁾⁽²⁰⁾ In our study there was a significant positive correlation between changes of the maxillary lip position and ANB angle. Also a positive correlation was found between changes in upper and lower lip to each other. Thus means that decreasing ANB angle will lead to a retraction of upper lip in relation to Ricketts's E-line. So the tremendous change in the soft tissue profile and lip position could be explained by the correction of the relation between the maxillary base and mandibular base.

The current study had several limitations. First, the absence of a control group of growing patients with matched criteria who would have their follow-up after 9 months to rule out the natural effect of growth on the soft tissue as it is not ethical to postpone the patient's treatment to form a control group. Second all the treated patients were class II mandibular deficiency without concern to the vertical direction of growth which may affect the final facial profile and lip position.

V. Conclusion

1. Twin-block therapy restrict the growth of maxilla and retrocline the maxillary incisor significantly
2. Twin-block has a positive effect on the facial esthetic which could be explained by the significant retraction of upper lip in relation to E-line.
3. The upper lip position was positively correlated with the ANB angle.

References

- [1]. Baccetti T, Franchi L, McNamara JA. The Cervical Vertebral Maturation (CVM) method for the assessment of optimal treatment timing in dentofacial orthopedics. *Semin Orthod.* 2005;11(3):119-129.
- [2]. Baysal A, Uysal T. Soft tissue effects of twin block and herbst appliances in patients with class ii division 1 mandibular retrognathia. *Eur J Orthod.* 2013;35(1):71-81.
- [3]. Baccetti T, Franchi L, Toth R, McNamara J a. Treatment timing for Twin-block therapy. *Am J Orthod Dentofac Orthop.* 2000;118(2):159-170.
- [4]. Antonarakis GS, Kiliaridis S. Short-term anteroposterior treatment effects of functional appliances and extraoral traction on class II malocclusion: A meta-analysis. *Angle Orthod.* 2007;77(5):907-914.
- [5]. Sharma AK, Sachdev V, Singla A, Kirtaniya BC. Skeletal and Dentoalveolar changes concurrent to use of Twin Block appliance in Class II division i cases with a deficient mandible: A cephalometric study. *J Indian Soc Pedod Prev Dent.* 2012;30(3):218-226.
- [6]. Yildirim E, Karacay S, Erkan M. Condylar response to functional therapy with Twin-Block as shown by cone-beam computed tomography. *Angle Orthod.* 2014;84(6):1018-1025.
- [7]. Elfeky HY, Fayed MS, Alhammadi MS, Soliman SAZ, El Boghdadi DM. Three-dimensional skeletal, dentoalveolar and temporomandibular joint changes produced by Twin Block functional appliance. *J Orofac Orthop.* 2018;79(4):245-258.
- [8]. Jena AK, Duggal R, Parkash H. Orthopedic and orthodontic effects of twin-block appliance. *J Clin Pediatr Dent.* 2005;29(3):225-230.
- [9]. Saikoski LZ, Caçado RH, Valarelli FP, de Freitas KMS. Dentoskeletal effects of Class II malocclusion treatment with the Twin Block appliance in a Brazilian sample: A prospective study. *Dental Press J Orthod.* 2014;19(1):36-45.
- [10]. Perillo L, Femiano A, Palumbo S, Contardo L, Perinetti G. Skeletal and dental effects produced by functional regulator-2 in pre-pubertal class II patients: A controlled study. *Prog Orthod.* 2013;14(1):1-8.
- [11]. Quintão C, Brunharo IHVP, Menezes RC, Almeida MAO. Soft tissue facial profile changes following functional appliance therapy. *Eur J Orthod.* 2006;28(1):35-41.
- [12]. Trenouth MJ. Proportional changes in cephalometric distances during Twin Block appliance therapy. *Eur J Orthod.* 2002;24(5):485-491.
- [13]. Koretsi V, Zymperdikas VF, Papageorgiou SN, Papadopoulos MA. Treatment effects of removable functional appliances in patients with Class II malocclusion: A systematic review and meta-analysis. *Eur J Orthod.* 2015;37(4):418-434.
- [14]. Ahmed A, Fida M, Sukhia RH. Cephalometric predictors for optimal soft tissue profile outcome in adult Asian class I subjects treated via extraction and non-extraction. A retrospective study. *Int Orthod.* 2021;19(4):641-651.
- [15]. Drobocky OB, Smith RJ. Changes in facial profile during orthodontic treatment with extraction of four first premolars. *Am J Orthod Dentofac Orthop.* 1989;95(3):220-230.
- [16]. Caplan MJ, Shivapuja PK. The effect of premolar extractions on the soft-tissue profile in adult African American females. *Angle Orthod.* 1997;67(2):129-136.
- [17]. Faysal Talass M, Tollaae L, Baker RC. Soft-tissue profile changes resulting from retraction of maxillary incisors. *Am J Orthod Dentofac Orthop.* 1987;91(5):385-394.
- [18]. McDonagh S, Moss JP, Goodwin P, Lee RT. A prospective optical surface scanning and cephalometric assessment of the effect of functional appliances on the soft tissues. *Eur J Orthod.* 2001;23(2):115-126.
- [19]. Bourzgui F, Alami S, Sebbar M, et al. Effet du traitement orthodontique sur la position des lèvres. *Int Orthod.* 2013;11(3):303-313.
- [20]. Kusnoto J, Kusnoto H. The effect of anterior tooth retraction on lip position of orthodontically treated adult Indonesians. *Am J Orthod Dentofac Orthop.* 2001;120(3):304-307.