

An Overview and Management of Dens in Dente: Report of a Case Series of 9 Patients

H.D Adhikari¹, Shelly Sharma²

¹(Professor & Head, Dept. of Conservative Dentistry and Endodontics, RADCH, WBUHS, India)

²(Final Year Postgraduate student, Dept. of Conservative Dentistry and Endodontics, RADCH, WBUHS, India)

Abstract: *Dens invaginatus is an abnormal developmental anomaly merely agreed to be a gene-related disorder. There are three types of invaginations, of which Type I is the most common. The diagnosis is based on clinical and radiological examinations. Because of the defect in development, these teeth are very vulnerable to pulp involvement and are a great threat to success of endodontic treatment due to the varied and complex anatomy of the root canal system and the invagination. An early prophylactic approach is often the most effective mean of treatment and with little intervention before the involvement of pulp, one may avoid complicated endodontic treatment many a times. This paper gives an overview regarding this developmental anomaly and describes the clinical and radiographic features related to the different types of dens invaginatus and the therapeutic approaches through 9 cases.*

Key Words: *Dens invaginatus, prophylaxis, treatment.*

Date of Submission: 05-04-2022

Date of Acceptance: 20-04-2022

I. Introduction

Dens invaginatus is a developmental anomaly of a tooth resulting from invagination or deepening of enamel organ into the dental papilla before calcification of the dental tissue has taken place. Subsequently, the invaginated enamel organ develops into a small tooth within the tooth. "Ploquet" discovered dens invaginatus in Whale's dentition in 1794. A dentist named "Socrates" (1856) was the first to describe this anomaly in human tooth¹. This anomalous condition has been described by a number of other terms such as "dens in dente" by Busch in 1897 meaning radiographic appearance of tooth within a tooth, "dilated composite odontoma" by Hunter (1951) indicating an abnormal dilatation of the dental papilla; while Colby (1956) used the term "gestant anomaly"².

Among these various nomenclature, dens invaginatus appears to be appropriate as it implies to describe the infolding of a portion of tooth (enamel) within another (dentin) forming a pocket or a dead space. This term also better represents to describe the range of clinical presentation than others nomenclature.

TEETH COMMONLY AFFECTED

Teeth of upper jaw are more commonly affected than that of mandible. Maxillary lateral incisors are affected most followed by central incisors, canines, premolars and molars^{3,4}. Supernumerary and deciduous teeth are also seen to be involved. Presence of bilateral dens invaginatus is not uncommon. In some reported cases, it is associated with other dental anomalies and syndromes such as Rubinstein-Taybi syndrome and Sturge Weber syndrome⁵.

CLINICAL PRESENTATION

Many a times, invaginated tooth remains unnoticed to clinician as crown form seems normal and tooth remains asymptomatic and gets only highlighted in radiography done for other purposes. Careful examination of tooth would reveal caries susceptible deep lingual pit (foramen caecum) or fissure coronal to the prominent cingulum indicating the presence of invagination.

It is easier to diagnose dens invaginatus with unusual crown morphologies such as greater labio-lingual and mesio-distal diameter, peg shaped, barrel shaped & coronoid crown and dilated conical cusp & talon cusp.

Presence of deep lingual pit and the abnormal morphologies provide definite hints for presence of dens invaginatus. Radiologically, a radiopaque invagination is seen extending from cingulum to within varying depth of pulpal space. Radio-opacity of the defect appears equal to enamel. It may vary in shape and size from loop like or pear shaped pointing towards the pulp to a more complex form looking like tooth within a tooth⁶.

ENAMEL AND DENTIN IN THE INVAGINATION AND RISK OF PULP INVOLVEMENT

The wall of invagination is lined by enamel. In mild form, it is tear shaped and in severe form, it is like a fissure and may extend upto periodontium.

Usually it contains traces of dental papilla or periodontal connective tissue (Kronfeld 1934)⁷ which will facilitate bacterial growth, being contaminated from oral cavity. The enamel lining of the invagination is seen to be malformed or defective in nature or absent at places or may be with numbers of fine canals or communications allowing bacterial contamination of the pulp through dentinal tubules of the invagination (Kramer 1953)⁸. Enamel with altered chemical structure has also been reported, compared to normal coronal enamel (Morfis 1993)⁹ which also includes it's hypomineralized nature. (Beynon 1982)¹⁰.

The dentinal layer of invagination is also reported to be defective- irregular, soft tissue inclusions, communication channels for pulp^{10,11}.

All these observations of poor anatomical features both at macro and micro level, help to conclude that tooth with dens invaginatus poses high risk of pulpal involvement^{3,10} and that too can occur without any history of trauma to tooth or any obvious caries involvement (Seow 2003)¹². Therefore, thorough examination, early diagnosis and appropriate treatment of the invagination may save the tooth from infecting the pulp.

ETIOPATHOGENESIS

Exact cause of this malformation is not clear though there are several theories which are put forward to explain the etiopathogenesis of dens invaginatus:-

1. It may be due to focal failure or retardation of growth of inner enamel epithelium while tissue surrounding it continue to proliferate and engulf the area where growth is retarded (Kronfeld 1934)⁷
2. Reverse is suggested by Rushton (1937)¹³ that dens invaginatus may develop from rapid rather than retarded proliferation of a part of inner enamel epithelium which invades the dental papilla.
3. Effect of infection is also considered for the development of this malformation (Fischer 1936, Spraws 1937)^{14,15}.
4. There may be increased localized pressure due to growth of developing dental arch causing bending or buckling of the enamel organ (Euhler 1939¹⁶ and Atkinson 1943¹¹). Such force of pressure may generate from adjacent tooth germ eg. central incisor and canine that develop at least 6 months before lateral incisor (Segura et al 2002)¹⁷ and exert pressure on its tooth bud. This could be the possible explanation of lateral incisors being commonly affected.
5. It is also said that incomplete lateral fusion of two tooth germs- "Twin theory" may be a possible explanation (Bruszt 1950)¹⁸. However, Kronfeld and Dr Smit^{7,19} contradicted this concept of fusion and explained that orientation of dentinal tubules in dens invaginatus is like folding of one layer of dentin rather than the two separate dentinal layers lying side by side.
6. Trauma may be another cause which is proposed by Gustafson and Sundberg in 1950²⁰.
7. Oehlers is of the opinion that it is the distortion and subsequent protrusion of a portion of enamel organ during development of the tooth and may result into formation of an enamel lined sac or channel which ends at cingulum and even may sometimes extend upto the incisal edge.
8. Apart from all these, genetic theory is gaining ground, according to which, the growth and folding of enamel organ are regulated specifically by ectomesenchymal signalling system (Kettunen et al 2000)²¹ that occurs between inner dental epithelium and dental papilla, having definite role in tooth morphogenesis (Ohazama et al 2004)²². Therefore absence of certain such signalling molecules may cause defects in developing tooth germ or even may result in abnormally shaped tooth (Dassule et al 2000)²³. This is the reason why genetic factors are being held responsible for this malformation (grahnen et al 1959, Casamassimo et al 1978^{24,25}, Ireland et al 1987²⁶) and evidences of increased prevalence seen in the members of the same family²⁷.

INVAGINATION AND ROOT CANAL SYSTEM

Anatomy of root canal and it's number in an invaginated tooth are variable and may not be predictable all the times. During development of tooth, folding or invagination of inner dental epithelium may take place either at one point or more than one point resulting into a single invagination which is commonly seen or two/three invaginations in a single tooth²⁸. Either the pulpal space may contain it or it may exist as separate entity within the tooth. The presence of communications, deficient, malformed or defective enamel and dentin between pulp and invagination and also the bacterial nutrients within the invagination, predispose the rapid onset of pulpal inflammation¹².

Commonly it is the lingual pit in the crown from where it originates and it is the early detection of pit followed by the simple sealing of the pit or treating and sealing invagination helps to prevent the developing pulpal pathology and avoid root canal therapy in the complicated root canal system¹⁵.

INCIDENCE

This anomaly is generally underdiagnosed. But this is perhaps the common among other developmental anomalies. In most of the cases, it is overlooked and remain undiagnosed as the clinical signs of this anomaly are not conspicuous usually. Careful examination of the lingual surface and incidental radiography may reveal it.

In a study of Caucasians² (Backman and Wahlin 2001)²⁹ of 739 individuals; dens invagination seemed to be 6.8% among other anomalies. This study is considered to be the representative of this ethnic group. Whereas, study in North America (White SC and Pharaoh MJ; oral radiology 4th edition; St. Louis, Mosby 2000)³⁰ showed equal frequencies in Caucasians and Asian population which is approximately 5%. Studies in various population reflect the incidence of dens invaginatus ranging from 0.25-10% (Ruprecht A, Batniji S, Sastry K, El neweihi E; the incidence of dens invaginatus, journal of pedodontics 1987)³¹, which include Indian population in which prevalence was found to be as low as 0.4%³².

CLASSIFICATION

To describe this developmental anomaly, different classifications have been elaborated on the basis of clinical and radiological appearances. But Oehlers classification 1957 A³, on the basis of radiological findings, is most commonly used as it is simple and also due to its ease of application clinically. Since it is based on 2-D image, finer details of the complexities and true extent of the invagination cannot be described. Therefore, classification system based on 3-D image such as CBCT is required to be evolved. Oehlers classified it depending on its extension within the tooth and relationship with apical foramen of root canal radiologically.

Type I :- The invagination is minimal and sac like, it is confined within the crown of the tooth and does not extend beyond the level of the CEJ .

Type II :- The invagination extends beyond CEJ into the pulp space but remains within the root canal with no communication with the periodontal ligament.

Type III A :- The invagination extends through the root and communicates laterally with the periodontal ligament space through a pseudo-foramen. There is usually no communication with the pulp, which lies compressed within the root.

Type III B :- The invagination extends through the root and communicates with the periodontal ligament at the apical foramen. There is usually no communication with the pulp.

A study was done by Capor et al in 2015 using CBCT and it was found that Type I was the most common (65.9%) followed by Type II (29.5%) and Type III (4.6%)³³. CBCT is of great help in evaluating the intricate detailed anatomy.

THERAPEUTIC APPROACH

Type I:- IOPA x-ray is sufficient to assess its presence . Prophylactic treatment protocol is usually adopted and vary depending on the depth of the invagination after caries removal

- a) Not deep - Sealing invagination with flowable resins
- b) Deep – flowable resins and composite resin material
- c) Very deep (meaning reaching near to pulp not involving it)- indirect pulp capping with MTA. If pulp is involved and infected, root canal therapy may be required.

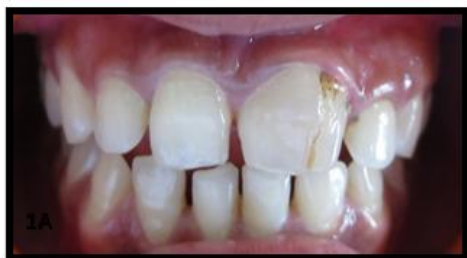Type II:- IOPA x-ray may not be sufficient and CBCT scanning would be required. If it is diagnosed early and pulp remain vital, though in rare circumstances, then only coronal instrumentation for cleaning the invagination, followed by sealing of the invagination would be sufficient. But in most of the cases, pulp has undergone necrosis before the completion of the root. Therefore, treatment option is to negotiate through the invagination and followed by either apical barrier formation with MTA / Biodentine and obturation of the remaining portion of the canal or by conventional root canal therapy. But it is a challenge to a clinician due to the anatomic complexities of the invagination. Adequate chemo-mechanical cleaning of invagination and the root canal system as well as the 3D obturation poses real threat.³⁴ (Tagger 1977; Holtzman & Dezein 1996). However, use of passive irrigation systems and handfiles are recommended³⁴. Many clinicians prefer to remove the invagination with GG drill, thus making a wide canal and then treat accordingly. SAF may be of great use in cleaning this type of canal morphology.

Type III:- CBCT evaluation is of paramount importance in diagnosing root canal system and the invagination. It may reveal distinct two or more root canals, one of which would be a false canal or invagination which is lined by enamel ending to a pseudo root canal opening, communicating to periodontium. If the communication is present at lateral aspect of root, it is Type III A and when it is present apically by the side of the apical foramen of root canal, it is Type III B. In case of a vital pulp, the invagination is to be cleaned and shaped suitably and obturated with GP like normal root canals without injuring the pulp. Otherwise when pulp is necrosed, both the infected root canal and the invagination would be treated separately. Hovland & Block in 1977 was the first to describe the method.³⁴

Intentional implantation and endodontic therapy (Lindner et al 1995 and Nedhya & Power 1997)³⁴, apical root resection with retrograde filling³⁴ are also suggested. However REP may also be attempted.³⁵

CASE SERIES

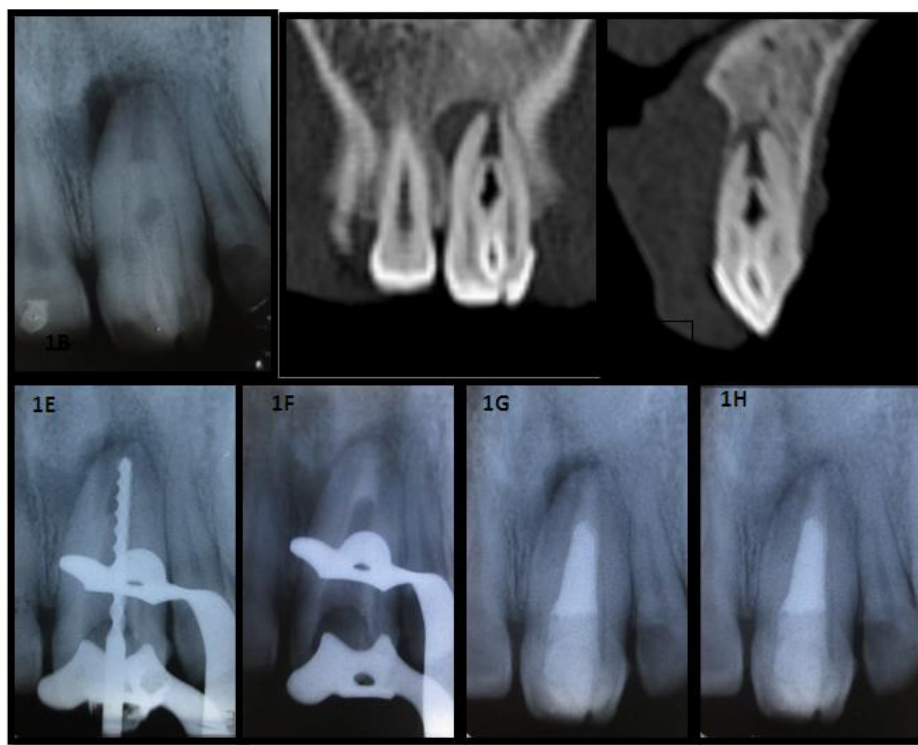
The reported cases were referred to Conservative Dentistry and Endodontics Department of Dr R Ahmed Dental College & Hospital from the Hospital OPD. Therapeutic management of complicated dens invaginatus are mentioned here. Various structural complexities were observed. Thus, treatment modalities varied accordingly.



Case 1:- TYPE II

Upper left central incisor with slightly abnormal crown form (1A), mesio-distally wider with fissure dividing the labial surface unequally. There was no previous history of trauma, nor the tooth was carious. It was discolored and tender on percussion and non-vital in heat and EPT tests.

IOPA x-ray (1B) and spiral CT-images (1C & 1D) revealed the tooth with invagination beyond half the length of root canal with open apex and apical radiolucency involving half of the root mesially.

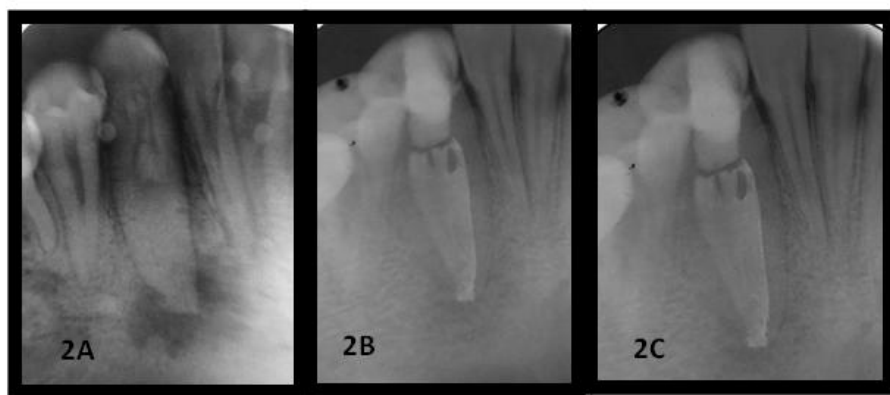


Invagination was removed with GG drill converting into a single wide canal. Working length was measured using hand file (1E) and SAF was used to clean and shape with copious irrigation with 2.5% sodium hypochlorite and saline through endovac irrigation system with negative ultrasonic pressure to prevent the irrigant and debris from passing beyond apex.

Calcium hydroxide (ultradent) dressings were given and the tooth became asymptomatic. Apical barrier (1F) was formed with biodentine. Rest of the canal was back-filled with GP and access cavity was filled with composites in layering techniques (1G). Direct composite veneering was done for treatment of the labial defect and for matching the shade and color with neighbouring tooth. A 13 month follow up showed bony healing(1H) and the tooth is sub serving normal function.

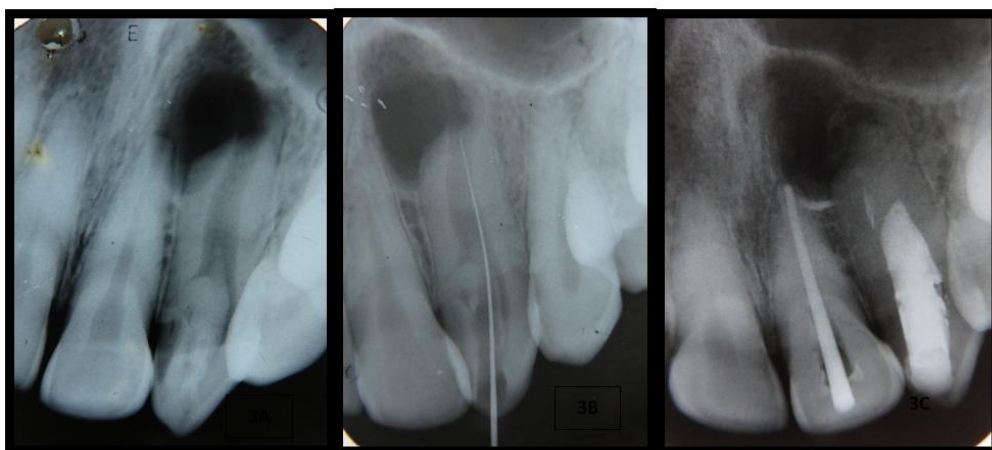
Case 2:- TYPE II

Left lower canine with closed apex and apical radiolucency (2A) was seen to contain Type II invagination through IOPA X-ray. The endodontic treatment was done in the same way as that in case 1(2B). Follow up of 6 months revealed satisfactory periapical healing. (2C)



Case 3:- TYPE II

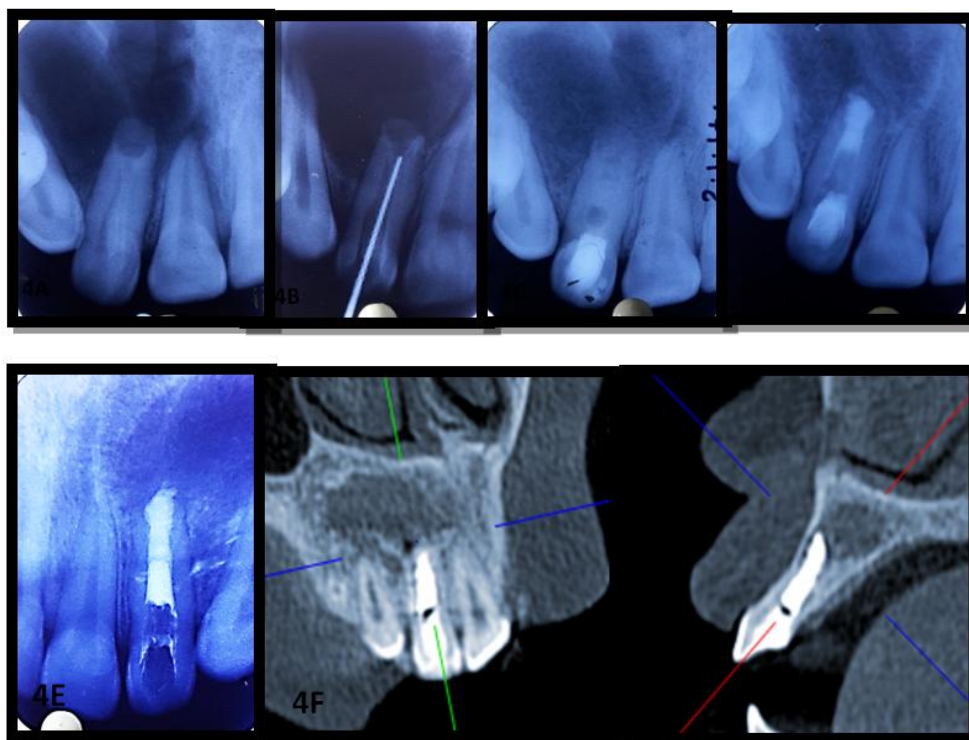
A Type II invagination - tear in shape pointing pulpally, was seen radiographically in a right upper lateral incisor with open apex and apical radiolucency (3A). Canal negotiated through invagination (3B). After proper chemo-mechanical preparation and calcium hydroxide dressings, apical barrier with biodentine was formed followed by backfilling with GP(3C). The involved right central incisor was also endodontically treated. The patient has been kept under observation.



Case 4:- TYPE II

Presence of Type II invagination was detected in an acutely tender and mobile left upper lateral incisor with blunderbuss apex. After the dens invagination was formed, some length of root was developed but rest part of root could not be due to pulpal involvement and subsequent necrosis which has resulted in a huge pathology involving adjacent central incisor and canine (4A). These teeth were sensitive to vitality tests.

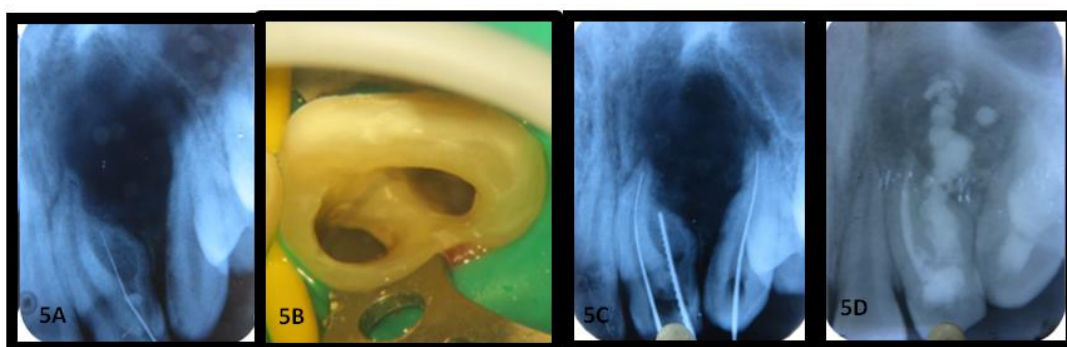
Invagination was removed and pus was drained. The resultant pulp space was cleaned, shaped and disinfected similarly (4B). Calcium hydroxide dressings (4C) were given to make the tooth asymptomatic. Then, MTA apical barrier was formed (4D) over which moist cotton was placed and sealed.

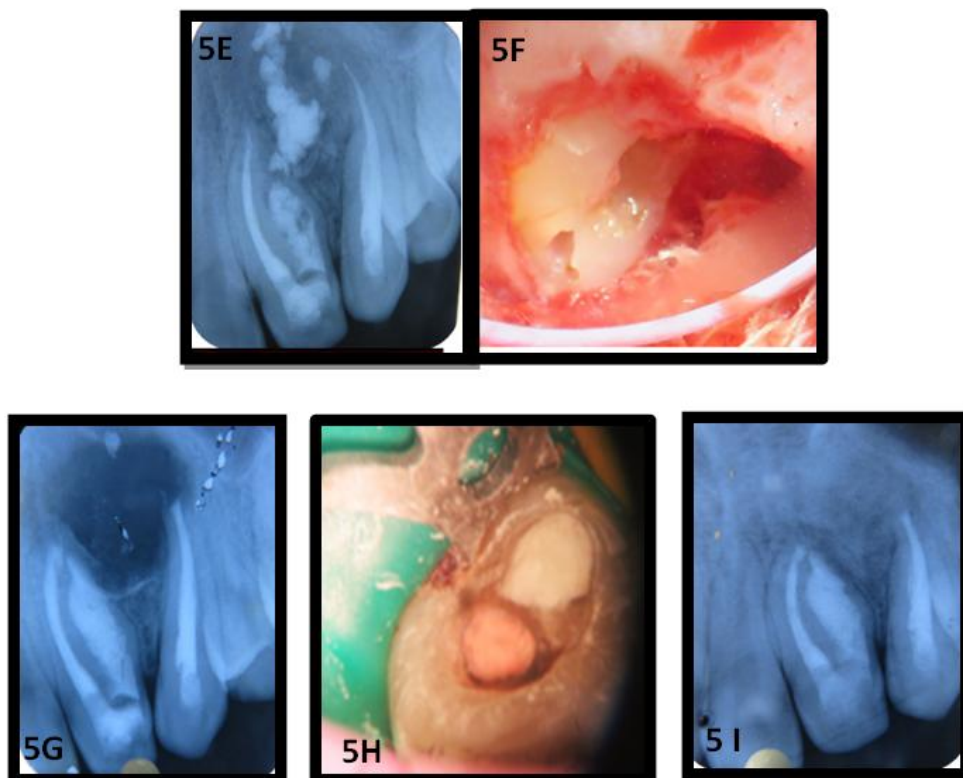


Rest of the canal was kept for backfilled GP (4E) next day. Three year follow up through CBCT showed satisfactory bony healing (4F) & (4G). The adjacent central incisor and canine responded to vitality testing.

Case 5:- TYPE III A

Patient presented with swelling and pain in right anterior region of maxilla. The area was tender on palpation. IOPA revealed an oval shaped periapical pathology involving apical and lateral bone of this tooth and the adjacent canine (5A). Through careful examination of the x-ray, it was found that right upper lateral incisor with two roots, distal one with invagination communicating with the lateral periodontium and the invagination was classified as Oehlers Type III A. Both the teeth were tested non-vital. After access preparation, two canal openings were seen (5B). Canals of mesial root of the lateral and the canine were instrumented conventionally, cleaned, shaped and disinfected. Special attention was taken for distal root of lateral. The invagination was penetrated and hand instrumented (5C). SAF with 2.5% sodium hypochlorite was used to clean the canal. Negative passive irrigation system of Endovac helped preventing irrigant and debris from reaching beyond apex. Canals were sealed with calcium hydroxide (5D).

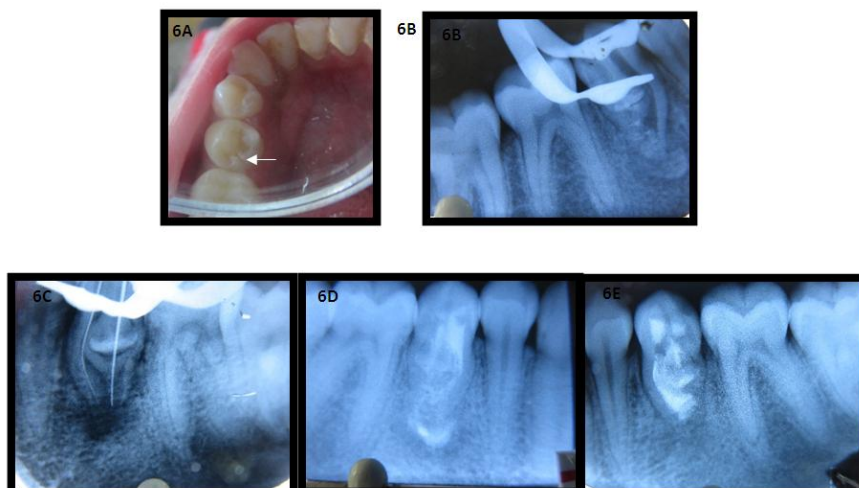




Root canals of mesial root and canine were obturated with GP (5E). With repeated application of calcium hydroxide, oozing from the invagination could not be stopped, so root end surgery was planned. After curettage, root resection and root end cavity preparation (5F), retrograde MTA placement was done in mesial root of lateral incisor and canine, whereas the invagination was filled both by retrograde and orthograde placement of MTA (5G) & (5H). Pluggers were applied to both the ends to ensure thorough packing of MTA into the invagination. The access cavity was restored with composite. The patient was kept under observation. A two year follow up shows complete bony healing (5 I).

Case 6:- TYPE IIIB

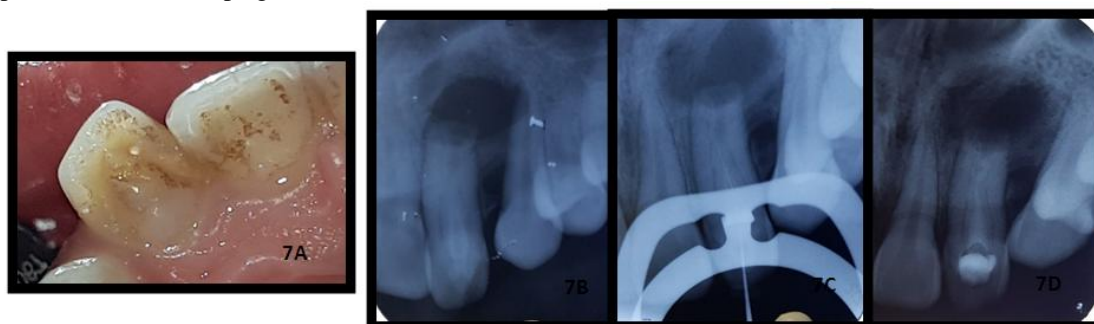
A symptomatic lower left 2nd premolar with normal coronal anatomic form (6A) and a deep lingual fissure extending from central groove of occlusal surface to free gingival margin was seen to contain a bulbous invagination in IOPA x-ray (6B). The root was distended due to the development and growth of the invagination which had pushed the root canal mesially. It was wide in the middle and pointing towards the root apex. The apex was wide open which was accompanying the apical pathology and the invagination communicating with the apical periodontium.



The invagination was complex in nature, detailed anatomy was not realized as CBCT could not be done due to lack of means. However, the root canal and invagination were negotiated through separate access cavity (6C), cleaning and shaping was done with hand instruments and copiously irrigated with 2.5% sodium hypochlorite and saline. Several calcium hydroxide dressings were given. When the tooth turned asymptomatic, an apical plug of MTA was given followed by filling of the root canal and the invagination with MTA, which were treated ultrasonically and packed with hand pluggers(6D). During apical placement of MTA, some amount of this biocompatible material was passed beyond apex. Access cavities were sealed with composite. Follow up of 4 months exhibited bony healing (6E).

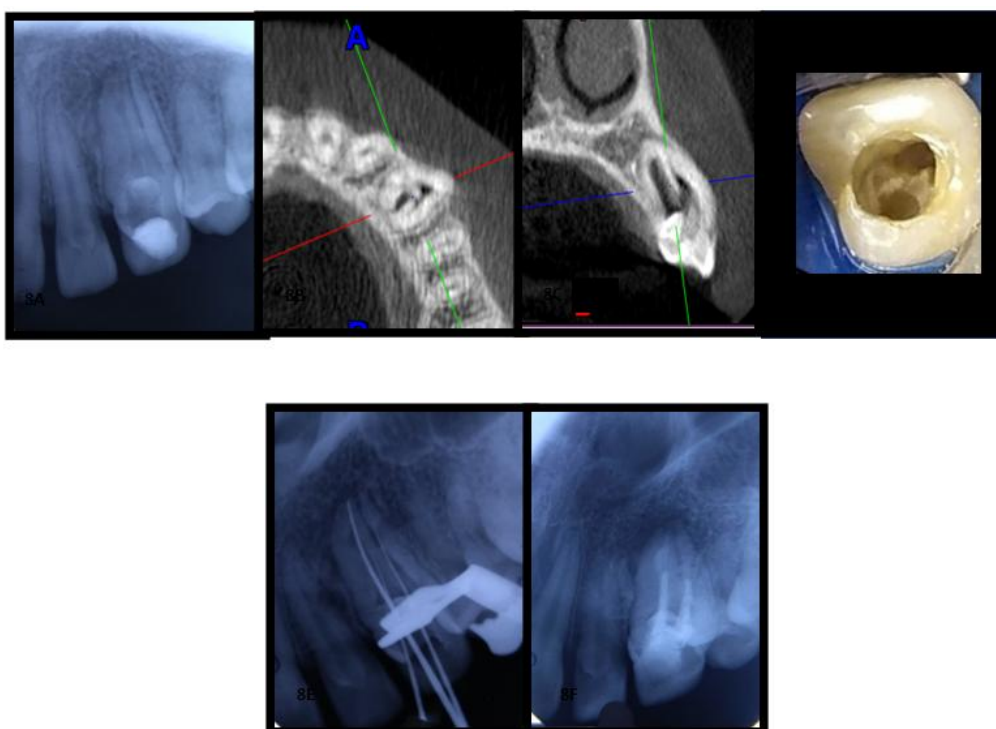
Case 7:- TYPE II

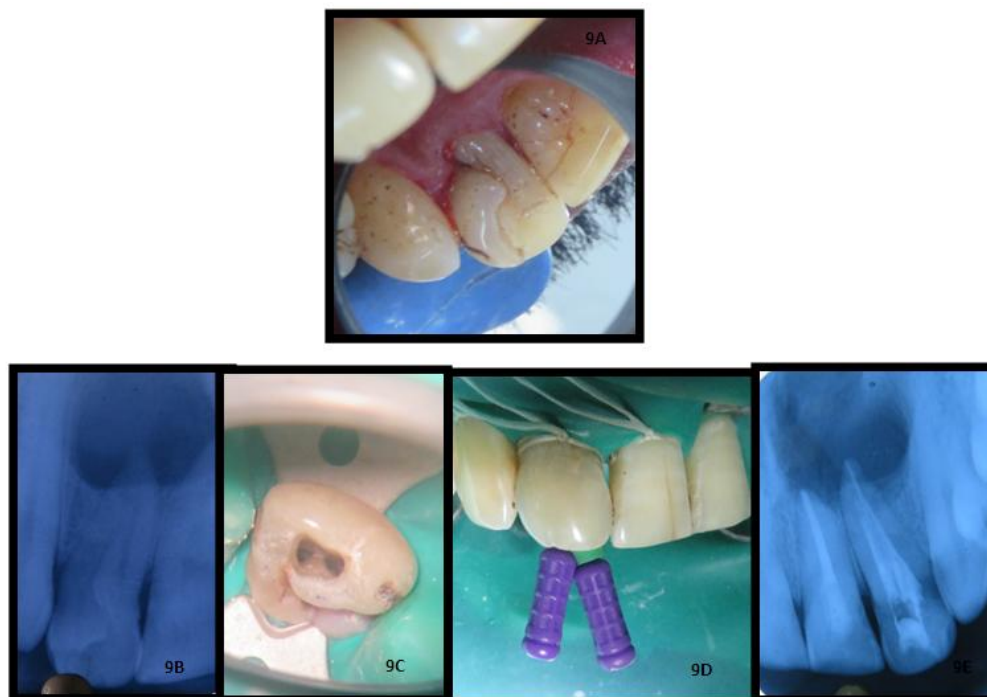
Right upper lateral incisor with bulbous cingulum (7A), apical swelling and pain, blunderbuss apex and apical pathology (7B). Canal was negotiated through invagination (7C) and calcium hydroxide dressing given (7D). The patient did not turn up again.



Case 8:- TYPE III B : canine

Patient presented with pain and swelling in region of right upper canine in which root canal treatment had been attempted from outside. IOPA x-ray (8A) and CBCT images (8B & 8C) and endodontic hand instrumentation (8D & 8E) revealed that root canal and invagination had separate entry from pulp chamber. Invagination was palatally placed and reached upto apical periodontium and had pushed the root canal buccally. The irregularities in shape were revealed in the lumen of the invagination. At some places, it was narrow and at some places, it was wide. So, the invagination and canal were treated endodontically with hand instruments and SAF, almost half of which was filled with biodentine. Rest part of the canal was backfilled with GP and the access was sealed with composite (8F)





Case 9:- TYPE II

A patient with mesio-distally wide upper central incisor of right side with prominent cingulum which was divided by a deep fissure extending sub gingivally (9A) reported with pain and swelling. An invagination was discovered in IOPA x-ray and was seen to extend to a deeper level of root canal space(9B). A periapical pathology involved both the central incisors. On negotiation, (9C & 9D) the presence of root canal was appreciated distally. This canal and the mesially placed pseudocanal of the invagination of right central incisor and root canal of left central incisor were treated endodontically and obturated (9E). The patient was recalled on a regular basis to evaluate the healing of the pathology.

II. Conclusion

There may be a wide variation in the possible clinical and radiographic presentations of Dens invaginatus. In addition, there are a number of approaches concerning the management of different types of anomalies. However, the main objective must aim to preserve the health of the pulp if at all possible and the tooth in the dental arch. This objective can be obtained by early detection of this developmental anomaly and immediate treatment, regardless of the invagination severity. When the prophylactic treatment is applied on time before the onset of any pulp complication, the prognosis of these invaginations turns out to be very good.

References

- [1]. Suruchi S, Maria R, Maria A. Dens invaginatus – A review and case report. *Endodontology* 2010; 22:73-80.
- [2]. Alani A, Bishop K. Dens invaginatus. Part 1: classification, prevalence and aetiology. *International Endodontic Journal* 2008; 41:1123–1136.
- [3]. Oehlers FA. Dens invaginatus (dilated composite odontome). I. Variations of the invagination process and associated anterior crown forms. *Oral Surg Oral Med Oral Pathol* 1957;10:1204- 18
- [4]. Mupparapu M, Singer SR. A rare presentation of dens invaginatus in a mandibular lateral incisor occurring concurrently with bilateral maxillary dens invaginatus. Case report and review of literature. *Aust Dent J* 2004;49:90-3.
- [5]. De Sousa SM, Tavano SM, Bramante CM. Unusual case of bilateral talon cusp associated with dens invaginatus. *Int Endod J* 1999;32:494- 8
- [6]. Gotoh T, Kawahara K, Imai K, Kishi K, Fujiki Y. Clinical and radiographic study of dens invaginatus. *Oral Surg Oral Med Oral Pathol* 1979;48:88- 91
- [7]. Kronfeld R. Dens in dente. *J Dent Res* 1934;14:49- 66
- [8]. Kramer IRH (1953) The pathology of pulp death in non-carious maxillary incisors with minor palatal invaginations. *Proceedings of the Royal Society of Medicine* 46, 503–6.
- [9]. Morfis AS (1993) Chemical analysis of a dens invaginatus by SEM microanalyses. *The Journal of Clinical Pediatric Dentistry* 17, 79–82.
- [10]. Beynon AD (1982) Developing dens invaginatus (dens in dente). A quantitative microradiographic study and a reconsideration of the histogenesis of this condition. *British Dental Journal* 153, 255–60.
- [11]. Atkinson SR (1943) The permanent maxillary lateral incisor. *American Journal of Orthodontics* 29, 685–98.
- [12]. Seow WK. Diagnosis and management of unusual dental abscesses in children. *Aust Dent J* 2003;48:156- 68

- [13]. Rushton MA. A collection of dilated composite odontomas. *Br Dent J* 1937;63:65- 85
- [14]. Fischer CH. To the question of the dens in dente. *Dtsch tooth mouth Kieferheilkd* 1936;3:621- 34
- [15]. Alessandro L, Fabrizio DF, Gennaro D, Dario DS, Eugenio G, Letizia P, Luigi F, Felice F. Dens invaginatus with necrotic pulp in a right maxillary lateral incisor with preserved vitality. *J Conserv Dent* 2018;21:109-13
- [16]. Euler H. Anomalies, deformities and mutilations of human teeth. München, Germany: Lehmann; 1939. p. 62- 7
- [17]. Segura JJ, Hattab F, Ri'os V (2002) Maxillary canine transpositions in two brothers and one sister: associated dental anomalies and genetic basis. *ASDC Journal of Dentistry for Children* 69, 54–8.
- [18]. Bruszt P. Etiology of dens in dente. *SSO Schweiz Monatsschr Zahnheilkd* 1950;60:534- 42
- [19]. Bansal et al. A rare presentation of dens in dente in the mandibular third molar with extra oral sinus. *Journal of Oral and Maxillofacial Pathology* 2010; Vol. 14:80-82.
- [20]. Gustafson G, Sundberg S. Dens in dente. *British Dental Journal* 1950;88,83-88, 111-122, 144-146
- [21]. Kettunen P, Laurikkala J, Ita'ranta P, Vainio S, Itoh N, Thesleff I (2000) Associations of FGF-3 and FGF- 10 with signaling networks regulating tooth morphogenesis. *Developmental Dynamics* 219, 322–32.
- [22]. Ohazama A, Courtney JM, Sharpe PT (2004) Opg, Rank and Rankl in tooth development: co-ordination of odontogenesis and osteogenesis. *Journal of Dental Research* 83, 241–4.
- [23]. Dassule HR, Lewis P, Bei M, Maas R, McMahon AP. (2000) Sonic hedgehog regulates growth and morphogenesis of the tooth. *Development* 127, 4775–85.
- [24]. Grahnén H, Lindahl B, Omnell K (1959) Dens Invaginatus. I. A clinical, roentgenological and genetical study of permanent upper lateral incisors. *Odontologisk Revy* 10, 115–37.
- [25]. Casamassimo PS, Nowak AJ, Ettinger RL, Schlenker DJ (1978) An unusual triad: microdontia, taurodontia, and dens invaginatus. *Oral Surgery, Oral Medicine, and Oral Pathology* 45, 107–12.
- [26]. Ireland JE, Black JP, Scures CC (1987) Short roots, Taurodontia and multiple dens invaginatus. *Journal of Pedodontics* 11, 164–75.
- [27]. Kimura R, Yamaguchi T, Takeda M, Kondo O, Toma T, Haneji K, et al. A common variation in EDAR is a genetic determinant of shovel-shaped incisors. *Am J Hum Genet* 2009;85:528-35
- [28]. Serrano J. Triple dens invaginatus in a mesiodens. *Oral Surg Oral Med Oral Pathol* 1991;71:648- 9.
- [29]. Backman B, Wahlin YB (2001) Variations in number and morphology of permanent teeth in 7-year-old Swedish children. *International Journal of Paediatric Dentistry* 11, 11–7.
- [30]. White SC and Pharaoh MJ; oral radiology 4th edition; St. Louis, Mosby 2000.
- [31]. Ruprecht A, Sastry K, Batniji S, Lambourne A (1987) The clinical significance of dental invagination. *Journal of Pedodontics* 11, 176–81.
- [32]. Patil S, Doni B, Kaswan S, Rahman F. Prevalence of dental anomalies in Indian population. *J Clin Exp Dent* 2013;5:e183- 6
- [33]. Capar ID, Ertas H, Arslan H, Tarim Ertas E. A retrospective comparative study of cone- beam computed tomography versus rendered panoramic images in identifying the presence, types, and characteristics of dens invaginatus in a Turkish population. *J Endod* 2015;41:473- 8
- [34]. Lejri W, Kallel I, Marwen O, Douki N. Diagnostic and therapeutic approach in dens in dente. *Endodontology* 2016;28:192-8.
- [35]. Tippashetty PM, Boregowda V, Pai VS, Mathew SP, George G, Nadig RR. Management of Dens Invagenatus (DI) in a Young Permanent Tooth. *Arch of Dent and Med Res* 2016;2(3):102-107.

H.D Adhikari, et. al. “An Overview and Management of Dens in Dente: Report of a Case Series of 9 Patients.” *IOSR Journal of Dental and Medical Sciences (IOSR-JDMS)*, 21(04), 2022, pp. 30-39.