

CEREBELLO-Pontine Angle Tumor A Series of 3 Cases

Dr.G.Satyavathi M.S,Dr.M.Harika M.S, Dr.K.Vikasini junior resident,
Dr.SK.N.Chandini junior resident, Dr.M.Sahana junior resident.
Department of ophthalmology , GGH, Guntur , A.P , India

Abstract

Background:- Cerebellopontine angle (CPA) is a triangular space in the posterior cranial fossa that is bounded by the tentorium superiorly, brainstem posteromedially and petrous part of temporal bone posterolaterally. It is an important landmark for the cranial nerves V,VI,VII,VIII. The tumors in cerebellopontine angle present with myriad of non-specific symptoms, the most common of which are sensorineural hearing loss, tinnitus, and dizziness and can also be associated with ocular manifestations. We discussed total of three cases of cerebellopontine angle tumor studied over a period of one year where we observed various ways of presentation.

Objectives:- To explain the different ophthalmic manifestations of cerebellopontine angle tumor.

Material and Methods:- A retrospective hospital based observational study was done in GGH , Guntur from the patients who presented to OPD with Cerebellopontine angle tumor and various ophthalmological manifestations were observed . Patients were evaluated by routine blood investigations –CBC, ESR, RFT, LFT, RBS, visual acuity with snellen's chart, IOP with Goldmann'sApplanation tonometry, slit-lamp examination, fundus examination with slit-lamp 90D lens/ Indirect ophthalmoscope +20D lens, CEMRI / MRI of brain with both orbits and histopathological examination for confirmation of diagnosis.

Conclusion:- Vestibular Schwannomas manifest as decreased corneal sensations, dizziness, tinnitus, nystagmus, deviation of mouth, diminished vision and show signs of facial nerve palsy, papilledema & optic atrophy (due to raised intracranial pressure).

Keywords:- Cerebellopontine angle tumor, Vestibular Schwannoma, ophthalmic manifestations, nystagmus, dizziness, hearing loss, tinnitus, facial nerve palsy, papilledema, optic atrophy.

Date of Submission: 02-04-2022

Date of Acceptance: 15-04-2022

I. Introduction

Cerebellopontine angle (CPA) is a triangular space in the posterior cranial fossa that is bounded by the tentorium superiorly, brainstem posteromedially and petrous part of temporal bone posterolaterally. It is an important landmark for the cranial nerves V,VI,VII,VIII. [1]CP angle tumors present with myriad of non-specific symptoms, the most common of which are sensorineural hearing loss, tinnitus, and dizziness. [2]These are mostly benign, slow-growing tumors with low potential for malignancy (~1%). [3] Although etiology is unknown, there are two major types – a) Sporadic (unilateral) b) Associated with NF 2 (bilateral). The most common tumors at the CPA are vestibular schwannoma, meningioma, and epidermoid tumors. [1][3]

In most cases the cause is unknown. In some cases there may be an association with neurofibromatosis 2. [1] The most common presenting symptoms of lesions involving the CPA include hearing loss, tinnitus, dizziness, vertigo, headaches, gait dysfunction and ocular symptoms. [6] Other cranial nerve deficits, brainstem compression symptoms, and hydrocephalus can also be seen.

Ophthalmic manifestations observed in CPA tumors:-

Decreased corneal reflex

Nystagmus

Papilledema

Decreased visual acuity

Restriction of extra-ocular movements [1]

Magnetic resonance image (MRI) is the gold standard for the diagnosis of CPA tumors. Differentiating features of meningioma from vestibular schwannoma include a hyperdense appearance on non-contrast CT, lack of internal auditory canal erosion, broad dural attachment, cleft of CSF between the tumor and brain parenchyma and thickening of dura around the tumor (dural tail sign). [4] Also, better information on more specific features such as ice-cream-cone shape, adjacent hyperostosis, presence of calcification, a dural tail that might be extended into any skull base foramina should help final diagnosis. [7]

Treatment include observation, radiation therapy, or microsurgery. Observation is suitable for elderly/unstable patients and in tumors with little/no evidence of growth. The tumor is monitored with routine annual scans, and tumor growth necessitates aggressive treatment. Radiation therapy provides low rates of recurrence. [2] Microsurgery : Most common approach is retrosigmoid. This approach allows hearing preservation and adequate exposure. [2] [9]

The differential diagnosis of CPA mass includes primary CPA tumors

Vestibular schwannoma,

Meningioma, epidermoid tumors,

Non-vestibular schwannoma,

Congenital, vascular, and metastatic lesions [1] [10] [11]

Disease prognosis depends on size, location, consistency of the tumor, early detection and treatment. The most common complications following radiosurgery are cranial neuropathy, hydrocephalus, and brainstem/cerebellar injury. [9] Complications following surgery include headache, hemorrhage, stroke, vascular injury, infection, cranial nerve injury, tumor recurrence, CSF leak, and death.[2][9] The conventional surgical complication involving cranial nerve dysfunctions is due to lesions in the facial, trigeminal, and vestibulocochlear nerves [5] Multi-specialty team is helpful. [2] [8] Post-operative changes should be evaluated carefully to differentiate them from tumor recurrence. [9]

II. Material And Methods

Study Design:- RETROSPECTIVE HOSPITAL BASED OBSERVATIONAL STUDY

Study Location:- GGH,Guntur

Study Duration:- one year

Subjects & Selection method:- The study population was drawn from GGH OPD who presented with cerebello-pontine angle tumor within a period of one year and various ophthalmic presentations were observed in these cases.

Inclusion criteria:- Patients who are either clinically and radiologically or HPE confirmed cases of cerebello-pontine angle tumor.

Exclusion criteria:- Space occupying lesions other than CP angle tumor.

Procedure methodology:- A total of three case series of cerebellopontine angle tumor studied over a period of one year . Routine blood investigations –CBC, ESR, RFT, LFT, RBS, visual acuity with snellen’s chart, IOP with Goldmann’sApplanation tonometry, slit-lamp examination, fundus examination with slit-lamp 90D lens/ Indirect ophthalmoscope +20D lens, CEMRI / MRI of brain with both orbits and histopathological examination for confirmation of diagnosis.We observed various ways of presentation in these cases despite of classical myraid of symptoms that are usually seen in CP Angle tumor.

CASE 1

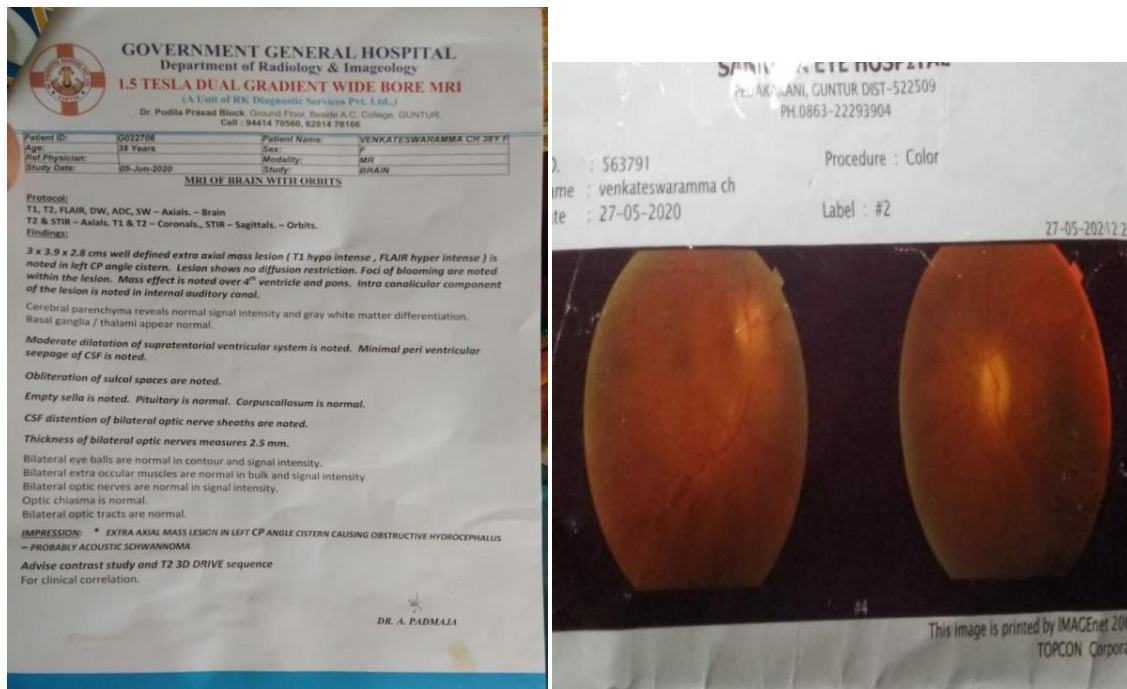
A 38year old non diabetic and non hypertensive female referred to ophthalmology OPD from neurosurgery with a chief complaint of loss of vision in both eyes (BE) since 3months associated with history of seizures and bilateral hearing loss

On examination, Vision in both eyes – No perception of light and tortional nystagmus was present, Extra-ocular movements in right eye(RE) showed elevation restriction and normal in left eye (LE), IOP on Goldmannapplanation tonometry RE 18mmHg and LE 20mmHg at 11:30 AM, On slit lamp examination, both eyes showed mid dilated sluggishly reacting pupils. Fundus picture of both eyes- pale disc, blurring of optic disc margins with secondary optic atrophy and vascular sheathing. Decreased corneal sensations and bilateral sensorineural hearing loss was noted (indicating V & VIII cranial nerve involvement)

Blood investigations are found to be normal. MRI showed- Extra-axial mass lesion in left CP angle cistern causing obstructive hydrocephalus – PROBABLY ACOUSTIC SCHWANOMMA.

Patient underwent surgical excision of the tumor. Histopathologically features are suggestive of acoustic schwannoma. Post-op condition was uneventful.

No Visual improvement is seen in both eyes



CASE 2

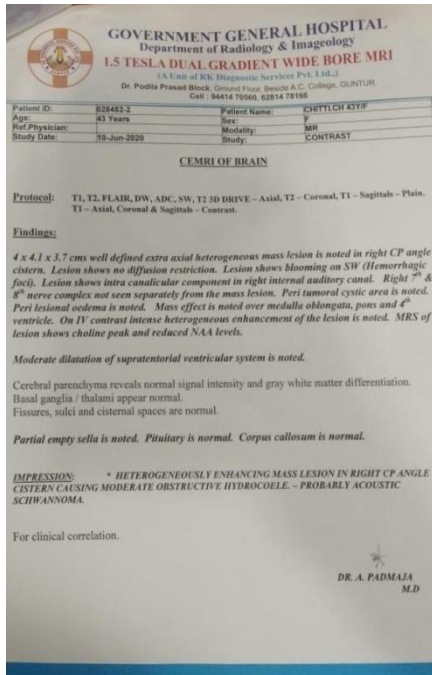
A 43-year-old female presented to ophthalmology OPD with a chief complaint of loss of vision in BE since 3 months associated with headache. No history of fever, vomitings or any other systemic illness. History of ophthalmic consultation in the past for diminution of vision and diagnosed as optic neuritis and referred to neurology OPD where she was diagnosed as Idiopathic Intracranial hypertension and further evaluated.

On examination :- visual acuity in RE light perception and LE no light perception. Nystagmus was present. Extra-ocular movements of BE are free, full, painless in all gazes. IOP on Goldmann applanation tonometry RE 16mmHg and LE 12mmHg at 12:54pm. On slit-lamp examination: pupillary reactions in RE sluggish and in LE grade II RAPD was noted. On Cranial nerves examination bilateral Lateral rectus palsy and loss of corneal sensations in left eye were noted. Fundus examination showed pale optic disc, disc edema with secondary optic atrophy

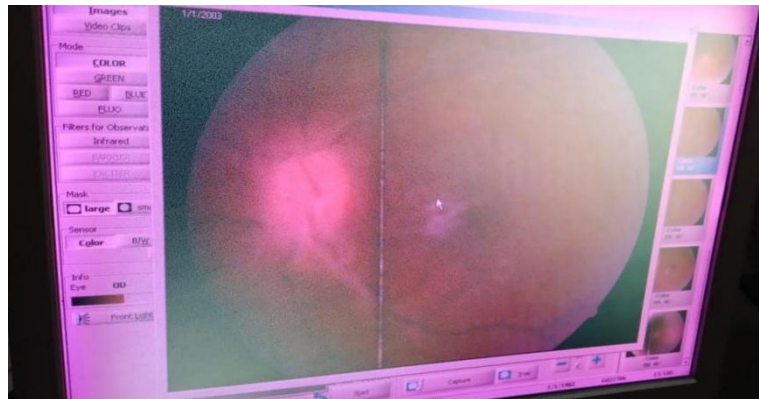
CEMRI Brain showed Heterogeneously enhancing mass lesion in right CP angle cistern causing obstructive hydrocephalus- probably ACOUSTIC SCHWANOMMA. Histopathologically features are suggestive of acoustic schwannoma.

Surgical excision of tumor was done & post-operative status was uneventful.

- No Visual improvement is seen in both eyes



FUNDUS EXAMINATION showed pale optic disc, chronic disc edema with secondary optic atrophy

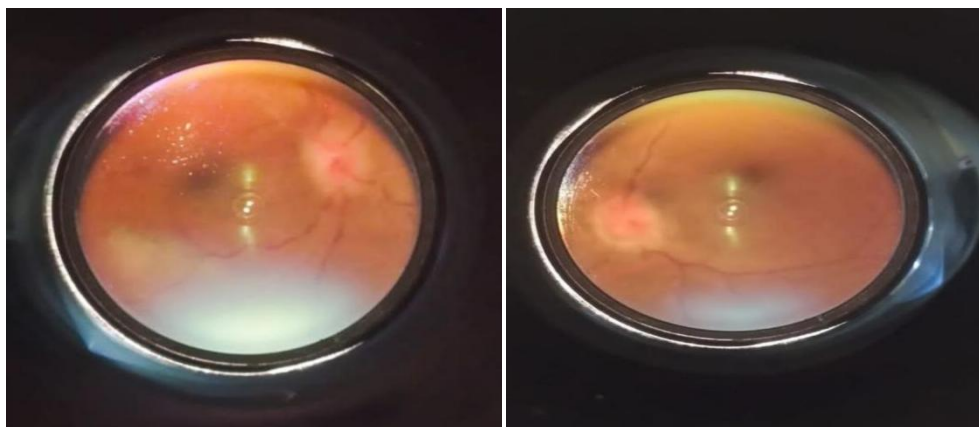


CASE 3

A 50yrs old male patient came to ophthalmology OPD with a chief complaint of diminution of vision in BE since 10days, which is painless and gradually progressive associated with sudden loss of consciousness & Seizures, deviation of mouth 10days back. . History of right ear pain & dizziness, headache which was radiating to neck since 10 days

On examination, Vision in RE hand movements and in LE no perception of light, nystagmus was present and no restriction in extra ocular movements. On slit lamp examination, sluggish pupillary reaction in RE and mid dilated non reacting pupil in LE. Deviation of mouth and hearing loss with intact corneal sensations were noted. Fundus examination showed BE PALE optic disc more in left eye , margins are blurred & elevated with arteriolar narrowing.

- All blood investigations were found to be normal. MRI Findings:- Extra-axial mass lesion in left CP angle cistern causing Obstructive hydrocephalus – PROBABLY ACOUSTIC SCHWANOMMA.
- Histopathologically features are suggestive of acoustic schwannomma
- surgical excision was done and post-op condition was uneventful.
- Visual improvement is seen from HM to CF 2mts in RE



FUNDUS EXAMINATION :-Optic disc BE – pale disc LE >RE, margins are blurred & elevated. Vessels showed arteriolar narrowing. FR is altered in BE

A total of three cases of cerebellopontine angle tumor were studied over a period of one year where we observed various ways of presentations like seizures in one case, gradual loss of vision with a history of headache and vomitings in 2 cases. All three cases presented with gross fall of vision ranging hand movements to no perception of light associated with nystagmus during their first visit to ophthalmology OPD. One of them presented with Bilateral superior restriction of ocular movements. All three cases showed abnormal pupillary reflexes for light with normal anterior segment. In 2 cases corneal sensations are diminished unilaterally. Cranial nerves examination showed involvement of V & VIII nerve in first case, V & VI cranial nerve in second case, VII & VIII cranial nerve in third case. Fundus examination showed Bilateral chronic papilledema stage III in one case & bilateral post-papilledema with secondary optic atrophic changes in two cases with vascular sheathing. MRI brain with both orbits showed left CP angle tumor in two cases & right CP angle tumor in one case. After neuro-surgical intervention one patient regained vision slowly from Hand movements to CF 2mtrs and remaining two patients remained same without further improvement.

III. Conclusion

All three cases were diagnosed as vestibular schwannoma both radiologically and histopathologically. Manifestations observed in these Vestibular Schwannomas are dizziness, tinnitus, seizures, nystagmus, deviation of mouth, diminution of vision, decreased corneal sensations, signs of facial nerve palsy, papilledema & optic atrophy (due to raised intracranial pressure).

References

- [1]. Samii M, Gerganov VM. Tumors of the cerebellopontine angle. *HandbClin Neurol*. 2012;105:633-9. [PubMed]
- [2]. Huang MY, Vermeulen S. Clinical perspectives regarding patients with internal auditory canal or cerebellopontine angle lesions: surgical and radiation oncology perspectives. *Semin Ultrasound CT MR*. 2003 Jun;24(3):124-32. [PubMed]
- [3]. Renowden S. Imaging of the cerebello-pontine angle. *Pract Neurol*. 2014 Oct;14(5):e2. [PubMed]
- [4]. Zamani AA. Cerebellopontine angle tumors: role of magnetic resonance imaging. *Top MagnReson Imaging*. 2000 Apr;11(2):98-107. [PubMed]
- [5]. Springborg JB, Poulsen L, Thomsen J. Nonvestibular schwannoma tumors in the cerebellopontine angle: a structured approach and management guidelines. *Skull Base*. 2008 Jul;18(4):217-27. [PMC free article] [PubMed]
- [6]. Kan P, Shelton C, Townsend J, Jensen R. Primary Malignant Cerebellopontine Angle Melanoma Presenting as a Presumed Meningioma: Case Report and Review of the Literature. *Skull Base*. 2003 Aug;13(3):159-166. [PMC free article] [PubMed]
- [7]. Greene J, Al-Dhahir MA. StatPearls [Internet]. StatPearls Publishing; Treasure Island (FL): Aug 11, 2021. Acoustic Neuroma. [PubMed]
- [8]. Backer-Grøndahl T, Moen BH, Torp SH. The histopathological spectrum of human meningiomas. *Int J Clin Exp Pathol*. 2012;5(3):231-42. [PMC free article] [PubMed]
- [9]. Petsavage JM, Fink JR, Chew FS. Cerebellopontine angle meningioma presenting with hearing loss. *Radiol Case Rep*. 2010;5(2):434. [PMC free article] [PubMed]
- [10]. Spena G, Sorrentino T, Altieri R, Zinis LR, Stefani R, Panciani PP, Fontanella M. Early-Career Surgical Practice for Cerebellopontine Angle Tumors in the Era of Radiosurgery. *J Neurol Surg B Skull Base*. 2018 Jun;79(3):269-281. [PMC free article] [PubMed]
- [11]. Tonn JC, Schlake HP, Goldbrunner R, Milewski C, Helms J, Roosen K. Acoustic neuroma surgery as an interdisciplinary approach: a neurosurgical series of 508 patients. *J Neurol Neurosurg Psychiatry*. 2000 Aug;69(2):161-6. [PMC free article] [PubMed]
- [12]. Larson TL. Understanding the posttreatment imaging appearance of the internal auditory canal and cerebellopontine angle. *Semin Ultrasound CT MR*. 2003 Jun;24(3):133-46. [PubMed]
- [13]. Tatagiba MS, Roser F, Hirt B, Ebner FH. The retrosigmoid endoscopic approach for cerebellopontine-angle tumors and microvascular decompression. *World Neurosurg*. 2014 Dec;82(6 Suppl):S171-6. [PubMed]
- [14]. Swartz JD. Lesions of the cerebellopontine angle and internal auditory canal: diagnosis and differential diagnosis. *Semin Ultrasound CT MR*. 2004 Aug;25(4):332-52. [PubMed]
- [15]. Heier LA, Comunale JP, Lavyne MH. Sensorineural hearing loss and cerebellopontine angle lesions. Not always an acoustic neuroma--a pictorial essay. *Clin Imaging*. 1997 May-Jun;21(3):213-23. [PubMed]
- [16]. Shulev Y, Trashin A, Gordienko K. Secondary trigeminal neuralgia in cerebellopontine angle tumors. *Skull Base*. 2011 Sep;21(5):287-94. [PMC free article] [PubMed]