

Orthognathic surgery & the psychological impact: a Case report

Dr. Sunita Saini¹ BDS, MDS, Medical officer of government of Rajasthan,

Dr. Brijkishore Saini², MBBS, Resident doctor of psychiatry department at government medical college
Kota,

Dr. Ruhee Gupta³, BDS, Resident doctor of orthodontics department at government dental college,
Jaipur.

Abstracts: Adult patients with severe skeletal malocclusions require orthognathic surgeries. During the treatment the patients can suffer from varieties of anxiety and the stress level. To assess the impact of orthognathic surgery in terms of anxiety and stress levels in pre-treatment and post-treatment one case report with skeletal Class II malocclusion due to retrognathic mandible discussed in this article. The patient was treated by bilateral sagittal split osteotomy mandibular advancement. Treatment results showed good improvement in facial profile, Angle Class I molar and canine relation, good occlusion after surgery for case. Also patients showed good improvement in psychiatric scores of anxiety and depression.

Keywords: Bilateral sagittal split osteotomy, mandibular advancement surgery, orthognathic surgery, skeletal Class II.

Date of Submission: 02-04-2022

Date of Acceptance: 15-04-2022

I. Introduction:

Skeletal Class II malocclusion with mandibular deficiency is one of the most common problems that patients seek treatment. Adult patients with severe skeletal Class II malocclusion need orthognathic surgery for successful treatment¹. Bilateral sagittal split osteotomy (BSSO) is the most often preferred technique for these patients. This procedure includes three phases: (1) presurgical orthodontic phase, (2) surgical phase, and (3) postsurgical orthodontic phase. BSSO along with orthodontic treatment improves hard-tissue relationship along with soft-tissue profile improvement. Most patients with dentofacial deformity are usually less confident and suffer from the negative impact of the deformity. Not only their physical health such as oral function but also social function and other psychosocial condition can be affected. Low self-esteem and poorer oral health-related quality of life were reported as well as emotion problems including depression and anxiety¹. Several studies have shown those with dentofacial deformity report more distress and insecurity compared to the control group, regarding their facial appearance^{2,4}. Patients tend to exhibit more psychological stress in social situations than those with other jaw deformities³. Thus, most people would try to find a way to fix their problem. Among the reasons to receive orthognathic surgery, the aesthetic desire is frequently and mostly reported, and there are other reasons such as functional improvement. To evaluate the psychology of patient, HAM-A, AAI and Beck's Depression inventory scale were used and pre surgical and post surgical score was compared. After the comparison it was noticed that scores were reduced, indicating patient anxiety and depression related to her physical appearance were reduced.

Case:

- A 16 year 4 months old female patient reported to the Department of Orthodontics with a chief complaint of forwardly placed upper front teeth. Clinical examination revealed Angle's class II division 1 malocclusion on class II skeletal bases due to retrognathic mandible with vertical growth pattern having spacing in upper and lower arch, Proclined maxillary & mandibular incisors, overjet 9 mm and overbite 5.5 mm, rotated 11, 21 and increased curve of spee of 3mm with TSALD of 2 mm in maxilla and 6 in mandible.
- Convex profile, incompetent lip & protruded lower lip.

Psychological screening and evaluation assessment: for psychological screening and evaluation HAM-A (Hamilton anxiety rating scale), Appearance Anxiety Inventory(AAI) and Beck's Depression inventory scale were used. According to these scales the patient was depressed and anxious due to facial appearance. Self confidence was low. According to orthodontic point of view the patient was not that much of facially deformed. But patient thought that she was less beautiful than others, this is indicating body dysmorphic syndrome.

According to HAM-A scores indicating anxiety (scores 18)⁶, Beck's depression inventory scale showing mild depressive symptoms (scores 24)⁷ and the AAI scores were (22)⁸ indicating that patient was anxious about their appearance.

Treatment plan:

Case started with pre adjusted edgewise mechanotherapy after leveling & alignment, intrusion of maxilla was done by TAD. After that dental decompensation was done in lower arch by extraction of lower first premolars followed by retraction with 9mm NiTi closed coil springs. Then orthognathic surgery was planned, surgical predication & mock surgery was done. Treatment plan and BSSO with mandibular advancement was suggested both to the patient and her parents, and a written informed consent was obtained. Surgery was done under GA. Later gingivectomy was done in upper arch from premolar to premolar region followed by finishing & detailing.

Treatment progress:

Treatment progress both the upper and lower arches were banded and bonded with 0.022" slot preadjusted MBT bracket prescription (McLaughlin, Bennett, and Trevisi). Upper and lower arches were leveled and aligned using the nickel–titanium (NiTi) wires. Wire sequence was 0.016" NiTi, 0.018" NiTi, 0.016" × 0.022" NiTi, and 0.019" × 0.025" NiTi. Space closure was done on 0.019" × 0.025" stainless steel wires, and 0.021" × 0.025" stainless steel stabilizing wires were placed in upper and lower arches. Presurgical records were taken [Figure 4 to 9], models were mounted [Figure 10], mock surgery [Figure 11] was done, and a surgical splint was fabricated. Mandibular advancement of 10 mm with BSSO was performed, and osteotomy cuts were secured with titanium plates. Finishing and detailing was done for 4 months, and debonding was done after achieving the preset treatment goals. An upper wraparound retainer and a lower fixed bonded lingual retainer were given.

II. Discussion:

Clinical and cephalometric findings of the patient in this case report had skeletal Class II bases due to retrognathic mandible and orthognathic maxilla, with proclination of the upper and lower anterior teeth. Case was treated by the extraction method because of proclination of lower anterior teeth and in upper arch intrusion and retraction was done due to spacing. After the completion of presurgical orthodontic phase, mock surgery was done [Figure 11]. Later, BSSO advancement was done. Superimposition of pretreatment and posttreatment lateral cephalometric tracings was done [Figures 16]. There was a change of 7° for SNB and 6° ANB with no change in maxillary position and an increase in mandibular plane angle. Demonstrating both sagittal and vertical skeletal changes, which translated into a reduced facial convexity and an increased lower facial height [Tables 1] and a pleasing soft-tissue facial profile. Molars and canines were finished in Class I with ideal overjet and overbite. The post surgical values of HAM-A (12) AAI (7) and beck's depression inventory scale were (12) indicating that patient was psychologically improved.

III. Conclusion:

A skeletal Class II malocclusion treated with proper diagnosis and treatment planning improves the esthetic value of the patient. In the present article skeletal Class II cases with orthognathic maxilla, retrognathic mandible, and reduced lower anterior facial height treated with BSSO were presented which not only improved the overall facial esthetics but also resulted in good occlusion. The good occlusion and the improved facial profile improved the psychiatric behaviour of the patient.

Declaration of patient consent:

The authors certify that they have obtained all appropriate patient consent forms. In the form the patient(s) has/have given his/her/their consent for his/her/their images and other clinical information to be reported in the journal. The patients understand that their names and initials will not be published and due efforts will be made to conceal their identity, but anonymity cannot be guaranteed.

Financial support and sponsorship: Nil.

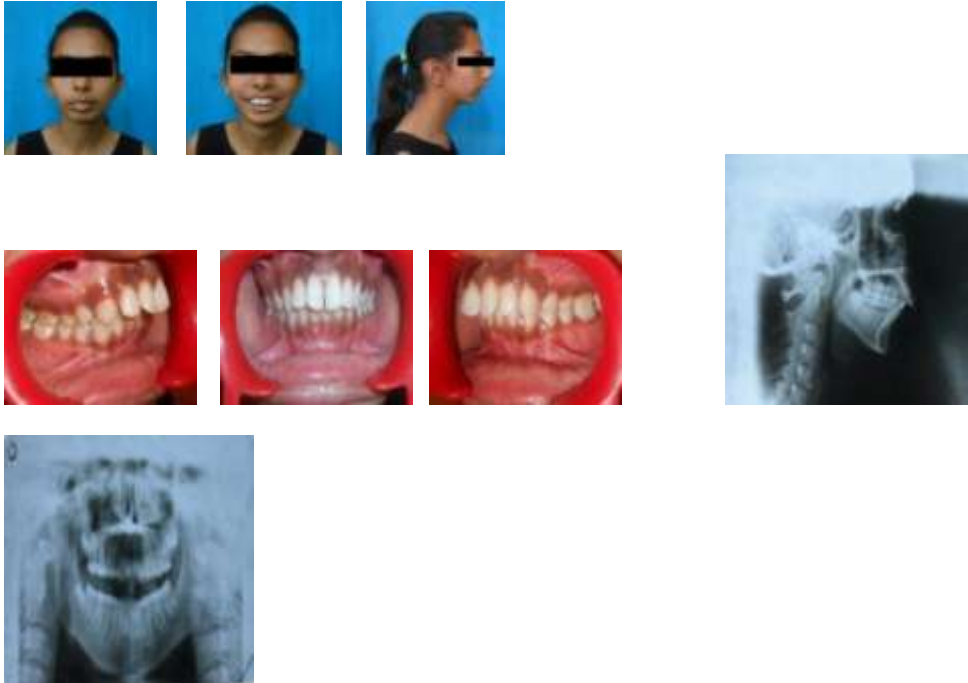


Fig.1 (Pre treatment photographs)

fig.2 (Pre treatment radiograph)

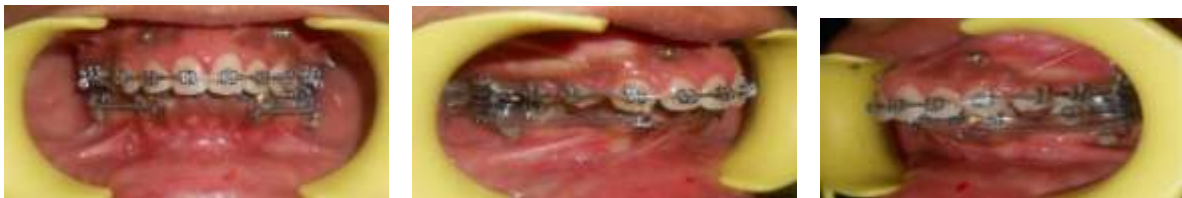

Fig.3 (Retraction mechanics)




Fig.4 (Pre surgical photographs)

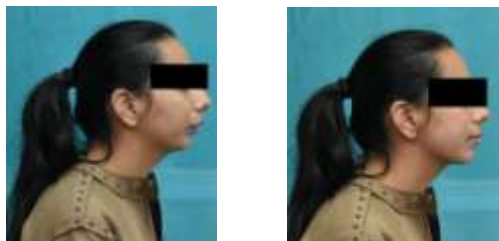

Fig.5 (VTO)

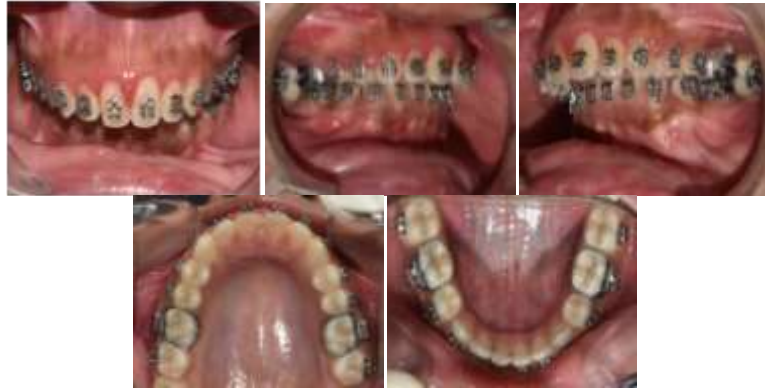

Fig.6 (Pre surgical intra oral photographs)

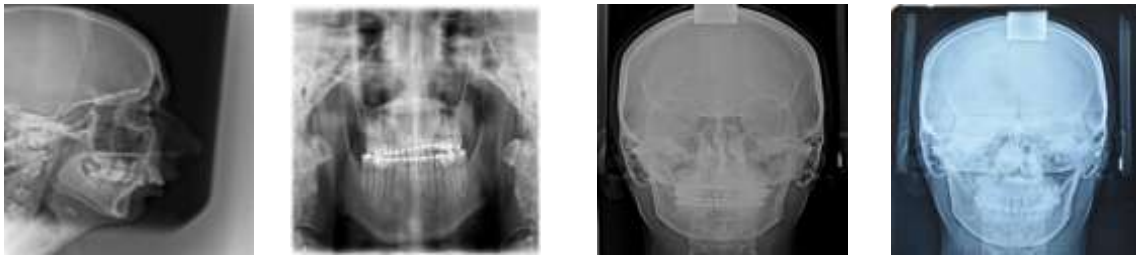

Fig.7 (Pre surgical radiographs)

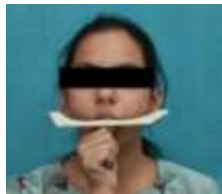
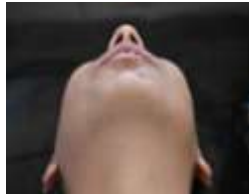
Fig.8 (Pitch & roll identification)



(submentoververtex view)



(Dolphin prediction)

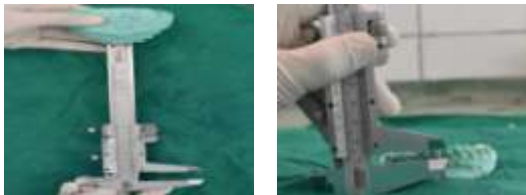

Fig.9 (Overbite & overjet measurement)



fig.10 (Mounting on hanau articulator)



Fig.11 (Mock surgery)

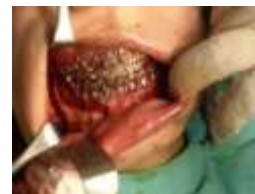

fig.12 (Bilateral saggital split osteotomy)

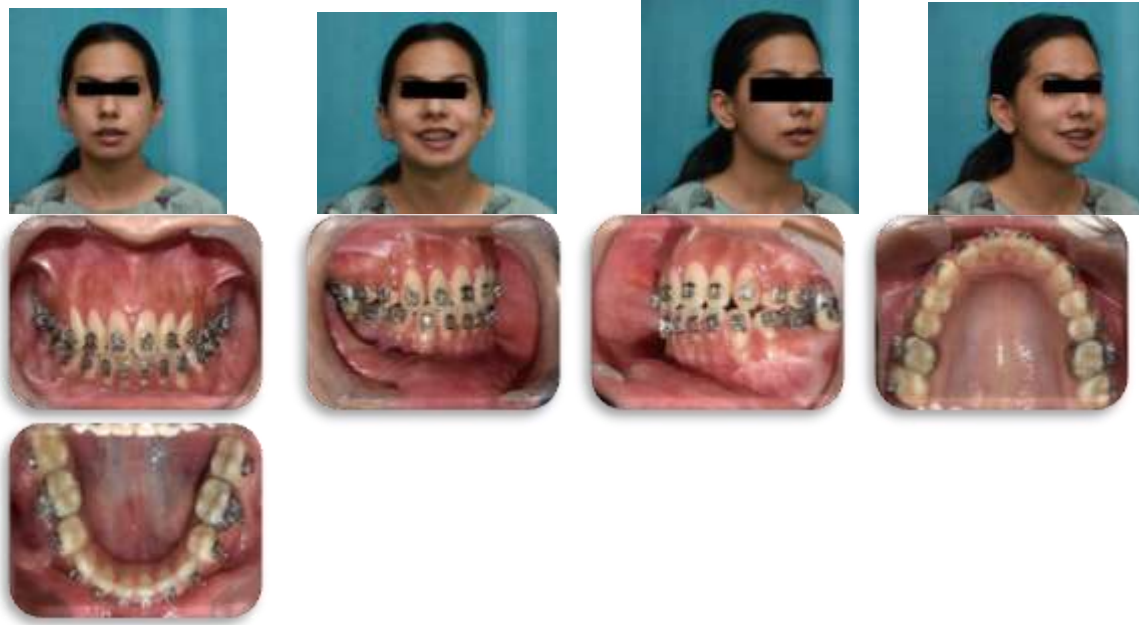

Fig.13 (Post surgical photographs)

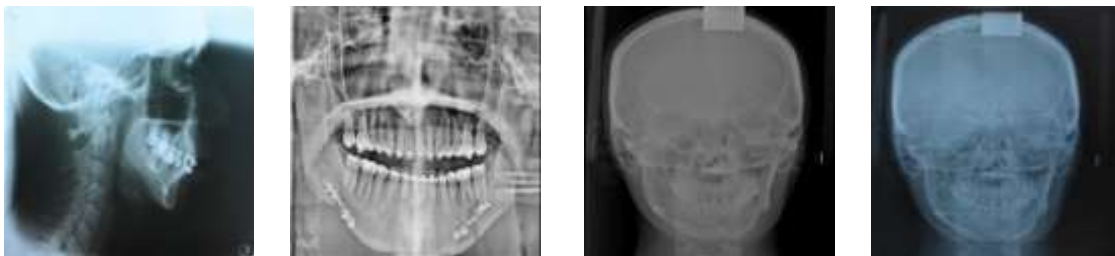


Fig.14 (Post surgical radiographs)

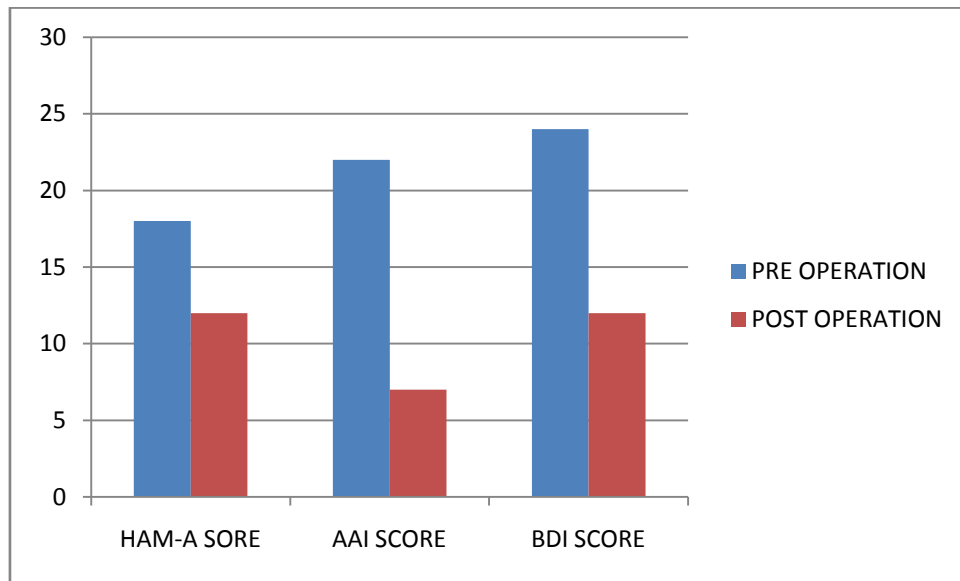
Table-1 (Pre treatment & post treatment cephalometric values)

s.no	measurements	Pre treatment	Mid treatment	Post treatment
1.	Position of maxilla			
	SNA	82	83	83
	N perpendicular to point A	-15	0	0
2.	Position of mandible			
	SNB	72	73	79
	Facial angle	79	79	83
3.	Maxillomand relation			
	ANB	10	10	4
	WITTS (AO-BO)	+11	+11.5	0.5
	AB TO N-POg	-13	-14	-5
	Beta- angle	21	22	27
4.	Effective length			
	Maxilla	92	92.5	92.5
	Mandible	111	111	121
	LAFH	68	67	68
5.	Growth pattern			
	GO-Gn to SN	40	37	37.5
	FMA	37	34	35
	Y- axis	68(down)	67	68
	Facial axis angle	-10	-9.5	-5
	Jaraback ratio	59.9%	62%	61.5%
	Gonial angle	131	129	130
6.	Dental			
	Interincisal angle	102	121	121
	Upper incisor to point A vertical	+6	+3	+3
	Upper incisor to SN	111	103	103
	Upper incisor NA(angle)	28	20	20
	Upper incisor NA(mm)	+6mm	+3mm	+3mm
	IMPA	104	94	95

	Lower incisor to A-POg	5.5mm	3mm	3mm
	Lower incisor to NB(angle)	39	28	28
	Lower incisor to NB(mm)	+12.5mm	+5mm	+5mm
7.	Soft tissue			
	S-line Ulip/L lip	+4.5/+6mm	+4/+2.5mm	+2/+3mm
	Upper lip curvature	3mm	1mm	1mm
	Nose tip to H-line	-3mm	-1mm	+3.5mm
	Upper sulcus depth	11mm	8mm	5mm
	Upper lip strain	4mm	0	0
	Lower lip to H-line	+4mm	0	+2mm
	Soft tissue chin thickness	11mm	11mm	11mm
	Nasolabial angle	91	110	110
	Lower lip to E-line	+4.5mm	0.5mm	0.5mm
	Upper lip thickness	15mm	14mm	14mm

Table-2 psychiatric scores of HAM-A Scale, AAI Scale, Beck’s depression anxiety scale

Psychiatric scales	Pre treatment	Post treatment
HAM-A scale	18	12
AAI scale	22	7
Beck’s depression anxiety scale	24	12



Graph- 1 (psychiatric scores of HAM-A Scale, AAI Scale, Beck’s depression anxiety scale)

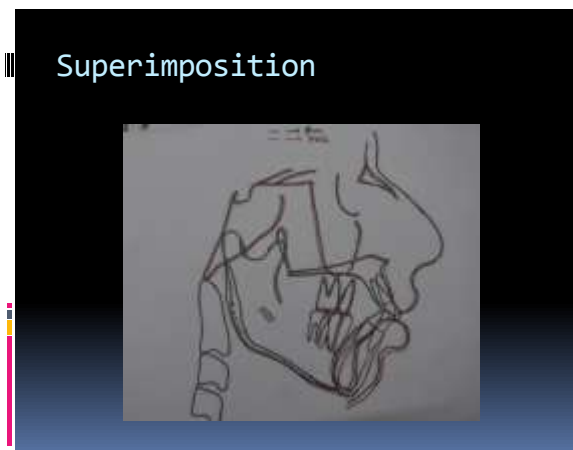


Fig.16 (Cephalometric superimposition)

References :

- [1]. McNeill RW, West RA. Severe mandibular retrognathism: Orthodontic versus surgical orthodontic treatment. *Am J Orthod* 1977;72 : 176-82.
- [2]. Proffit WR, White RP Jr. Mandibular deficiency in patients with normal or short face height. In: Proffit WR, White RP Jr., editors. *Surgical-Orthodontic Treatment*. St. Louis: C. V. Mosby; 1990. p. 334-77.
- [3]. Bailey LJ, Proffit WR. Combined surgical and orthodontic treatment. In: Proffit WR, Fields HW Jr., editors. *Contemporary Orthodontics*. 3rd ed. St. Louis, MO: Mosby; 1999. p. 674-709.
- [4]. Villanueva JJ, Estrada HA, Carvalho JR, Garcia MG. Surgical-orthodontic treatment in a Class II malocclusion patient. Case report. *Rev Mex Ortod* 2016;4:e85-92.
- [5]. Shelly AD, Southard TE, Southard KA, Casco JS, Jakobsen JR, Fridrich KL, et al. Evaluation of profile esthetic change with mandibular advancement surgery. *Am J Orthod Dentofacial Orthop* 2000;117:630-7
- [6]. Hamilton M. The assessment of anxiety states by rating. *Br J Med Psychol* 1959;32:50-55.
- [7]. Psychometric properties of the Beck Depression Inventory: Twenty-five years of evaluation, *clinical psychological review*, vol. 8, issue 1, 1988, page no. 77-100.
- [8]. The appearance anxiety inventory: Factor structure and associations with appearance-based rejection sensitivity and social anxiety, Carly Roberts, Melanie J. Zimmer-Gembeck Cassie Lavell Takayuki Miyamoto Eva Gregertsen L ara J. *journal of obsessive-compulsive and related disorders*. Vol.19 october, pages 124-130.

Dr. Sunita Saini, et. al. "Orthognathic surgery & the psychological impact: a Case report." *IOSR Journal of Dental and Medical Sciences (IOSR-JDMS)*, 21(04), 2022, pp.13-19.