

Immunohistochemical expression of p63 in meningiomas

Alisha Aliyar¹, Geetha K²

¹Department of Pathology, Government medical college, Kannur/ Kerala University of Health Sciences, India)

²(Department of Pathology, Government medical college, Kannur/ Kerala University of Health Sciences, India)

Abstract:

Background: Meningiomas are the most common tumours of the central nervous system. They are graded based on histological criteria into 3 grades based on WHO 2016 CNS tumours. Grade II and III are aggressive meningiomas. Sometimes histological criteria alone are insufficient to predict biological behavior and grade them especially in small biopsies. Several immunohistochemical markers have been studied for differentiating benign from aggressive types. KI-67 is the most commonly used for predicting recurrence of meningiomas. P63, a family of p53 gene have been shown to play an important role in neoplasia including metastasis. Only few studies have been done to assess p63 expression in meningioma.

Materials and Methods: This was a descriptive study. A total of 30 cases of meningiomas diagnosed on histopathological examination from January 2020 to January 2021 were included. Of these 17 were grade I, 9 grade II and 4 grade III. P63 IHC was done along with the routine ki67 staining on the representative blocks of tumour. Results were subsequently analysed.

Results: Higher p63 staining was seen in grade II and grade III meningioma. P63 positivity was seen in 7/9 grade II and 3/4 grade III meningiomas. P63 was significantly associated with grade and showed moderate correlation. 3 cases of grade I meningioma which showed high p63 expression did not show high KI-67. KI-67 was also significantly associated with grade but showed poor correlation.

Conclusion: P63 expression is associated more with higher grade meningiomas which was also noted in the previous studies done. P63 was better correlated with grade when compared to ki67 but both p63 and ki67 were significantly associated with higher grade of meningioma. Few of the benign cases that showed high p63 expression did not show elevated ki67. Thus p63 may not be used a sole marker in differentiating between the grades but can be used in adjunct with ki67, progesterone receptor that are routinely used along with histological grading

Keywords: P63, KI-67, meningioma, Immunohistochemistry

Date of Submission: 08-03-2022

Date of Acceptance: 24-03-2022

I. Introduction

Meningioma is one of the most common intracranial tumours with a slight female preponderance. Meningiomas constitute 24 to 30% of all the Central Nervous System tumors.¹ Revised WHO classification of tumours of CNS 2016, histologically classifies meningioma into three grades: well differentiated (grade I), atypical (grade II), and anaplastic (grade III)¹. Meningiomas are graded based on their histological anaplasia and potential for aggressive behavior. . However, these histological criteria for grading are sometimes not fulfilled and other criteria are necessary for prediction of biological behavior of meningioma .The immunohistochemical markers which have been studied to assist the grading include proliferation markers such as MIB-1^{2,3}, P62⁴, claudin⁵, and progesterone receptors of which MIB-1(KI-67) is most commonly used. Recent investigations have shown the role of p63 in tumorigenesis in various tumors such as squamous cell carcinomas. Most of the studies in meningiomas are p53 based and only very few studies based on p63 expression have been mentioned in literature.

II. Material And Methods

This descriptive study was carried out in Department of pathology at GMC Kannur, kerala from january 2020 to January 2021. A total of 30 biopsy specimens of histologically confirmed meningioma cases were selected and p63 and KI67 was done in all the cases. Available clinical data, including patient age, sex, clinical and radiological findings were retrieved from the records.

Study Design: Descriptive study

Study Location: This was a tertiary care teaching hospital based study done in Department of Pathology at government medical college , kannur

Study Duration: January 2020-January2021

Sample size: 30 cases

Sample size calculation: sample size was calculated based on the formula $n = \frac{(Z_{1-\alpha/2} + Z_{1-\beta})^2}{r^2}$ where

$$Z_{1-\alpha/2} = 1.96$$

$$Z_{1-\beta} = 1.28 \text{ and } r = 0.683 \text{ (correlation coefficient obtained from the study by rushing et al}^9\text{)}$$

Subjects & selection method : All the cases of meningioma which came to our department during the study period were included. Since only few cases of atypical and anaplastic were received ,we included atypical and anaplastic meningiomas which we received in the previous 2 years from the study period so that the p63 expression could be better studied in grade 2 and 3 meningiomas

Inclusion criteria:

Diagnosed cases of meningiomas irrespective of site in the department of pathology, GMC Kannur during the study period.

Exclusion criteria:

Inadequate and poorly processed samples were excluded

Procedure methodology

All histopathologically proven meningiomas were be taken into study. Formalin fixed sections underwent tissue processing and stained using Hematoxylin and Eosin stain. The steps of tissue processing include dehydration, clearing, impregnation and embedding. Histopathology of the sections are identified by examination under the microscope. Subtyping and grading were done based on WHO classification of tumors of central nervous system,2016 and Eosin stain. The steps of tissue processing include dehydration, clearing, impregnation and embedding. Histopathology of the sections are identified by examination under the microscope. Subtyping and grading will be done based on WHO classification of tumors of central nervous system,2016 Immunohistochemistry for p63 and KI-67 was done on all the histologically diagnosed cases.

Immunoreactivity to p63 was scored semiquantitatively based on nuclear and cytoplasmic positivity in the neoplastic cells of an average of 10 high power field.The p63 staining was graded as follows : no staining, less than 10% of cells , 10-50% cells , more than 50% cells

Expression of ki-67/mib-1 is determined as percentage by counting 1000 nuclei in the busiest foci of tumour.

Statistical analysis

Data was entered into Microsoft excel and analysed using spss software. Descriptive statistics like frequency, percentages, mean and standard deviation was used. Inferential statistics like spearman’s rank correlation coefficient and chi square test will be used to assess the correlation between p63,KI-67and histological grading . P value< 0.05 is considered statistically significant

III. Result

A hospital based descriptive study was done to assess p63 immunohistochemical expression on 30 biopsy proven cases of meningiomas during the study period 2020-2021.Grading of meningioma was done based on histological criteria in WHO 2016 classification of CNS tumours.

The age of the patient ranges from 30 to 79 yrs. The maximum number of patients were in the age group 60-69 yrs. Out of 30 patients 17 were females and 13 males.Most of the meningiomas were intracranial of which most commom site was parietal region

Most of the meningiomas were grade1 (56.7%), 30 % were grade II and 11% were grade III meningiomas.Table no.1 shows the frequency of the 3 grades of meningiomas

Table no 1 :showing frequency of the 3 grades of meningioma

GRADE	Frequency	Percent
I	17	56.7
II	9	33.3
III	4	11
Total	30	100

Table no.2 : showing frequency of different histological subtypes

TYPE	Frequency	Percent
MENINGIOTHELIAL	7	23.3
TRANSITIONAL	6	20
FIBROUS	2	6.7
ANGIOMATOUS	1	3.3
MICROCYSTIC	1	3.3
ATYPICAL	9	29.9
ANAPLASTIC	4	13
Total	30	100

Table3 shows the frequency distribution of the three grades and p63 staining . Of the 17 benign meningiomas (grade1), 3 cases of grade 1 tumors showed nuclear reactivity for p63 protein (17.7%) whereas 14 cases were either completely negative or showed nuclear expression in fewer than 10% of tumor cells. 7 cases of grade II and 3 cases of grade III were positive for p63 protein (63.6%). The association between histological grade and p63 was done using chi square test and was found to be significant (p value <0.01). Correlation between grade and p63 was done and the spearman's rank correlation coefficient was 0.546 and p value =0.002.

Table no. 3: frequency distribution and association between p63 and grade of meningioma

p63	Grade						Total	
	I		II		III		N	%
	N	%	N	%	N	%		
No staining	13	76.5	2	22.2	1	25	16	53.3
<10%	1	5.9	0	0	0	0	1	3.3
10-50%	1	5.9	0	0	1	25	2	6.7
>50%	2	11.8	7	77.8	2	50	11	36.7
Total	17	100	9	100	4	100	30	100
	χ^2	df	p					
Chi-Square test	43.197	12	0.002					

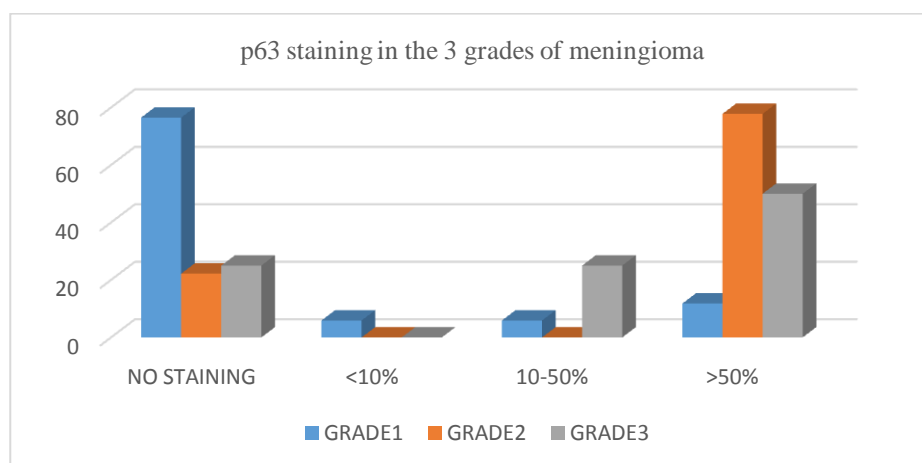


Table no. 4 : p63 staining in different histological subtypes

Type	P63							
	No staining		<10%		10-50%		50%	
	N	%	N	%	N	%	N	%
MENGIOTHELIAL	5	31.3	1	100	0	0	1	9.1
TRANSITIONAL	5	31.3	0	0	0	0	1	9.1
FIBROUS	2	12.5	0	0	0	0	0	0
ANGIOMATOUS	1	6.3	0	0	0	0	0	0
MICROCYSTIC	0	0	0	0	1	50	0	0

ATYPICAL	2	12.5	0	0	0	0	7	63.6
ANAPLASTIC	1	6.3	0	0	1	50	2	18.2
Total	16	100	1	100	2	100	11	100

Table no. 4 shows >50% nuclear staining in atypical and anaplastic meningiomas while of the grade 1 meningiomas only 1 meningothelial and 1 transitional types showed more than 50% staining and 1 microcystic type showed 10-50 % nuclear staining for p63. No staining was seen in 2 of the atypical and 1 anaplastic meningioma

Table no.5: showing ki67 index in the 3 meningioma grades

Ki 67	Grade						Total	
	I		II		III			
	N	%	N	%	N	%	N	%
0-4 %	14	82.4	3	33.3	2	50	19	63.3
4.1-7 %	3	17.6	2	22.2	0	0	5	16.7
7.1-11%	0	0	2	22.2	0	0	2	6.7
>11%	0	0	2	22.2	2	50	4	13.3
Total	17	100	9	100	4	100	30	100

Table no.5 Shows ki-67 in different grades of meningioma. All grade 1 meningiomas showed ki67 index less than 7 %. Higher ki67 index was seen in grade II and grade III meningiomas. Chi square test done to find association between grade and ki67 and p value was found to be significant (p= 0.023).

Higher ki67 of 7.1-11% and > 11% were found in atypical and anaplastic meningioma. Meningothelial and transitional subtypes showed predominantly less than 4 % ki67 index. Only 2 meningothelial and 1 transitional type showed ki67 4-7.1%

IV. Discussion

30 biopsies of histologically proven meningiomas were analysed during the study period. Of which 17 were grade 1, 9 grade II and 4 grade III meningiomas and p63 and ki-67 immunohistochemical markers were done.

The most frequent age group in our study was 60-69 yrs while in the other studies mean age group was 40- 49 yrs in mittal et al⁹ and in shareifi et al⁸ the mean age group was 50-59yrs.

In our study most of the patients were females; 56.7% females compared to 43.3% males. Most of the meningiomas were intracranial of which parietal was the most common location. 66.6 % tumours involved brain convexities while 33.3 % of tumours occurred in other locations like CP angle, intraspinal and olfactory. Of the histological subtypes in grade I meningiomas, meningothelial is the most common followed by transitional fibrous then microcystic and angiomatous. Benign or grade I meningiomas are most commonly encountered, whereas atypical or grade II and anaplastic or grade III meningiomas are rare. Anaplastic meningiomas in general constitute 1% to 2% of all meningiomas. In the present series, the percentage of gradeII and III tumors is higher (29.9% and 13%) than described. Because there were a fewer number of anaplastic variants in earlier series, we wished to examine the expression of p63 in more number of malignant cases to validate its role. Hence all the atypical and anaplastic cases in the previous 1 year from our study period were also included.

Only 4 literatures have been published so far regarding p63 expression in meningiomas and all of them have described the association between p63 and histological grade. All 4 studies have tried to evaluate p63 IHC expression in all three 3 grades and compared it with the standard ki67 staining. Several studies have been conducted using various markers to assist with the histological grade but no single marker has been found to correctly differentiate benign from aggressive meningiomas. This study has used p63 immunohistochemical expression in all the three grades of meningioma.

In all of the 17 benign meningiomas (grade1), 3 cases of the grade 1 tumors showed nuclear reactivity for p63 protein ,whereas 14 cases were either completely negative or showed nuclear expression in fewer than 10% of tumor cells. Also, 7/9 cases of grade II and 3/4 cases of grade III were positive for p63 protein (Table 6). The association between histological grade and p63 was done using chi square test and was found to be significant (p value 0.02). Our findings are similar to the studies done by mittal et al and shareifi et al where most of the grade II and grade III meningiomas showed nuclear positivity for p63

Table no. 6: Shows comparison of percentage of p63 nuclear staining in meningioma done in previous studies and present study

GRADES	Rushing et al ⁶	Shareifi et al ⁸	Mittal et al ⁹	Somalwar et al ⁷	Present study
Grade1	5%	16%	34.9%	16%	17.7%
Grade2	92%	75%	63.6%	100%	77.8%
Grade3	75%	100%	63.6%	100%	75%

In the study by rushing et al cytoplasmic and nuclear staining for p63 was noted and higher grade tumours showed more cytoplasmic staining⁶. However no cytoplasmic staining for p63 was seen in our study and also in the other studies by mittal et al⁹, somalwar⁷ and shareifi et al⁸.

All the 4 studies showed a statistical significance (p value < 0.05) when correlating p63 with histological grade which was reciprocated in our study. The spearman rank correlation in the present study was 0.546 and the p value 0.002; thus p63 and grade showed moderate correlation and was highly significant.

Higher ki67 expression was seen in grade II and grade III meningiomas. 3 of the 9 grade II and 2 of the 4 grade III only showed ki67 less than 4 %. Chi square test done showed ki67 and grade of meningioma were significantly associated p value=0.023(< 0.05) and spearman rank correlation coefficient of 0.4 was obtained (weak correlation) . In our study all the cases of gradeI meningioma that showed high p63 expression did not show elevated ki67 and this is similar to mittal et al where ki67 index was not elevated in p63 positive grade I meningiomas. However in somalwar et al grade 1 tumours with high p63 expression also showed high ki-67. p63 showed better correlation with grade compared to ki67 with grade (r=0.546 and r=0.4 respectively) .

V. Conclusion

P63 expression is associated more with higher grade meningiomas. No significant association was found with other variables like age, gender and site of tumour. P63 was better correlated with grade when compared to ki67.

References

- [1]. Weltgesundheitsorganisation. *WHO classification of tumours of the central nervous system*. (International Agency for Research on Cancer, 2016).
- [2]. Abramovich, C. M. & Prayson, R. A. MIB-1 labeling indices in benign, aggressive, and malignant meningiomas: A study of 90 tumors. *Hum. Pathol.* **29**, 1420–1427 (1998).
- [3]. Challa, S. *et al.* Meningiomas: Correlation of Ki67 with histological grade. *Neurol. India* **59**, 204 (2011).
- [4]. Kärjä, V. & Alafuzoff, I. Protein p62 common in invaginations in benign meningiomas—a possible predictor of malignancy. *Clin. Neuropathol.* **25**, 37–43 (2006).
- [5]. Hahn, H. P., Bundock, E. A. & Hornick, J. L. Immunohistochemical staining for claudin-1 can help distinguish meningiomas from histologic mimics. *Am. J. Clin. Pathol.* **125**, 203–208 (2006).
- [6]. Rushing, E. J., Olsen, C. & Man, Y.-G. Correlation of p63 Immunoreactivity With Tumor Grade in Meningiomas. *Int. J. Surg. Pathol.* **16**, 38–42 (2008).
- [7]. Somalwar, S. B., Bajaj, N. K., Madabhushi, S. & Arasi, E. Prognostic Significance of Ki 67 Labelling Index and P63 Immunoreactivity in Intra Cranial and Intra Spinal Meningiomas. *Ann. Pathol. Lab. Med.* **03**, 7 (2016).
- [8]. Sharifi, N. & Katebi, M. An Immunohistochemical Study of P63 Protein Expression in Meningioma. *5* (2008).
- [9]. Mittal, S., Jain, D., Roy, S. & Mehta, V. S. Correlation of p63 Protein Expression With Histological Grade of Meningiomas: An Immunohistochemical Study. *Int. J. Surg. Pathol.* **20**, 349–354 (2012).

Alisha Aliyar, et. al. “Immunohistochemical expression of p63 in meningiomas.” *IOSR Journal of Dental and Medical Sciences (IOSR-JDMS)*, 21(03), 2022, pp. 27-31.