

Comparative Study of Stoppa's Repair by Pfannensteil Incision Versus Lichtenstein Technique for Management of Bilateral Inguinal Hernia

Dr. DEEPAK J VORA, Dr. UNNATI S PATEL

Dr KUSH DHAMA, Dr HARSH PANDYA

Smt S.C.L. Muni. General Hospital, Saraspur, Ahmedabad Department of General Surgery

Smt NHL Municipal Medical College, Ahmedabad

Associate Professor, Dept. Of General Surgery, Smt Scl hospital Smt NHL Municipal medical college
ahmedabad

Assistant Professor, Dept. Of General Surgery, Smt scl hospital Smt NHL Municipal medical college ahmedabad

Resident Doctor, Dept. Of General Surgery, Smt scl hospital Smt NHL municipal Medical college ahmedabad

Resident Doctor, Dept. Of General Surgery, Smt scl hospital Smt NHL municipal Medical college ahmedabad

Corresponding author: Kush Dhama

Abstract

Background: Hernia repair is one of the most commonly performed general surgical procedures worldwide. Today, Stoppa's repair has been considered as an alternative to Lichtenstein's tension free mesh hernioplasty in the case of bilateral inguinal hernias. This new technique is theoretically closer to ideal hernia repair and based on the concept of providing a strong, mobile and physiologically dynamic posterior inguinal wall. The technique is simple, easy to learn and does not require complicated dissection or suturing. **Aims and Objectives:** To establish the influence of Stoppa's repair on early clinical outcomes of bilateral inguinal hernia repair and limited study of long term outcomes, especially with regards to post-operative pain, operative time, wound complications, recurrence, time taken to ambulate etc.

Settings and Design: This is a comparative study carried out in 40 patients, out of which 20 underwent Lichtenstein's repair and 20 underwent Stoppa's repair, admitted in surgical ward in Smt SCL Gen Hospital, Ahmedabad

Materials and Methods: Data was collected by meticulous history taking, careful clinical examination, appropriate radiological, haematological investigation, operative findings and follow-up of the cases.

Results: Post-operative pain relief was more in Stoppa's group compared to Lichtenstein group on day 1, 3 and 7. Also, early and late wound complications were lesser in Stoppa's group compared to Lichtenstein's group. Patients of Stoppa's group returned to routine work faster compared to Lichtenstein group. Chronic groin pain was found to be less incident in Stoppa's group, but that was not statistically significant due to the limited follow-up period. There was no recurrence seen in both groups during the 3 months follow-up period.

Conclusion: It can be reliably concluded that Stoppa's repair using pfannensteil incision is definitely a promising procedure for the management of patients with bilateral inguinal hernias.

Keywords: Stoppa's repair, Lichtenstein's meshplasty, Inguinal hernia, Postoperative Pain, Hernioplasty.

Date of Submission: 28-01-2022

Date of Acceptance: 09-02-2022

It has been said that the history of grain hernias is the history of surgery of . Hernia repair is one of the most commonly performed general surgical produture worldwide. Since the time Bassini described his technical the search for an ideal Inguing Hernia reapiir is still on An Ideal Hernia repair should be Tension free, Tissue based, with no potential damage to vital structures, no Long Term pain or complications and no recurrence.

Lichtenstein's prosthetic repair using prolene mesh has been popular lately & it is a tension free repair. The mesh works as a mechanical barrier, but it does not give mobility and physiologically dynamic posterior wall.³ Moreover this technique is associated with risk of infections, recurrence, chronic pain testicular atrophy and infertility, foreign body sensations and chronic groin sepsis which sometimes may require mesh removal.⁴

Other tissue repairs like such as modified Bassini, Iliotibial tract repair, Shouldice, Nylon- Darn, Halsted- Tanner, McVay and many others either requires good surgical experience or are tension repairs fraught with recurrences. Recurrences vary from surgeon to surgeon and centre to centre owing to complexity of the procedures.⁵

The Stoppa's Repair first described in 1975 by Rene Stoppa, also known as giant prosthetic reinforcement of the visceral sac (GPRVS), is a tension free type of hernia repair, which is performed by wrapping the lower part of the parietal peritoneum with prosthetic mesh and placing it at a preperitoneal level through pfannensteil incision. This technique has met particular success in the repair of bilateral hernias, large scrotal hernias, and recurrent hernias in which conventional repair is difficult and carries a high morbidity and failure rate.

This new technique is theoretically closer to ideal hernia repair and based on the concept of providing a strong, mobile and physiologically dynamic posterior inguinal wall. The technique is simple, easy to learn and does not require complicated dissection or suturing.

The purpose of this study is to attempt to establish the influence of this new technique on early clinical outcomes of bilateral inguinal hernia repair, and limited study of long term outcomes.

I. Materials and Methods

This is a comparative study carried out in 40 patients admitted in surgical ward in Smt SCL Gen Hospital, Ahmedabad with a follow up period of 3 months. All patients of bilateral inguinal hernia and age more than 18 years were included in this study. Patients with complicated inguinal hernia, obstructed or strangulated inguinal hernia, previous abdominal surgery, local skin infection and age less than 18 years were excluded. By simple randomization, patients were divided into two groups; Twenty of them undergoing Lichtenstein tension free mesh hernioplasty in which two separate inguinal incisions were kept and Twenty of them undergoing Stoppa's repair in which pfannensteil incision was kept. Purpose of the study and the methods of treatment were carefully explained to the patients individually and written informed consent taken. Detailed history was collected including age, chief complaints and duration, other associated conditions like chronic cough, chronic constipation, urinary complaints etc, history of previous abdominal surgeries, family history, occupation, marital status etc. Detailed physical examination was conducted by any experienced surgeon. Telephonic contact numbers and detailed addresses were collected for follow up.

Method of Lichtenstein Tension Free Mesh Hernioplasty

A 5–6 cm skin incision, which starts from the pubic tubercle and extends laterally within the Langer line, gives an excellent exposure of the pubic tubercle and the internal ring. After skin incision, the external oblique aponeurosis is opened.

Indirect hernial sacs are freed from the cord to a point beyond the neck of the sac and are inverted into the pre-peritoneal space without ligation. In the event of direct hernias, if large, the direct sacs are inverted with an absorbable suture. A sheet of 7.5×15cm of mesh is used preferably monofilament polypropylene meshes because their surface texture promotes fibroplasia and their monofilament structure does not perpetuate or harbor infection.

With the cord retracted upward, the sharper corner is sutured with a nonabsorbable monofilament suture material to the insertion of the rectus sheath to the pubic bone and overlapping the bone by 1 to 2 cm. This is a crucial step in the repair because failure to cover this bone with the mesh can result in recurrence of the hernia. A slit is made at the lateral end of the mesh, creating two tails, a wide one (two-thirds) above and a narrower one (one-third) below. The wider upper tail is grasped with forceps and passed toward the head of the patient from underneath the spermatic cord; this positions the cord between the two tails of the mesh. The wider upper tail is crossed and placed over the narrower one and held with a hemostat. With the cord retracted downward and the upper leaf of the external oblique aponeurosis retracted upward, the upper edge of the patch is sutured in place with two interrupted absorbable sutures, one to the rectus sheath and the other to the internal oblique aponeurosis, just lateral to the internal ring.

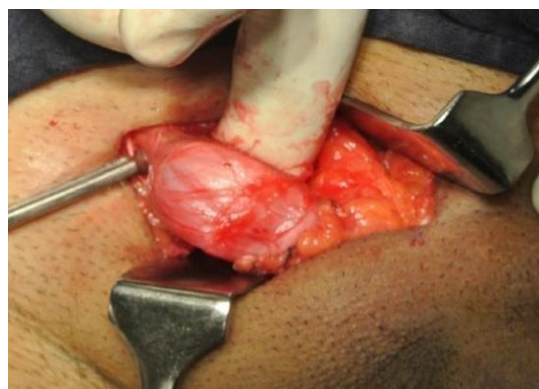

Figure 1: Separation of Sac and Cord structures

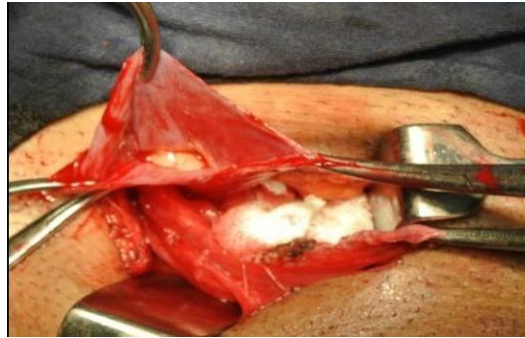

Figure 2: Reduction of sac contents and Ligation of sac

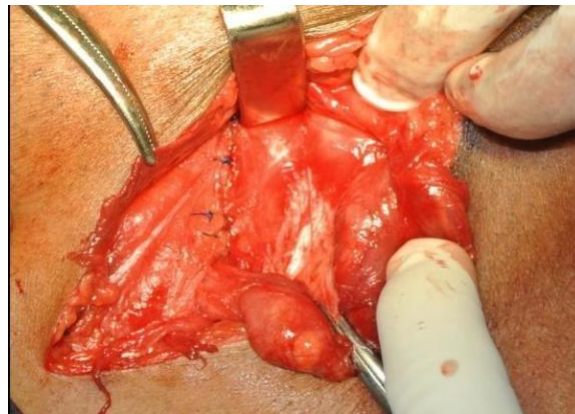


Figure 3: Preparation of posterior wall for Repair

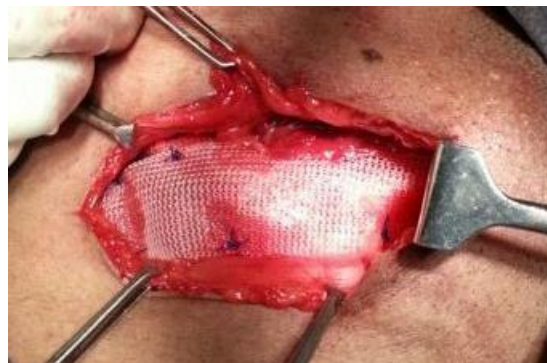

Figure 4: Placement and fixation of mesh with stay sutures

Using a single nonabsorbable monofilament suture, the lower edges of each of the two tails are fixed to the inguinal ligament just lateral to the completion knot of the lower running suture. The excess patch on the lateral side is trimmed, leaving at least 5 cm of mesh beyond the internal ring. This is tucked underneath the external oblique aponeurosis, which is then closed over the cord with an absorbable suture.

Method of Stoppa's Repair By Using Pfannensteil Incision

For all patients, a pfannensteil incision was used as a standard, followed by vertical separation of both recti to enter the preperitoneal space. Blunt dissection of the preperitoneal space was performed. Dissection involved the retropubic space of Retzius, and reached the rectus abdominis muscle and epigastric vessels laterally, extending to the retroinguinal space. The spermatic cord and gonadal vessels were visualized. The superior pubic ramus, the obturator foramen, and iliac vessels were exposed.

Direct hernias were identified and reduced. Large sacs were removed and ligated with a purse-string suture. Indirect sacs were divided, the proximal peritoneum was sutured, and the distal peritoneum was left in place attached to the cord. Separation of the spermatic cord and gonadal vessels was performed by dissection of their peritoneal attachment. Two prolene mesh of 15 by 15cm² were placed in the preperitoneal space in bilateral inguinal region. Fixation of the mesh was done by suturing mesh with pubic tubercle on both sides.

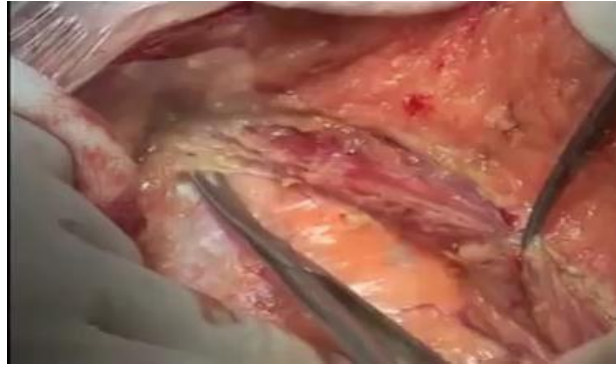

Figure 5: Vertical separation of both recti done to enter pre-peritoneal space

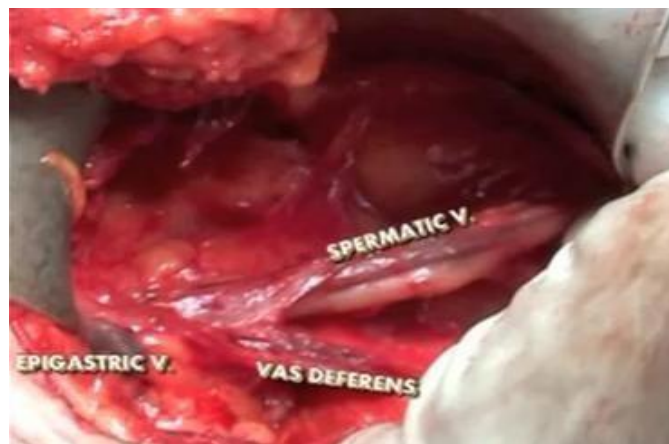

Figure 6: Spermatic cord and cord structures are identified and separated from hernia sac carefully

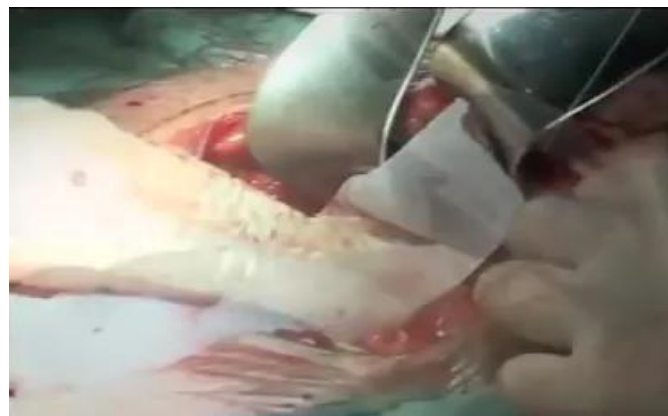

Figure 7: Prolene mesh is kept in preperitoneal region

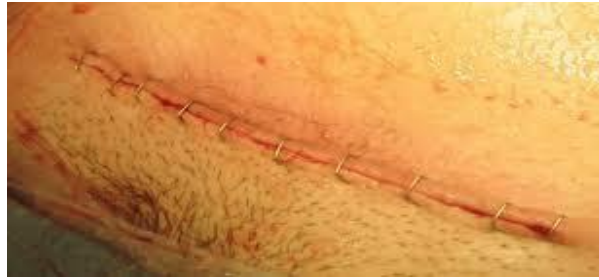

Figure 8: Skin is closed with staples

Inj. Ceftriaxone 1gm intravenously was given for all patients half an hour prior to surgery. Post operatively analgesia in the form of Inj. Diclofenac single dose and then Tab. Diclofenac 50mg twice a day for next 2 days was given to all patients. Per urethral catheter was done in all patients of Stoppa's group.

Operating time was measured as the time of total procedure i.e. starting from the skin incision till the final suture taken for skin closure. The patients were followed up for postoperative pain which was evaluated using Visual Analogue Score Scale on day 1, day 3 and day7, wound hematoma, seroma, wound infection, scrotal swelling, chronic pain and foreign body sensation. Time for return to routine daily activities done by the patient pre-operatively, postoperative duration of hospital stay and recurrence rate was also documented.

II. Observation and Results

This is a comparative study carried out in 40 patients, twenty of them undergoing Lichtenstein tension free meshplasty and twenty undergoing Stoppa's repair, admitted in surgical ward in Smt SCL Gen Hospital, Ahmedabad

The mean age of presentation in Lichtenstein group was 43.89 + 10.27 years and in Stoppa's group was 45.97 + 10.69 years. There was no significant difference in the age in both the groups (p=0.08).

The mean duration of the total surgery in Lichtenstein group was 74.68±2.86 mins while that in Stoppa's group was 64.43±2.59 mins. There was a statistically significant difference of nearly 10 minutes with a 'p' value of <0.0001.

Table 01: Comparison of Post-Operative Pain (VAS Scores)

STUDIES	LICHTENSTEIN	STOPPA'S	P Value
Youssef et al	2.8±1.6	2.4±1.9	0.09
Z Abbas et al	3.5±0.97	2.86±0.70	0.0004
Present study	5.93±1.12	4.39±1.03	<0.0001

Table 02: Post-operative complications

Complication		Surgery		Total
		Lichtenstein	STOPPA'S	
Fever	Count	2	3	5
	Percentage	10	15	12.5
Seroma	Count	8	10	18
	Percentage	40	50	45
Scrotal Swelling	Count	12	2	14
	Percentage	60	10	35
Hematoma	Count	1	0	1
	Percentage	5	0	2.5
Wound infection	Count	1	1	2
	Percentage	5	5	5

The Mean duration of Postoperative Hospital stay in Lichtenstein group was 3.89 + 0.69 while that in Stoppa Group was 3.35 + 0.48, with a statistically significant difference of 1.43 days with a P value of 0.003. Though some patients had to stay for prolonged duration due to complications it was not statistically significant as complications occurred in both groups.

The Mean duration (in days) to return to the routine light sedentary job work (occupation) was 15.04 + 1.90 in the Lichtenstein group and 11.03 + 1.34 in the Stoppa group. On statistical calculation the P Value is <0.0001, which is considered statistically significant.

No recurrence in inguinal hernia was seen in patients of both the Lichtenstein and Stoppa groups during the 3 months follow up period.

III. Discussion

Inguinal hernia is the most common surgical abdominal entity in adults. In the past decade Lichtenstein repair has become the gold standard for treatment of inguinal hernias mainly due to the reduction in recurrences noted and due to the reproducibility of the procedure.

It is used as a gold standard surgery for all types and sizes of bilateral inguinal hernia with very few exceptions but with two separate inguinal incisions. Several other complications of mesh repair include hematoma, seroma, ischemic orchitis, testicular atrophy, mesh infection and sinus formation. Young patients especially those undergoing mesh repair for Indirect Hernias are affected mostly with a risk of infertility in future²⁸. Hence a search for ideal hernia repair is still underway and Stoppa procedure through pfannensteil incision might be the procedure satisfying the criteria for an ideal bilateral hernia repair as it is tension free. Also it requires only single incision for the repair of bilateral inguinal hernia so patient satisfaction is achieved too.

Table 03:- Comparison of Age Distribution in various studies

STUDIES	LICHTENSTEIN (years)	STOPPA'S (years)	P Value
Youssef et al ^[30]	43.89±10.27	45.97±10.69	0.37
Z Abbas et al ^[31]	39.26±1.58	39.84±10.97	0.44
Present Study	53±17	53.7±15.98	0.86

Table 04:- Comparison of Operative Times in various studies

STUDIES	LICHTENSTEIN (minutes)	STOPPA (minutes)	P Value
Youssef et al	72.3±12.2	59.4±6.3	<0.001
Z Abbas et al	65.67±6.97	65.64±7.89	0.82
Rodriguez et al	48	39	<0.01
Present study	74.68±2.86	64.43±2.59	<0.0001

Table 05:- Comparison of Early Complications in various studies

Studies	Early Complications					
	Wound Infections		Cord/ Scrotal Oedema		Hematoma	
	L	S	L	S	L	S
Youssef et al	2.7%	1.4%	5.6%	7.1%	--	--
Rodriguez et al	1.3%	0.8%	--	--	3.9%	2%
Szopinski et al	1.9%	0.9%	--	--	7.7%	6.8%
Z Abbas et al	--	--	2%	2%	--	--
Present study	3.6%	3.6%	14.2%	7.1%	3.6%	0%

Table 06:- Comparison of Duration of Hospital Stay in various studies

STUDIES	LICHTENSTEIN (DAYS)	STOPPA'S (DAYS)	P Value
Manylirah et al ^[27]	6.1	5.8	-
Present study	3.89±0.69	3.35±0.48	0.035

Table 07:- Comparison of Return to Routine Daily Activities

STUDIES	LICHTENSTEIN (days)	STOPPA'S (days)	P Value
Youssef et al	4.4±1.1	3.9±0.9	<0.05
Z Abbas et al	3.90±0.86	2.58±0.70	<0.0001
Present study	15.4±1.90	11.3±1.34	<0.0001

Table 8: Post-operative pain

Post-operative pain		Surgery		Total
		Lichtenstein	STOPPA'S	
Mild	Count	12	16	28
	%	60	80	70
Moderate	Count	7	3	10
	%	35	15	25
Severe	Count	1	1	2
	%	5	5	5
Total	Count	20	20	40
	%	100	100	100

Stoppa's Repair using pfannensteil incision has less tissue dissection requirement. Lichtenstein technique requires more dissection, tissue handling.

This may contribute to significant less Post- Operative Pain after the Stoppa technique, compared to Lichtenstein technique.

Table 09:- Comparison of Chronic Pain and Recurrence in various studies

STUDIES	Chronic Pain			Recurrence		
	L	S	P Value	L	S	P value
Youssef et al	1.4%	2.8%	0.55	---	---	---
Rodriguez et al	1%	1%	---	4%	1%	---
Present study	10%	5%	0.30	0%	0%	---

It suggests that patients operated with Stoppa's Repair by using Pfannensteil incision get ambulatory sooner and return to the routine activities before the patients operated with Lichtenstein repair.

Patients with wound infection had minimal sero- purulent soakage and one or two sutures wereremoved and wound culture was sent. Oral antibiotics were given according to the wound culture. None of the patient required wound re- exploration or removal of the mesh.

The oedema is due to the dissection around the sac of hernia and handling of tissues while separating the spermatic cord from sac. On ultrasound, epididymo- orchitis was found in 1 patient from all Strong foreign body fibrous reactions are seen at the mesh placement sites after inguinal hernia repair. This causes spermatic cord and nerve entrapment leading to chronic pain. It implies that the occurrence of chronic pain is similar in both the groups. The exact cause of post-hernioplasty pain is not known. The patients were managed with oral analgesics.

IV. Conclusions

Lesser operating time, post-operative pain, complications like fever, seroma, hematoma, scrotal swelling and wound infection have certainly been seen in Stopp's repair compared to Lichtenstein's tension free meshplasty. Also, duration of post-operative hospital stay and time taken to return to routine daily activities was significantly less in Stoppa's group compared to Lichtenstein group, making it a favourable procedure in patients with bilateral inguinal hernia. Stoppa's repair using pfannensteil incision is definitely a promising procedure but

more number of Randomized control trials and multicenter trials need to be undertaken to study the pros and cons of this procedure in future.

References

- [1]. Talha AR, Shaaban A, Ramadan R. Preperitoneal versus Lichtenstein tension- free hernioplasty for the treatment of bilateral inguinal hernia.
- [2]. Stoppas procedure: place in present era. IOSR Journal of Dental and Medical Sciences (IOSR-JDMS) e-ISSN: 2279- 0853, p-ISSN: 2279-0861. Volume 13, Issue 5 Ver. I. (May. 2014), PP 75-76
- [3]. Comparative study of laparoscopic TEP over Stoppa's and Lichtenstein technique for the management of bilateral inguinal hernia- A prospective study international. Journal of Development Research Vol. 4, Issue, 5, Pp. 1031- 1034, May, 2014
- [4]. Giant prosthetic reinforcement of the visceral sac: the Stoppa groin hernia repair in 234 patients, From the Department of Surgery, Tabriz University of Medical Sciences, Faculty of Medicine Tabriz, Iran, Accepted for publication: February 2005, Ann Saudi Med. 2005;25(3):228-232
- [5]. Preperitoneal hernioplasty via Pfannenstiel approach for recurrent inguinal hernia. Sci. Med. J. Cai. Med. Synd., Vol. 2, No. 3, July 1990
- [6]. Prospective study of open preperitoneal mesh hernioplasty: An early experience of 25 consecutive cases with good short-term outcome. The THAI Journal Of SURGERY 2008; 29:69-72.
- [7]. Amid P, Shulman AG, Lichtenstein I. The Lichtenstein open tension-free Hernioplasty. In: Arregui ME, Nagan RF. eds. Inguinal hernia. Advances or Controversies? Oxford & N.York:
- [8]. Radcliffe Medical Press, 1994; p.185-190.
- [9]. Wagner J, Brunicardi F, Amid P, Chen D. Inguinal Hernias. In: Schwartz S, Brunicardi F, Andersen D, Billiar T, Dunn D, Hunter J, ed. by. Schwartz's principles of surgery. 10th ed. New York: McGraw- Hill Education; 2015. p. 1495- 1516.
- [10]. Skandalakis J, Colborn G. Skandalakis' Surgical anatomy. Athens, Greece: PMP; 2004.
- [11]. Fischer JE. Introduction to Hernia Section. 5th ed. In: Mastery of Surgery, Skandalakis JE, Skandalakis LJ, Celtrom GL, Androulakis J, McClusky DA III, Skandalakis PN, et al. Lippincott: Williams & Wilkins; 2007. pp. 1857-59
- [12]. Abramson JH, Gofin J, Hopp C, et al. The epidemiology of inguinal hernia. A survey in western Jerusalem. J Epidemiol Community Health. 1978;32:59.
- [13]. Robert E. Condon. The anatomy of the inguinal region and its relation to groin hernia-Nyhus LM and Robert E. Condon ed. Hernia 4th edition:16-72.
- [14]. Carbonell JF, Sanchez JL, Peris RT, et al. Risk factors associated with inguinal hernias: a case control study. Eur J Surg. 1993;159:481.
- [15]. Das S. A manual on clinical surgery. 6th ed. Chapter 38. Calcutta, India: Das S; 2004. pp. 436-48.
- [16]. Nyhus LM: The preperitoneal approach and iliopubic tract repair of inguinal hernias. Chapter 8 in Hernia Nyhus, Lloyd
- [17]. M. Robert. E. Condon, Philadelphia. J.B. Lippincott Company, 1995; 153-177. R Am J Roentgenol. 2006; 187:185.
- [18]. Irving L. Lichtenstein, Alex G. Sulman, and Parviz K. Amid (1995). The tension free repair of groin hernias. In: Nyhus, Lloyd M. Robert. E. Condon (Ed) Hernia, 4th edn. Philadelphia. J.B. Lippincott Company, 237-249.
- [19]. Fischer JE. Lichtenstein Tension-Free Hernioplasty. Chap:176, 5th ed. In: Mastery of Surgery, Skandalakis JE, Skandalakis LJ, Celtrom GL, Androulakis J, McClusky DA III, Skandalakis PN, et al. Lippincott: Williams & Wilkins; 2007. pp. 1933-39 43.
- [20]. Taylor SG, O' Dwyer PJ. Chronic Groin Sepsis Following Tension-Free Inguinal Hernioplasty. Br J Surg. 1999;86:562-565.
- [21]. Cunningham J. The physiology and anatomy of chronic pain after inguinal herniorrhaphy. In: Fitzgibbons R, Greenberg G, editors. Nyhus and Condon's Hernia. 5th ed. Philadelphia USA: Lippincott Williams and Wilkins; 2002. p.297.
- [22]. Stephensen BM. Complications of Open Groin Hernia Repairs. SurgClin N Am. 2003;83:1255-1278.
- [23]. Courtney CA, Duffy K, Serpell MG and O' Dwyer PJ. Outcome of patients with severe chronic pain following repair of groin hernia. Br. J Surg. 2002;89:1310- 1314.
- [24]. Starling JR. Neuralgia (Inguinodynia) After Inguinal Herniorrhaphy. In: Fitzgibbons R, Greenberg G, editors. Nyhus and Condon's Hernia. 5th ed. Philadelphia USA: Lippincott Williams and Wilkins; 2002. p.317.
- [25]. Fong Y, Wantz GE. Prevention of Ischemic Orchitis during Inguinal Hernioplasty. SurgGynaceol Obstet. 1992;174:399-402.
- [26]. Richards AT. Cord and Testicular Complication of Groin Herniorrhaphy. In: Fitzgibbons R, Greenberg G, editors. Nyhus and Condon's Hernia. 5th ed. Philadelphia USA: Lippincott Williams and Wilkins; 2002. p.291.
- [27]. Fitzgibbons, Robert J. (2005). "Can We Be Sure Polypropylene Mesh Causes Infertility?". Annals of Surgery 241 (4): 559-6.
- [28]. Nordin P, Bartelmess P, Jansson C, Svensson C and Edlund G. Randomized Trial of Lichtenstein Versus Shouldice Hernia Repair in General Surgical Practice. Br J Surg 2002;89:45-49.
- [29]. Bay-Nielsen M, Nordin P, Nilsson E, Kehlet H. Operative Findings in Recurrent Hernia after a Lichtenstein Procedure. Am J Surg. 2001;182:134-136.
- [30]. Manyilira W, Kijjambu S, Upoki A, Kiryabwire J. Comparison of non-mesh (Stoppa) and mesh (Lichtenstein) methods for inguinal hernia repair among black African patients: a short-term double-blind RCT. Hernia. 2012; 16 (2): 133-144.
- [31]. Szopinski J, Dabrowiecki S, Pierscinski S, Jackowski M, Jaworski M, Szuffel Z. Stoppas versus Lichtenstein technique for primary inguinal hernia treatment: 3- year results of a randomized clinical trial. World J of surgery. 2012; 36 (5): 984-- 992.
- [32]. Youssef T, El-Alfy K, Farid M. Randomized clinical trial of Stoppas versus Lichtenstein repair for treatment of primary inguinal hernia. Int J Surg. 2015 Aug;20:28-34. doi: 10.1016/j.ijsu.2015-.05.055. Epub 2015 Jun 11.
- [33]. Zaheer Abbas, Sujeet Kumar Bhat, Monika Koul, Rakesh Bhat. Stoppa's repair versus lichtenstein's open mesh repair of inguinal hernia: a comparative study. DOI:10.14260/jemds/2015/1910. J of Evolution of Med and Dent Sci/ eISSN- 2278-4802, pISSN-2278-4748/ Vol. 4/ Issue 77/Sept 24, 2015.
- [34]. P.R.I. Rodríguez, P.P. Herrera, O.L. Gonzalez, J. R.C. Alonso, H.S.R. Blanco. ISSN 2073-9990 East Cent. Afr. J. surg July/August; 2013 Volume 18 (2).

Kush Dhama, et. al. "Comparative Study of Stoppa's Repair by Pfannensteil Incision Versus Lichtenstein Technique for Management of Bilateral Inguinal Hernia." *IOSR Journal of Dental and Medical Sciences (IOSR-JDMS)*, 21(02), 2022, pp. 59-66.