

## Interception of a developing skeletal Class III malocclusion by facemask therapy and Wunderer's Activator with the use of CBCT

1- Mahadia Saad Allafe

2- Marwa S. Shamaa

3- Maher Abd El-salam Fouda

Master degree of orthodontics department, faculty of dentistry, Mansoura University, Mansoura, Dakahlia, Egypt. University of sirte orthodontist

### Abstract

Most of developing Class III malocclusion are accompanied by skeletal discrepancies. Skeletal class III could be maxillary jaw retrusion. Mandibular jaw protrusion. Combination of both. Interception of mild to moderate cases should be carried out as early as possible before it becomes severe. Orthopedic appliances are those appliances through which growth could be modified include maxillary protraction appliances. Mandibular retractors and functional appliances. Orthopedic facemask is extra oral appliance of choice in cases with maxillary retrusion and produces dramatic results in the shortest period of time, also Functional appliance treated of class III by hold the mandible in a retruded position to enhance the advancement growth of maxilla and inhibit the growth of the mandible. The purpose of this study was to use the CBCT to reveal the dentoskeletal changes, and upper air way morphology before and after growth modification.

We present a patient ( boys) with a developing skeletal class III malocclusion with maxillary retrusion in mixed dentition using a facemask and wunderer's activator, there was successful interception of the skeletal malocclusion.

**Methods and Material:** The sample included eleven boys cases with average age of 8 and six months, who were treated by Wunderer's Activator and a face mask for 12 months. All cases had skeletal class III malocclusion due to maxillary retrusion. The CBCT were taken and analyzed before and after by doing superimposition to evaluate the efficacy of Wunderer's Activator and a face mask.

**Result:** statistical analysis using the SPSS version 20.0 revealed that there was highly significant increase in SNA angle by 1.98mm ( $P = 0.001$ ). Significant decrease in SNB was -0.83 mm ( $P < 0.001$ ). Also, the wits appraisal was found to be highly significantly increased by 2.8 ( $p < 0.001^*$ ). The vertical measurements showed significant decrease with (SN/ OCP, SN/COGN) by -0.68, -0.78 ( $p < 0.003^*$  and  $0.025^*$  respectively). The dentoalveolar measurements were significantly difference with overjet was improved and statically significant with ( U1/NA, L1/NB, UI - SN, UI/pp, L1/MP) recorded ( $p < 0.007, 0.28, 0.02, 0.046$  and  $0.007$  respectively).

**Conclusion:** The study concluded that the treatment of Class III malocclusion of boys due to maxillary retrusion by Wunderer's Activator and face mask was effective.

**Key words:** Skeletal class III, mixed dentition, maxillary retrusion, Wunderer's Activator, face mask, Upper air way and CBCT

Date of Submission: 06-02-2022

Date of Acceptance: 20-02-2022

### I. Introduction

Correction of skeletal class III malocclusion in growing patients is a challenging part of contemporary orthodontic practice. The etiology of Class III malocclusion is believed to be mainly hereditary, but environmental factors such as mouth breathing and habits may also play a role.<sup>[1,2]</sup> prevalence of skeletal class III malocclusion varies greatly within different geographic regions and races<sup>[3]</sup>. McNamara and Ellis found that 65-67% of skeletal class III malocclusion were characterized by maxillary deficiency<sup>[4]</sup>. Thus, maxillary protraction is an important paradigm in early correction of skeletal Class III malocclusion.

In skeletal class III malocclusion, Many management approaches can be found in the literature regarding orthodontic treatment and orthopedic in skeletal Class III malocclusion, including intra-oral and extra-oral appliances such as facial mask<sup>[5]</sup>, Frankel III (fr-3) appliance<sup>[6]</sup>, reverse bionator<sup>[7]</sup>, double-piece corrector<sup>[8]</sup>, chin cup<sup>[9]</sup> and a ctivator III<sup>[10]</sup>.

The upper air ways has been assessed with various imaging techniques including fluoroscopy, nasopharyngoscopy, cephalometry, computerized tomography (CT), cone beam computed tomography (CBCT), and magnetic resonance imaging(MRI) <sup>[11,12]</sup>. A three-dimensional(CBCT) system provides more reliable landmark identification of the anatomical structures than two dimensional cephalometry <sup>[13,14]</sup> and allows precise measurement of air way space <sup>[15]</sup>.

The upper air way is divided into three parts <sup>[16,17]</sup>.The first part is nasopharynx (NA) ( from the top of upper air way to hard palatal plane ),the second part is Oropharynx (OR) ( from the hard palate plane to the superior border of the epiglottis), the latter is divided into 2 parts:1.The velopharynx (VE) ( from the hard palate plane to the point of uvula) and 2.the glossopharynx (GL)( from the point of the uvula to the superior border of the epiglottic) and the third part is the hypopharynx (HY) (from the superior border of epiglottic to the bottom of the epiglottic) <sup>[18]</sup>.

The study was concentrated on the assessment of dentoskeletal changes and The upper air ways morphology as result of wunderer's activator and face mask in the correction of skeletal class III in growing patients.

## II. Materials and Method

- A sample of eleven cases in growing period with average age of 8 and six months selected from the clinic of Orthodontic Department, Faculty of Dentistry, Mansoura University, Egypt. The patients involved in This study had the following inclusion criteria:

- Age ranges from 7-12 years.
- Skeletal Class III due to maxillary retruded.
- Reverse Overjet and reverse over bite
- No Systemic problems.
- No Previous orthodontic treatment.

- **Materials**

- Case sheet: A paper sheet included the following information: patient's name, age, gender, case number, dental history was done
- Cone beam computed tomography will measure the following:The upper air way analysis (fig.1), panoramic view and lateral Cephalometric views (fig.2a,b) .
- Disposable diagnostic instruments (dental Probe, mirror, tweezer).
- Suitable orthodontic trays.
- Silicon rubber base, impression material. \*
- Dental stone, Exacto bite.
- The angles and lines of the lateral Cephalometric (fig .3)

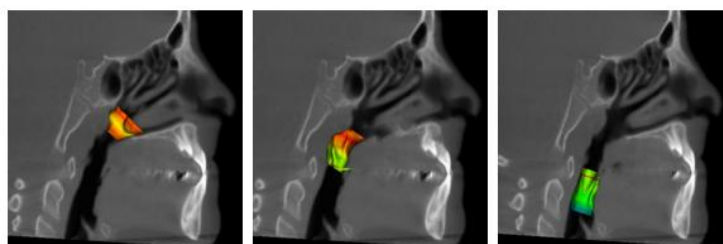


Figure 1:The upper air way analysis

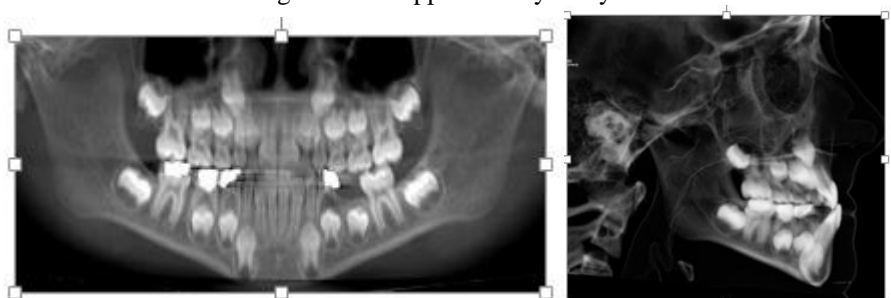

Figure 2(a,b) panorama and cephalometric viwes

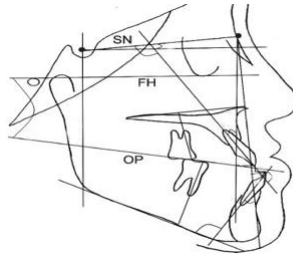


Figure 3: The lines and angles of the cephalometric

**Method:**

Upper and lower good silicon rubber base impressions will be taken and bite construction will be taken by exactobite in the most retruded of position the mandible with the incisal edges 2mm . The bite was transferred to the working upper and lower models and articulated in the hinge articulator construction bite will be used for appliance fabrication.

Wunderer’s activator is removable appliance composed Adams and short labial bow made of 0.8 mm stainless steel wire were constructed on the permanent first molars and anterior incisor teeth on the both casts . All the components were waxed and a separating medium was applied to the upper and lower casts. Splited horizontally with the upper and lower portions connected by Weise screw( fig.4) .Part of the weise screw will be embedded in the mandibular portion of the activator, The other part of the screw is attached to the maxillary portion of the activator( fig.5). Acrylic base plate were made in upper and lower casts to hold the components of the appliance with posterior bite plane in between(fig.6) . Two retention hooks,

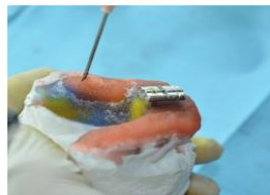
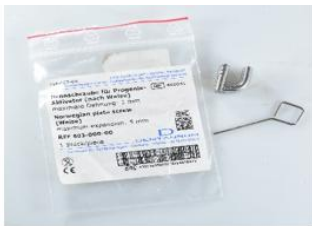

Figure4:weise screw Figure 5: The other part of the screw is attached to the maxillary portion of the activator



Figure6:the upper and lower casts to hold the components of the appliance in each part in the higher area of the activator will be put at the premolar areas roughly 15 mm gingival to occlusal planes for attachment of elastics( fig.7) . Trimming and polishing of the appliance to finished it( fig.8).

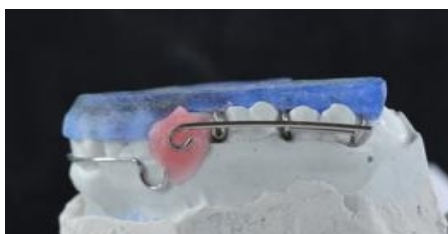

figure7: Two retention hooks for attachment of elastics Figure 8: Trimming and polishing

**Face mask:**

Facemask will be attached on the hooks of wunderer’s activator.The force of five hundred grams on each side will be utilized during treatment .But this study we strated gradually forces until come to 500g.

**Statistical analysis:**

Data were tabulated, coded then studied by SPSS software package version 20.0. Measurements data were described using mean, standard deviation and change before and after treatment. Significance of the obtained results was less than or equal of 5%.

**Table 1:** Means, standard deviation and change of pre-and post-treatment and results of paired t-test for skeletal changes of wunderer’s activator and a facemask appliance in participiates with class III due to maxillary retrusion

Measurements	Pretreatment Mean ± SD	Post treatment Mean ±SD	Mean Change	Paired t-test	P value
SNA	80.19±1.7	82.17±2.6	1.98	5.29	0.001**
SNB	80.92±1.8	80.09±1.9	-0.83	6.2	<0.001**
ANB	-0.78±1.13	2.08±1.5	2.86	6.8	<0.001**
WITTS	-5.27±1.7	-2.46±1.6	2.8	6.6	<0.001**

**Table 2:** Means and SD of pre-and post-treatment and results of paired t-test for vertical changes of the wunderer’s activator with face mask in children with Class III due to maxillary retrusion

Measurements	Pretreatment Mean ± SD	Post treatment Mean ± SD	Mean Change	Paired t-test	P value
SN OCP	17.32±2.8	16.64±2.6	-0.68	2.76	0.025*
SN GOGN	33.7±2.7	32.92±2.2	-0.78	4.28	0.003**

**Table 3:** Means and SD of pre-and post-treatment and results of paired t-test for dentoalveolar changes of the wunderer’s activator with face mask in children with Class III due to maxillary retrusion

Measurements	Pretreatment Mean ± SD	Post treatment Mean ± SD	Mean Change	Paired t-test	P value
+1/NA	21.4±4.8	23.86±3.7	2.5	3.6	0.007**
+1/SN	102.47±5.8	105.68±4.0	2.9	2.9	0.02*
-1/NB	22.82±4.5	19.14±1.3	-3.7	2.7	0.028*
+1i/NA	2.30±1.5	3.27±1.5	0.97	5.5	0.001**
-1i/NB	4.16±1.4	2.91±1.4	-1.24	4.52	0.002**
L1/MP	87.95±3.07	84.51±4.4	-3.4	3.6	0.007**
U6/SN	70.32±7.02	72.79±4.02	2.47	1.01	0.3
U6/PP	78.19±7.6	79.48±4.7	1.3	0.65	0.5
L6/MP	82.22±5.2	78.31±11.7	-3.91	0.95	0.37

**Table 4:** Means and SD of pre-and post-treatment and results of paired t-test for airway changes of the wunderer’s activator with face mask in children with Class III due to maxillary retrusion

Measurements	Pretreatment Mean ± SD	Post treatment Mean ± SD	Mean Change	Paired t-test	P value
1 <sup>st</sup> area	2.24±0.57	2.07±0.65	-0.18	0.91	0.39
2 <sup>nd</sup> area	3.9±1.9	3.96±2.2	0.06	0.11	0.92
3 <sup>rd</sup> area	3.54±2.3	3.76±2.3	0.21	0.49	0.64

P: p values for **Paired t-test** for comparing between Pre-Treatment and Post Treatment \*: Statistically significant at  $p \leq 0.05$

**III. Results**

eleven participiates , (eleven boys) used the wunderer’s activator and a face mask as their treatment procedure , with average age (7.50 ±2.35) years . The data in Table 1 showed that SNA angle there was highly significant increase in SNA angle by 1.97 mm (P = 0.001). Anterior of A point movement was evidenced by highly significant statistically and significant increased of ANB was significant increase by 2.85 (P <0.001) . Also, the wits appraisal was found to be highly significantly increased by (p< 0.001\*). On other hand , significant decrease in SNB was -0.83 mm (P< 0.001). Regarding the vertical results in Table 2, the present study showed significant decreased (SN-COP, SN-COGN respectively ) by -0.68, -0.78. Regarding the dentoalveolar changes angular and linear in table 3, the results showed significant statistically , the maxillary incisors position were a highly significant increased and mandibular incisors were significant decreased in this results showed (

U1/NA ,L1/NB, U1 – SN , U1/pp, L1/MP) recorded (  $p < 0.007, 0.28, 0.02, 0.046$  and  $0.007$  respectively). The (U6/SN, U6/PP and L6/MP) lines were not significantly affected , also air way measurements showed non a significant change in

#### **Case presentation:**

The patient was male who was 6 years and 2 months old at the time of initial records . His parents worried about his lower jaw being in front .During the clinical interview, the presence of this malocclusions in other family members was reported . The pre-treatment records showed that the patient had normal vertical proportions, a Concave profile [Figure9a, b and c ]. Evaluation of the case confirmed a Class III skeletal relationship with maxillary deficiency and slight mandibular jaw protrusion . Intra orally there was reverse over jet [Figure10].

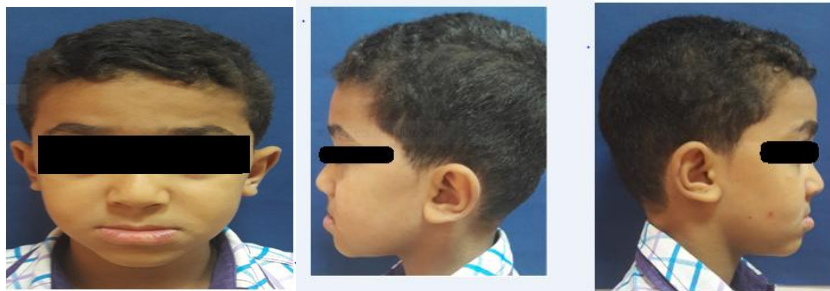

Figure 9a,b and c: frontal ,left and right sides

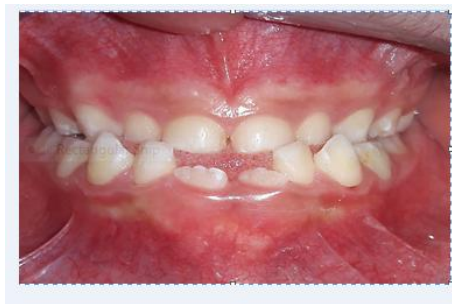

Figure 10: revers over jet

#### **Treatment Objectives**

Early skeletal Class III management creates an environment in which more benefit dentofacial growth can occur<sup>[19]</sup>.Some studies suggested that a greater degree of advancement maxillary growth can be found when correction was initiated in deciduous or early mixed dentition <sup>[20,21]</sup> .The optimal time to intervene a Class III malocclusion is at the time of the initial eruption of the maxillary incisors The goals of early skeletal Class III treatment may include the following :

1. To adjust skeletal discrepancies and provide a more favorable environment for future growth. Excessive mandibular growth is often accompanied by dental compensation of the mandibular incisors. Early orthopedic correction using chin cup or facemask therapy improves the skeletal relationships, which in turn minimize excessive dental compensation such as over closure of the mandible and retroclination of the mandibular incisors <sup>[22]</sup>
2. To prevent progressive irreversible soft tissue or bony changes. Class III malocclusion is often accompanied with a reverse over jet. Uncorrected reverse over jet may lead to abnormal wear of the lower incisors, dental compensation of mandibular incisors, leading to thinning of the labial alveolar plate and/or gingival recession <sup>[23]</sup>
3. To improve occlusal function. Class III malocclusion with an anterior cross bite is often accompanied by a functional shift. Early orthopedic treatment may help in eliminating centric relation/ centric occlusion (CO/CR) discrepancies and avoid adverse growth potential<sup>[22]</sup>
4. To simplify phase II comprehensive treatment. In moderate and mild Class III patients, early orthopedic or orthodontic treatment may eliminate the necessity for orthognathic surgery treatment. Even if surgery is eventually needed, early management of the transverse dimension and maximizing the growth potential of the maxilla may minimize the extent of the surgical procedures <sup>[22]</sup>

5. To provide more pleasing facial esthetics, thus improving the psychosocial development of a kid. Several studies have shown that treatment with chin cap and/or facemask improves lip posture and facial profile [24,25]

### **Treatment Progress**

Treatment was started with a delaire type facemask, which was used along a wunderer's activator as intra-oral appliance with hooks, to engage elastics. Intraoral, a wunderer's activator was fitted inside patient mouth [figure 11]. The patient was instructed to wear the appliance continuously for as long as possible. The appliance from the oral side was activated ¼ turn twice a week by a screw driver. A wunderer's activator composed the upper and lower portions connected by Weise screw (figure 12). Part of the weise screw will be embedded in the mandibular portion of the activator. The other part of the screw is attached to the maxillary portion, through the continuous activation of the sagittal screw spindle: a repositioning of lower jaw and advancement of the upper jaw will be possible [26].

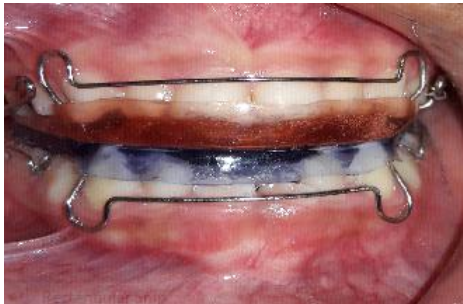

Figure 11: fitted inside patient mouth



Figure 12: wunderer's activator

### **Treatment Results**

At the end 6 months of treatment, improvement in the facial appearance on wearing the appliance was noted and appreciated by the parent immediately [Figure 13a, b and c] revealed marked improvement in her profile with a slight fullness in the maxillary anterior region. The anterior cross bite was corrected [Figure 14] and analysis of the cephalometric radiograph (before and after) [Figure 15a,b]

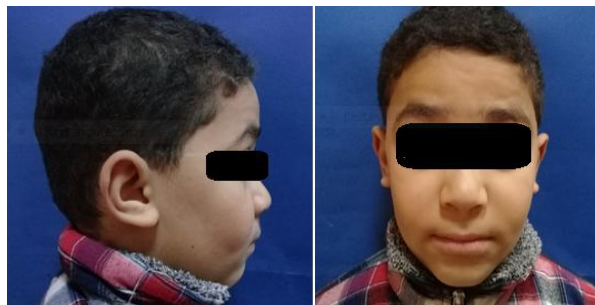
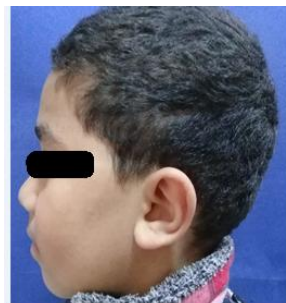
Figure 13 a,b and c: frontal, left and right sides



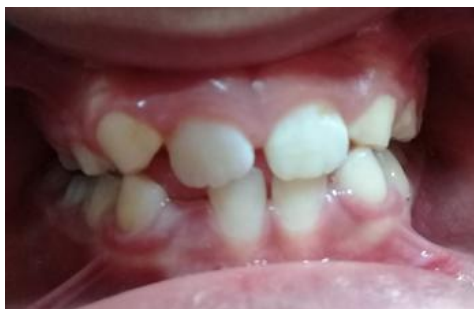

Figure 14: correct over jet

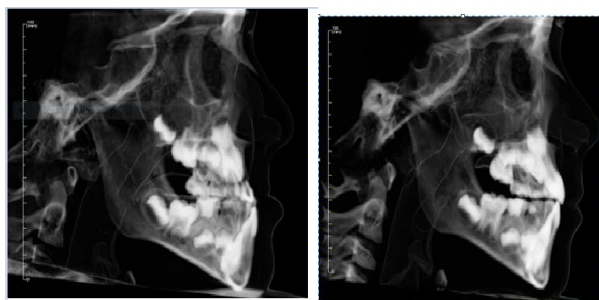


Figure 15 a,b: lateral cephalomertic (before and after)views

#### IV. Discussion

The facemask has an adjustable anterior wire that can accommodate and a downward and forward pull on the maxilla with elastics. To minimize the tipping of the palatal plane, the protraction elastics are connected to hooks in wunderer's activator near the maxillary canines with a downward and forward pull of 30° to the occlusal plane<sup>[23]</sup>. Facemask usually requires 400-600 g of force per side, depending on the age of the patient. The wunderer's activator provides as an intra-oral appliance for connection of force modules as well as create an anterior force on the maxillary jaw. In additionally design of the intra oral appliance wunderer's activator by made while mandible is positioned posteriorly. Patients are instructed to wear the face mask and wunderer's activator continuously for as long as possible. Correction using facemask along with wunderer's activator occurs by a combination of skeletal and dental effects in both vertical and sagittal dimensions. These effects occur as a result of anterior forward maxillary displacement, backward and downward rotation of the mandible, proclination of the upper incisors and a decrease of the lower incisors proclination. Anterior cross bite can be corrected from 5 to 6 months. Improvement in molar relationship and overbite can be expected with an additional 3-6 months of correction.

#### V. Conclusion

wunderer's activator and a face mask was successful in improving of skeletal, dentoalveolar discrepancy, and could be used in treatment of skeletal class III due to maxillary retrusion. Additionally, the wunderer's activator and a face mask treatment influences on growth potential of the mandible was evidenced by restriction growth of the mandible and forward advancement of the maxilla.

#### Reference

- [1]. Litton SF, Ackermann LV, Isaacson RJ, Shapiro BL. A genetic study of Class 3 malocclusion. Am J Orthod 1970; 58:565-77.
- [2]. Rakosi T, Schilli W. Class III anomalies: A coordinated approach to skeletal, dental, and soft tissue problems. J Oral Surg 1981; 39:860-70.
- [3]. Ainsworth NJ. The incidence of dental disease in the children in medical research council. Reports of the committee for the investigation of dental disease. 1925. Special report series. No 97.
- [4]. Franchi L, Baccetti T, McNamara JA. Post pubertal assessment of treatment timing for maxillary expansion and protraction therapy followed by fixed appliances. Am J Orthodontics and Dentofacial Orthop. 2004; 126:555-568
- [5]. Delaire, J. (1976) Le syndrome prognathique mandibulaire. Orthodontic Free Journal 1976; 47, 203-219
- [6]. Fränkel, R. (1970) Maxillary Retrusion in Class III Malocclusion with the Function Corrector III. Trans Eur Orthod Soc. 1970; 46, 249-259
- [7]. Grattini, G., Levrini, L., Grozzoli, P. and Levrini, A. Skeletal and Dental Modifications Produced by the Bionator III Appliance Malocclusion Appliance. The Am J of Orthop. 1998; 114, 4.
- [8]. Üçem, T.T., Uçuncu, N. and Yüksel, S. Comparison of Double-Plate Appliance and Facemask Therapy in Treating Class III Malocclusions. Am J of Orthod and Dentofacial Orthop. 2004; 126, 672-679.
- [9]. Graber, L.W. Chin Cup Therapy for Mandibular Prognathism. Am J of Orthod. 1977; 72, 23-41.
- [10]. Satravaha S, Taweeseed N. Stability of skeletal changes after activator treatment of patients with class III malocclusions. Am J Orthod Dentofacial Orthop 1999; 116:196-206.

- [11]. Avrahami E, Solomonovich A, Englander M. (1996) Axial CT measurements of the cross-sectional area of the oropharynx in adults with obstructive sleep apnea syndrome. *AJNR Am J Neuroradiology* . [Internet];17: 1107-1111.
- [12]. Fredberg JJ, Wohl ME, Glass GM, Dorkin HL. (1980) Airway area by acoustic reflections measured at the mouth. *J Appl Physio*. [Internet] ;48:749-758.
- [13]. Sorensen H, Solow B, Greve E. (1980) Assessment of the nasopharyngeal airway. A rhinomanometric and radiographic study in children With adenoids. *acta Otolaryngol*. [Internet] ; 89: 227-232
- [14]. Brown AA, Scarfe WC, Scheetz JP, Silveira AM. (2009) Farman Linear accuracy of cone beam CT derived 3D images. *Angle Orthod. AG*. [Internet] ; 79: 150-157.
- [15]. Kerr WJ. (1985)The nasopharynx, face height, and overbite. *Angle Orthod*. [Internet]; 55: 31-36.
- [16]. Chen Y, Hong L, Wang CL, Zhang SJ, Cao C, Wei F, et al.(2012) Effect of large incisor retraction on upper airway morphology in adult bimaxillary protrusion patients. *Angle Orthod.*; 82(6): 964–970.
- [17]. Wang T, Yang Z, Yang F, Zhang M, Zhao J, Chen J, et al.(2014) A three dimensional study of upper airway in adult skeletal Class II patients with different vertical growth patterns. *PLoS* 9(4):e95544
- [18]. Cheung T, Oberoi S.(2012) Three dimensional assessment of the pharyngeal airway in individuals with nonsyndromic cleft lip and palate. *PLoS One*; 7(8):e43405.
- [19]. Joondeph DR. Early orthodontic treatment. *Am J Orthodontics Dentofacial Orthop* 1993;104:199-200.
- [20]. Baccetti T, McGill JS, Franchi L, et al: Skeletal effects of early treatment of class III malocclusion with maxillary expansion and facemask therapy. *Am J Orthodontics Dentofacial Orthop*. 1998; 113:333-343
- [21]. Kapust A, Sinclair P, Turley P: Cephalometric effects of facemask/expansion therapy in class III children children: a comparison of three age groups *Am J Orthod*. 1998; 113:204-212
- [22]. Peter Ngan. Early Timely Treatment of Class III Malocclusion. Elsevier Inc. All rights reserved. 2005.04.007. doi:10.1053/j.sodo
- [23]. Ngan P: Treatment of Class III malocclusion in the primary and mixed dentitions, in Bishara SE (ed): *Textbook of Orthodontics*. Philadelphia, PA, WB Saunders. 2001, pp 375-411
- [24]. Ngan P, Hagg U, Merwin D, et al: Soft tissue and dentoskeletal profile changes associated with maxillary expansion and protraction headgear treatment. *Am J Orthod Dentofacial Orthop*. 1996 109:38-49,
- [25]. Kilicoglu H, Kirlic Y: Profile changes in patients with Class III malocclusions after Delaire mask therapy. *Am J Orthod Dentofacial Orthop*. 1998; 113:453-462
- [26]. Ursula Wirtz, Diedrich, W. Bauer, T.Hetz, G.kinzinger, H.Wehrbein, Sous I. Atlas of orthodontic and orothopedic technique