

## **Comparison of USG and FNAC in detecting breast lesions**

Dr. Anurakshat Gupta Dr. Deep Yadav, Dr. Natasha Dogra, Dr. Anand s

---

Date of Submission: 01-12-2022

Date of Acceptance: 12-12-2022

---

### **I. Introduction**

Diseases of breast, with their uncertain causes and confusion of treatments, have intrigued physicians and medical historians throughout the ages. Benign as well as malignant breast lesions are quite common in Indian population. It is the most common cancer site followed by cancer cervix in Indian females. Currently, 75,000 new cases of breast cancer are detected in India yearly.<sup>1</sup>

Breast health means more than breast cancer. It has been noted that non-cancerous pathology of the breast has always been neglected, despite the fact that vast majority of breast lesions are benign and far more frequent than the malignant ones (10:1).<sup>2</sup> Most benign breast disorders are relatively minor aberrations of the normal processes of development, cyclical hormonal response and involution. It has been reported that 90% of the patients attending breast clinics belong to the group of benign breast disorders. Magnitude of the problem is such that almost 50% of women, at some point in their life, have signs and/or symptoms of benign breast disorder.<sup>3</sup>

The vast majority of the lesions that occur in the breast are benign. Much concern is given to malignant lesions of the breast because breast cancer is the most common malignancy in women in Western countries; however, benign lesions of the breast are far more frequent than malignant ones.<sup>4-7</sup> With the use of mammography, ultrasound, and magnetic resonance imaging of the breast and the extensive use of needle biopsies, the diagnosis of a benign breast disease can be accomplished without surgery in the majority of patients. Because the majority of benign lesions are not associated with an increased risk for subsequent breast cancer, unnecessary surgical procedures should be avoided. It is important for pathologists, radiologists, and oncologists to recognize benign lesions, both to distinguish them from in situ and invasive breast cancer and to assess a patient's risk of developing breast cancer, so that the most appropriate treatment modality for each case can be established.

During the past few decades, across the world, breast cancer has emerged as one of the major cancers resulting in mortality among women. In the year 2010, one million new cases were diagnosed and more than five hundred thousand lives were claimed by breast cancer globally. For a long time, USA had the worst breast cancer mortality statistic in the world but for the first time, in 2008, India surpassed USA with more than fifty thousand deaths due to breast cancer. As per WHO, till last year in 2020, 70% of all breast-cancer cases worldwide were present in developing countries.<sup>8</sup>

Most concerning is the spread of breast cancer in Asian world including India and China, where breast cancer is rapidly emerging in younger, premenopausal women, as featured in an article in TIMES 2007 with inputs from WHO cancer prevention and control programmes.<sup>9</sup>

Benign breast disease is common in young woman and less common in postmenopausal women. The discovery of a breast lump, whether by the woman herself or by a clinician, is a common occurrence and distressing for any woman. Evaluation of breast lumps in young females is essential to identify patients with benign proliferative lesions of the breast.

Most cases of breast lumps are benign but most of these patients are in a state of heightened anxiety until they have undergone specialist assessment, the necessary investigations and eventual reassurance. To minimize delay and, therefore, reduce anxiety in the majority of cases presenting to hospital and to avoid unnecessary outpatient follow-up and open biopsy, many breast clinics have evolved a policy of triple assessment with immediate reporting to provide a one-stop diagnostic service.

Mammography and ultrasonography (US) are the diagnostic methods which have shown the highest sensitivity in the detection of breast cancer. However, both methods present some limitations. Mammography performed in dense breasts may often yield false-negative results.<sup>10</sup> US is sensitive in the detection of lesions, but specificity is poor as most solid lesions are benign. In order to obtain an acceptable specificity, various characteristics of the lesions must be evaluated according to the BI-RADS criteria defined by the American College of Radiology (ACR).<sup>11</sup> Unfortunately, the BI-RADS criteria generate a significant number of false positive results.<sup>12</sup> This limitation leads to an increase in biopsies with a cancer "detection rate" of only 10%–30%.<sup>13-14</sup> Many biopsies are performed in benign lesions causing discomfort to the patients and increased costs.

With growing awareness in the general population, especially about breast pathologies, a lady with a breast lump is one of the commonest presentations in outpatient departments. Clinical examination would be followed in most patients with a confirmatory diagnosis under the microscope. Previously, this involved invasive methods, such as an excision biopsy as an inpatient, under anaesthesia, followed by the definitive operative treatment a few days later in case the biopsy report demanded it. The final specimen so obtained would then be sent for histopathology again, for determination of other parameters. This entailed repeated admission to hospital in most cases, and more than one surgery along with its attendant social and physical inconvenience. The delay in procuring the histopathology report was also added to the woes of the patient.

Ultrasonography (US) has been playing an increasingly important role in the evaluation of breast cancer. US is useful in the evaluation of palpable masses that are mammographically occult, or clinically suspected breast lesions in women and of many abnormalities seen on mammograms.

High frequency, high-resolution USG helps in its evaluation. This is exemplified in women with dense breast tissue where USG is useful in detecting small breast cancers. US is also useful in the guidance of biopsies and therapeutic procedures. It is now well established that US also provides valuable information about the nature and extent of solid masses and other breast lesions.

Ultrasonography does not expose a patient to ionizing radiation—a factor that is particularly important for pregnant patients and young patients. It is believed that in these patients, the breast is more sensitive to radiation.

The use of fine-needle aspiration cytology (FNAC) is increasing for preoperative diagnosis of breast carcinoma. Fine needle aspiration cytology (FNAC) has become popular as a valuable tool in preoperative assessment of breast masses, and it shows high accuracy, sensitivity, and specificity. It has gained popularity due to its fast and easy approach, being inexpensive, and can be performed with little complications. To differentiate benign from malignant lesions is one of the major goals of FNAC. In the evaluation of breast masses, the time honored triple assessment combines clinical, radiological, and pathological information, and FNAC, together with core needle biopsy, is the initial pathological investigative methods of choice. Much confidence has been placed on this approach for it can obviate standard excisional biopsy when all three components of the triple test are conclusively negative or positive.<sup>15</sup>

Breast imaging-reporting and data system (BI-RADS) is a classification system proposed by the American College of Radiology (ACR) in 1986 with the original report released in 1993. The 1980s saw an exponential increase in mammography with the implementation of yearly screening mammograms and overwhelming variation amongst radiology reports. BI-RADS was implemented to standardize risk assessment and quality control for mammography and provide uniformity in the reports for non-radiologist.

The collective collaboration by the ACR, AMA, National Cancer Institute, Centers for Disease Control and Prevention (CDC), FDA, American College of Surgeons, and College of American Pathologist to create the BI-RADS guidelines allowed for broad support and an effective transition to BI-RADS nationally. The fluidity of BI-RADS allows for it to evolve with changes in technology and research.

The ACR used scientific analysis to create a lexicon of descriptors that had shown to correlate with high predictive values associated with either benign or malignant disease. The second important aspect of the BI-RADS system was the category classification for the overall assessment of the imaging findings. The categorization provides an approximate risk of malignancy to a lesion from essentially zero to greater than 95%. The categorization and final assessment decreased ambiguity in recommendations. BI-RADS was built to be fluid and change with the adaptation of new techniques and research.

Lump in breast is therefore a cause of great anxiety both to the patient and family members. The main motive behind the evaluation of such a newly detected palpable lump is basically to rule out malignancy. Evaluation of breast lumps involves the rational use of a detailed history, clinical breast examination, imaging modalities and tissue diagnosis. Though the final diagnosis is made by HPE of excised tissue, routine excision of all breast lumps would not be rationale, because as much as 80% of lumps are benign. Thus the need is painful and invasive surgical biopsy. The modality should also be acceptable to the patient accurate easy to apply, reproducible and must not need too much preparations.

Given the common occurrence of breast cancer and the importance accurately diagnosing a clinically palpable breast lump, with non invasive techniques without routinely resorting to formal biopsy which is much invasive, In a very recent study Richie AJ et al<sup>16</sup> reported FNAC was found to have sensitivity of 98.4% and specificity of 95.7% and USG is better in detection of benign lesions whereas cytology is better in case of malignancies. The triple assessment is an accurate, simple and cost-effective method for the evaluation of breast cancer and as a safe alternative for open biopsy.

Hence the present study was done at our tertiary care centre to evaluate the accuracy of USG and FNAC in the diagnosis of newly detected clinically palpable breast lumps in comparison to the final HPE report of biopsied specimens.

## II. Aims And Objectives

To compare Ultrasonography and Fine Needle Aspiration Cytology in the Diagnosis of Breast Lesions.

## III. MATERIAL AND METHODS

The present prospective study was done at our tertiary care centre on 40 cases to evaluate the accuracy of USG and FNAC in the diagnosis of newly detected clinically palpable breast lumps in comparison to the final HPE report of biopsied specimens.

**Study design:** A hospital based prospective study

**Study Duration:** 18 months

**Study area:** The study was done at our tertiary care centre in the department of general surgery, Pathology, Radiology, cytology and histopathological section, Command Hospital Air Force, Bengaluru attending OPD/IPD.

**Study population:** All patients being evaluated for Breast lesions attending the OPD/IPD of Tertiary care Hospital who fulfilled the inclusion criteria.

**Sample size:** 40 patients

Sample size was calculated using the formula:

$$n = [z^2 p(1-p)] / d^2$$

Where: Z = table value of alpha error from Standard Normal Distribution table (0.95)

Power (p) = 80%

Precision error of estimation (d) = 0.06

$$n = [0.95 \times 0.95 \times 0.8 (0.2)] / 0.06 \times 0.06 = 40.11$$

Hence a sample size of 40 patients was considered adequate for our study.

### Inclusion criteria

- Clinically palpable breast lesion
- BIRADS 4,5
- BIRADS 1,2,3 with C3,C4,C5 classification on FNAC

### Exclusion criteria:

- Clinically not palpable breast lesion
- BIRADS 2 with C2 classification on FNAC
- Breast abscess

## IV. METHODOLOGY

The study was done at our tertiary care centre in the department of Pathology, Radiology, cytology and histopathological section, Command Hospital Air Force, Bengaluru attending OPD/IPD after due permission from the Institutional Ethics Committee and Review Board and after taking Written Informed Consent from the patients.

After approval from the Institutional Ethics Committee a valid informed consent was taken. Once the patients were enrolled for the study, a thorough history and physical examination was done as per proforma. An informed consent was taken in written from patients or patient's attendant.

The study was done in both outdoor and indoor patients of the department of General Surgery, Command Hospital, Bangalore, India, presenting with clinically palpable breast lump. The term palpable breast lump meant area of denser breast tissue and/or from similar area of the contralateral breast, which could be subjectively and reproducibly felt. All patients undergoing ultrasonographic evaluation at the department of Radiodiagnosis, Command Hospital, Bangalore, the reports were grouped based on BIRADS classification. Following USG the cases were sent to Aspiration cytology room (Pathology) at OPD for fine needle aspiration cytology examination of breast lump.

Before the FNAC procedure, an information sheet, describing the procedure, its benefits and possible complications, was routinely distributed to the patients. Majority of the FNAC tests were done by the pathologist. During the procedure, a 23G disposable hypodermic needle and 10 ml plastic syringe were routinely used. With the needle in situ at the designated location of the breast lump and the syringe attached to it, "needling" continued until adequate yield was observed at the needle hub. The material in the needle lumen was expelled onto the center of a pretabled glass slide.

The smears were prepared by gently spreading the aspirate using another slide inclined at 45°. Subsequently, wet-fixed slides were obtained by placing the slides into a coplin jar containing 95% ethanol. These slides were

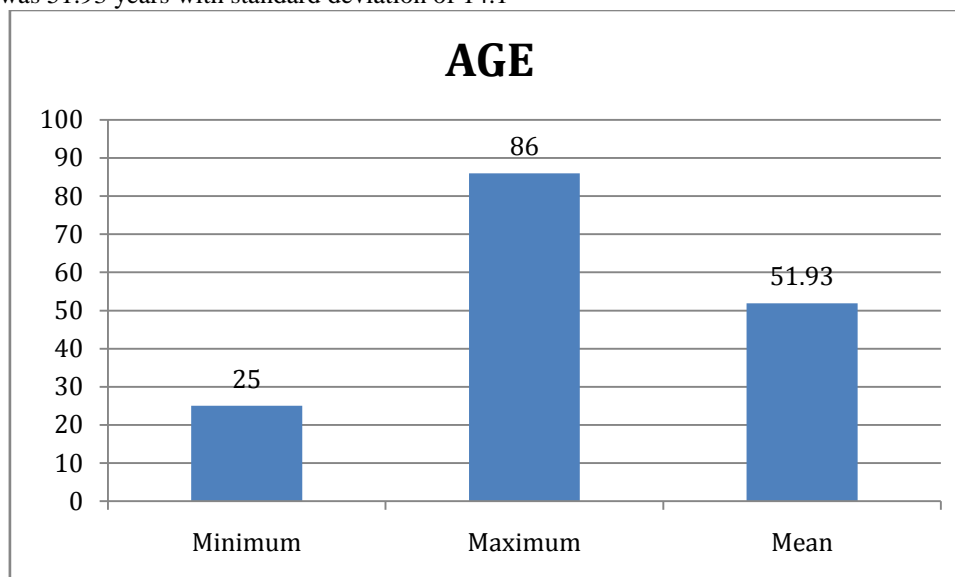
transported to pathology laboratory for staining using Hematoxylin and Eosin (H and E) method and immediate reporting by the cytopathologist. Whenever possible, the lesions were subclassified using specific cytological

**V. OBSERVATIONS AND RESULTS**

**Table 1- Distribution according to age**

	N	Minimum	Maximum	Mean	Std. Deviation
AGE	40	25	86	51.93	14.101

Mean age was 51.93 years with standard deviation of 14.1

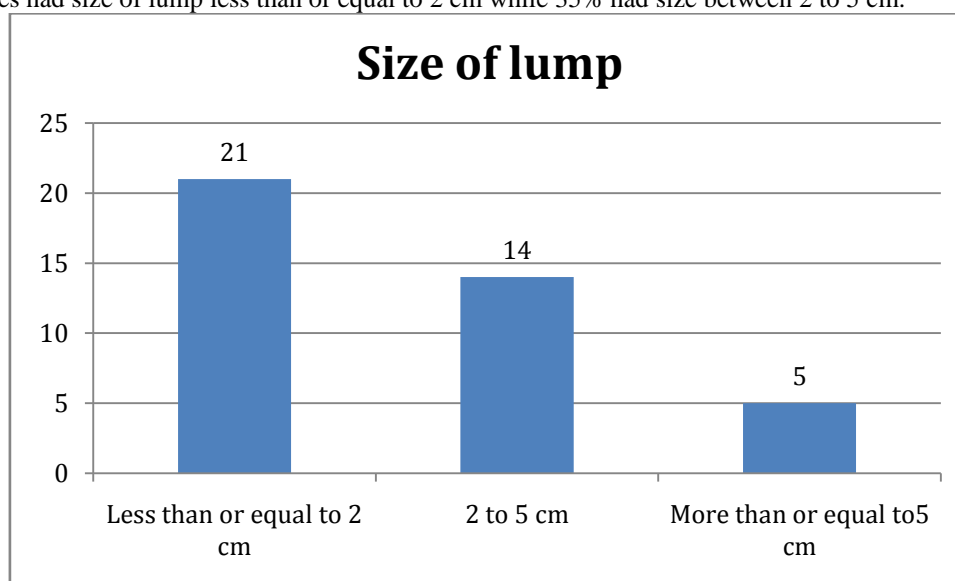


**Graph 1- Distribution according to age**

**Table 2- Distribution according to size of lump at the time of presentation**

Size of lump	Number	Percent
Less than or equal to 2 cm	21	52.5%
2 to 5 cm	14	35%
More than or equal to 5 cm	5	12.5%
Total	40	100%

52.5% cases had size of lump less than or equal to 2 cm while 35% had size between 2 to 5 cm.

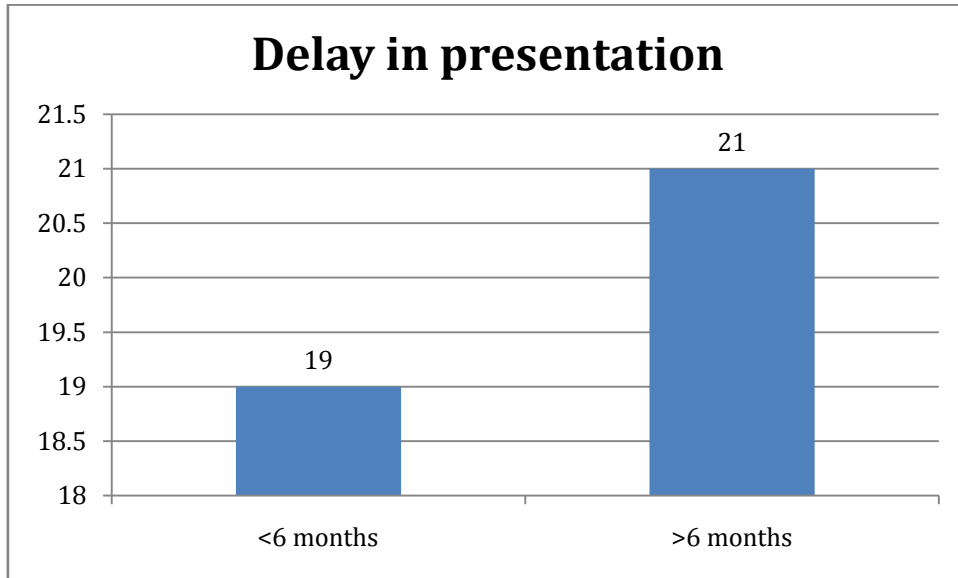


**Graph 2- Distribution according to size of lump at the time of presentation**

**Table 3- Distribution according to delay in presentation of lump**

Delay in presentation	Number	Percent
<6 months	19	47.5%
>6 months	21	52.5%

Delay in presentation of lump was less than 6 months in 47.5% cases while greater than 6 months in 52.5% cases.

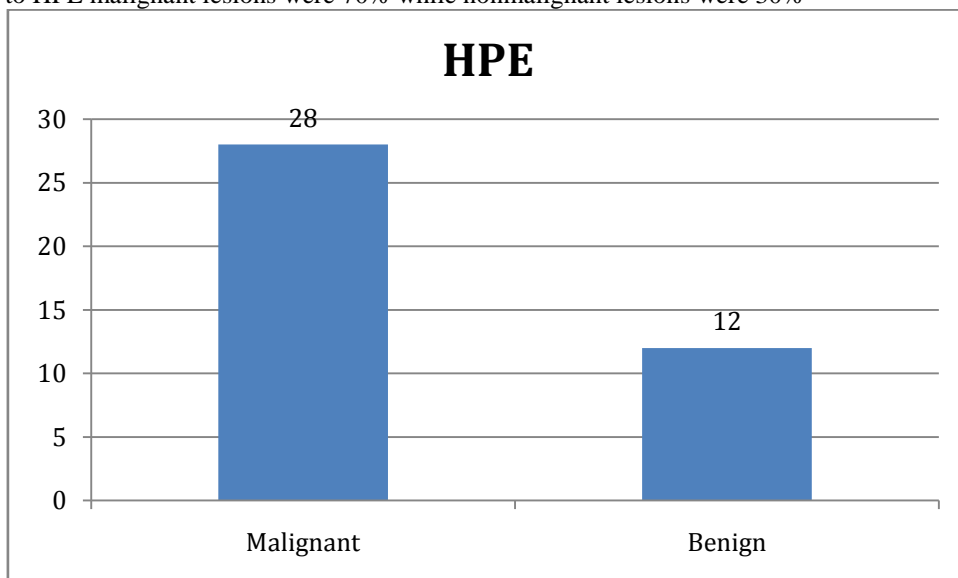


**Graph 3- Distribution according to delay in presentation of lump**

**Table 4- Distribution according to histopathological results**

HPE	Number	Percent
Malignant	28	70%
Benign	12	30%

According to HPE malignant lesions were 70% while nonmalignant lesions were 30%

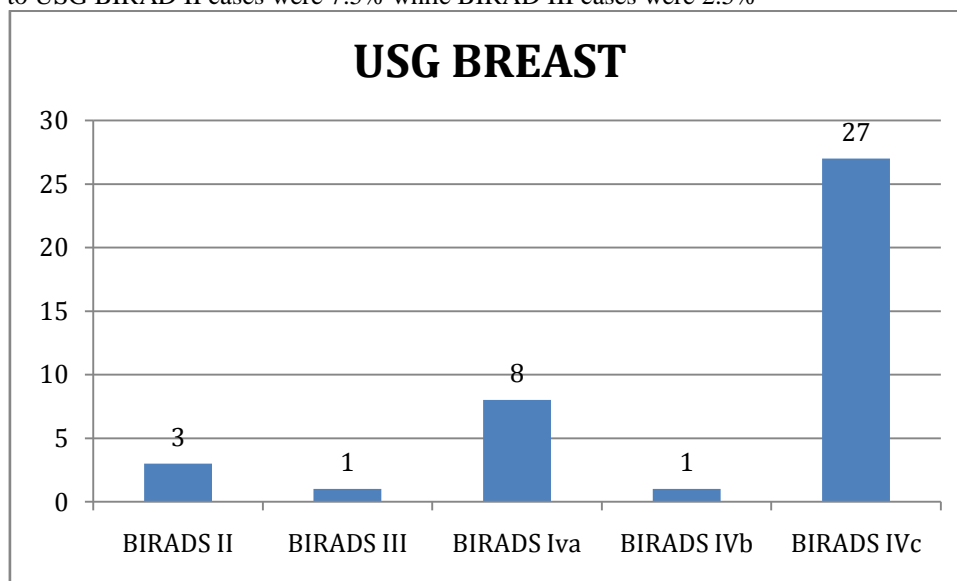


**Graph 4- Distribution according to histopathological results**

**Table 5 - Distribution according to USG findings**

USG BREAST	Number	Percent
BIRADS II	3	7.50%
BIRADS III	1	2.50%
BIRADS Iva	8	20.00%
BIRADS IVb	1	2.50%
BIRADS IVc	27	67.50%

According to USG BIRAD II cases were 7.5% while BIRAD III cases were 2.5%

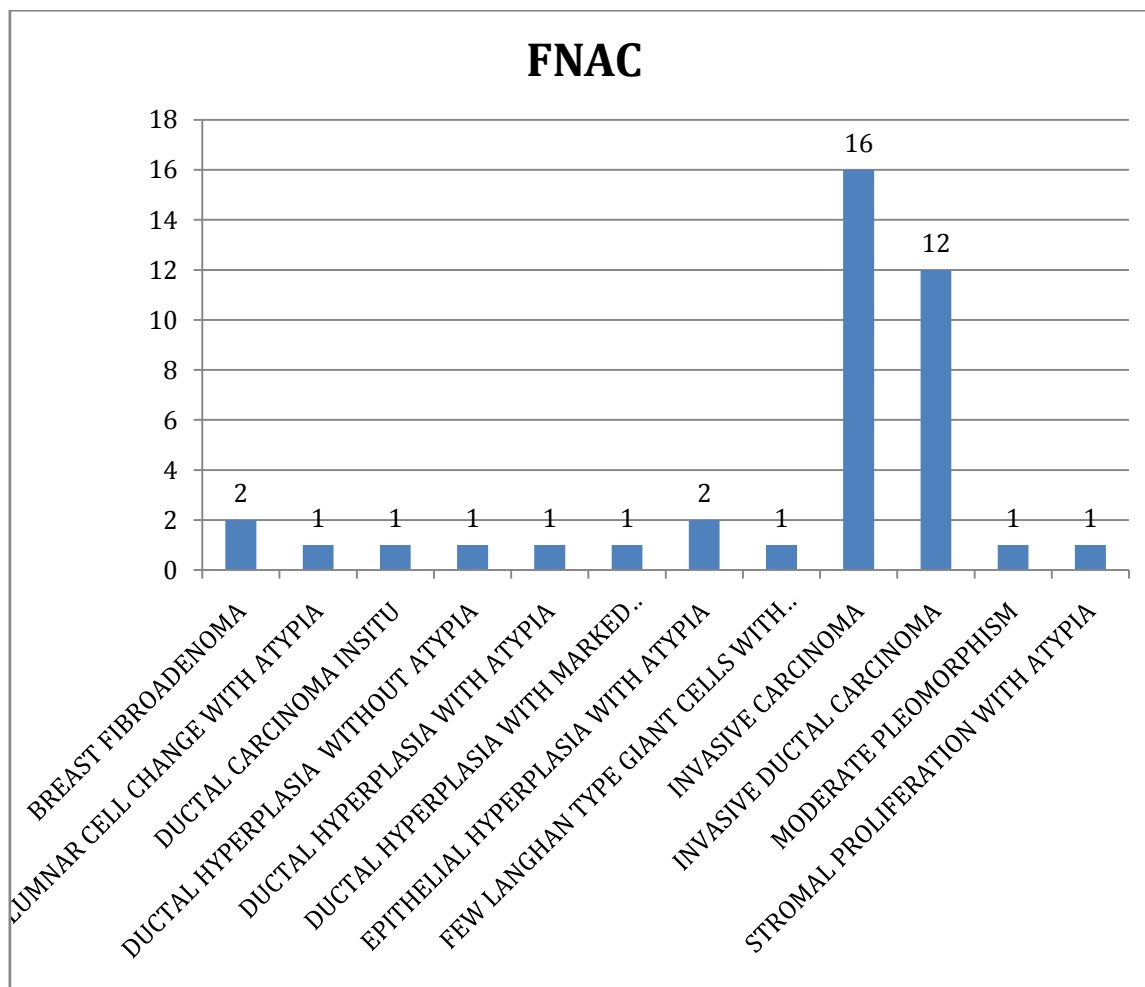


**Graph 5 - Distribution according to USG findings**

**Table 6- Distribution according to FNAC**

FNAC	Number	Percent
Breast fibroadenoma	2	5.00%
Columnar cell change with atypia	1	2.50%
Ductal carcinoma insitu	1	2.50%
Ductal hyperplasia without atypia	1	2.50%
Ductal hyperplasia with atypia	1	2.50%
Ductal hyperplasia with marked apocrine metaplasia	1	2.50%
Epithelial hyperplasia with atypia	2	5.00%
Few langhan type giant cells with atypia	1	2.50%
Invasive carcinoma	16	40.00%
Invasive ductal carcinoma	12	30.00%
Moderate pleomorphism	1	2.50%
Stromal proliferation with atypia	1	2.50%

According to FNAC invasive carcinoma was found in 40% cases while breast fibroadenoma was seen in 5% cases.

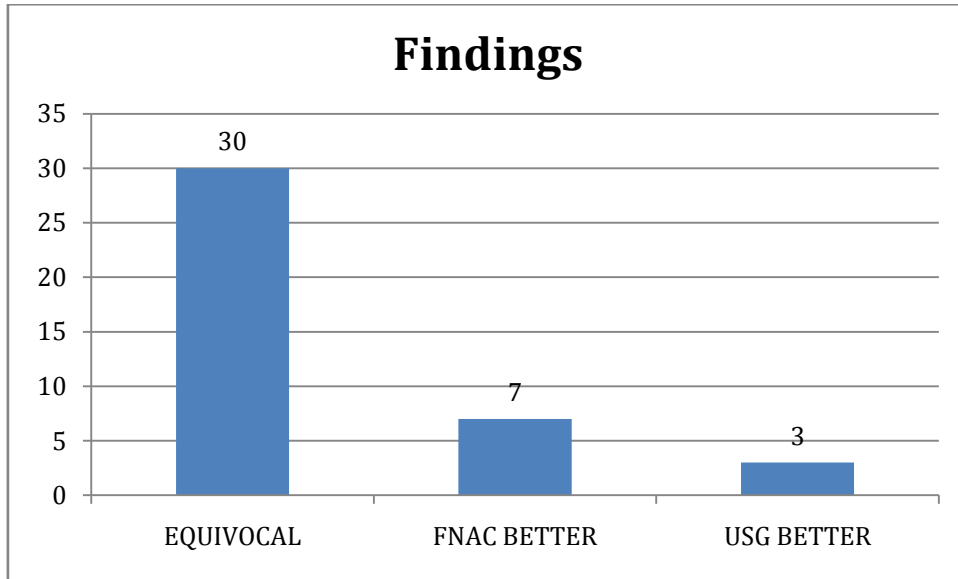


Graph 6- Distribution according to FNAC

Table 7 –Distribution according to findings

Findings	Number	Percent
<b>EQUIVOCAL</b>	30	75.00%
<b>FNAC BETTER</b>	7	17.50%
<b>USG BETTER</b>	3	7.50%

Findings were equivocal in 75% cases while FNAC was better in 17.5% cases and USG was better in 7.5% cases

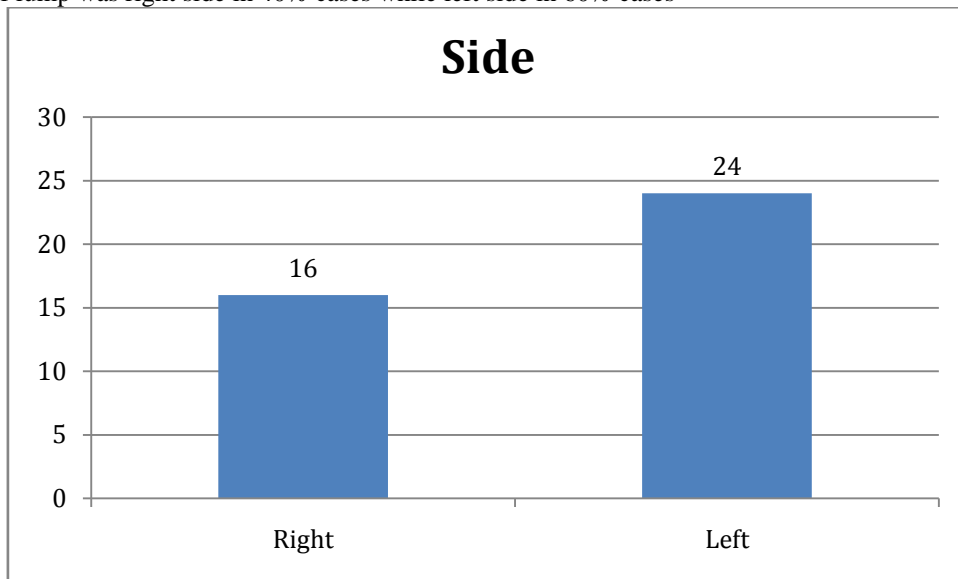


Graph 7 –Distribution according to findings

Table 8- Distribution according to side of lump

Side	Number	Percent
Right	16	40%
Left	24	60%

Location of lump was right side in 40% cases while left side in 60% cases



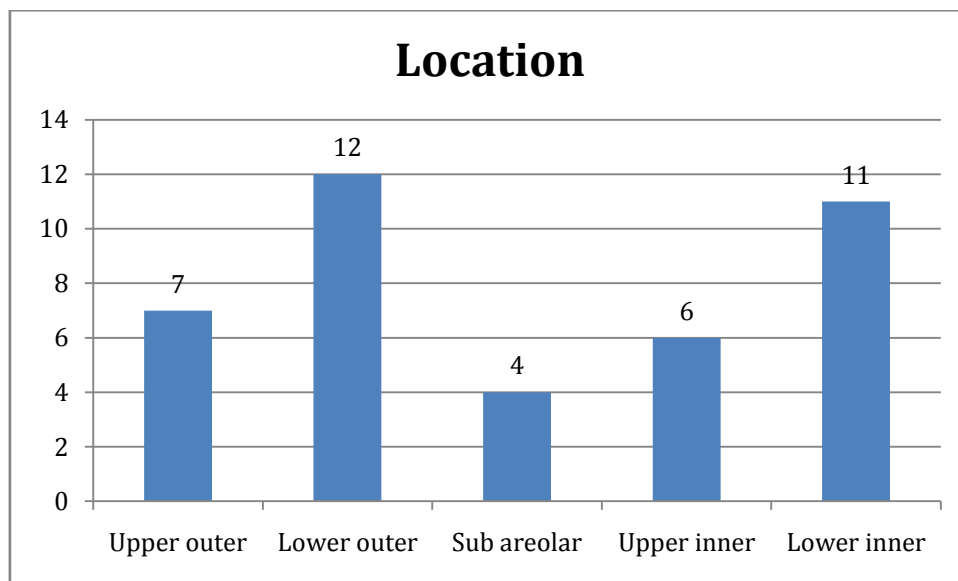
Graph 8- Distribution according to side of lump

Table 9- Distribution according to location of lump

Location	Number	Percent
Upper outer	7	17.5%
Lower outer	12	30%
Sub areolar	4	10%
Upper inner	6	15%
Lower inner	11	27.5%
Total	40	100%

Lump was located in upper outer region in 17.5% cases and subareolar in 10% cases. 15% cases had upper inner location and 27.5% had lower inner location





Graph 9- Distribution according to location of lump

Table 10- Sensitivity of FNAC with respect to HPE

HPE/FNAC	Malignant	Benign	Total
Malignant	25	3	28
Benign	2	10	12
Total	27	13	40

Sensitivity = 92.5%

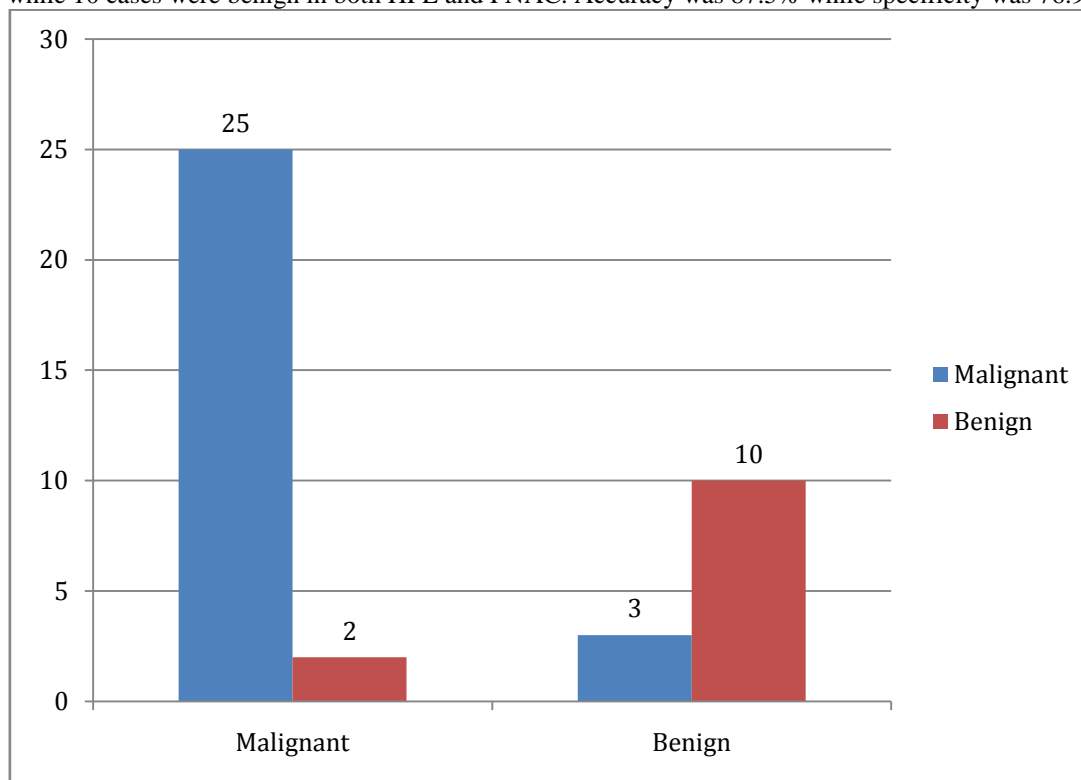
Specificity= 76.9%

PPV= 89.3%

NPV= 83.3%

Accuracy= 87.5%

Sensitivity of FNAC with respect to HPE was found to be 92.5%. 25 cases were malignant in both FNAC and HPE while 10 cases were benign in both HPE and FNAC. Accuracy was 87.5% while specificity was 76.9%



Graph 10- Sensitivity of FNAC with respect to HPE

**Table 11- Sensitivity of USG with respect to HPE**

HPE/USG	Malignant	Benign	Total
<b>Malignant</b>	21	7	28
<b>Benign</b>	2	10	12
<b>Total</b>	23	17	40

Sensitivity = 91.3%

Specificity= 58.8%

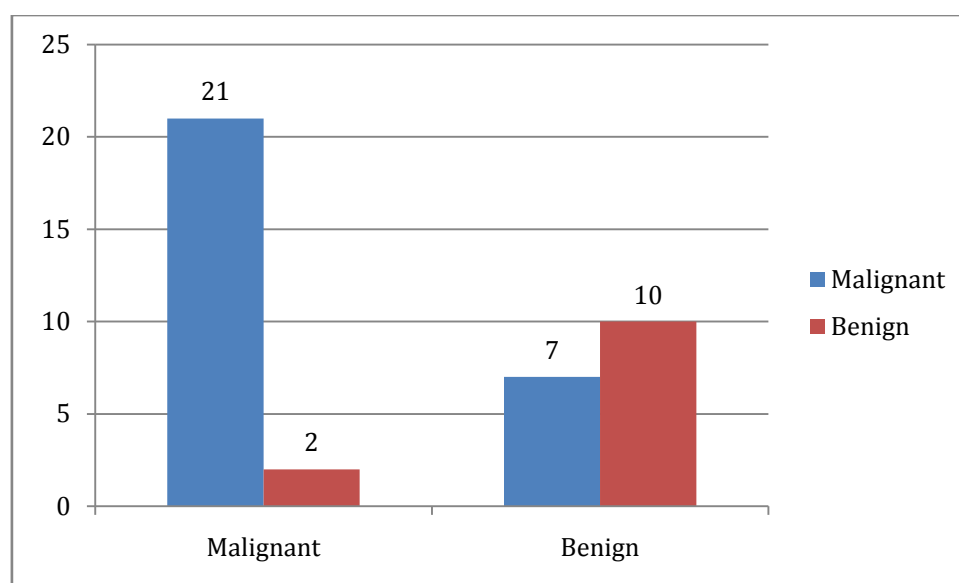
PPV= 75%

NPV= 83.3%

Accuracy= 77.5%

Sensitivity of USG with respect to HPE is 91.3% while specificity is 58.8%.

Accuracy of USG is 77.5%. 21 cases were malignant in both USG and HPE while 10 cases were benign in both HPE and USG.



**Graph 11- Sensitivity of USG with respect to HPE**

## VI. DISCUSSION

The present study was done at our tertiary care centre on 40 cases to evaluate the accuracy of USG and FNAC in the diagnosis of newly detected clinically palpable breast lumps in comparison to the final HPE report of biopsied specimens.

In the present study, mean age was 51.93 years with standard deviation of 14.1. This is similar to the studies of Farras Roca JA et al<sup>91</sup>, Ogbuanya AU et al<sup>93</sup>, Panwar H et al<sup>94</sup>, Richie AJ et al<sup>16</sup>, Obrzut M et al<sup>92</sup> and Kalwani R et al<sup>90</sup>.

Farras Roca JA et al<sup>91</sup> multidisciplinary study assessing ultrasound-guided fine-needle aspiration (USFNA) in nonpalpable breast lesions found mean age of the patients was 57.8±12.2 years (minimum 18 years and maximum 94 years). Patients were younger than 50 years at USFNA in 708 (27.2%).

Ogbuanya AU et al<sup>93</sup> descriptive prospective study found mean age of the 88 breast cancer patients ranged from 18–85 years with a mean of 45.8±15.7 years.

Panwar H et al<sup>94</sup> study assessing FNAC of Breast Lesions with Cytohistological Grading of Breast Carcinoma found age group ranged from 15 years to 79 years and majority of the cases (60.5%) were in 2nd and 3rd decade.

Richie AJ et al<sup>16</sup> prospective, quantitative and descriptive study assessing the radiological and cytological correlation of breast lesions with histopathological findings found age of the patients ranged from 18 to 75 years with mean age of 46 years.

ObrzutM et al<sup>92</sup> retrospective study assessing fine-needle aspiration biopsy (FNAB) in the diagnosis of breast lesions found age ranged from 20 to 64 years and abnormalities were diagnosed most frequently in the age groups 36-45 and 26-35 years.

Kalwani R et al<sup>90</sup> cross-sectional, prospective study found age range of malignant cases was 26 to 75 years with the mean age of  $51.25 \pm 11.40$  years and the maximum malignant cases were found in the 5th decade followed by 6th decade.

In our study, 52.5% cases had size of lump less than or equal to 2 cm while 35% had size between 2 to 5 cm.

Kalwani R et al<sup>90</sup> cross-sectional, prospective study found size of lump in 56.36% of the malignant cases T3 stage (>5 cm) whereas 41.82% cases had a lump size of T2 stage ( $2 \leq 5$  cm) with the overall average size of lump being  $5.36 \pm 2.93$  cm.

It was observed in the present study that delay in presentation of lump was less than 6 months in 47.5% cases while greater than 6 months in 52.5% cases.

Kalwani R et al<sup>90</sup> cross-sectional, prospective study found that 72% of the patients that were from the rural areas had consulted the clinician after a delay of >6 months on the self-detection of lump and approximately 70% of the malignant cases that were from urban cities had consulted the clinician within the 15 days of noticing the lump.

It was observed in our study that location of lump was right side in 40% cases while left side in 60% cases. Panwar H et al<sup>94</sup> noted similar observations in their study.

Panwar H et al<sup>94</sup> study found predominance of right sided breast lesions 107 (47%) cases, followed by left side 103 (46%) cases and the bilateral 15 (7%) cases.

In the present study, lump was located in upper outer region in 17.5% cases and subareolar in 10% cases. 15% cases had upper inner location and 27.5% had lower inner location. This is comparable to the studies of Farras Roca JA et al<sup>91</sup>, Kalwani R et al<sup>90</sup> and ObrzutM et al<sup>92</sup>.

Farras Roca JA et al<sup>91</sup> multidisciplinary study showed contralateral in 641 (24.6%), ipsilateral in 664 (25.5%), and bilateral in 158 (6.1%).

Kalwani R et al<sup>90</sup> cross-sectional, prospective study found maximum number of lumps 47.41% were in the upper-outer quadrant.

ObrzutM et al<sup>92</sup> retrospective study found slightly higher rate of lesions in the left breast and most of the abnormalities (60%) were found in the upper-outer quadrant with the majority of lesions smaller than 15 mm. Abnormalities bigger than 15 mm accounted for 31% of all cases.

In our study, according to HPE malignant lesions were 70% while nonmalignant lesions were 30%. This is concordant to the studies of Farras Roca JA et al<sup>91</sup>, Kalwani R et al<sup>90</sup>, Vijaya K et al<sup>97</sup> and Ogbuanya AU et al<sup>93</sup>.

Traditionally, histopathology is utilized to make diagnosis of breast lesions; but with combined diagnostic approach, FNAC has now become an established definitive diagnostic procedure for breast diseases worldwide.

Farras Roca JA et al<sup>91</sup> multidisciplinary study found according to the diagnostic reference standard, 1,599 (61.5%) NPBLs were benign and 1,002 (38.5%) were malignant.

Kalwani R et al<sup>90</sup> in 2016 in a cross-sectional, prospective study found out of the 116 patients, HPE being gold standard revealed 61 patients (52.58%) had benign whereas 55 patients (47.41%) were malignant breast lump.

Vijaya K et al<sup>97</sup> retrospective study observed incidence of benign lesions was 80% with FNAC and 74% in biopsy.

Ogbuanya AU et al<sup>93</sup> descriptive prospective study showed of the 88 histopathological diagnoses patients over three-fourth (76.1%) of the cancers were due to invasive ductal carcinomas.

It was observed in the present study that according to USG BIRAD II cases were 7.5% while BIRAD III cases were 2.5%. This finding was like the studies of Farras Roca JA et al<sup>91</sup>, Richie AJ et al<sup>16</sup>, Panwar H et al<sup>94</sup> and Kalwani R et al<sup>90</sup>.

Farras Roca JA et al<sup>91</sup> multidisciplinary study observed BI-RADS category 2 in 196 (7.5%) cases, BI-RADS category 3 in 809 (31.1%) cases, BI-RADS category 4A in 366 (14.1%) cases, BI-RADS category 4B in 341 (13.1%) cases, BI-RADS category 4C in 498 (19.1%) cases, and BI-RADS category 5 in 343 (13.2%) cases respectively.

Richie AJ et al<sup>16</sup> prospective, quantitative and descriptive study found on breast ultrasonography 98 cases of the 158 cases were diagnosed as benign breast disease (BIRADS I, II and III). 60 cases were diagnosed as suspicious for carcinoma or carcinoma of the breast (BIRADS IV, V).

Panwar H et al<sup>94</sup> study found out of the total 225 cases, the final cytological report was as per the IAC coding system and had C1 in 03 (1.3%) cases, C2 in 186 (82.6%) cases, C3 in 13 (5.7%) cases, C4 in 04 (1.7%) cases, and C5 in 19 (8.4%) cases. C3 lesion were fibrocystic disease with mild atypia 01 case, benign fibroepithelial lesion 03 cases, fibroadenoma with atypia 05 cases, benign phyllodes tumor 03, and papillary neoplasm 01 case. C4 lesions 4 cases of suspicious for duct carcinoma. C5 lesions were all ductal carcinoma.

Kalwani R et al<sup>90</sup> study showed USG 64 as benign, 46 as malignant, 6 as indeterminate with no normal breast finding.

It was observed in our study that according to FNAC invasive carcinoma was found in 40% cases while breast fibroadenoma was seen in 5% cases. Similar observations were noted in the studies of Richie AJ et al<sup>16</sup>, Panwar H et al<sup>94</sup>, Vijaya K et al<sup>97</sup>, Farras Roca JA et al<sup>91</sup> and Kalwani R et al<sup>90</sup>.

Richie AJ et al<sup>16</sup> prospective, quantitative and descriptive study found on FNAC 91 cases were diagnosed as benign and 67 cases were diagnosed as malignant. Cytologically of the 91 benign cases, fibroadenoma being the commonest, followed by benign proliferative breast disease, fibrocystic disease, duct ectasia, mastitis and least being phylloides.

Panwar H et al<sup>94</sup> study found among C2 lesions, 48.3% (90) cases were fibroadenoma followed by 32.7% (61) cases of benign breast disease, inflammatory lesion 07% (13) cases, fibrocystic disease in 5.4% (10) cases, galactocele 4% (07) cases, and mastitis 2.6% (05) cases.

Vijaya K et al<sup>97</sup> retrospective study assessing various breast lesions on FNAC and their Histopathological correlation FNAC showed 76 cases were benign, 2 cases were atypical, 3 were suspicious of malignancy, 10 cases were diagnosed as malignant and 4 cases was unsatisfactory. Of the 76 benign cases on FNAC majority were fibroadenoma 55, followed by fibrocystic disease 15, suppurative inflammation i.e abscess -4, and phyllodes tumor -1. The cytological spectrum of 10 malignant cases showed that 8 cases were IDC and 1 each of medullary carcinoma and lobular carcinoma.

Farras Roca JA et al<sup>91</sup> multidisciplinary study found cytologically, 1,600 (61.5%) NPBLs were benign, 185 (7.1%) were suspicious, 794 (30.5%) were malignant, and 22 (0.9%) were inadequate. Among benign lesions, 24 (1.5%) showed atypical epithelial hyperplasia (14 ductal and 10 lobular). Malignant lesions were 797 (79.5%) ductal invasive carcinomas, 136 (13.6%) lobular invasive carcinomas, 11 (1.1%) mixed lobular and ductal carcinomas, eight (0.8%) other (nonductal and nonlobular) invasive carcinomas, 40 (4%) ductal in situ carcinomas, eight (0.8%) lobular in situ carcinomas, and two (0.2%) sarcomas.

Kalwani R et al<sup>90</sup> study reported FNAC 67 (57.7%) breast lumps as benign and 47 (40.51%) cases as malignant with 1 case each of indeterminate report and inadequate sample.

In the present study, findings were equivocal in 75% cases while FNAC was better in 17.5% cases and USG was better in 7.5% cases. This is similar to the studies of Farras Roca JA et al<sup>91</sup>, Ogbuanya AU et al<sup>93</sup> and Panwar H et al<sup>94</sup>.

Farras Roca JA et al<sup>91</sup> multidisciplinary study showed among 1,002 malignant NPBLs, cytology yielded concordant malignant results in 780 (77.8%), suspicious results in 148 (14.7%), benign results in 67 (6.7%), and inadequate results in seven (0.7%). Among 1,599 benign lesions, cytology showed concordant benign results in

1,533 (95.8%), suspicious results in 37 (2.3%), malignant results in 14 (0.9%), and inadequate results in 15 (0.9%) cases. The diagnostic accuracy of USFNA was therefore 88.9% (2,313/2,601).

Ogbuanya AU et al<sup>93</sup> descriptive prospective study found FNAC proved an overall concordance rate of 87.7% for 57 histologically confirmed cancer cases and of the 51 patients with breast ultrasound reports, 28 were highly suspicious of malignancy, seven benign, and the rest 16 equivocal. Overall, ultrasound achieved concordance of 54.9% and equivocal rate of 31.4%.

Panwar H et al<sup>94</sup> study reported overall Robinson's grade for cytology was well differentiated 15.7% cases, moderately differentiated in 57.8% cases, and poorly differentiated in 26.3% cases.

In our study, Sensitivity = 92.5% Specificity= 76.9% PPV= 89.3%, NPV= 83.3% and Accuracy= 87.5% was noted. Sensitivity of FNAC with respect to HPE was found to be 92.5%. 25 cases were malignant in both FNAC and HPE while 10 cases were benign in both HPE and FNAC. Accuracy was 87.5% while specificity was 76.9%. This is comparable to the studies of Ogbuanya AU et al<sup>93</sup>, Farras Roca JA et al<sup>91</sup>, Vijaya K et al<sup>97</sup>, Panwar H et al<sup>94</sup> and Kalwani R et al<sup>90</sup>.

Ogbuanya AU et al<sup>93</sup> descriptive prospective study evaluating FNAC in the triple assessment of patients with malignant breast lumps found FNAC performed better than clinical examination in for breast malignancies were 97.2% sensitivity, 98.9% specificity, 1.4% false positive, 2.1% false negative, 98.6% PPV, 97.9% NPV and overall diagnostic accuracy of 98.2%. FNAC showed an overall concordance rate of 87.7%. The validity results for malignant tumors ≤5 cm included sensitivity (83.3%), specificity (100.0%), false positive rate (FPR) (0.0%), false negative rate (FNR) (2.3%), and ODA of 97.9%. The validities for lumps >5 cm had a sensitivity (98.0%), specificity (94.7%), FPR (2%), FNR (5.3%), and ODA of 97.1%.

Farras Roca JA et al<sup>91</sup> study found NPV for benign cytologic diagnosis was 96%, and the PPV for a cytologic diagnosis of malignancy was 98%. For a cytologic suspicious diagnosis, the PPV was 80%.

Vijaya K et al<sup>97</sup> retrospective study showed on histopathological correlation 75 cases 56 were diagnosed as benign by FNAC. In these cases histopathology of 56 was fibroadenoma, 4 cases showed atypical ductal hyperplasia. 2 Cases diagnosed as atypical on FNAC, turned out to be fibrocystic disease with apocrine metaplasia on histopathology. 3 cases which were suspicious on cytology were diagnosed to be malignant lesions on histopathology the histopathology of 10 cases diagnosed by FNAC as malignant was the same in histopathology and there was no disparity. The three cases which were unsatisfactory on FNAC were biopsied and showed malignancy in 2 cases and benign histopathology in one case.

Panwar H et al<sup>94</sup> study found on histological grading most of the cases were in moderately differentiated grade 58% (11 cases) followed by poorly differentiated in 26.3% (06 cases) and well-differentiated in 16% (02 cases) and on cytology was well differentiated 15.7% cases, moderately differentiated in 57.8% cases, and poorly differentiated in 26.3% cases. Cytohistological grade concordance was found to be 89% (17 cases) with an overall sensitivity and specificity of 100% and 97%, respectively.

Kalwani R et al<sup>90</sup> study observed FNAC with a sensitivity of 88.68%, specificity of 100%, PPV of 100%, NPV of 91.04% with an overall diagnostic accuracy of 94.73%. Of 116 cases, only 16 cases where disparity was found between reports of USG and FNAC with 6 false negative cases in FNAC in which the masses were benign were found malignant on final HPE. In all those 6 cases, USG could correctly diagnose them as malignant.

In the present study, Sensitivity = 91.3%, Specificity= 58.8%, PPV= 75%, NPV= 83.3% and Accuracy= 77.5% was noted. Sensitivity of USG with respect to HPE is 91.3% while specificity is 58.8%. Accuracy of USG is 77.5%. 21 cases were malignant in both USG and HPE while 10 cases were benign in both HPE and USG. This is concordant to the studies of Farras Roca JA et al<sup>91</sup>, Ismail Al-Saadi W et al<sup>98</sup>, Richie AJ et al<sup>16</sup>, Ismail Al-Saadi W et al<sup>98</sup>, Richie AJ et al<sup>16</sup>, Kumar N et al<sup>99</sup>, Kulandai Velu AR et al<sup>100</sup> and Kalwani R et al<sup>90</sup>.

Farras Roca JA et al<sup>91</sup> multidisciplinary study showed USFNA's sensitivity, specificity, PPV, and NPV were, 92.6%, 96.8%, 94.8%, and 95.4% respectively.

Ismail Al-Saadi W et al<sup>98</sup> study evaluating the imaging modalities for the characterization of non-palpable breast masses in conjunction with cytology / histopathology reported breast ultrasound had a sensitivity of 100%,

specificity of 91.6 respectively. The sensitivity, specificity, positive predictive value negative predictive value & accuracy for ultrasonography was 100%, 91.1%, 55.5%, 100% & 92% respectively.

Richie AJ et al<sup>16</sup> prospective, quantitative and descriptive study reported a sensitivity of 90.6% and specificity of 97.8%. Benign lesions of the breast were more readily diagnosed by ultrasound than malignant lesions.

Kumar N et al<sup>99</sup> study on evaluation of Breast Masses with Pathological correlation found the sensitivity and specificity of breast ultrasound in categorising breast lesions as benign and malignant was 85.4% and 89.31% respectively.

Kulandai Velu AR et al<sup>100</sup> study on cytological evaluation of benign breast lesions with histopathological correlation showed that breast FNAC had a sensitivity ranging from 82% to 97.5% and specificity of more than 99% respectively.

Kalwani R et al<sup>90</sup> study reported USG revealed the sensitivity of 92%, specificity 100%, PPV of 100%, NPV of 93.75% with the overall diagnostic accuracy of 96.36% respectively. 4 false negative cases on USG as benign were malignant on HPE. Out of those 4 cases, 2 were correctly diagnosed by FNAC as malignant and of the 2 false negative cases by USG, FNAC was inconclusive in diagnosing the condition.

## **VII. SUMMARY**

The present study was done at our tertiary care centre on 40 cases to evaluate the accuracy of USG and FNAC in the diagnosis of newly detected clinically palpable breast lumps in comparison to the final HPE report of biopsied specimens. The following observations were noted:

1. Mean age was 51.93 years with standard deviation of 14.1
2. 52.5% cases had size of lump less than or equal to 2 cm while 35% had size between 2 to 5 cm.
3. Delay in presentation of lump was less than 6 months in 47.5% cases while greater than 6 months in 52.5% cases.
4. According to HPE malignant lesions were 70% while nonmalignant lesions were 30%.
5. According to USG BIRAD II cases were 7.5% while BIRAD III cases were 2.5%
6. According to FNAC invasive carcinoma was found in 40% cases while breast fibroadenoma was seen in 5% cases.
7. Findings were equivocal in 75% cases while FNAC was better in 17.5% cases and USG was better in 7.5% cases
8. Location of lump was right side in 40% cases while left side in 60% cases.
9. Lump was located in upper outer region in 17.5% cases and subareolar in 10% cases. 15% cases had upper inner location and 27.5% had lower inner location
10. Sensitivity of FNAC with respect to HPE was 92.5%, Specificity= 76.9%, PPV= 89.3%, NPV= 83.3% and Accuracy= 87.5% 25 cases were malignant in both FNAC and HPE while 10 cases were benign in both HPE and FNAC. Accuracy was 87.5% while specificity was 76.9%
11. Sensitivity of USG with respect to HPE was 91.3%, Specificity= 58.8%, PPV= 75%, NPV= 83.3% and Accuracy= 77.5%. 21 cases were malignant in both USG and HPE while 10 cases were benign in both HPE and USG.

## VIII. CONCLUSION

Breast ultrasound is a non-invasive imaging-based technique and Breast FNAC is a tissue based minimally invasive technique. Both these diagnostic tools can complement each other. Breast FNAC is more reliable method to diagnose breast lesions with high diagnostic accuracy compared to breast ultrasound. Diagnostically challenging cases and clinically malignant masses histopathological examination should be done, which is the gold standard for tissue diagnosis.

Fine needle aspiration cytology is an accurate and time conserving method in diagnosing benign and malignant lesions of the breast. It is a safe and accurate outpatient method for diagnosing palpable lesions of the breast.

## REFERENCES

- [1]. Chopra R. The Indian scene. *J Clin Oncol*. 2001;19(18 suppl):106–111.
- [2]. Guray M, Sahin AA. Benign breast diseases: classification, diagnosis, and management. *The Oncologist*. 2006;11:435–449.
- [3]. Bhargava GS, Gupta A, Grover A et al. Benign breast disorders: rural Punjab population study compared with urban population studies. *Int Surg J*. 2015, 2(4):629–633.
- [4]. Caleffi M, Filho DD, Borghetti K et al. Cryoablation of benign breast tumors: evolution of technique and technology. *Breast*. 2004;13:397–407.
- [5]. Kelsey JL, Gammon MD. Epidemiology of breast cancer. *Epidemiol Rev*. 1990;12:228–240.
- [6]. Cole P, Mark Elwood J, Kaplan SD. Incidence rates and risk factors of benign breast neoplasms. *Am J Epidemiol*. 1978;108:112–120.
- [7]. Hutchinson WB, Thomas DB, Hamlin WB et al. Risk of breast cancer in women with benign breast lesion. *J Natl Cancer Inst*. 1980;65:13–20.
- [8]. Jones SB. Cancer in the developing world: a call to action. *BMJ*. 1999;319(7208): 505–508
- [9]. Parkin DM, Fernández LMG: Use of statistics to assess the global burden of breast cancer. *Breast J*. 2006;12(s1):S70–S80
- [10]. Saarenmaa I, Salminen T, Geiger U et al. The effect of age and density of the breast on the sensitivity of breast cancer diagnosis by mammography and ultrasonography. *Breast Cancer Res Treat*. 2001; 67:117–123.
- [11]. Breast imaging reporting and data system (BI-RADS). <http://www.acr.org>.
- [12]. Athanasiou A, Tardivon A, Tanter Met al. Breast lesions: quantitative elastography with supersonic shear imaging – preliminary results. *Radiology*. 2010;256:297–303.
- [13]. Duncan JL, 3rd, Cederbom GJ, Champaign JL et al. Benign diagnosis by image-guided core-needle breast biopsy. *Am Surg*. 2000; 66(1):5–9. discussion 9–10.
- [14]. Chiou SY, Chou YH, Chiou HJ et al. Sonographic features of nonpalpable breast cancer: a study based on ultrasound-guided wire-localized surgical biopsies. *Ultrasound Med Biol*. 2006;32:1299–1306.
- [15]. Morris KT, Stevens JS, Pommier RF et al “Usefulness of the triple test score for palpable breast masses,” *Archives of Surgery*. 2001; 136(9):1008–1012.
- [16]. Richie AJ, Mellonie P. Radiological and cytological correlation of breast lesions with histopathological findings in a tertiary care hospital in coastal Karnataka. *International Journal of Contemporary Medical Research*. 2019;6(2):B1–B4.
- [17]. Webb AJ. A cytological study of mammary disease. *Ann R Coll Surg Engl*. 1975;56(4):181–191.
- [18]. Greig ED and Gray AC. Note on the lymphatic glands in sleeping sickness. *Br Med J*. 1904;1(2265):1252.
- [19]. Diamantis A, Magiorkinis E, Koutselini H. Fine needle aspiration (FNA) biopsy: historical aspects. *Folia Histochem Cytobiol*. 2009;47(2):191–197.
- [20]. Berg JW, Robbins GF. A late look at the safety of aspiration biopsy. *Cancer*. 1962; 15:826–827.
- [21]. Chaurasia BD. Chaurasia’s *BD Human Anatomy*. Chapter 3, The Pectoral Region. 4th edition. New Delhi: CBS Publisher. 2004:39–43.
- [22]. Young B, Heath JW, Lowe JS et al. *Wheater’s Functional Histology*. 5th edition. Churchill Livingstone, An imprint of Elsevier. 2006:386–391.
- [23]. Kumar V, Abbas A, Aster JC. *Robbins & Cotran Pathologic Basis of Disease*. 9th ed. Chicago, Illinois: Elsevier. 2014:1043–1071.
- [24]. Ferlay J, Soerjomataram I, Dikshit R et al. Cancer incidence and mortality worldwide: sources, methods and major patterns in GLOBOCAN 2012. *Int J Cancer*. 2015;136: E359–386.
- [25]. Gupta A, Shridhar K, Dhillon PK. A review of breast cancer awareness among women in India: cancer literate or awareness deficit? *Eur J Cancer*. 2015;51: 2058–2066.
- [26]. Porter PL. Global trends in breast cancer incidence and mortality. *Salud Pública de México*. 2009;51: s141–s46.
- [27]. Babu GR, Lakshmi SB, Thiyagarajan JA. Epidemiological correlates of breast cancer in South India. *Asian Pac J Cancer Prev*. 2013;14: 5077–5083.
- [28]. Ali I, Wani WA, Saleem K. Cancer scenario in India with future perspectives. *Cancer Therapy*. 2011;8: 56–70.
- [29]. Kaarthigeyan K. Cervical cancer in India and HPV vaccination. *Indian J Med Paediatr Oncol*. 2012;33: 7–12.
- [30]. Anonymous. *Three Year Report of Population Based Cancer Registries 2012–2014*. Indian Council of Medical Research (ICMR), Bangalore, India 2016.
- [31]. Lakshmi R, Athira R, Joy TM et al. Breast cancer risk factors: preventable and non-preventable. *IRJP*. 2012;3(10):48–52.
- [32]. Singletary SE. Rating the risk factors for breast cancer. *Ann Surg*. 2003;237(4):474–482
- [33]. *Bailey Love’s Short Practice of surgery-25th edition 2009*.
- [34]. Yiangou C. Diagnostic role of cytology in screen detected breast cancer. *Br J Sing*. 1996, 83, 816–819.
- [35]. Cappelari A. Application of monoclonal antibody in diagnosis of human breast cancer by FNAC. *Oncology*. 1990;47(5): 398–400.
- [36]. *Aspiration cytology for Clinicians & Pathologists*. TMH
- [37]. Giard. Value of aspiration cytologic examination of the breast. *Cancer*. 1992;69: 2104–2110.
- [38]. Weigelt B, Geyer FC, Reis-Filho JS. Histological types of breast cancer: how special are they?. *Molecular oncology*. 2010;4(3):192–208.
- [39]. Edge SB, Byrd DR, Compton CC et al. *American Joint Committee on Cancer Staging Manual*, 7th ed, Springer, New York 2010.
- [40]. Gillies RJ. In vivo molecular imaging. *J. Cell. Biochem. Suppl*. 2002;39:231–238.
- [41]. Mankoff DA, Eary JF, Link JM et al. Tumor-specific positron emission tomography imaging in patients: [18F] fluorodeoxyglucose and beyond. *Clin. Cancer Res*. 2007;13:3460–3469.

- [42]. Specht JM, Mankoff DA. Advances in molecular imaging for breast cancer detection and characterization. *Breast Cancer Res.* 2012;14:206.
- [43]. Bos R, van Der Hoeven JJ, van Der Wall E et al. Biologic correlates of 18fluorodeoxyglucose uptake in human breast cancer measured by positron emission tomography. *J. Clin. Oncol.* 2002;20:379–387.
- [44]. MARIBS Study Group. Screening with magnetic resonance imaging and mammography of a UK population at high familial risk of breast cancer: a prospective multicentre cohort study (MARIBS). *The Lancet.* 2005;365(9473):1769-1778.
- [45]. Kolb TM, Lichy J, Newhouse JH. Comparison of the performance of screening mammography, physical examination, and breast US and evaluation of factors that influence them: an analysis of 27,825 patient evaluations. *Radiology.* 2002;225(1):165-175.
- [46]. Shapiro RS, Wagreich J, Parsons RB et al. Tissue harmonic imaging sonography: evaluation of image quality compared with conventional sonography. *AJR. American journal of roentgenology.* 1998;171(5):1203-1206.
- [47]. Stavros AT, Thickman D, Rapp CL et al. Solid breast nodules: use of sonography to distinguish between benign and malignant lesions. *Radiology.* 1995;196(1):123-134.
- [48]. Mainiero MB, Goldkamp A, Lazarus E et al. Characterization of breast masses with sonography. *Journal of ultrasound in medicine.* 2005;24(2):161-167.
- [49]. Zhi H, Ou B, Luo BM et al. Comparison of ultrasound elastography, mammography, and sonography in the diagnosis of solid breast lesions. *Journal of ultrasound in medicine.* 2007;26(6):807-815.
- [50]. Itoh A, Ueno E, Tohno E et al. Breast disease: clinical application of US elastography for diagnosis. *Radiology.* 2006;239(2):341-350.
- [51]. Howlett DC, Marchbank NDP, Allan SM. Sonographic assessment of symptomatic breast – a pictorial review. *J Diagnostic Radiography & Imaging.* 2003;5:3–12.
- [52]. Stavros AT. *The Breast.* In: Rumack CM, Wilson SR, Charboneau JW, editors. *Diagnostic Ultrasound.* 3rd ed. St Louis: M, Elsevier Mosby. 2005: 828.
- [53]. Versluijs FNL, Roumen RMH, Goris RJA. Chronic recurrent subareolar breast abscess: incidence and treatment. *British Journal of Surgery.* 2002;87:952.
- [54]. Shetty MK, Shah Y. Sonographic Findings in Focal Fibrocystic Changes of the Breast. *Ultrasound Quarterly.* 2002;18:35–40.
- [55]. Rizzatto G, Chersevani R, Giuseppetti GM et al. *Sonography. Breast Ultrasound.* Bologna: Editorial Grosso; 1993: 15–80.
- [56]. Valea FL, Katz VL, Lobo RA et al. *Breast diseases: diagnosis and treatment of benign and malignant disease. Comprehensive Gynecology.* 5th ed. Philadelphia, Pa: Mosby Elsevier. 2007: 15.
- [57]. Stavros AT. *Benign Solid Nodules: Specific pathologic diagnosis.* In: Stavros AT, editor. *Breast Ultrasound. Vol. 13.* Lippincott Williams & Wilkins. 2004: 528–596.
- [58]. Maniero MB, Goldkamp A, Lazarus E et al. Characterization of Breast Masses with Sonography. *J Ultrasound Med.* 2005;24:161–167.
- [59]. Meyberg-Solomayer GC, Kraemer B, Bergmann A et al. Does 3-D sonography bring any advantage to noninvasive breast diagnostics? *Ultrasound Med Biol.* 2004;30:583–589.
- [60]. Lee WJ, Chu JS, Huang CS et al. Breast cancer vascularity: Color Doppler sonography and histopathology study. *Breast Cancer Research & Treatment.* 1996;37:291–298.
- [61]. D’Orsi CJ, Sickles EA, Mendelson EB et al. *ACR BI-RADS Atlas, 5th ed. Breast Imaging Reporting and Data System.* American College of Radiology, 2013.
- [62]. Mendelson EB, Böhm-Vélez M, Berg WA et al. *ACR BI-RADS® Ultrasound. ACR BI-RADS® Atlas, Breast Imaging Reporting and Data System.* Reston, VA,: American College of Radiology. 2013.
- [63]. Magny SJ, Shikhman R, Keppke AL. *Breast Imaging Reporting and Data System.* 2020 Jan.
- [64]. He P, Cui LG, Chen W et al. Subcategorization of Ultrasonographic BI-RADS Category 4: Assessment of Diagnostic Accuracy in Diagnosing Breast Lesions and Influence of Clinical Factors on Positive Predictive Value. *Ultrasound Med Biol.* 2019; 45 (5):1253-1258.
- [65]. Zakhour H and Wells C, *Diagnostic Cytopathology of the Breast,* Churchill Livingstone, London, UK, 1999.
- [66]. Scopa CD, Koukouras D, Androulakis J et al. “Sources of diagnostic discrepancies in fine-needle aspiration of the breast,” *Diagnostic Cytopathology.* 1991;7(5):546– 548.
- [67]. Lee KR, Foster RS, Papillo JL. “Fine needle aspiration of the breast. Importance of the aspirator,” *ActaCytologica.* 1987;31(3): 281–284.
- [68]. Brown LA, Coghil SB. “Fine needle aspiration cytology of the breast: factors affecting sensitivity,” *Cytopathology.* 1991;2(2):67–74.
- [69]. Zarbo RJ, Howanitz PJ, Bachner P. “Interinstitutional comparison of performance in breast fine-needle aspiration cytology: a Q-probe quality indicator study,” *Archives of Pathology and Laboratory Medicine.* 1991; 115(8): 743–750.
- [70]. The uniform approach to breast fine needle aspiration biopsy. A synopsis,” *ActaCytol.* 1996; 40: 1120–1126.
- [71]. Howell LP, Gandour-Edwards R, Folkins K et al. “Adequacy evaluation of fine-needle aspiration biopsy in the breast health clinic setting,” *Cancer.* 2004;102(5):295–301.
- [72]. Boerner S, and Sneige N. “Specimen adequacy and falsenegative diagnosis rate in fine-needle aspirates of palpable breast masses,” *Cancer.* 1998;84(6): 344–348.
- [73]. Rubenchick IR, Sneige N, Edeiken B et al. “Insearch of specimen adequacy in fine needle aspirates of non palpable breast lesions,” *American Journal of Clinical Pathology.* 1997;108(1): 13–18.
- [74]. Goodson WH, Mailman R, Miller TR. “Three year follow-up of benign fine-needle aspiration biopsies of the breast,” *American Journal of Surgery.* 1987; 154(1) 58–61.
- [75]. O’Malley F, Casey TT, Winfield AC et al. “Clinical correlates of false-negative fine needle aspirations of the breast in a consecutive series of 1005 patients,” *Surgery Gynecology and Obstetrics.* 1993; 176(4):360–364.
- [76]. Layfield LJ, Mooney EE, Glasgow B et al. What constitutes an adequate smear in fine-needle aspiration cytology of the breast?” *Cancer.* 1997; 81(1) 16–21.
- [77]. Tse GM, Tan PH, Pang ALM et al. “Calcification in breast lesions: pathologists’ perspective,” *Journal of Clinical Pathology.* 2008; 61(2):145–151.
- [78]. Opez-Ferrer PL, Jiménez-Heffernan JA, Vicandi B et al. “Fine needle aspiration cytology of breast fibroadenoma: a cytohistologic correlation study of 405cases,” *ActaCytologica.* 1999; 43(4): 579–586.
- [79]. Maygarden SJ, Novotny DB, Johnson DE et al. “Subclassification of benign breast disease by fine needle aspiration cytology: comparison of cytologic and histologic findings in 265 palpable breast masses,” *ActaCytologica.* 1994;38(2):115–129.
- [80]. Kollur SM and El Hag IA. “FNA of breast fibroadenoma:observer variability and review of cytomorphology with cytohistological correlation,” *Cytopathology.* 2006;17(5): 239–244.



- [81]. Powell CM, Cranor ML, and Rosen PP. "Multinucleated stromal giant cells in mammary fibroepithelial neoplasms: a study of 11 patients," *Archives of Pathology and Laboratory Medicine*. 1994; 118(9): 912–916.
- [82]. Tse GMK, Law BKB, Chan KF et al. "Multinucleated stromal giant cells in mammary phyllodes tumours," *Pathology*. 2001; 33( 2): 153–156.
- [83]. Tse GMK, Ma TKF, Lui PCW et al. "Fine needle aspiration cytology of papillary lesions of the breast: how accurate is the diagnosis?" *Journal of Clinical Pathology*. 2008;61(8): 945–949.
- [84]. Tran PVT, Lui PCW, Yu AMC et al. "Atypia in fine needle aspirates of breast lesions," *Journal of Clinical Pathology*. 2010;63(7):585–591.
- [85]. Arisio R, Cuccorese C, Accinelli G et al. "Role of fine-needle aspiration biopsy in breast lesions: analysis of a series of 4110 cases," *Diagnostic Cytopathology*. 1998; 18(6): 462–467.
- [86]. Ciatto S and Catania S, "Fine needle aspiration cytology of solid masses," *Breast Cytology in Clinical Practice*. 1992: 75–79.
- [87]. Park A, and Ham EK. "Fine needle aspiration cytology of palpable breast lesions: histologic subtype in false negative cases," *Acta Cytologica*. 1997; 41(4):1131–1138.
- [88]. Takhellambam YS, Lourebam SS, Sapam OS et al. Comparison of ultrasonography and fine needle aspiration cytology in the diagnosis of malignant breast lesions. *J Clin Diagn Res*. 2013;7(12):2847-2850.
- [89]. Ajkay N, Bloomquist EV, Martin RC 2<sup>nd</sup> et al. Fine-needle aspiration cytology in the evaluation of patients with radiographically occult, palpable breast abnormalities. *Surgery*. 2015;158(4):946-953.
- [90]. Kalwani R, Kher KS, Daftari SS. Comparison of Ultrasonography and Fine Needle Aspiration Cytology in the Diagnosis of Malignant Breast Lesions in a Rural Setup. *Int J Recent Surg Med Sci*. 2016;2(2):58-65.
- [91]. Farras Roca, JA, Tardivon A, Fabienne Thibault Fet al. Diagnostic Performance of Ultrasound-Guided Fine-Needle Aspiration of Nonpalpable Breast Lesions in a Multidisciplinary Setting: The Institut Curie's Experience, *American Journal of Clinical Pathology*. 2017; 147( 6): 571–579.
- [92]. Obrzut M, Cholewa M, Baran J et al. Does fine-needle aspiration biopsy still have a place in the diagnosis of breast lesions?. *Prz Menopauzalny*. 2018;17(1):28-31.
- [93]. Ogbuanya AU, Anyanwu SN, Iyare EF et al. The Role of Fine Needle Aspiration Cytology in Triple Assessment of Patients with Malignant Breast Lumps. *Niger J Surg*. 2020;26(1):35-41.
- [94]. Panwar H, Ingle P, Santosh T et al. FNAC of Breast Lesions with Special Reference to IAC Standardized Reporting and Comparative Study of Cytohistological Grading of Breast Carcinoma. *J Cytol*. 2020;37(1):34-39.
- [95]. deCursi, JAT, Marques MEA, de Assis Cunha et al. Fine-Needle Aspiration Cytology (FNAC) is a reliable diagnostic tool for small breast lesions ( $\leq 1.0$  cm): a 20-year retrospective study. *Surg Exp Pathol*. 2020;3:29.
- [96]. Harada-Shoji N, Suzuki A, Ishida T et al. Evaluation of Adjunctive Ultrasonography for Breast Cancer Detection Among Women Aged 40-49 Years With Varying Breast Density Undergoing Screening Mammography: A Secondary Analysis of a Randomized Clinical Trial. *JAMA Netw Open*. 2021;4(8):e2121505.
- [97]. Vijaya K, Sirisha O. Study of fine needle aspiration cytology of breast lumps and their histopathological correlation among rural population of Vikarabad, TS. *Indian J Pathol Oncol*. 2021;8(2):198-201.
- [98]. Ismail Al-Saadi W, Ahmed BS, Mahdi QA et al: Non Palpable Breast Mass. *Mustansiriya Medical Journal*. 2016;15(1):20-24.
- [99]. Kumar N, Shilpa N et al. Mammographic And Sonomammographic Evaluation Of Breast Masses With Pathological Correlation. *Innovative Journal of Medical and Health Science* 2016;6:132 – 135.
- [100]. Kulandai Velu AR, Srinivasamurthy BC, Rani J. Cytological evaluation of benign breast lesions with Histopathological correlation. *Indian Journal of Pathology and Oncology*. 2016;3: 7-10.