

## Assessment of Corticosteroid Response for Trigger Finger: A Single Tertiary Centre Experience

Dr. Vishwas, Dr. Rahul Rathi, Dr. Shivam Garg, Dr. B.L Kumar\*

(Department of Orthopaedic, PIMS Hospital, Udaipur, Rajasthan, India,

\*Corresponding Author: Dr. B.L Kumar

(Professor and Head of Orthopaedic Department, Pacific Institute of medical sciences, Udaipur, Rajasthan, India)

### Abstract

Trigger finger is a commonly occurring condition affecting the hand, presenting symptoms of pain, locking, clicking, and catching of the finger. Corticosteroid injection is a non-operative management option used for this condition. In this article, we evaluate the effectiveness of corticosteroid injections for the trigger finger. We conducted our study on a total of 108 patients who had trigger fingers and follow-up them for a period of one year after corticosteroid injection. If the patients experienced recurrence, they were given another injection of corticosteroid, or pulley release surgery was proposed. Out of 108 patients, 18 patients had recurrence after six months, for which they received a second dose of corticosteroid, and six out of those 18 patients had another relapse after a period of four months. These patients received a third dose of corticosteroid injection, and two patients still had a relapse after two months. These patients underwent pulley release surgery for this condition.

**Keywords:** Trigger finger, Corticosteroid injection, Efficacy, Tenosynovitis.

Date of Submission: 03-10-2022

Date of Acceptance: 17-10-2022

### I. Introduction

Trigger finger, also known as tenosynovitis or trigger digit (TD), is caused by mechanical impingement at the level of the A1 pulley, which causes inhibition of smooth tendon gliding that results in progressive pain, clicking, catching, and locking of the digit[1-4]. It has a prevalence rate of 2-5% in the general population and 10% in people with diabetes; diabetes is a significant risk factor for developing trigger fingers. The trigger finger is diagnosed by physical examination; active triggering and tenderness at the A1 pulley aid the diagnosis. Treatment option varies from splinting, anti-inflammatory medications, and steroid injections to surgical release. In our study, we use corticosteroid injection as a primary treatment option for the trigger finger in a group of 108 patients and evaluate its efficacy for the treatment of the trigger finger. Bunnell first described corticosteroid injection for the trigger finger in 1953 [5]. While the exact mechanism by which corticosteroids are used for the treatment of the trigger finger is unclear, they have proven to be an effective first-line treatment [6] with a reported long-term resolution of symptoms in 32-90% of patients. This study aims to evaluate the treatment response of corticosteroids to the trigger finger. Figure 1 shows showing basic anatomy of a finger.

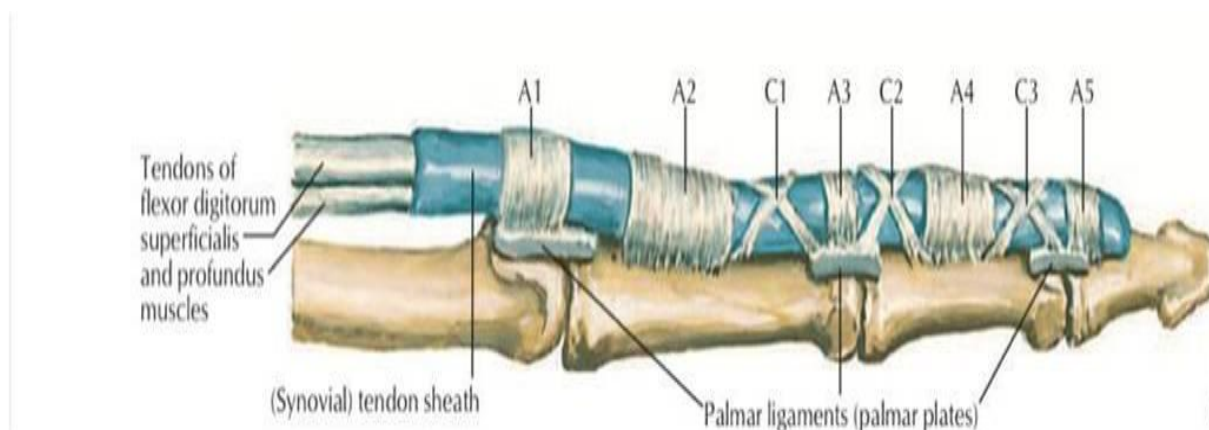


Figure 1: Shows showing basic anatomy of a finger.

## II. Materials And Methods

The study was conducted on a total of 108 patients for a period of 12 months at the orthopedics department of PIMS hospital. The patients who came to our orthopedic department were evaluated for trigger fingers. A detailed history of the symptoms, any comorbidities (diabetes, rheumatoid arthritis, carpal tunnel syndrome, De Quervain tenosynovitis), and consumption of alcohol or tobacco were obtained. The physical examination was carried out using palpation, range of motion of the affected finger consisting of triggering with digit flexion & extension fixed flexion of PIP joint, and provocative tests including flexion and extension of the digits. The patients were then explained about the various treatment options like splinting, anti-inflammatory medications, steroid injections, and surgical release. They have explained the benefits of corticosteroid therapy, and the chances of recurrence were explained as well. If the patients agreed to corticosteroid therapy, written informed consent was obtained.

### Inclusion criteria

1. Both male and female patients with trigger fingers above the age of 20 years.
2. Patients giving consent for corticosteroid therapy.

### Exclusion criteria

1. Immunocompromised patients.
2. Patients with poorly controlled diabetes, hypothyroidism, and amyloidosis.

### Corticosteroid injection regimen

The procedure was carried out under all aseptic precautions. The patient was made to sit on the bed with their hand in the supine position on the examination table.

Marking was done with the tip of an ear speculum for the no-touch technique over the central proximal phalangeal flexor crease. The target site was prepared using Savlon, spirit, and betadine. In an insulin syringe, 0.1 mL (4mg)\_methylprednisolone [Figure 2] was taken and mixed with 0.6 mL of 1% Lidocaine hydrochloride; total volume 0.7 ml. This preparation was then inserted at the target site through the combined superficial and deep flexor tendon to the central volar proximal phalanx bone; if no flow occurs, withdraw the needle almost imperceptibly about 1 mm to achieve flow into the space between the posterior flexor tendon sheath and the tendon. There is no need to confirm placement outside the tendon through the movement of the digit as in the classic method of injection into the sheath at the A1 pulley Since the flexor tendon of the thumb is less flat, it may help to grasp either side of the tendon with a clean gloved nondominant hand in the no-touch technique to insert the needle on the ulnar/palmar side of the thumb over the proximal phalanx.

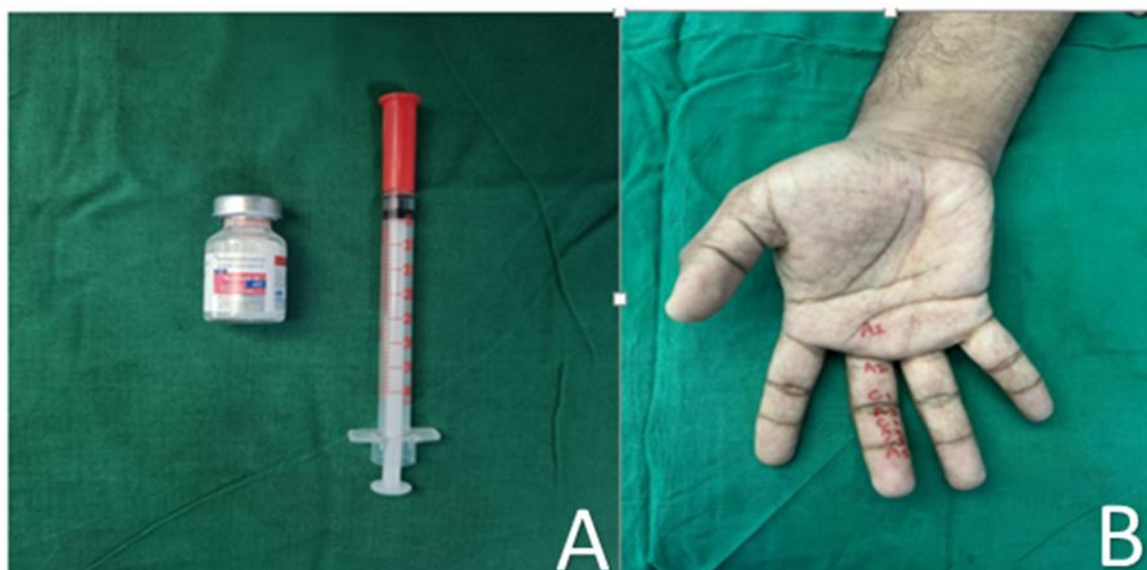

Figure 2- (A) Inj.Methylprednisolone 40mg (B) Surface marking of pulley of hand

The patients were given a set of instructions after the procedure. Buddy strapping was done to avoid the usage/ motion of the treated digit. They were advised to avoid tight grasping of any object. They were called for follow-up if there was no improvement in the symptoms.

### III. Results

#### Patient Demographics

In a total of 108 patients, there were 72 women (66.6 %), and 36 (33.3%) men with mean presentation age were 48.5 years (range, 20–88 years). Women were significantly younger than men [38.3 years (range, 27–79 years) versus 56.3 years (range, 20–88 years), 65 (60.1%) were right-handed, and 43 (39.8%) were left-handed, respectively.

#### Finger Distribution

The right long finger (18, 16.6 %) and the right thumb (26, 24 %) were the most affected [Fig 3]. Most of the patients had only one affected digit per hand. No patient presented with simultaneous ipsilateral involvement of the five digits.

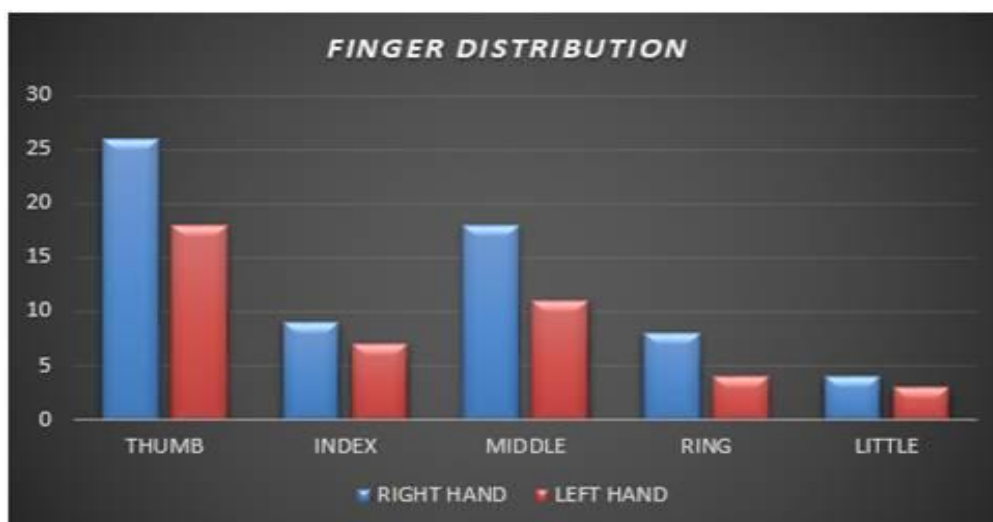


Figure 3- Distribution of trigger finger in various digits

#### Corticosteroid Injections

After the 108 initial injections, 18 TDs (16.6 %) recurred. Of those 18 recurrences, all 18 TDs were treated with a second injection. After the second injection, 6 TDs (5 %) recurred, all of which were treated with a third injection. After the third injection, two TDs (1%) had a third recurrence. This time, both patients were treated surgically; no fourth corticosteroid injection was given.

In total, 132 injections were administered, and two TDs were treated surgically. The number of injections in the same finger averaged 1.22 injections/finger for our study group.

Recurrence after the first, second, and third injections was 16.6%, 33.3, % and 33.3%, respectively, and the cumulative recurrence was 5.536 %.

In cases of recurrence, the duration of efficacy for the first, second, and third injections averaged 180 days, 120 days, and 60 days respectively. However, the efficacy of the third injection was reduced by 34 % compared to that of the first injection [Figure 4]. The duration of efficacy for steroid injection averaged 180 days in those patients with recurrence. There were two open releases performed. Fortunately, we did not encounter any major complications or wound-healing problems that would require further intervention.

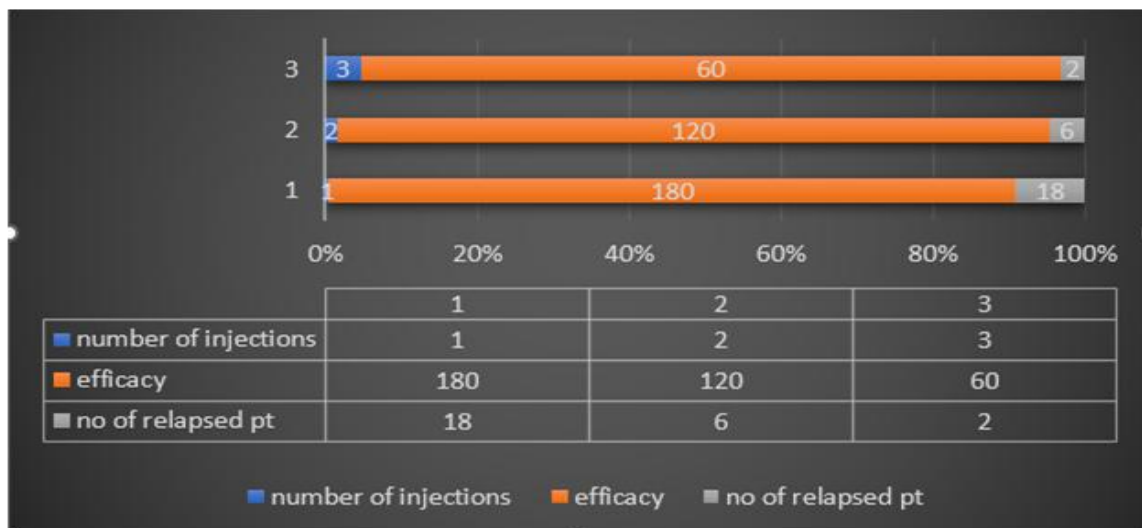


Figure 4: Graph comparing number of patients and efficacy of corticosteroid treatment on trigger finger.

#### IV. Discussion

Since the first description of corticosteroid injection therapy in TDs in 1953 [7], multiple studies have analyzed its efficacy. Investigators disagree with regard to the correlation between hand use and the development of triggering symptoms. Based on a TD prevalence of 14 % among 665 workers in a meat-packing plant, Gorsche et al. [8] claimed that intense hand tool use increased the risk of developing TD. Yet, Trezies et al. [9] found that most TDs developed for reasons other than occupation. Our finding that 91.5 % of patients were right-handed, whereas only 60.18 % of all TDs occurred on the right hand, may suggest a lack of direct correlation between hand use and triggering.

There was significant ( $p < 0.01$ ) female dominance among patients with TD (66.6%), and symptoms started significantly ( $p < 0.01$ ) earlier in women (3.8 years younger than men at symptom onset). These data are consistent with those of multiple other studies [10,11]. Nevertheless, little is known about the reasons for the increased incidence and earlier onset of TD in women; further investigations are needed.

In our study, 43 (39.8 %) patients had diabetes, which supports the association between TD and diabetes mellitus (“diabetic hand syndrome”) reported in the literature, with percentages of 7 to 22 % [12,13]. Patients with diabetes and other comorbidities [Figure 5] remain a treatment challenge because of the increased risks of side effects of steroid injection and surgery, such as elevated blood glucose levels and wound-healing problems.

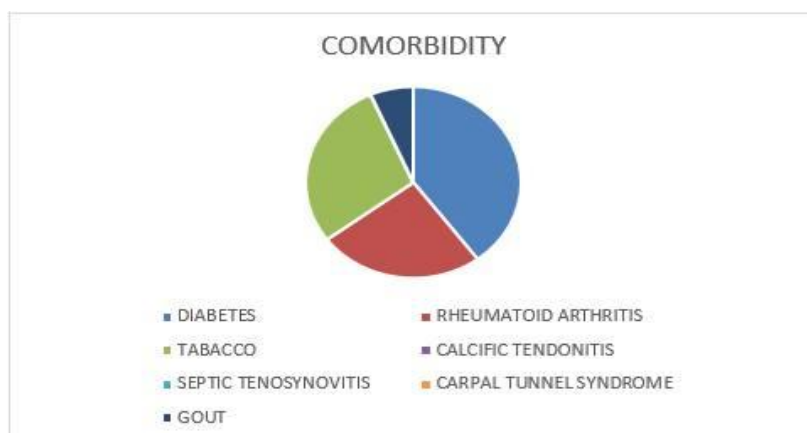


Figure 5: Pie chart demonstrating the comorbidities associated with trigger finger in our patients.

In our study, the efficacy of the total injection therapy regimen was 98.14 %. Only 1.85 % of patients required an open surgical release. Symptoms resolved with one injection in 83.33 % of TDs; 16.77 % required additional intervention. Both values are within the ranges reported in the literature [14, 15], underlining the potent efficacy of this therapy. We found that if there was a recurrence, the efficacy of the first injection averaged 180 days.

We did observe the drastic diminishing effectiveness of multiple steroid injections as has been described in the literature [12, 16]; we noted the major reduction in the duration of efficacy. Two studies reported the maximum duration as six weeks [16] and 12 months [17]. Our maximum duration was more than six months. In our series, the dose of 4 mg was injected into the tendon sheath only by the senior author.

In our study, we set the recurrence date as the office visit for a repeat injection or for scheduling surgery. Although the symptoms of recurrence may have existed before the office visit, selecting this date eliminated the uncertainty of how long before the visit the symptoms recurred. What may be a few weeks to the patient may actually have been a few months or a few days. Although this definition and method do lengthen the duration of “efficacy,” we were unable to find another solution to this dilemma because some of the patients could no longer be contacted or, if they could, had difficulty recalling exactly when their recurrence was (in some cases, ten years previously).

## V. Conclusion

Our data confirm that TDs affect women more often than men and at a younger age. There seems to be no distinct correlation between hand dominance and the appearance of TDs. Treatment with a corticosteroid injection therapy regimen appears to be safe and highly effective (symptom resolution in 98.14 %). Even patients with symptomatic recurrence benefited from corticosteroid injection, with an average injection efficiency duration of 120 days.

## References

- [1]. Trigger finger: etiology, evaluation, and treatment. Makkouk AH, Oetgen ME, Swigart CR, Dodds SD. *Curr Rev Musculoskelet Med.* 2008;1:92–96.
- [2]. Flexor tendon entrapment of the digits (trigger finger and trigger thumb) Moore JS. *J Occup Environ Med.* 2000;42:526–545.
- [3]. Outcome of trigger finger treatment in diabetes. Stahl S, Kanter Y, Karnielli E. *J Diabetes Complicat.* 1997;11:287–290.
- [4]. Trigger finger in diabetes. Strom L. <https://pubmed.ncbi.nlm.nih.gov/269967/> *J Med Soc N J.* 1977;74:951–954.
- [5]. Bunnell S. *Surgery of the Hand.* Philadelphia, PA: JB Lippincott Co.; 1944. Injuries of the hand.
- [6]. Treatment of trigger finger: randomized clinical trial comparing the methods of corticosteroid injection, percutaneous release and open surgery. Sato ES, dos Santos JB, Belloti JC, Albertoni WM, Faloppa F. *Rheumatology (Oxford)* 2012;51:93–99.
- [7]. Gorsche R, Wiley JP, Renger R, et al. Prevalence and incidence of stenosing flexor tenosynovitis (trigger finger) in a meat-packing plant. *J Occup Environ Med.* 1998;40:556–560.
- [8]. Howard LD, Jr, Pratt DR, Bunnell S. The use of compound F (hydrocortone) in operative and non-operative conditions of the hand. *J Bone Joint Surg Am.* 1953;35:994–1002.
- [9]. Trezies AJ, Lyons AR, Fielding K, et al. Is occupation an aetiological factor in the development of trigger finger? *J Hand Surg Br.* 1998;23:539–540.
- [10]. Fahey JJ, Bollinger JA. Trigger-finger in adults and children. *J Bone Joint Surg Am.* 1954;36:1200–1218.
- [11]. Fleisch SB, Spindler KP, Lee DH. Corticosteroid injections in the treatment of trigger finger: a level I and II systematic review. *J Am AcadOrthop Surg.* 2007;15:166–171.
- [12]. Newport ML, Lane LB, Stuchin SA. Treatment of trigger finger by steroid injection. *J Hand Surg Am.* 1990;15:748–750.
- [13]. Nimigan AS, Ross DC, Gan BS. Steroid injections in the management of trigger fingers. *Am J Phys Med Rehabil.* 2006;85:36–43.
- [14]. Marks MR, Gunther SF. Efficacy of cortisone injection in treatment of trigger fingers and thumbs. *J Hand Surg Am.* 1989;14:722–727.
- [15]. Saldana MJ. Trigger digits: diagnosis and treatment. *J Am AcadOrthop Surg.* 2001;9:246–252.
- [16]. Ring D, Lozano-Calderon S, Shin R, et al. A prospective randomized controlled trial of injection of dexamethasone versus triamcinolone for idiopathic trigger finger. *J Hand Surg Am.* 2008;33:516–522.
- [17]. Peters-Veluthamaningal C, Winters JC, Groenier KH, et al. Corticosteroid injections effective for trigger finger in adults in general practice: a double-blinded randomised placebo controlled trial. *Ann Rheum Dis.* 2008;67:1262–1266.

Dr. Vishwas, et. al. “Assessment of Corticosteroid Response for Trigger Finger: A Single Tertiary Centre Experience.” *IOSR Journal of Dental and Medical Sciences (IOSR-JDMS)*, 21(10), 2022, pp. 12-16.