

“Study of profile of patients with right ventricular infarction with diagnosed acute inferior wall myocardial infarction”

Dr Salam Kenny Singh¹, Dr Phrang Kupar Swer² Dr Lalmuankima Tlau³ Dr Ferdinand Mynthlu⁴ Dr Sarath Chandran KR⁵ Dr Mustaqueem Phusam⁶ Dr Lalrinchhani Fanai⁷

¹(Associate professor, Department of Medicine, Regional Institute of Medical Science, RIMS, Imphal, India)

²(Former Resident, Department of Medicine, RIMS, Imphal, India)

^{3,4,5,6,7}(Junior Resident, Department of Medicine, RIMS, Imphal, India)

Corresponding author: Dr Lalmuankima Tlau

Abstract

Background: Right ventricular myocardial infarction (RVMI) which was considered just a pathological entity is now known to be commonly seen with Inferior wall myocardial infarction (IWMI) primarily from occlusion of the right coronary artery and left anterior descending artery.

Aims: To document the profile of patients with RVMI with diagnosed Acute IWMI and to study its Electrocardiography (ECG) manifestations in correlation with clinical and echocardiographic findings

Materials and Methods: Cross-sectional study carried out for a period of two years from September 2019 to August 2021 in Regional Institute of Medical Sciences (RIMS), Imphal

Results: Total of 65 patients with Male: Female ratio 1.6: 1. Median age was 61. Almost half were smokers and 44.6% had either hypertension or dyslipidaemia. 12.3% had family history of ischemic heart disease and 27.7% were diabetic under medication. Patients with RVMI had more chance of hypotension, raised JVP, pedal oedema and positive Kussmaul's sign

Conclusion: It is concluded that IWMI with RVMI was associated with more severe complications.

Keyword: acute coronary syndrome, inferior wall myocardial infarction, right wall myocardial infarction

Date of Submission: 26-09-2022

Date of Acceptance: 11-10-2022

I. Introduction

Acute myocardial infarction (AMI) is a serious complication of atherosclerotic coronary artery disease with commonest diagnosis presenting with chest pain and associated with a mortality of approximately 25%¹. AMI was earlier thought to be mainly a disease of left ventricle (LV), isolated infarction of right ventricle (RV) was considered rare. However later studies suggest that RVMI is commonly seen in more than one third of cases with IWMI. It results primarily from occlusion of the right coronary artery and infrequently from involvement of the left anterior descending artery^{2, 3}. It is important to recognize RVMI in patients presenting with IWMI because management of differs substantially from the management of left ventricular myocardial infarction(LVMI)⁴. RVMI which is clinically significant causes signs of severe right ventricular failure, jugular venous distention, Kussmaul's sign, hepatomegaly with or without hypotension⁵. ST-segment elevations in right-sided precordial ECG leads, particularly in lead VR4 are frequently present in the first 24 hour in patients with right ventricular infarction. The degree of right ventricular dysfunction assessed by using two-dimensional echocardiography (2D Echo) is found to be helpful. This study aims to document the profile of patients with RVMI with diagnosed acute IWMI; to study its ECG manifestations in correlation with clinical and echocardiographic findings

II. Methods And Objectives

It is a Cross-sectional study which was carried out for a period of two years from September 2019 to August 2021 in Department of Medicine, RIMS, Imphal. The study population included all patients diagnosed as STEMI according to WHO criteria and joint ESC/ACCF/AHA/WHF committee guidelines⁶. Patients with history of previous myocardial infarction, patients with associated anterior and lateral wall MI, proved by ST elevation in anterior and lateral leads in ECG⁷, history of chronic lung disease or associated pericardial disease were excluded. Detailed history, clinical examinations, Chest X-ray, 12 conventional leads ECG with 4 Right-

Sided Leads ECG, 2D Echo and haematological profiles including CK-MB and Trop-I was done. Data was analysed using IBM SPSS statistics version 21 summarized using descriptive statistics like percentages, means (standard deviation) and median. Inferential statistics like Chi-square test (for categorical data), Student’s t test (for quantitative data with normal distribution) were used. A probability value of < 0.05 was taken as significant

III. Results

This study included 65 patients with Male: Female 1.6: 1. Median age was 61. Age distribution varied from 23 years to 85 years with majority above 60 years (52.3%). Majority of the patients (83,1%) have normal BMI (18.5-24.9), 16.9% was overweight but no obese patients. 31 patients (47.7%) were smokers and 29 patients (44.6%) had either hypertension, dyslipidaemia or both, only 4 patients (6.2%) were alcoholics. 8 patients (12.3%) had family history of ischemic heart disease and 18 patients (27.7%) were diabetic under medication.

In both groups, i.e. isolated IWMI or IWMI with RVMI most common finding following AMI was pedal oedema (38.5%) followed by hypotension (30.8%). Hypotension was significantly ($p < 0.05$) more in IWMI with RVMI than those with isolated IWMI (57% vs 18.2%). Bradycardia was more with RVMI (33.3% vs 6.8%) while tachycardia was observed only in isolated IWMI. Patients with RVMI had more chance of hypotension, raised JVP, pedal oedema and positive Kussmaul’s sign

Table 1: Demographics of Sample Population

| Age in years | Frequency | Percentage |
|--------------|-----------|------------|
| 20-30 | 2 | 3.2 |
| 31-40 | 1 | 1.5 |
| 41-50 | 6 | 9.2 |
| 51-60 | 22 | 33.8 |
| >60 | 34 | 52.3 |

| | | |
|-----------|------------|------------|
| Median | 61 (23-85) | |
| Sex | Frequency | Percentage |
| Male | 40 | 61.5 |
| Female | 25 | 38.5 |
| Total | 65 | |
| BMI | Frequency | Percentage |
| <18.5 | 0 | 0 |
| 18.5-24.9 | 54 | 83.1 |
| 25-29.9 | 11 | 16.9 |
| >30 | 0 | 0 |

Table 2: Distribution of the respondents by presenting complain

| Presenting complain | Frequency | Percentage |
|---------------------|-----------|------------|
| Typical Angina | | |
| Chest Pain | 51 | 78.5 |
| Angina Equivalents | | |
| Breathlessness | 3 | 4.6 |
| Palpitations | 3 | 4.6 |
| Presyncope/Syncope | 2 | 3.1 |
| Nausea/Vomiting | 6 | 9.2 |
| Total | 65 | |

Table 3: Relation between risk factors and presence of RVMI

| Risk factors | With RVMI n (%) | Isolated IWMI n (%) | Total n(%) | Chi-square test/fisher exact test* |
|-----------------------|-----------------|---------------------|------------|------------------------------------|
| Hypertension | 9(42.9) | 20(45.5) | 29(44.6) | Value=0.039 p-0.844 |
| Diabetes | 10(47.6) | 8(18.2) | 18(27.7) | Value=6.152 p-0.013 |
| Smoker | 9(42.9) | 22(50.0) | 31(47.7) | Value=0.291 p-0.590 |
| Alcoholic | 1(4.8) | 3(6.8) | 4(6.2) | Value=0.291 p-1.000 |
| Overweight | 4(19.0) | 7(15.9) | 11(16.9) | Value=0.100 p-0.752 |
| Dyslipidemia | 13(61.9) | 16(36.4) | 29(44.6) | Value=3.75 p-0.053 |
| Family History of IHD | 2(9.5) | 6(13.6) | 8(12.3) | Value=0.223 p-0.637 |
| Total | 21 | 44 | 65 | |

Table 4: Distribution of patients with greater ST elevation in standard Lead III than in Lead II in right precordial lead ECG amongst subjects with RVMI

| ST Elevation in Lead III>Lead II | Frequency | Percentage |
|----------------------------------|-----------|------------|
| VR4 | 14 | 82.4 |
| VR3 | 3 | 17.6 |
| Total | 17 | 100 |

Greater ST elevation in standard Lead III than in Lead II was more in right precordial lead ECG VR4 than inVR3

Diagram 1: Examination findings and presence of RVMI

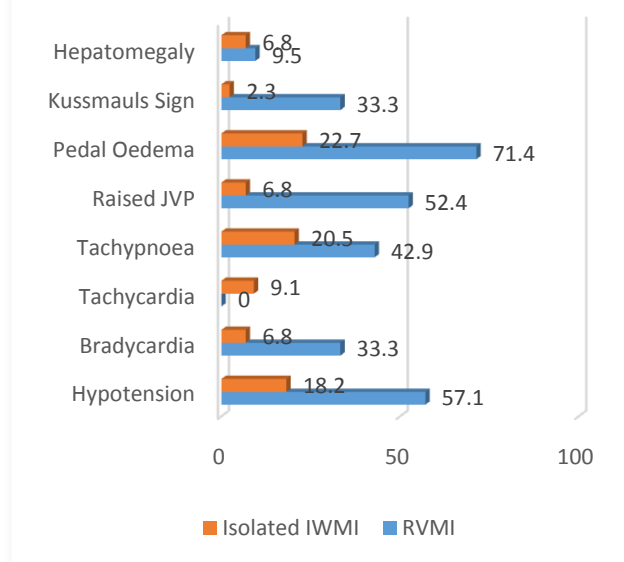


Table 5: Relation between greater ST elevation in standard Lead III than in Lead II and presence of RVMI

| ECG Finding | With RVMI | Isolated IWMI | Total | Fischer Exact test |
|-----------------------------|------------|---------------|-----------|------------------------|
| ST Elevation in Lead III>II | 17 (89.5%) | 2 (10.5%) | 19(29.2%) | Value = 40.118 p=0.000 |

Greater ST elevation in standard Lead III than in Lead II was seen in 29.2% of total cases out of which 89.5% was seen in subject with RVMI and found to be statistically significant.

Table 6: Relation between Two dimensional Echocardiography findings with presence of RVMI

| Echo Findings | With RVMI n(%) /mean+SD | Isolated IWMI n(%) /mean+SD | Total n(%) | Chi square test/Fisher exact test |
|-------------------------|----------------------------|--------------------------------|------------|-----------------------------------|
| RVEDD | | | | Value=52.220 p=0.00 |
| >25mm | 20(95.2) | 2(4.5) | 22(33.3) | |
| <25mm | 1(4.8) | 42(95.5) | 43(66.2) | |
| RVEDD/LVEDD ratio | | | | Value = 40.857 p=0.000 |
| <0.7 | 6(28.6) | 44(100) | 50(76.9) | |
| >0.7 | 15(71.4) | 0(0) | 15(23.1) | |
| RWMA | 10(47.6) | 8(18.2) | 18(27.7) | Value+=6.152 p=0.013 |
| LVEF (%) | 44.8+4.69 | 52.86+3.74 | -8 | Value=7.465 p=0.000 |
| LV Systolic Dysfunction | | | | Value=9.307 p=0.0014 |
| Mild | 12(57.1) | 28(63.6) | 40(61.5) | |
| Moderate | 9(42.9) | 1(2.3) | 10(15.4) | |
| Normal | 0(0) | 15(34.1) | 15(23.1) | |
| Total | 21(100) | 44(100) | 65(100) | |

RVEDD >25mm and RVEDD/LVEDD ratio >0.7 was more with RVMI and this finding was statistically significant (p=0.05). Regional wall motion abnormality (RWMA) was seen in 47.6% of subjects with RVMI against 18.2% of subjects with Isolated IWMI but not significant. Left ventricular ejection fraction (LVEF) was lower in cases with RVMI and this finding was statistically significant

IV. Discussion:

In this study IWMI with RVMI was found in 32.3% of cases. The finding was consistent with the study by Croft CH et al⁸ and Azhar M et al⁹ based on ECG evidence of ST-Segment elevation in VR4 and was prevalent in around one third of IWMA patients. Those patients with associated RVMI were bit younger and male predominance was seen in both the groups in equal proportion. All the patients reported within 24 hours of onset of symptoms; typical angina was the most common clinical presentation in around four fifth of the total patients. Among the risk factors of IWMI, diabetes was the most important risk significantly associated with RVMI. There was increased chance of hypotension and raised JVP and Kussmaul’s sign, which were signs of severe right ventricular failure which was significantly associated in patients with RVMI, consistent with studies of Siddeswari R et al¹⁰ and George S et al¹¹. All types of heart blocks were found in IWMI with RVMI. Those patients with associated RVMI had more chance of ECG findings of ST elevation in Lead III>II. On 2D Echocardiography, Right Ventricular End Diastolic Diameter(RVEDD)>25mm was more prevalent among patients associated with RV involvement. And also, RVEDD/LVEDD ratio >0.7 was only seen among patients with right ventricular wall involvement. Moreover, Left Ventricular Ejection Fraction (LVEF) was also lower in cases with right ventricular wall involvement. They were also more likely to have LV systolic dysfunction. Regarding mortality; though frequency were less; it was more among IWMI associated RVMI patients.

V. Conclusions:

It is concluded that IWMI with RVMI was associated with more severe complications. This is the first of its kind study in RIMS, Manipur. Further studies with a bigger sample size are recommended to reveal the true picture of RVMI associated IWMI.

Reference:

- [1]. Alexander RW, Craig MP, Thomas JR, Robert R. ST segment elevation myocardial infarction. In: Fuster V, Alexander RW, Robert A, Rourke O, editors. Hurst’s The Heart. 11th ed. New York: McGraw Hill; 2004. p. 1277-350.
- [2]. Iqbal A, Muddarangappa R, Shah SKD, Vidyasagar S. A study of right ventricular infarction in inferior wall myocardial infarction. J Clin Sci Res 2013; 2:66-71.
- [3]. Chhapra DA, Mahajan SK, Thorat ST. A study of the clinical profile of right ventricular infarction in context to inferior wall myocardial infarction in a tertiary care centre. J Cardiovasc Dis Res 2013; 4(3):170-6.
- [4]. Kakouros N, Cokkinos DV. Right ventricular myocardial infarction: pathophysiology, diagnosis and management. Postgrad Med J 2010; 86(1022):719- 28.
- [5]. Menown IB, Allen J, Anderson JM, Adgey AA. Early diagnosis of right ventricular or posterior infarction associated with inferior wall left ventricular acute myocardial infarction. Am J Cardiol 2000; 85(8):934-8.

- [6]. Antman E, Bassand JP, Klein W, Ohman M, Lopez SJL, Ryden L, et al. Myocardial infarction redefined-a consensus document of the Joint European Society of Cardiology/American College of Cardiology Committee for the redefinition of Myocardial infarction. *J Am Coll Cardiol* 2000; 36(3):959-69.
- [7]. Schamroth L, Schamroth C. Myocardial infarction. In: Schamroth C, editor. *An introduction to electrocardiography*. 7th ed. Oxford: Blackwell Science; 2003. p. 150-3.
- [8]. Croft CH, Nicod F, Corbett JR, Lewis SE, Huxley R, Mukharji J, et al. Detection of acute right ventricular infarction by right Precordial electrocardiography. *Am J Cardiol* 1982;50(3):421-7
- [9]. Azhar M, Salim S, Karim S, Zubair M. Right ventricular infarction incidence and outcome. *Pak Heart J* 1993; 26(3-4):36-9.
- [10]. Siddeswari R, Kumar PS, Reddy T, Manohar S. Clinical Profile of Right Ventricular Infarction. *Int J Sci Res Publ* 2015 Apr; 5(4):96-102.
- [11]. George S, Patel M, Thakkar A. Clinical Profile and In-Hospital Outcome of Patients with Right Ventricular Myocardial Infarction. *Int J Clin Med* 2014; 5:459- 63.

Dr Salam Kenny Singh, et. al. “Study of profile of patients with right ventricular infarction with diagnosed acute inferior wall myocardial infarction.” *IOSR Journal of Dental and Medical Sciences (IOSR-JDMS)*, 21(10), 2022, pp. 21-25.