

## “Evaluation of Maxillary Sinus Mucosal Thickening and Periapical Radiolucency Associated With Maxillary Posteriors Using CBCT”

Dr Ameena M S<sup>1</sup>, Dr Sunu Ramachandran<sup>2</sup>

<sup>1</sup>(Department of Oral Medicine and Radiology, Government dental college, Thiruvananthapuram, Kerala, India)

<sup>2</sup>(Department of Oral Medicine and Radiology, Government dental college Thiruvananthapuram, Kerala, India)

---

### **Abstract:**

**Background:** Periapical inflammation is often responsible for distinct maxillary sinus changes. This study evaluated the association between the clinical characteristics of periapical lesions in maxillary premolar and molar teeth and the presence of maxillary sinus mucosal thickening by evaluating cone beam computed tomography (CBCT) images.

**Materials and Methods:** In this retrospective study, CBCT images of 75 patients with 100 exposed maxillary sinuses were inspected. The relationship of each tooth root with apical lesions and maxillary sinus and effect of these conditions on sinus mucosal thickness (MT) was evaluated. Spearman's Rank Correlation test was used to assess the correlation between the ordinal variables. The association between the parameters were assessed using Chi-Square Test. The inter-examiner reproducibility was determined using Kappa Statistics.  $p$  value  $< 0.05$  was considered statistically significant.

**Results:** Spearman rank correlation coefficient obtained was 0.774. It indicate a strong positive correlation between mucosal thickening (MT) of maxillary sinus and periapical lesions of maxillary posteriors. The prevalence of maxillary sinus mucosal thickening increased dramatically as the severity of periapical lesions increased. Older individuals had the highest prevalence of maxillary sinus mucosal thickening.

**Key Word:** Maxillary sinus mucosal thickening, periapical radiolucency, CBCT.

---

Date of Submission: 18-09-2022

Date of Acceptance: 03-10-2022

---

### **I. Introduction**

Maxillary sinuses are pneumatic cavities within maxillary bone that communicate with the nasal cavity by ostium.<sup>1</sup> The sinus is lined with a thin respiratory mucous membrane referred as the Schneiderian membrane which adheres to the periosteum and is about 1 mm thick, normally not visible on a radiograph.<sup>2,3</sup> Although, when the mucosa comes to be irritated from either an infectious or allergic process, it may increase and may be seen on radiograph. Mucosal thickness (MT) greater than 3 mm is most likely pathological.<sup>4</sup> The radiographic image of thickened mucosa is a non-corticated radiopaque band, paralleling the bony wall of the sinus. Maxillary sinus is very closely linked to the alveolar crest and in some cases the floor can be perforated by the apices of the teeth. This close anatomic proximity of root apices to the maxillary sinuses makes dental disease, especially periapical lesion, a potential source for the spread of the disease into the maxillary sinuses.<sup>5</sup> In addition, the close relationship between the maxillary sinus floor and the roots of molars and premolars can lead to accidental oroantral communication.<sup>6,7</sup> It is essential for clinicians to be aware of the exact relationship between the apical roots of the maxillary teeth and the maxillary sinus floor. Cone beam computed tomography (CBCT) has raised the interest in revisiting the anatomical features of the jaws. It provides an accurate evaluation of maxillary bone quality and quantity around posterior root apices without the distortion and superimposition caused by teeth and the surrounding structures.<sup>8,9</sup> Periapical and periodontal lesions are the most commonly encountered abnormalities in dental practice and have a profound influence on the thickness of the maxillary sinus mucosa. Increased thickness of sinus mucosa is found to be associated with periapical and periodontal pathologies affecting maxillary posterior teeth. The significance of assessing the mucosal thickening becomes important while planning procedures like sinus augmentation. CBCT is the preferred modality for maxillary sinus imaging as it has several advantages over traditional CT such as lower radiation dose and higher image resolution. Only a very few studies have reported the correlation between maxillary sinus mucosal thickening and periapical pathologies affecting maxillary posterior teeth. Thus the present study was conducted to evaluate the correlation between periapical radiolucency and sinus mucosal thickening using CBCT.

## II. Material And Methods

This Observational Analytical study was conducted in the Radiology wing, Department of Oral Medicine and Radiology, GDC, Trivandrum during 3 months (1/9/2019 to 30/11/2019). Maxillary posterior CBCT images of patients, taken as a part of their diagnosis and treatment planning with at least one maxillary sinus exposed were enrolled into the study.

**Study Design:** Observational analytical study

**Study Location:** This was a tertiary care teaching hospital based study done in Department of Oral Medicine And Radiology, GDC ,Trivandrum.

**Study Duration:** 3 months (1/9/2019 to 30/11/2019).

**Sample size:** 100

**Sample size calculation:** Sample size calculation was done using formulae  $N = \left[ \frac{Z\alpha + Z\beta\sqrt{1-r^2}}{r} \right]^2 + 2$  (Where, N= number of images required,  $\alpha$ = Type I Error, For an  $\alpha$  of 5%,  $Z\alpha = 1.96$  ,  $\beta$  = Type II Error,  $Z\beta = 0.84$  for a power of 80% ,  $r$  = Expected correlation coefficient, taken as 0.17).

**Subjects & selection method:** Maxillary posterior CBCT images , taken as a part of diagnosis and treatment planning with at least one maxillary sinus were enrolled into the study. Ethical clearance from the ethical committee of the institution (Ethical clearance No:IEC/E/26/2019/GDCT Dated 12.11.2019) was obtained before starting the study.

**Inclusion criteria:**

1. Presence of atleast oneof the premolars or molars in each left or right side (fully erupted teeth and fully formed apices)

**Exclusion criteria:**

1.CBCT images of Patients with a history of trauma,developmental abnormality & surgery related to maxillary sinus  
2.CBCT images of poor quality

**Procedure methodology**

The study was conducted in maxillary posterior CBCT images of patients taken as a part of diagnosis and treatment planning during the study period. Every consecutive CBCT image satisfying the inclusion criteria was recruited for study.

The images were acquired using the Planmeca promax 3D CBCT imaging system with a 12-bit sensor and 4096 gray values. The images were captured with varying exposure parameters depending upon the chosen FOV using a flat panel detector. A single 360 degree scan was used. Primary reconstruction of the data using with a voxel size of 0.15mm was performed, exported as DICOM data sets and then loaded in the Planmeca Romexis imaging software. The sagittal, coronal and axial sections were reconstructed from the projection data. The contrast and brightness of the images were adjusted using the image processing tool in the software to ensure optimal visualization. Patient's age, gender, tooth position, periapical lesions of posterior teeth and mucosal thickening (MT) of maxillary sinus were noted and recorded. Mucosal thickness was measured at the point of maximum thickness from the sinus floor. The diameter of the periapical lesion was measured at the maximum range. Imaging Characteristics of periapical lesions were assessed by **CBCT Periapical Index by Estrela et al, 2008.**

**CBCT periapical index**

- Score 0 –Intact periapical bone structures
- Score 1 –Diameter of periapical radiolucency>0.5-1mm
- Score 2 –Diameter of periapical radiolucency>1-2mm
- Score 3 –Diameter of periapical radiolucency>2-4mm
- Score 4 –Diameter of periapical radiolucency>4-8mm
- Score 5 –Diameter of periapical radiolucency>8mm

Score(n)+E- Expansion of periapical cortical bone

Score(n)+D-Destruction of periapical cortical bone

**Evaluation of Sinus Mucosal Thickness (MT)**

MT in the maxillary sinus floor was evaluated from the cross-sectional, coronal and tangential views. In each sinus, mucosal thickness was measured in the point of maximum thickness from the sinus floor over all the teeth apices. MT was considered to be present when the thickness is more than 1mm.

The amount of MT is classified into five classes (According to *Lu Y et al,2012*)

1. Class 1- Normal (no mucosal thickness)
2. Class 2 - 0-2 mm
3. Class 3 – 2 -4 mm
4. Class 4 – 4-10 mm
5. Class 5 - >10 mm<sup>4</sup>

**Statistical analysis**

Statistical analysis was done using **SPSS 16** for windows. All the data was first analysed descriptively .The values obtained were tabulated. Descriptive statistics like mean and standard deviation were calculated for continuous variables and proportion was calculated for Categorical variables. The association between the parameters was calculated using Chi-Square Test. Spearman’s Rank Correlation test was used to assess the correlation between the variables. The inter-examiner reproducibility was determined using Kappa Statistics. p<0.05 was considered as statistically significant.

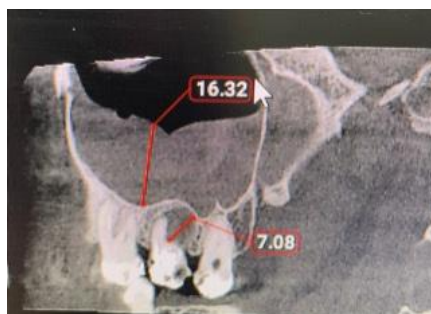**III. Result**

CBCT images of 100 exposed maxillary sinuses(66 Right side and 34 left side) and 181 teeth(35 first premolars,39 second premolars,77 first molars,30 second molars) of 100 individuals(65 images of males \$ 35 images of females),aged between 15 to 79(mean age=42.7±15.5) were examined. Among the 100 images, 47% shows maxillary sinus mucosal thickening score ≥3(MT≥2mm) of which 88.9% show CBCT Periapical index score≥2 (Table 1, figure 1). Correlation between maxillary sinus mucosal thickening and periapical radiolucency in relation to maxillary posterior teeth was estimated using spearman rank correlation. Spearman rank correlation coefficient obtained was 0.774.It indicates a strong positive correlation between maxillary sinus mucosal thickening and periapical pathology and it is statistically significant (Figure 2).

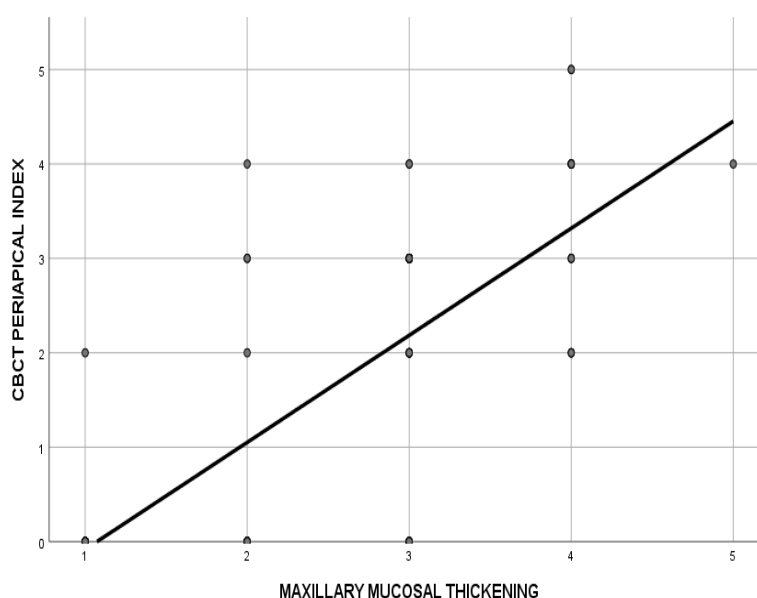
**Table no 1:** Shows Correlation between maxillary sinus mucosal thickening and CBCT Periapical Index Score

CBCT PERIAPICAL INDEX SCORE	MAXILLARY SINUS MUCOSAL THICKENING				Total		$\chi^2$	df	p
	≥3		<3		n	%			
	n	%	n	%					
≥2	40	88.9	5	11.1	45	100	57.633	1	<0.001
<2	7	12.7	48	87.3	55	100			
Total	47	47	53	53	100	100			

**Figure No 1:** CBCT image of maxillary posterior teeth with CBCT Periapical index score 5 and Sinus thickening of class 5



**Figure No 2:** Shows Correlation between maxillary sinus mucosal thickening and periapical radiolucency.



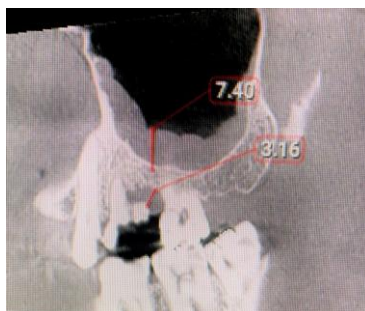Among 181 examined teeth, 53% (96) of them presented with no maxillary sinusitis, no mucosal thickness or uniform mucosal thickness < 2 mm (MT class 1, 2) detected on the images, in either the left or right maxillary sinus. MT was observed in 46.96% (85) of teeth in which 19.9% were first premolars, 22.2% were second premolars, 42.2% were first molars and 15.27% were second molars (Table 2). Maxillary right first molars (25.8%) were more associated with sinus mucosal thickening (MT ≥ 2mm) (figure 3).

**Table No 2:** Shows association between sinus mucosal thickening and maxillary posterior teeth (except 3<sup>rd</sup> molar).

Teeth number	MAXILLARY SINUS MUCOSAL THICKENING				Total		$\chi^2$	df	p
	≥3		<3		n	%			
	n	%	n	%					
14	9	10.5	8	8.3	17	9.3	7.023	7	0.04
15	9	10.5	9	9.3	18	9.9			
16	22	25.8	30	31.25	52	28.7			
17	6	7.05	9	9.3	15	8.2			
24	8	9.4	10	10.4	18	9.9			
25	10	11.7	11	11.4	21	11.6			

26	14	16.4	11	11.4	25	13.8			
27	7	8.2	8	8.3	15	8.2			
Total	85	100	96	100	181	100			

**Figure No 3:** CBCT image of Maxillary right first molar with CBCT periapical index score 4 with sinus thickening of Class 4

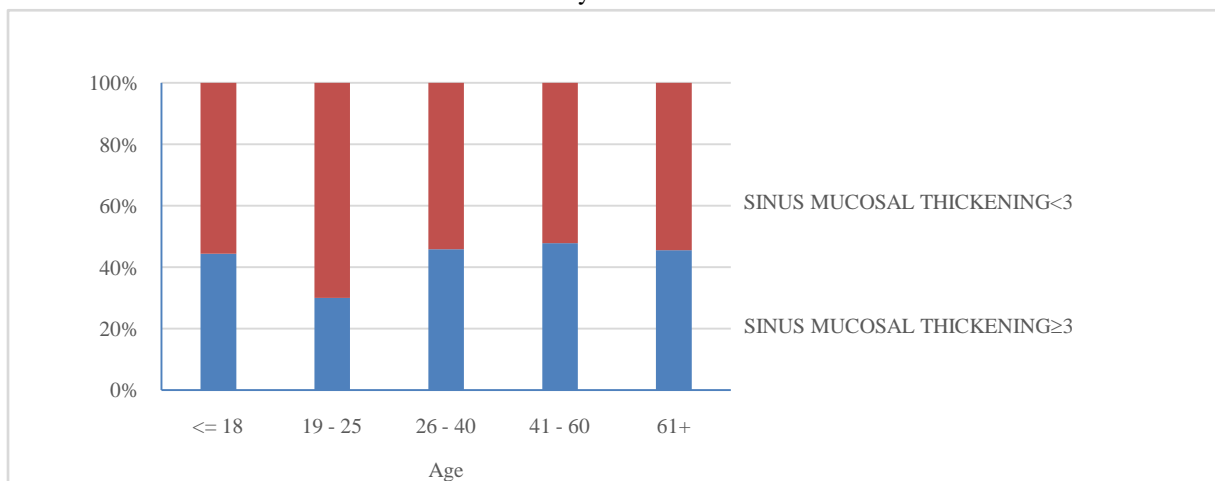


Among the 100 images examined, maxillary sinus mucosal thickness score  $\geq 3$  was observed in 8.5% among the juvenile patients ( $\leq 18$  years), 6.3% among the young patients (19-25 years), 23.4% among the adults (26-40 years), 48.9% among the patients aged between 41 to 60 years, and 12.7% among geriatric patients ( $>60$  years). (Table 3). The maxillary sinus mucosal thickness was mostly associated with patient age between 41 to 60 years (48.9%) (figure 4).

**Table No 3:** Shows association between maxillary sinus mucosal thickening and age.

Age	SINUS MUCOSAL THICKNESS				Total		$\chi^2$	df	p
	$\geq 3$		$< 3$		n	%			
	n	%	n	%					
$\leq 18$	4	8.5	5	9.4	9	100.0	1.066	4	0.04
19 - 25	3	6.3	7	13.2	10	100.0			
26 - 40	11	23.4	13	24.5	24	100.0			
41 - 60	23	48.9	23	43.3	46	100.0			
61+	6	12.7	6	11.3	11	100.0			
Total	47	47.0	53	53.0	100	100.0			

**Figure No 4:** Shows maxillary sinus mucosal thickening was more associated with patient age between 41 to 60 years

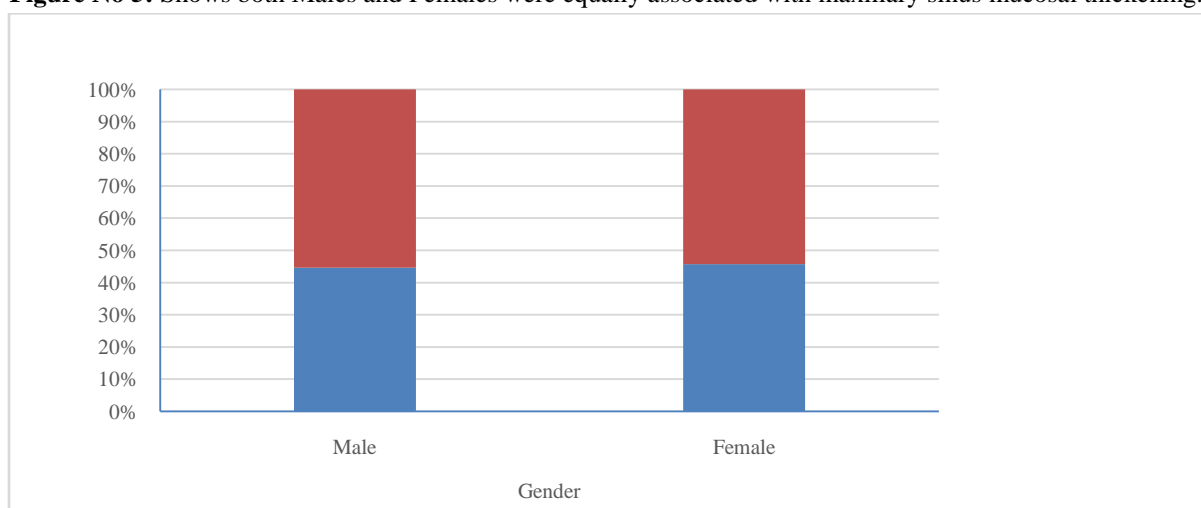


In this study it was assessed that 44.6% males and 45.7% females shows sinus mucosal thickening score  $\geq 3$  (MT  $\geq 2.1$ mm) which signifies that there is no association between gender and maxillary sinus mucosal thickening (figure 6). Both males and females were almost equally associated with maxillary sinus mucosal thickening. p value calculated as 0.9 which was not statistically significant (Table 4, Figure 5).

**Table No 4:** Shows association between Gender & Maxillary sinus mucosal thickening.

Gender	SINUS MUCOSAL THICKNESS				Total		$\chi^2$	df	p
	$\geq 3$		$< 3$		n	%			
	n	%	n	%					
Male	29	44.6	36	55.4	65	100.0	.011	1	.916
Female	16	45.7	19	54.3	35	100.0			
Total	45	45.0	55	55.0	100	100.0			

**Figure No 5:** Shows both Males and Females were equally associated with maxillary sinus mucosal thickening.

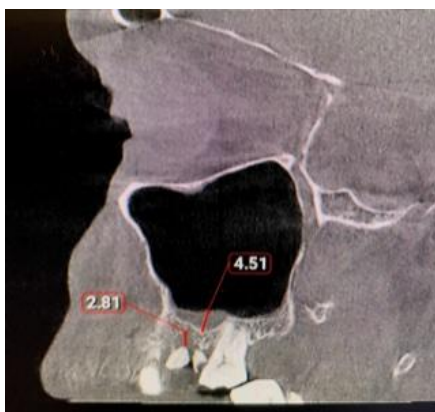


Among the CBCT images, 54.1% right side maxillary posterior teeth and 45.8% left side maxillary posterior teeth shows a sinus mucosal thickness  $\geq 2$ mm which signifies maxillary sinus mucosal thickening is mostly associated with maxillary posterior teeth on the right side (Table 5, Figure 6).

**Table No 5:** Shows association between right & left side with maxillary sinus mucosal thickening.

Side	MAXILLARY MUCOSAL THICKENING				Total		$\chi^2$	df	p
	$\geq 3$		$< 3$		n	%			
	n	%	n	%					
Right	46	54.1	56	58.3	102	100.0	1.632	1	0.034
Left	39	45.8	40	41.6	79	100.0			
Total	85	100	96	100	181	100.0			

**Figure No 6:** CBCT image of Maxillary right first molar with CBCT Periapical Index Score 3 and sinus mucosal thickening of Class 4.



#### IV. Discussion

The present study attempted to clarify the possible correlation between maxillary sinus mucosal thickening and periapical radiolucency of maxillary posterior teeth. CBCT is a technological invention without superimposition seen in conventional radiographic techniques. Anatomic structures are seen in clearer detail with the CBCT scanning. CBCT imaging was helpful in evaluating the preoperative and postoperative conditions of the maxillary sinuses. It was also helpful in explaining the etiology and extent of the association between the dental pathology and the involved sinus<sup>10,13,14</sup>. The normal maxillary sinus MT is about 1 mm and homogenous thickness up to 2 mm is non pathogenic. If mucosal thickness of  $>2$  mm was evaluated as indication of MT.<sup>15</sup> The prevalence of MT may change in accordance with the demarcation of normal MT. Phothikhun *et al.*<sup>16</sup> defined the MT when it was  $>1$  mm and found MT in 42% of patients. In his study it was seen that periapical infection of maxillary first molar tooth is mostly associated with sinus mucosal thickening. In the present study also ,among the examined teeth, mucosal thickening was mostly associated with maxillary first molar (42.27%) .Janner *et al*<sup>17</sup>. reported the existence of MT when it was more than 2 mm and found MT in 37% of patients. The MT greater than 2 mm was a significant indicator of maxillary sinusitis and was considered to be a pathologic form.<sup>18</sup> Several studies have reported varying prevalence rates of odontogenic maxillary sinusitis, ranging from 10% to 86%<sup>11,12,19</sup>. One recent study reported that 98 of 135 maxillary sinus MT cases were tooth related, presenting with changes in the maxillary sinus floor<sup>20</sup>. Periapical diseases<sup>21,22</sup>, apical periodontitis, implant therapy<sup>23</sup> and tooth extraction<sup>24</sup> were thought to increase the risk of maxillary sinus MT. There was a significant association between MT and age.<sup>16</sup> With age, most of individuals present with dental diseases, such as missing teeth, apical abscess and other pathologic conditions and this has also triggered to increase the possibility of maxillary sinusitis.<sup>25</sup> In the study of Yu Lu *et al.*<sup>4</sup> it was seen that patients more than 60 years of age were found to be most likely to present with MT. But in our study, it was seen that maxillary sinus MT was higher among the patients aged between 41 to 60 years(48.9%). Using CBCT scanning, Maillet *et al.*<sup>26</sup> found that odontogenic sinusitis can be identified as localized MT of maxillary sinus related to dental infections. The complication of a periapical lesion related to a root apex that is in close proximity or penetrated into the sinus floor should be considered when a sinus infection is present specifically once the periapical disease reaches into the maxillary sinus, spreading and increasing the possibility of serious infections.<sup>4,28</sup> The local increased level of pathogenic bacteria and toxins and also inflammatory cytokines in apical lesions may directly infiltrate from the porous maxillary bone or they can reach indirectly through blood and lymph vessels. Both direct and indirect ways cause maxillary sinus MT.<sup>27,28,29</sup> If the amount of bacteria and toxins increase, this increases the severity of periapical lesion and thus increases the possibility of maxillary sinus MT.<sup>4</sup> According to various studies, it was assessed that 10-12% of maxillary sinusitis cases have an odontogenic origin. In the cases of odontogenic sinusitis the most common pathogens are commonly anaerobic and which don't respond to antibiotic therapies prescribed for common non-odontogenic pathogens and in the cases of non-odontogenic sinusitis pathogens are aerobic.<sup>31</sup> According to the studies of Janner *et al* & Maillet *et al*, Males are mostly associated with odontogenic maxillary sinusitis. But in our study it is assessed that there is no association between gender and maxillary sinus mucosal thickening. Both males and females were almost equally (Males=44.6%, Females=45.7%) associated with maxillary sinus mucosal thickening. p value calculated as 0.9 which was not statistically significant.

In our study, Among the 100 images, 47% shows maxillary sinus mucosal thickening score  $\geq 3$ (MT $\geq 2$ mm) in which 88.9% show CBCT Periapical index score  $\geq 2$ (figure 7).Spearman rank correlation coefficient obtained was 0.774.It indicates a strong positive correlation between maxillary sinus mucosal

thickening and periapical pathology and it is statistically significant. In the present study, the right side maxillary posterior teeth periapical infection (55.9%) were mostly associated with mucosal thickening than the left side posterior teeth. According to studies of Gollet-Bulut *et al*<sup>1</sup>, there was a significant relationship between the pulpoperiapical condition and MT was found. In the cases of odontogenic sinusitis the most common pathogens are commonly anaerobic and which doesn't respond to antibiotic therapies prescribed for common non-odontogenic pathogens and in the cases of non-odontogenic sinusitis pathogens are aerobic. Hence, diagnosing the exact source of infection is important for correct treatment planning. There is a need for additional studies to clear up the accurate relationship between MT of maxillary sinus and possible underlying causes with regards to the clinical symptoms. In the cases of maxillary sinus MT caused by periapical pathology endodontic and periodontal treatment helps to reduce the pathogens result in a reduction in MT.<sup>19,30,32</sup>

## V. Conclusion

There was a strong positive correlation between maxillary sinus MT and periapical radiolucency of maxillary premolar and molar teeth (excluding 3<sup>rd</sup> molar). The anatomic relationship between root apices or periapical lesions and the maxillary sinus floor influenced the likelihood of maxillary sinus MT development. Clinicians need to be aware of the exact relationship between the apical roots of the maxillary teeth and the maxillary sinus floor. CBCT imaging enabled a better evaluation of maxillary sinus, posterior teeth and surrounding structures compared to other imaging tools. It provides an accurate evaluation of maxillary bone quality and quantity around posterior root apices without the distortion and superimposition caused by teeth and the surrounding structures.

## References

- [1]. Goller-Bulut D, Sekerci AE, Köse E, Sisman Y. Cone beam computed tomographic analysis of maxillary premolars and molars to detect the relationship between periapical and marginal bone loss and mucosal thickness of maxillary sinus. *Med Oral Patol Oral Cir Bucal*. 2015 Sep 1; 20(5):e52.
- [2]. Sheikhi M, Pozve NJ, Khorrani L. Using cone beam computed tomography to detect the relationship between the periodontal bone loss and mucosal thickening of the maxillary sinus. *Dent Res J (Isfahan)*. 2014; 11:495-501.
- [3]. Chanavaz M. Maxillary sinus: anatomy, physiology, surgery, and bone grafting related to implantology--eleven years of surgical experience (1979-1990). *J Oral Implantol*. 1990; 16:199-209.
- [4]. Lu Y, Liu Z, Zhang L, Zhou X, Zheng Q, Duan X, et al. Associations between maxillary sinus mucosal thickening and apical periodontitis using cone-beam computed tomography scanning: a retrospective study. *J Endod*. 2012; 38:1069-74.
- [5]. Savolainen S, Eskelin M, Jousimies-Somer H, Ylikoski J. Radiological findings in the maxillary sinuses of symptomless young men. *Acta Otolaryngol Suppl*. 1997; 529:153-7.
- [6]. Hauman CH, Chandler NP, Tong DC. Endodontic implications of the maxillary sinus: a review. *Int Endod J*. 2002; 35:127-41.
- [7]. Watzek G, Bernhart T, Ulm C. Complications of sinus perforations and their management in endodontics. *Dent Clin North Am*. 1997; 41:563-83.
- [8]. Kilic C, Kamburoglu K, Yuksel SP, Ozen T. An assessment of the relationship between the maxillary sinus floor and the maxillary posterior teeth root tips using dental cone-beam computerized tomography. *Eur J Dent*. 2010; 4:462-7.
- [9]. Ezzodini Ardakani F, Razavi SH, Tabrizizadeh M. Diagnostic value of cone-beam computed tomography and periapical radiography in detection of vertical root fracture. *Iran Endod J*. 2015; 10:122-6.
- [10]. Scarfe WC, Farman AG, Sukovic P. Clinical applications of cone-beam computed tomography in dental practice. *J Can Dent Assoc*. 2006; 72:75-80.
- [11]. Cotton TP, Geisler TM, Holden DT, Schwartz SA, Schindler WG. Endodontic applications of cone-beam volumetric tomograph. *J Endod*. 2007; 33:1121-32.
- [12]. Soikkonen K, Ainamo A. Radiographic maxillary sinus findings in the elderly. *Oral Surg Oral Med Oral Pathol Oral Radiol Endod*. 1995; 80:487-91.
- [13]. Gang TI, Huh KH, Yi WJ, Lee SS, Heo MS, Choi SC. The effect of radiographic imaging modalities and the observer's experience on postoperative maxillary cyst assessment. *Imaging Sci Dent*. 2014; 44:301-5.
- [14]. Cymerman JJ, Cymerman DH, O'Dwyer RS. Evaluation of odontogenic maxillary sinusitis using cone-beam computed tomography: three case reports. *J Endod*. 2011; 37:1465-9.
- [15]. Nurbakhsh B, Friedman S, Kulkarni GV, Basrani B, Lam E. Resolution of maxillary sinus mucositis after endodontic treatment of maxillary teeth with apical periodontitis: a cone-beam computed tomography pilot study. *J Endod*. 2011; 37:1504-11.
- [16]. Phothikhun S, Suphanantachai S, Chuenchompoonut V, Nisapakulorn K. Cone-beam computed tomographic evidence of the association between periodontal bone loss and mucosal thickening of the maxillary sinus. *J Periodontol*. 2012; 83:557-64.
- [17]. Janner SF, Caversaccio MD, Dubach P, Sendi P, Buser D, Bornstein MM. Characteristics and dimensions of the Schneiderian membrane: A radiographic analysis using cone beam computed tomography in patients referred for dental implant surgery in the posterior maxilla. *Clin Oral Implants Res*. 2011; 22:1446-53.
- [18]. Rak KM, Newell JD, Yakes WF, Damiano MA, Luethke JM. Paranasal sinuses on MR images of the brain: significance of mucosal thickening. *AJR. American journal of roentgenology*. 1991; 156:381-4.
- [19]. Engström H, Chamberlain D, Kiger R, Egelberg J. Radiographic evaluation of the effect of initial periodontal therapy on thickness of the maxillary sinus mucosa. *J Periodontol*. 1988; 59:604-8.
- [20]. Maillet M, Bowles WR, Mc Clanahan SL, John MT, Ahmad M. Cone-beam computed tomography evaluation of maxillary sinusitis. *J Endod*. 2011; 37:753-7.
- [21]. Melén I, Lindahl L, Andréasson L, Rundcrantz H. Chronic maxillary sinusitis. Definition, diagnosis and relation to dental infections and nasal polyposis. *Acta Otolaryngol*. 1986; 101:320-7.
- [22]. Abrahams JJ, Glassberg RM. Dental disease: a frequently unrecognized cause of maxillary sinus abnormalities?. *AJR Am J Roentgenol*. 1996; 166:1219-23.
- [23]. Doud Galli SK, Lebowitz RA, Giacchi RJ, Glickman R, Jacobs JB. Chronic sinusitis complicating sinus lift surgery. *Am J Rhinol*. 2001; 15:181-6.



- [24]. Kretzschmar DP, Kretzschmar JL. Rhinosinusitis: review from a dental perspective. *Oral Surg Oral Med Oral Pathol Oral Radiol Endod.* 2003;96:128-35.
- [25]. Shao MY, Huang P, Cheng R, Hu T. Interleukin-6 polymorphisms modify the risk of periodontitis: A systematic review and meta-analysis. *J Zhejiang UnivSci B.* 2009;10:920-7.
- [26]. Bomeli SR, Branstetter BF, Ferguson BJ. Frequency of a dental source for acute maxillary sinusitis. *Laryngoscope.* 2009;119:580-4.
- [27]. Mafee MF, Tran BH, Chapa AR. Imaging of rhinosinusitis and its complications: plain film, CT, and MRI. *Clin Rev Allergy Immunol.* 2006;30:165-86.
- [28]. Selden HS. Endo-Antral syndrome and various endodontic complications. *J Endod.* 1999;25:389-93.
- [29]. Jung YH, Cho BH. Assessment of the relationship between the maxillary molars and adjacent structures using cone beam computed tomography. *Imaging Sci Dent.* 2012;42:219-24.
- [30]. Nenzén B, Welander U. The effect of conservative root canal therapy on local mucosal hyperplasia in the maxillary sinus. *Odontol Revy.* 1967;18:295-302.
- [31]. Puglisi S, Privitera S, Maiolino L, Serra A, Garotta M, Blandino G, et al. Bacteriological findings and antimicrobial resistance in odontogenic and non-odontogenic chronic maxillary sinusitis. *J Med Microbiol.* 2011;60:1353-9.
- [32]. Falk H, Ericson S, Hugoson A. The effects of periodontal treatment on mucous membrane thickening in the maxillary sinus. *J Clin Periodontol.* 1986;13:217-22.

Dr Ameena M S, et. al. "Evaluation of Maxillary Sinus Mucosal Thickening and Periapical Radiolucency Associated With Maxillary Posteriors Using CBCT." *IOSR Journal of Dental and Medical Sciences (IOSR-JDMS)*, 21(10), 2022, pp. 04-12.