

A Case series of congenital lobar emphysemas

Dr.C.Aparna.¹ Dr.B.Taheer Hussain,³ Dr. K.Sunil Kumar².

Dr.C.N. Bhargavi.³ Dr. Lakshmi Soundarya.³

1.Professor 2. Asst.Professor, 3. Postgraduate,
Department of pathology
,Kurnool Medical College,Kurnool
.AndhraPradesh.

Abstract

Background ; Congenital lobar emphysema is a rare cause of respiratory distress in neonates and infants. It is characterized by over-inflation of one or more lung lobes which is due to localized air trapping that compresses the ipsilateral and contralateral normal lungs.

Material & methods; Four cases are reported over a period of 2 years. Clinical and morphological data are collected.

Results ; Four cases in neonates from 45 days to 6 months. Not associated with any syndromes or other anomalies. Not associated with family history.

Conclusion : Very rare disease, can be corrected by surgery.

Key words; Emphysema, Congenital

Date of Submission: 01-01-2022

Date of Acceptance: 12-01-2022

I. Introduction :

Congenital lobar emphysema (CLE) is a rare developmental malformation of the lung. Its incidence being nearly 1 per 25000 births . This disease entity was precisely described for the first time in 1932 by Doctor Nelson. The cause of CLE is not yet fully understood; bronchial abnormalities or alveolar defects have been reported as etiological factors. The most frequently affected lobe is the left upper lobe (LUL), followed by the middle and then the right upper lobe (RUL). Males are more commonly affected with a male to female ratio is 3:1. The most common clinical presentation is neonatal acute respiratory distress. Dyspnea, tachypnea, wheezing, cough, and cyanosis are among the most common presenting symptoms. Symptoms may be exaggerated by feeding or crying . The time of onset and severity of symptoms varies depending on the degree of hyperinflation. In some infants, progressive respiratory distress develops rapidly, while others have a more gradual and insidious onset, 50% presenting by one month of age . On the other hand, there is a rare adult presentation .(1)

II. Results

Case1; 45days, female child, presented with tachypnea. Gross; lobectomy specimen with multiple small bullae on the surface. Largest measuring 3x2 cms. Microscopy; Dilated alveoli filled with blood. Some alveoli showing ruptured walls.(1131)

Case 2 ;(1097) 6 months female child, presented as failure to thrive. Gross: Received lobectomy specimen measuring9x7x1 cms. Microscopy: Ruptured alveoli with septa infiltrated by lymphocytes.

Case3; One month male child , presented with tachypnea.Gross: Received lobectomy specimen measuring 7.5x5x2 cms. Surface shows bullae, largest measuring0.2x0.2 cms. Microscopy: Distended alveoli filled with blood and exudate.(fig1&2)

Caase4;

In all the four cases left upper lobe is involved, three are female babies and one male baby. Post operative period was uneventful in all the cases. No associated cardiac anomalies were seen.

III. Discussion :

Congenital lobar emphysema is also termed as congenital overinflation. In the present study, there are 4 case over a period of two years, of which 3 are females which is in contradiction to the literature.Physical findings include hyper-resonant percussion, diminished breath sounds on the affected side and mediastinal shift which manifested by displacement of the cardiac point of maximal impulse. The chest may appear hyper expanded with limited respiratory excursion. The infants may present with recurrent respiratory infections or

poor feeding with failure to thrive .The diagnosis is suspected by clinical examination and chest X-ray imaging which can be confirmed by computed tomography (CT) of chest . The traditional treatment of CLE is lobectomy of the involved lobe or lobes . Some authors reported conservative treatment for patients with mild symptoms . The first curative lobectomy for CLE was performed on a four-year-old girl in 1943 by Gross and Lewis.(1)

Over distension of a lobe or segment of lobe is due to a “check valve” mechanism leading to mediastinal shift and progressive respiratory distress. An abnormal lobar bronchus development, most often a cartilage defect, and several extrinsic causes have been postulated as a causative mechanism in CLE , with chance associations with MillerDieker Syndrome and with Fanconi anaemia also reported . The cross linking of collagen and elastin is crucial for structural and elastic property of healthy lung. Familial cases of CLE have been reported, indicating an autosomal dominance inheritance pattern. A minor alteration in transcription in homeobox genes Nkx2.1 has been hypothesized as one possible mechanism of familial CLE . The reported incidence of associated cardiac defects in infants with CLE is around 20%.(2). CLE has an association with CHD so Echocardiography should be done to exclude ATRIAL SEPTAL DEFECT II.(3).

CLE can be diagnosed during prenatal evaluation by ultrasonography and may be associated with polyhydramnios and fetal hydrops.(3). The most common clinical presentation is neonatal acute respiratory distress, which is caused by localized air trapping that compresses the ipsilateral and contralateral normal lungs. Symptoms worsen as the emphysematous lobe gradually enlarges. Cyanosis is the second most common finding. However, similar symptoms with CLE may occur in bronchopneumonia, cyanotic congenital heart diseases, and several congenital abnormalities of the lung. Congenital lobar emphysema may be confused with tension pneumothorax. Chest tube insertion may further increase respiratory distress and lead to injury of the lung parenchyma. In CLE the pulmonary vessels extend to the periphery of the hyperinflated lobe and there is no visualization of a pleural line unlike in pneumothorax Moreover, differential diagnosis includes congenital cystic adenomatoid malformation, sequestration, bronchogenic cyst, unilateral hyperlucent lung syndrome, and pulmonary interstitial emphysema. (4).

Actually true emphysematous changes are lacking and some investigators classify this disease as congenital hyperinflation. The etiology of congenital lobar emphysema is idiopathic in half of the cases, whereas the other 50% have several mechanisms proposed to explain the air-trapping, which can be divided into intrinsic and extrinsic subtypes. Early diagnosis is crucial and in many cases it is difficult to differentiate between CLE and hyperinflation resulting from extrinsic bronchial obstruction (lymph nodes, vessels, masses, or cysts) that compresses the bronchus and produces valve obstruction. However, it is stated that even more than half of CLE cases are not related to airway abnormalities. Surgical removal is the most common treatment of choice . Early diagnosis of CLE is crucial and in many cases is complicated due to the variety of its clinical presentation that varies from mild tachypnea to severe respiratory distress [5].

It is possible that location is related to embryonic stage . Moreover, in many cases a shift of the mediastinum occurs as was the case here.(4). In the 1970s, Hislop and Reid proposed the polyalveolar lobe theory for the etiology of CLE.Histopathological examination showed that the alveolar number in the affected lobes was three to five times higher than in the other, normal parts. It is not known why the air is trapped in this polyalveolar lobe. Bronchial disease is another cause of CLE. Bronchial stenosis, atresia, bronchomalacia, bronchiectasis, and Meconium aspiration ,Hypertrophic mucosa membranes, Mold mucous plaques ,Foreign body aspiration , Bronchial polyp can be the differential diagnoses. Surgical removal is the most common treatment of choice . Early diagnosis of CLE is crucial and in many cases is complicated due to the variety of its clinical presentation that varies from mild tachypnea to severe respiratory distress [5].

Conclusion : Out of 4 cases reported in the present study , three are seen in females, which is rare .Early intervention prevents further complications. Before lobectomy, other differential diagnoses like pneumothorax have to be excluded.

References

- [1]. Essam Elbadry Hashim Mohamed , Ayman Mohamed Mohamed Abdel Ghaffar , Khaled Mohamed Abdel-Aal, Abdelhady Ahmed Helmy, Mostafa Ashry .Surgical management of congenital lobar emphysema: A 15 years experience in a tertiary thoracic surgery unit Journal of the Egyptian Society of Cardio-Thoracic Surgery 2018 ; vol26:308-317.
- [2]. Timothy Andrew Walsh,1 Krishna Revanna Gopagondanahalli,1 and Atul Malhotra1, Williams-Beuren Syndrome and Congenital Lobar Emphysema: Uncommon Association with Common Pathology? Case Reports in Pediatrics 2017,<https://doi.org/10.1155/2017/3480980>.
- [3]. Irum Latif, Samina Shamim, Shah Ali. congenital lobar emphysema.-Case Report. JPMA 2016;vo(l66):210-212
- [4]. Meletios Kanakis, Konstantinos Petsios, Dimitrios Bobos, Kosmas Sarafidis,Stefanos Nikopoulos, Konstantinos Kyriakoulis, Achilleas Lioulis,and Nicholas Giannopoulos:left Upper Lobectomy for Congenital Lobar Emphysema in a Low Weight Infant. Case Reports in Surgery 2016, <https://doi.org/10.1155/2016/4182741>
- [5]. Omer Faruk Demir1 Melih Hangul2 Mehmet Kose. Congenital lobar emphysema: diagnosis and treatment options. international Journal of Chronic Obstructive Pulmonary Disease 2019;14 :921-928.

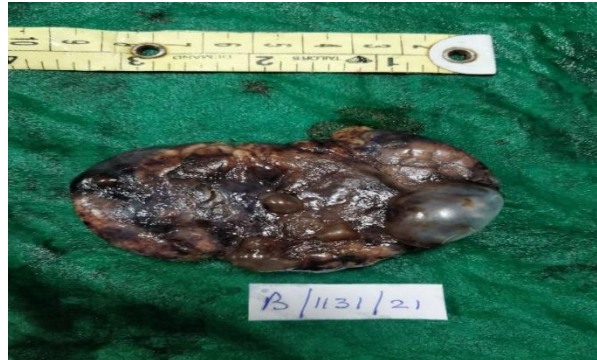

Fig:1 ;Gross picture of lobectomy Lung with a bullous.

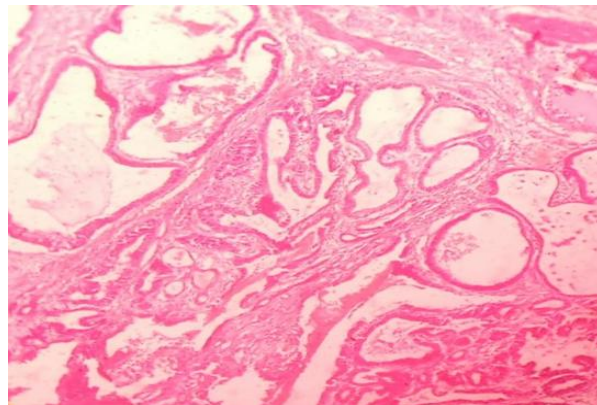


Fig2. 10x10,H&E stain; Microscopic picture of congenital lobar Emphysema showing dilated alveoli.

Dr.C.Aparna, et. al. "A Case series of congenital lobar emphysemas." *IOSR Journal of Dental and Medical Sciences (IOSR-JDMS)*, 21(01), 2022, pp. 05-07.