IOSR Journal of Dental and Medical Sciences (IOSR-JDMS)
e-ISSN: 2279-0853, p-ISSN: 2279-0861.Volume 21, Issue 1 Ser.4 (January. 2022), PP 05-08
www.iosrjournals.org

Giant Epidermal Cyst: A Case Report

T.T. Chhabda[1], Praful Pawar[1], A. Jibran Javed[2] , Pranav Wadhokar[2]
[1]*Assoc. Professor, Dept. of General Surgery, MGM Medical College and Hospital, Aurangabad, Maharashtra*
[2]*Assoc. Professor, Dept. of General Surgery, MGM Medical College and Hospital, Aurangabad, Maharashtra*
[3]*3rd year resident, Dept. of General Surgery, MGM Medical College and Hospital, Aurangabad, Maharashtra*
[4]*Lecturer, Dept. of General Surgery, MGM Medical College and Hospital, Aurangabad, Maharashtra*

Abstract:
Background: *Epidermal inclusion cysts are very common, benign swellings. They may be intradermal or subcutaneous, ranging from 1 to 4 cm in size[1]. They may occur anywhere in the body, mostly on the face, neck, and trunk and are typically asymptomatic. Transformation to squamous-cell carcinoma is rare.*
Case Report: *We present a case of a 65-year-old male patient with a large, growing mass in his right posterior gluteal region. Computed Tomography revealed a large cystic mass in the intramuscular plane of the right gluteal region compressing the underlying gluteal muscles with maintained fat planes. The mass was subsequently excised. Pathological examination revealed an inflamed epidermal inclusion cyst that measured 20.8 × 19.18 × 19.8 cm containing almost 1200 ml of white thick keratinous material. To our knowledge, this is the largest epidermal inclusion cyst reported in English literature.*
Keywords: Giant epidermoid cyst, rare case

Date of Submission: 20-12-2021 Date of Acceptance: 04-01-2022

I. Introduction :

Epidermal inclusion cysts occur as a result of the migration of epidermal cells into the dermis. They are lined with stratified squamous epithelium. These lesions are described in the literature as typically being small, solitary, and slow-growing, located on the trunk, face, scalp and neck, with uncommon cases of larger masses reported on the extremities [2,3].The overlying skin almost always shows a surface punctum[4]. They occur more commonly in men than women, with a ratio of 2:1 and present clinically in the 2nd to 4th decade of life. They can be hereditary in nature and can be seen in Gardner syndrome, Favre-racouchot syndrome and Gorlin syndrome. Complications of the cyst include infection, rupture, bleeding, compression of surrounding structures. Complete surgical excision in the standard surgical treatment.

II. Case Report:

A 65-year-old man presented with a large mass over the right buttock measuring 10 x 16 x 15 cm, which was first noticed 5 years ago. The patient denied any history of trauma to the area and never had any similar swellings. The mass slowly increased in size over 5 years and was associated with postural discomfort due to large size after 5 months. Patient also complained of pain over the mass region for 4 months. At the time of presentation, the patient was unable to lie in the supine position because of the large size of the mass. Physical examination revealed a very large spherical mass over the left gluteal region which was firm, slightly tender and non mobile. The skin over the swelling was normal with no punctum or redness.

Contrast enhanced CT imaging revealed a large oval well defined cystic lesion (11.5x17.9x16.1 cm) in the intramuscular plane of the right gluteal region with approximately 1700 cc of homogenous fluid content inside. It was compressing over the underlying gluteal muscles. Fat planes around the mass were maintained.

Figure 1: CT scan showing epidermal cyst (white arrow) with maintained fat planes in right gluteal region

Figure 2 : CT scan showing epidermal cyst (white arrow) with maintained fat planes in right gluteal region

Subsequently the patient was taken for surgical excision owing to discomfort on lying down and the increasing size of the swelling. The patient was operated under spinal anaesthesia in a prone position. An elliptical incision was taken along the length of the swelling and blunt dissection was performed using hemostat forceps to free the mass from the surrounding structures. Intraoperatively, the mass was well encapsulated with no invasion of surrounding tissues and cyst was excised in toto, on incision of the wall almost 1200 ml of white thick cheesy fluid was aspirated. Thorough normal saline wash was given and hemostasis confirmed. Negative drain was placed and closure was done in layers. Post operative period was uneventful and the patient was discharged on post op day 3. Sutures and drain were removed at 1 week and at 6 month follow up, the patient is completely recovered and shows no signs of recurrence. Histopathology examination revealed dermal cyst lined by stratified squamous epithelium and containing keratin flakes and collection of histiocytes, lymphocytes, foreign body giant cell reaction with no atypia or malignancy suggestive of inflamed epidermal inclusion cyst.

III. Discussion:

Epidermoid inclusion cyst are slow growing, asymptomatic, benign , subcutaneous or intradermal swellings generally growing upto 5 cm in size[7]. Primary epidermal cysts arise directly from the infundibulum of the hair follicle due to plugging of the follicular orifice. The cyst often communicates with the surface of the skin through a small orifice or visible central punctum. Secondary epidermoid cysts arise after the implantation of the follicular epithelium in the dermis due to trauma or comedone formation. Epidermoid cysts are lined with stratified squamous epithelium with the accumulation of keratin in the core.

There are no predictive markers to estimate whether a cyst will increase in size, get inflamed or remain asymptomatic. Inflamed, uninfected epidermal inclusion cysts rarely resolve spontaneously without therapy or surgical intervention.

Treatment is not emergent unless desired by the patient electively or an increase in symptom severity (pain and/or infection). Definitive treatment is the surgical excision of the cyst including the wall to reduce reccurence[5,6].

Figure 3: large right gluteal epidermal cyst of 11 x 18 x 16 cms.

Figure 4: cyst excision in toto with white cheesy keratinous material

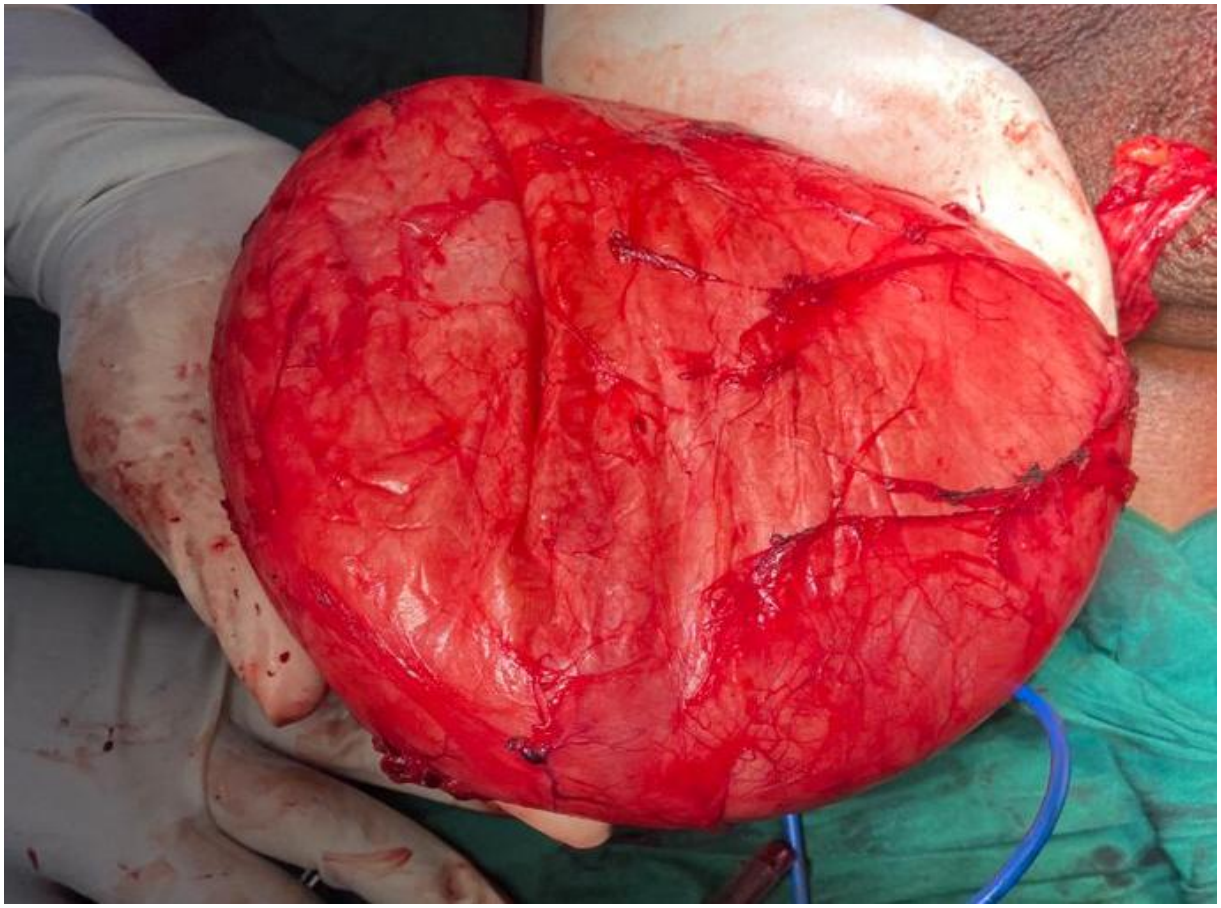

Figure 5: complete cyst excision with intact capsule.

IV. Conclusion:

In this case report we present a case of inflamed epidermoid cyst of size 11 x18 x 16 cms. As per our knowledge this is the largest epidermoid cyst reported in the available literature. Complete surgical excision of cyst along with its wall remains the mainstay of treatment to reduce recurrence.

[1]. Houdek M, Warneke J, Pollard C, Lindgren E, Taljanovic M. Giant epidermal cyst of the gluteal region. Radiology Case Reports. 2010;5(4):476.

[2]. Handa U, Chhabra S. Epidermal inclusion cyst: Cytomorphological features and differential diagnosis. *Diagn Cytopathol.* 2008;36:861–863. [PubMed] [PubMed] [Google Scholar] [Ref list]

[3]. Momeni MG, Anavim A. Giant epidermal inclusion cyst of buttock. *Skeletal Radiol.* 2006;35:864–866. [PubMed] [PubMed] [Google Scholar] [Ref list]

[4]. Weedon D. *Weedon's skin pathology.* 3rd Edition. Elsevier; 2010. pp. 442–446.

[5]. Weir CB, St.Hilaire NJ. Epidermal Inclusion Cyst. [Updated 2021 Aug 11]. In: StatPearls [Internet]. Treasure Island (FL): StatPearls Publishing; 2021 Jan-. Available from: https://www.ncbi.nlm.nih.gov/books/NBK532310/

[6]. Zito PM, Scharf R. StatPearls [Internet]. StatPearls Publishing; Treasure Island (FL): Sep 29, 2020. Epidermoid Cyst. [PubMed]

[7]. Kalgutkar A, Kini S, Jambhekar N, Das S. Intradiploic primary epithelial inclusion cyst of the skull. *Ann Diagn Pathol.* 2006;10:20–3.

T.T. Chhabda, et. al. "Giant Epidermal Cyst: A Case Report." *IOSR Journal of Dental and Medical Sciences (IOSR-JDMS)*, 21(01), 2022, pp. 05-08.