

## **The Efficacy of Rhomboid Excision and Limberg Flap in the Management of Chronic Pilonidal Sinus – A Case Series**

**Dr. V. T. Sathish, Dr. S. Dorian Hanniel Terrence, Dr. Akshar Aravind**

*Assistant Professor, Department of General Surgery, Govt Rajaji Hospital and Madurai Medical College*

*Assistant Surgeon, Department of General Surgery, Govt Headquarters Hospital, Cuddalore*

*Senior Resident, Department of General Surgery, Govt Karur Medical College and Hospital, Karur*

---

Date of Submission: 06-09-2021

Date of Acceptance: 20-09-2021

---

### **I. INTRODUCTION**

Sacrococcygeal Pilonidal Disease(PD) has an incidence of 26 per 100000 people and is a source of morbidity to young adults due to the chronicity of the disease and the extent of surgical intervention. Treatment of PD ranges from simple incision and drainage to excision with flap reconstruction. Wound complications and recurrence remain high despite the availability of multiple therapies. Hence it is a challenging disease process to both patients and surgeons.

The evolution of treatment for PD was guided by the various theories that were put forth for its origin. Since it is a disease of young adults, especially working men, there is a need to do as much as a conservative approach as possible, while avoiding recurrence.

Various studies have been done to find out which approach is the best for Pilonidal Disease. In a recent Cochrane review comparing open approach versus primary closure, there is no clear benefit in the type of technique with regard to healing time and surgical site infection. Ultimately the goal is complete wound healing with minimal patient disability and a low rate of recurrence. Therefore the surgeon must individualize the approach to suit the needs and expectations of the patient.

This case series consisting of the outcome for 37 cases, where rhomboid excision and Limberg Flap Cover was done for chronic pilonidal sinus, is presented here. This is a simple technique where excision of all sinus tracts and the natal cleft is done, followed by transposition of a fasciocutaneous flap, thereby lateralising the suture line. This study has been done in the Department of General Surgery, Govt Rajaji Hospital and Madurai Medical College.

The outcome proved that Rhomboid Excision of chronic pilonidal disease and Limberg Flap cover is a good primary procedure with low rates of wound infection and recurrence rates.

### **II. AIM AND OBJECTIVE**

To find out the efficacy of rhomboid excision of chronic pilonidal disease followed by Limberg flap cover as a primary procedure for Pilonidal disease.

### **III. REVIEW OF LITERATURE**

Etiopathogenesis of Pilonidal Disease :

PD was first described by M. Hodges in 1880 as a sinus containing a nest(nidus) of hair(pilas).

Congenital Theory :

Proposed by Gage in 1935, it attributed pilonidal sinus disease to anomalous embryonic development of the medullary canal. Others proposed that PD was caused by invagination of integumentary structures.

Acquired Theory:

- During 1939-1945 in the second World War, it was noted that PD was much more common in the military service than in the civilian life. Hence, Hardaway proposed that the disease was common in young men with poor personal hygiene. It was postulated that compression and irritation of the coccyx during field activities such as driving in jeeps could be the cause. Hence the term, Jeep Bottom.

- In 1946, Patey and Scarff found out after histological examination of pilonidal sinus tracts that they are a form of “infective track formed from surface hairs that have deeply penetrated the dermis causing a foreign body granulomatous reaction”.

- Bascom proposed that the intergluteal cleft creates a vacuum force that directs hair foreign bodies into the subcutaneous tissue.

▪ In 1992, Karydakis theorized that there were three major factors which underlie the pathogenesis of PD – the invasion of loose hair, the force which causes hair embedding and the vulnerability of affected skin.

▪ Recent electron microscopic analysis of pilonidal sinus hair samples showed that the majority of the embedded hair is rootless, with razor sharp ends.

As such, the current mechanism of action appears to be acquired and that of local irritation from embedding of loose cut hairs.

Clinical Features:

- More common in men.
- In the age groups of 18-30.
- Rare after 40 years of age.
- Principally affects whites and rare in blacks and Asians.
- Risk factors include obesity, high degree of hair growth, family history of PD, local trauma and sedentary occupation.
- In acute form, PD presents as an abscess and in chronic form, with single or multiple branching draining sinuses.(Fig 1). The acute abscess will be located cephalad to the natal cleft.
- PD is mostly a clinical diagnosis, with common differential diagnoses including Furunculitis, Hidranetis Suppurativa, Perianal fistula, Sacral osteomyelitis, Tuberculosis and Actinomyces.
- In chronic cases, PD can undergo malignant degeneration. Histology is predominantly Squamous cell carcinoma.

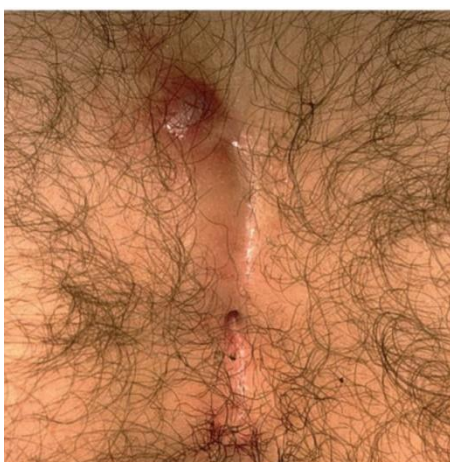


Fig 1 – Pilonidal sinus

Histology: (Fig 2)

- Pits lined with squamous epithelium.
- Sweat glands or hair follicles are rare, but hair shafts are found 75% of times.
- Foreign body giant cells are seen in a background of chronic granulation tissue.

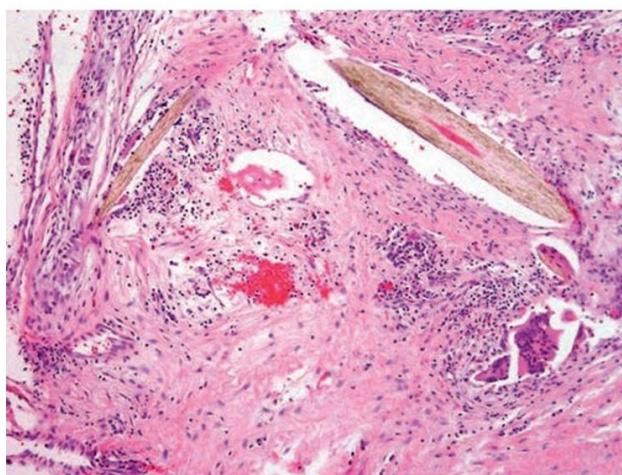


Fig 2 – Hair follicle with foreign body giant cell

Treatment:

In the era of the congenital theory for PD, treatment consisted of complete extirpation of subcutaneous tissue to the level of the sacral fascia.

With the acquired theory, complex resections with primary closure / cover aim to address both the offending tissue and underlying mechanical etiology.

Drainage for Acute Pilonidal Abscess:

- In acute pilonidal abscess, a staged approach is employed.
- Initially, drainage is done in a prone jackknife position with a paramedian longitudinal incision . All debris and hair should be removed from the cavity.
- The patient should perform routine Sitz baths and other good personal hygiene measures.
- Later after wound healing, definitive treatment should be done.
- Laser epilation can be offered as an adjunct.

Treatment for Chronic Pilonidal Disease:

The various treatment options performed historically and currently for chronic PD is summarized below;

Non resectional approach:

- Advocated by Armstrong and Barcia.
- Consists of minimal Incision and Drainage, meticulous shaving of hair and good perineal hygiene.
- Instillation of phenol can cause closure of the tracts.
- Complete healing was demonstrated in 101 cases over a 1 year period.

Midline follicle Excision and Lateral Drainage:

- Advocated by Bascom and by Lord and Millar.
- Longitudinal incision off of midline is done for access to the sinus tract. The tract is debrided of necrotic material, hypergranulation tissue and hairs.
- The midline pits are also excised. (Fig 3)
- Healing occurs in a short time of 3 weeks.
- Bascom reported an 84% cure rate following 149 patients.

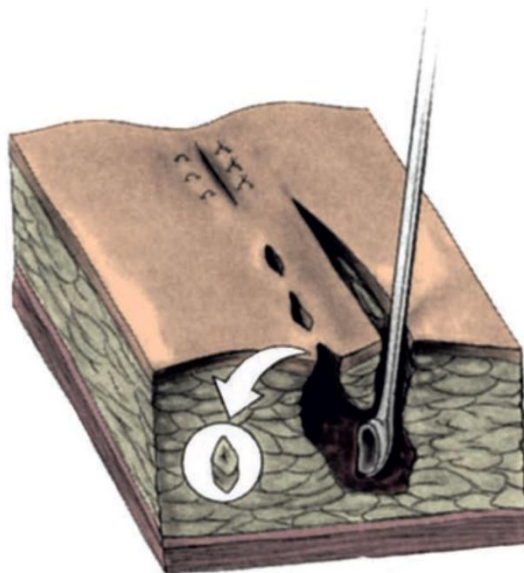


Fig 3 – Midline follicle excision and Lateral drainage

Incision and Curettage with Marsupialization or Saucerization: (Fig 4)

- The sinus cavity is opened and curetted off all debris and granulation tissue.
- All secondary tracts are identified with a fistula probe and deroofed.
- Skin edges are bevelled to allow for dependent drainage.
- Alternatively the skin edges can be sutured (marsupialization) to the base of the wound.
- Negative pressure therapy can be used to promote wound healing. (Fig 5)
- Metaanalysis demonstrated that this approach has low recurrence rates and shorter operative time.
- But patients seem to have more pain and discomfort after this procedure.

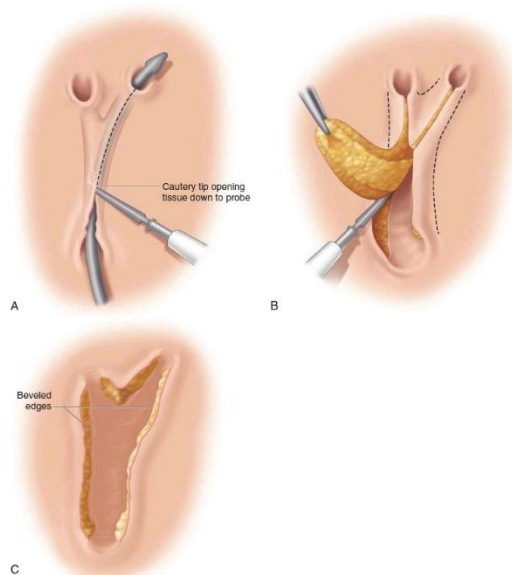


Fig 4 – Unroofing and Saucerization of Pilonidal Wound

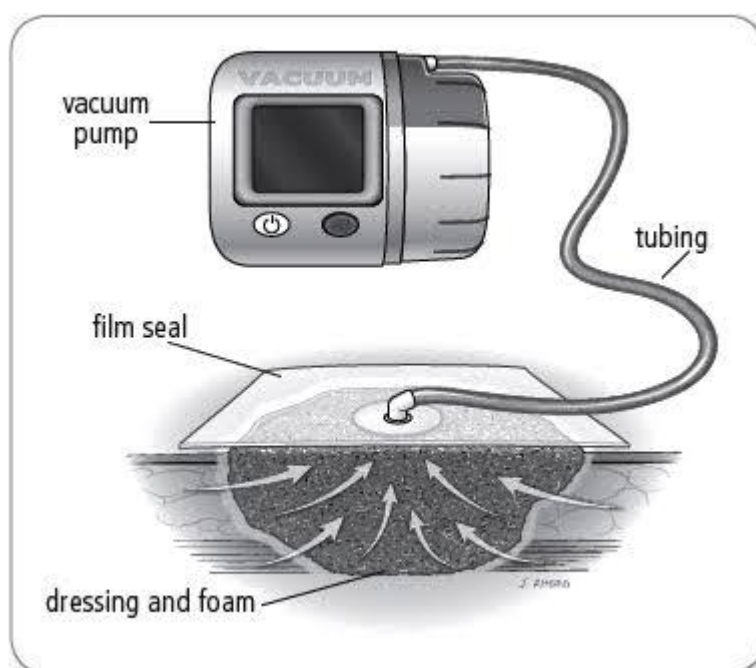


Fig 5 – Negative Pressure Therapy

Excision with or Without closure:

- Extirpation of the pilonidal cavity and all associated inflammatory tissue is done. (Fig 6)
- The wound can be closed primarily or left open to heal by secondary intention.
- Metaanalysis demonstrated the following results in open versus closed approaches;
- Wound healing – better with primary closure.
- No difference in infection rates among the two approaches.
- Decreased recurrence – with open approach.
- Decreased hospital stay and faster return to work – with primary closure.
- Off- midline closure is better than midline closures.

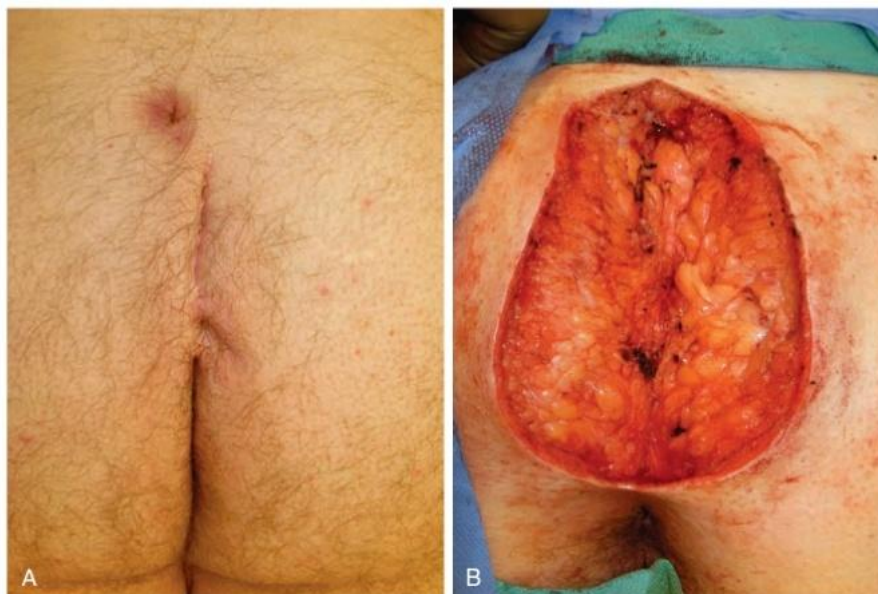

Fig 6 – Extirpation of the PD cavity

Treatment for Recurrent/Unhealed/Chronic Pilonidal Disease:

- These patients usually have extensive, complex disease and require a more radical approach.
  - Multiple procedures have been described and include Z plasty, V-Y Fasciocutaneous flap, Rhomboid excision and Limberg flap, Gluteal myocutaneous flaps, the Karydakis operation and cleft lip procedure.
- Bascom Technique of Cleft Lift: (Fig 7)
- Here, the midline non-healing wound is excised in a triangular fashion.
  - A full thickness skin flap is raised to overlap the skin edges of the wound on the opposite side.
  - End result – Superior gluteal cleft is eliminated and the incision line is displaced off of midline, leading to better healing.
  - Closed suction drain is placed.

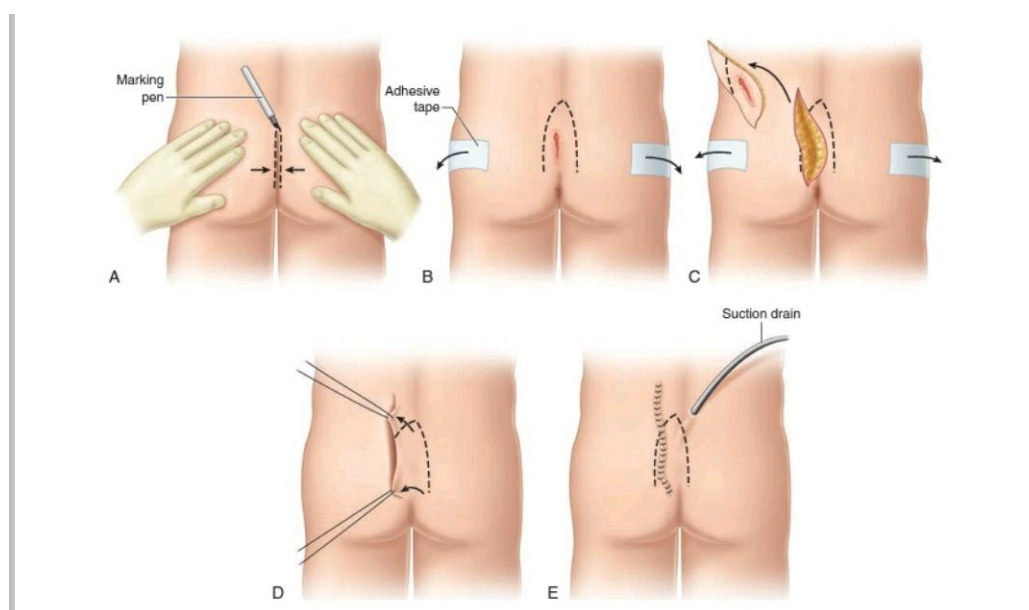


Fig 7 – Bascom cleft lift technique

Modified Bascom Procedure: (Fig 8)

- This is an ideal procedure when there are no unhealed wounds or scars in midline.
- All the pilonidal pits are excised with a 11 blade with a 2-3 mm depth to include the epithelialized portion of the pit.

- On the side of the previous infection, a 2-3 cm incision is made 2 cm away from the midline.
- Purposes of Incision:
  - 1) It is used to enter the sinus system and curette out all hairs and infective granulation tissue.
  - 2) Through it, the midline skin is released from its tethering to the post sacral fascia, hence the depth of the natal cleft is reduced.
  - 3) The incision is left open, relieving the tension on the midline.
- All the pits are closed with 5-0 prolene in the subcuticular plane.
- The flap described in the original Bascom procedure is omitted.
- The wound is simply bandaged with an antiseptic wick.
- Healing occurs by 2 weeks.

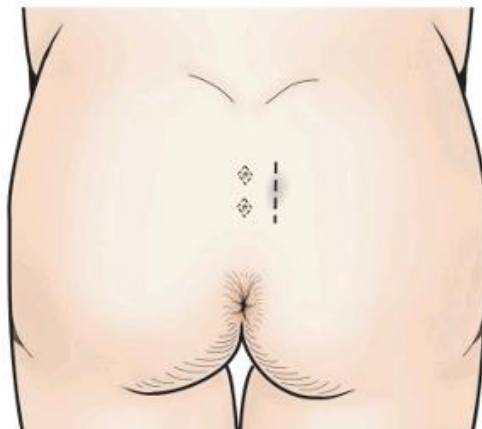
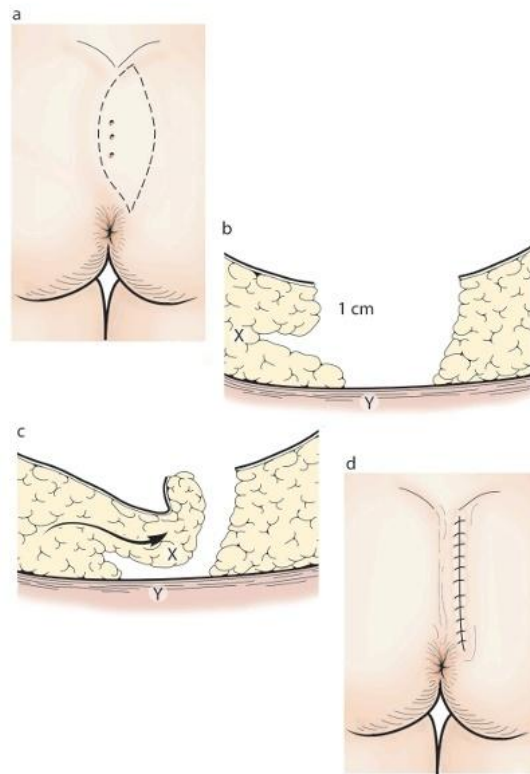


Fig 8 – Modified Bascom Technique

#### Karydakis Flap: (Fig 9)

- First, an elliptical incision is made down to the deep fascia, with length at least 5 cm, parallel to the midline.
- The medial side of the ellipse must cross the midline and must enclose all diseased tissue.
- The whole length of the medial side of the incision is then mobilized by undercutting a distance of 2 cm at a depth of 1 cm.
- The first suture is taken between the limit of the undercutting incision and the deep fascia in the midline. These draw the flap over and create a new shallow midline sulcus.
- A vacuum drain is placed.
- A second layer of superficial fat sutures are done.
- Skin is closed with interrupted non-absorbable sutures.
- The wound lies a few centimetres away from midline.



**Figure 24.24** Karydakís flap. (a) The long axis of the ellipse is parallel to the midline and 2 cm from it. The length of the ellipse must be such that the medial side of the ellipse crosses the midline to include all diseased midline tissue. The lateral side of the incision must be planned so that the ellipse is symmetrical. (b) An undercutting incision is made along the whole length of the medial side, 1 cm below the skin surface. This undercut should be extended out for 2 cm. (c) The medial flap is unrolled and advanced over the midline. Deep sutures are placed between points X and Y. (d) The final scar is not in the midline.

Fig 9 – Karydakís Flap

Limberg Rhomboid Flap:

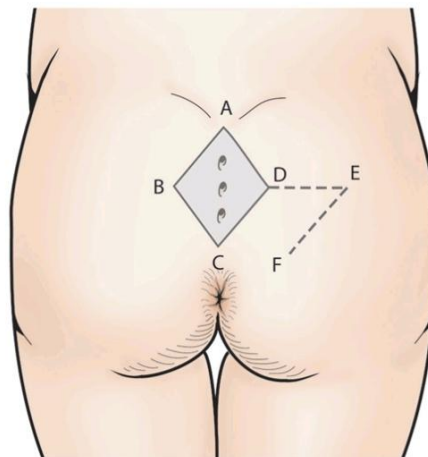
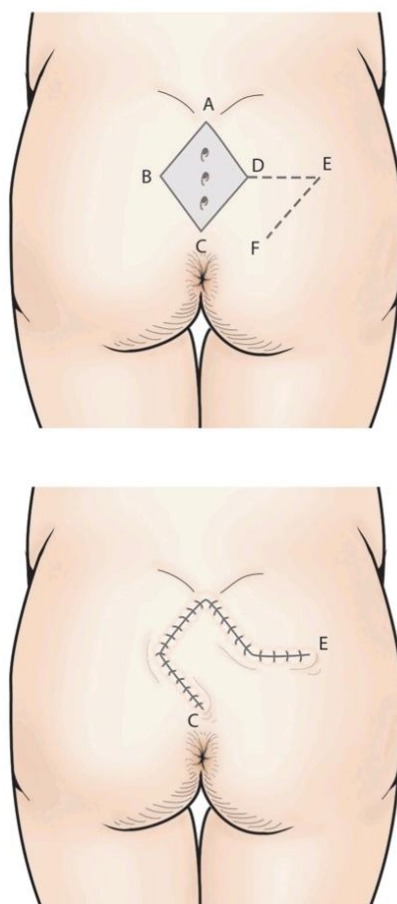


Fig 10 – Limberg Flap

- The patient is placed in prone position.
- Buttocks are strapped apart.
- A rhombic area of skin and sub cutaneous tissue is excised, which includes both the midline pits and any lateral sinus extensions.
- The long axis of the rhomboid is in the midline and its shape is determined by angles of 60 degrees at points A and C and 120 degrees at points B and D.
- The lines A-C and B-D is measured with the following conditions; (Fig 10)
- Point C should be adjacent to the perianal skin.
- Point A is placed so that all diseased tissue can be included in the excision.
- The line B-D transects the midpoint of A-C at right angles and is 60% of its length.
- The flap is planned so that, D-E is a direct continuation of B-D and is of equal length to B-A, to which it will be sutured after rotation.
- E-F is parallel to D-C, and of equal length. After rotation, it will be sutured to A-D.
- The flap is raised so that it includes skin, subcutaneous tissue and the fascia overlying the gluteus maximus.
- It is then rotated to cover the midline rhomboid defect and the defect this creates can be closed in a linear fashion. (Fig 11,12)
- A drain is kept before closing fascia and fat with deep, absorbable sutures and the skin is closed with interrupted sutures.
- This produces a tension free flap of unscarred skin in the midline.



**Figure 24.25** Limberg rhomboid flap. Marking is essential. B-D is 60% of the length of A-C. D-E is a direct continuation of B-D and the same length as A-B. E-F and C-D are parallel and of the same length. The tissue within A-B-C-D is excised. A flap of C-D-E-F is mobilised on a pedicle of C-F.

Fig 11 – Limberg Flap before and after completion.



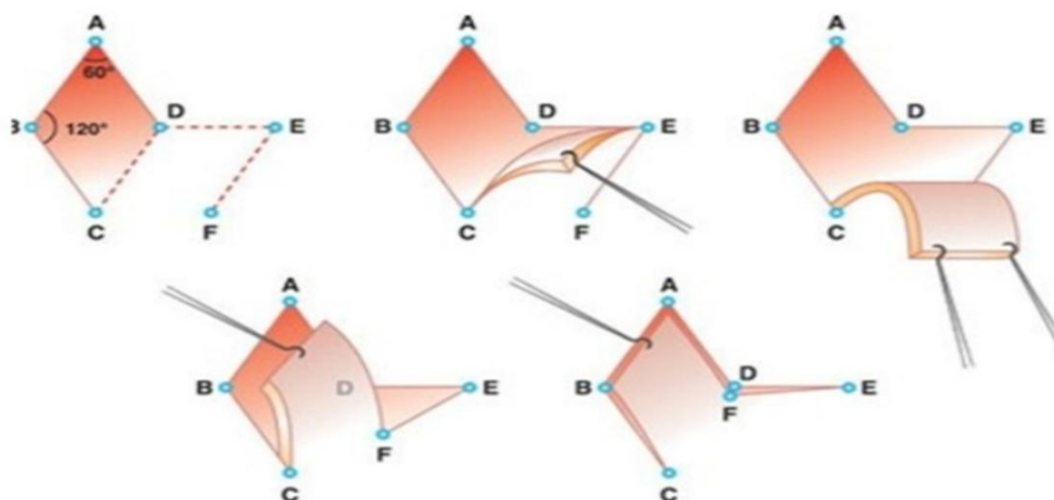


Fig 12 – Diagrammatic representation of Limberg Flap

#### IV. MATERIALS AND METHODS

##### Primary Objectives

To find out the efficacy of rhomboid excision of chronic pilonidal disease followed by Limberg flap cover as a primary procedure for Pilonidal disease, in terms of wound infection, rates of recurrence and other parameters.

##### Eligibility criteria

##### A. Inclusion Criteria:

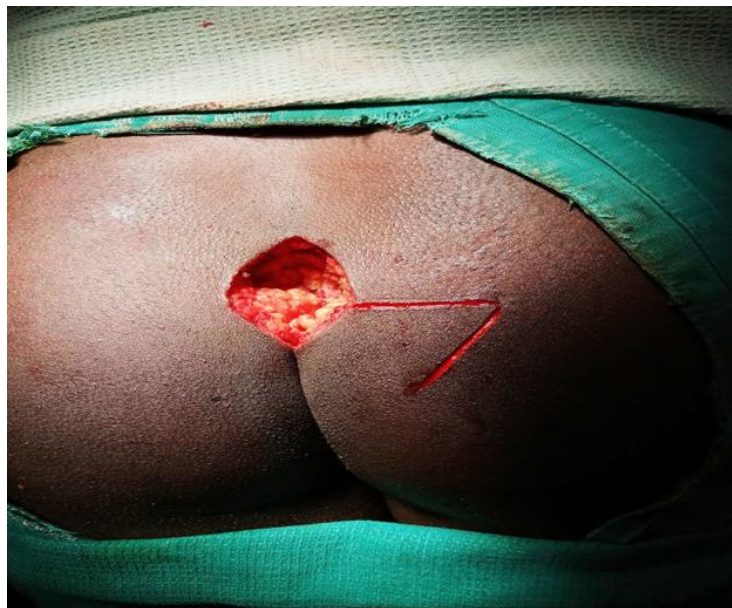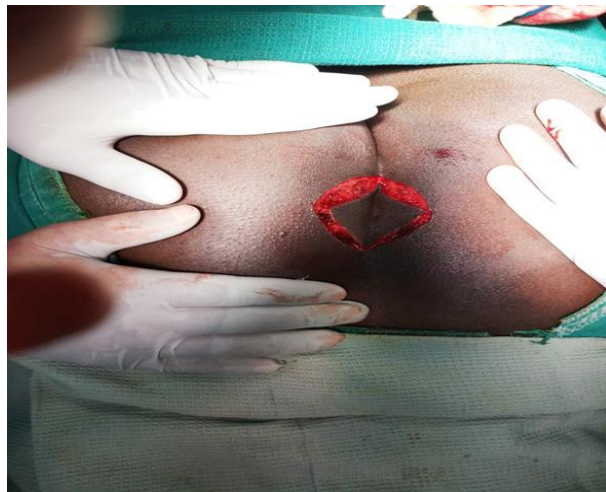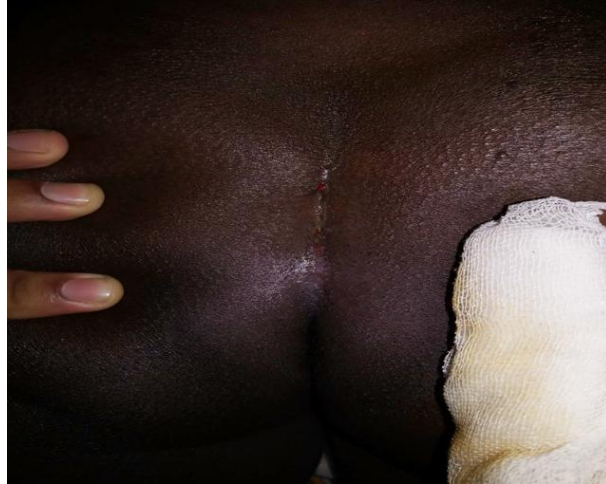- All patients presenting to Govt Rajaji Hospital, Madurai, Surgical OP with Chronic Pilonidal Disease in the age group 18-65 years, irrespective of sex.
- All patients should have given consent to be included in this study.

##### B. Exclusion Criteria:

- Patients <18 years and >65 years.
- Patients presenting with Acute Pilonidal abscess
- Patients with Chronic Anaemia and Uncontrolled Diabetes
- Patients who have not consented for the study.

##### Methodology:

- 37 patients presenting with Chronic Pilonidal Disease were selected for this study over a 2 year period from May 2018 – May 2020.
- All the patients were operated with Limberg flap cover as described above.(Fig 13), under Spinal anaesthesia and Jackknife position.
- Postoperatively they were treated with IV broad spectrum antibiotics, adequate analgesia and supportive measures.
- Postoperatively drain was removed between 6th and 8th post operative days.
- Sutures were removed in the 12th to 14th post operative days.
- All patients were observed for Postoperative pain, Haematoma formation, Surgical site infection, Flap Necrosis, Duration of Hospital Stay , Return to work and followed up for a period of six months to detect recurrence.
- All patients were counselled about good personal hygiene and Epilation methods.



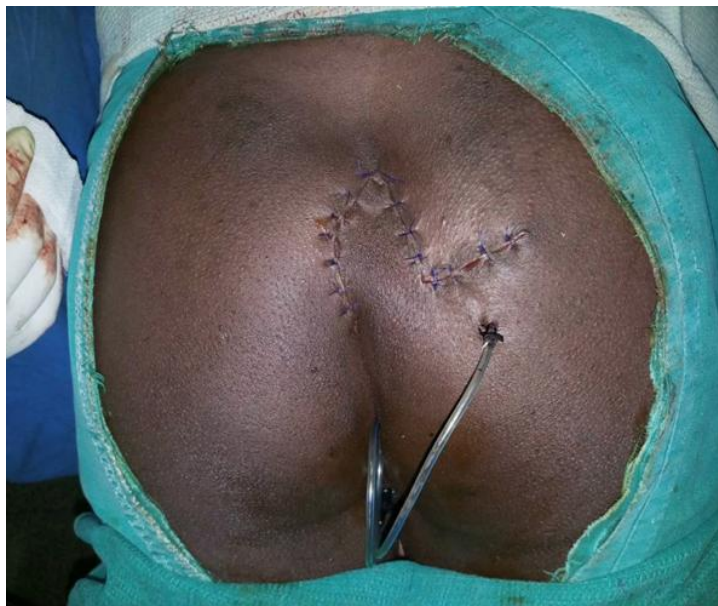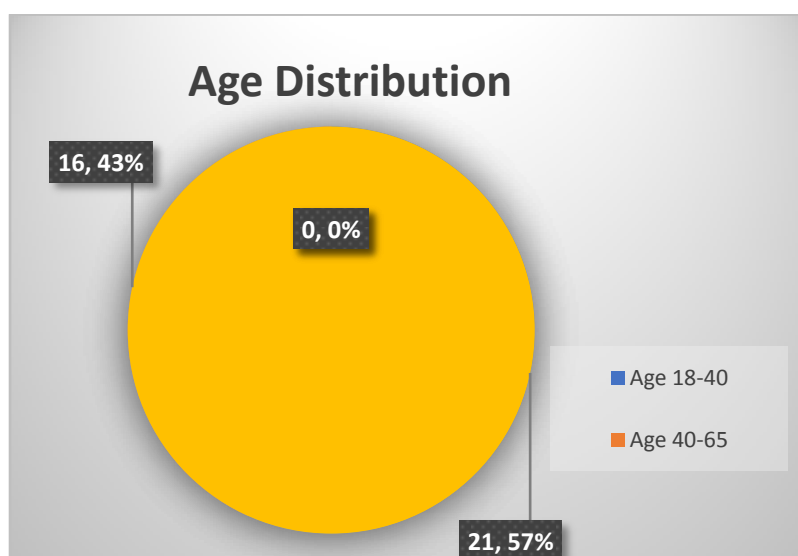


Fig 13 – Rhomboid Excision and Limberg Flap Cover

## V. RESULTS

### 1. Age Distribution:

S No	AGE	NUMBER
1	<18	0
2	18-40	21
3	40-65	16
4	>65	0



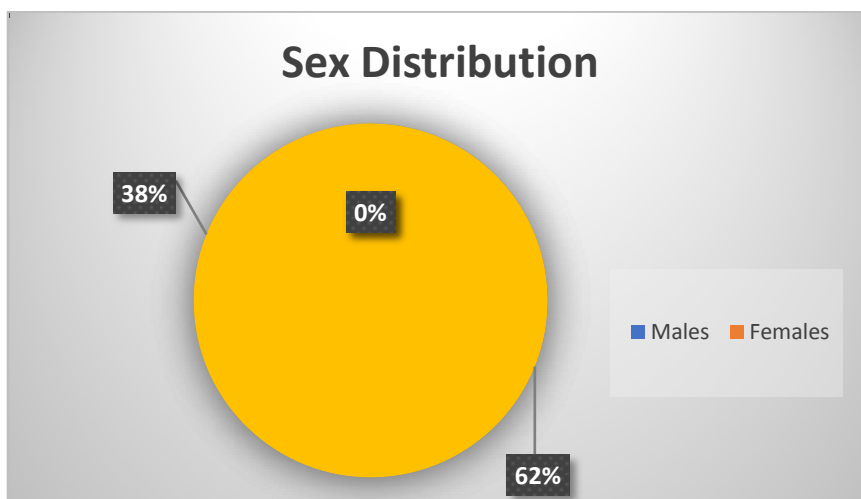
57% (21 patients) were in the age group 18 – 40 years

43% (16 patients) were in the age group 40 - 65 years.

### 2. Sex Distribution:

**Males – 23(62%)**

**Females – 14(38%)**



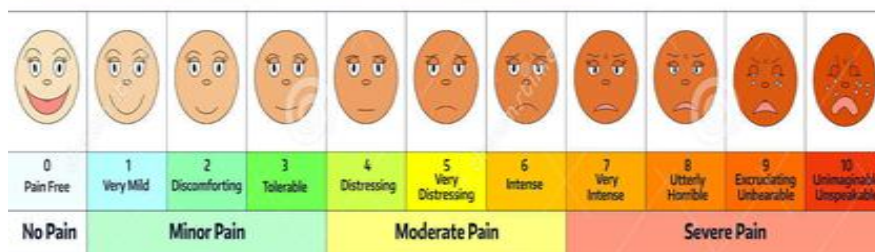
**3. Time Taken for Operation:**

The average time taken for the surgery to be completed was 85 mins.

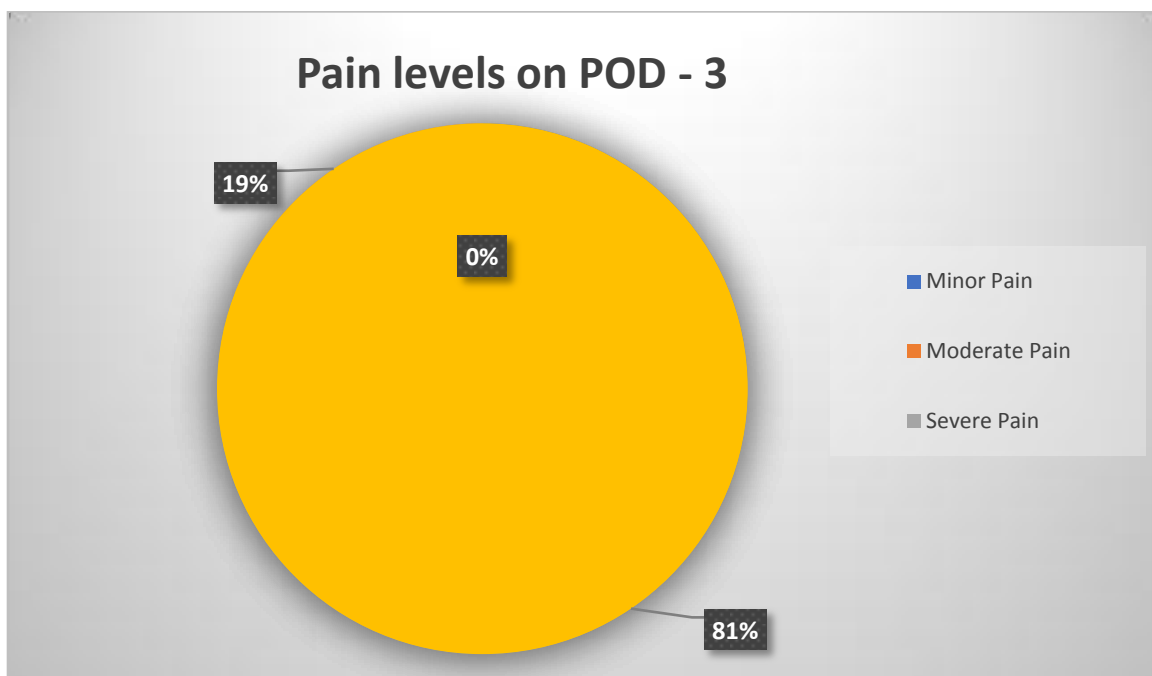
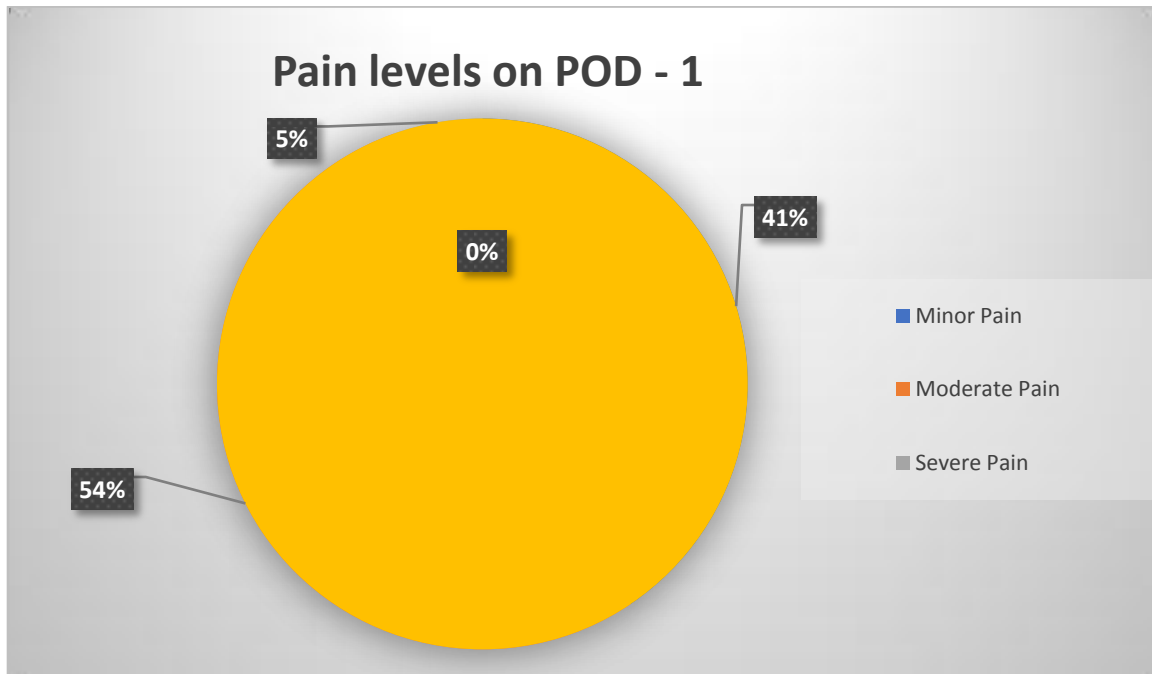
**4. Post – operative Pain:**

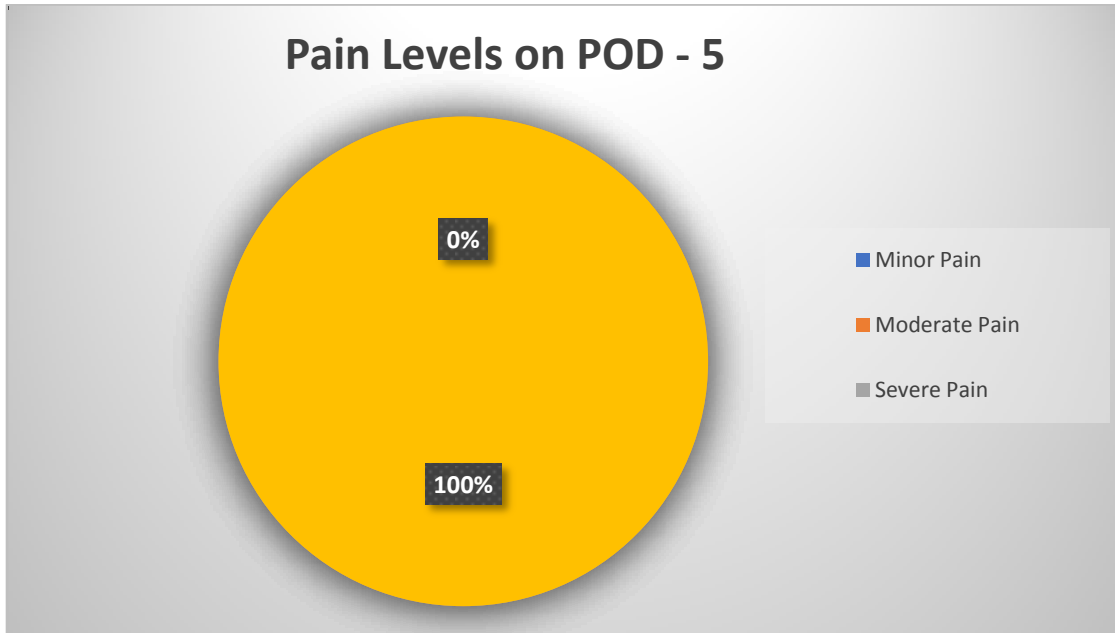
The degree of post operative pain was determined using the Visual Analog scale. It was assessed on POD – 1, 3 & 5.

**COMPARATIVE PAIN SCALE CHART (Pain Assessment Tool)**



Post – operative days	No. of patients with Score $\leq 3$ (Minor Pain)	No. of patients with Score 4 to 6 (Moderate Pain)	No. of patients with Score $>6$ (Severe Pain)
POD -1	15	20	2
POD – 3	30	7	0
POD - 5	37	0	0





- On POD – 1, 41% (15 patients) had minor pain, while 54% (20 patients) had moderate pain and 5% (2 patients) had severe pain; these 2 patients were alone treated with Opioid analgesics. All other patients were given NSAIDs only.

- While on POD – 5, all patients (100%) had Minor Pain only.

**5. Haematoma Formation:**

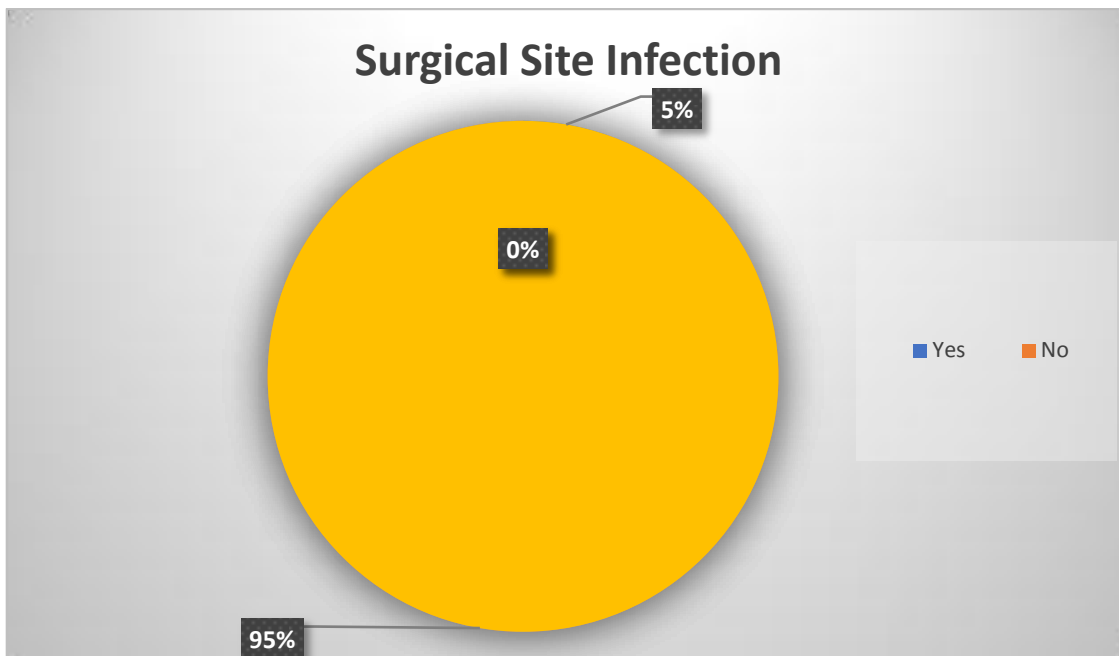
- It is defined as localized collection of blood at surgical site, found on aspiration of swelling (if present) on incision site or expressed after removal of sutures.

- None of the patients had Haematoma formation postoperatively.

**6. Surgical Site Infection:**

- It is identified by the collection of purulent material at the site of incision, associated with tenderness, erythema and edema at the incision site.

- 2 of the patients (5%) had superficial surgical site infection. They were treated with IV antibiotics according to Culture and Sensitivity, aspiration and wound Dressings. The organism identified in both cases was Staphylococcus aureus.

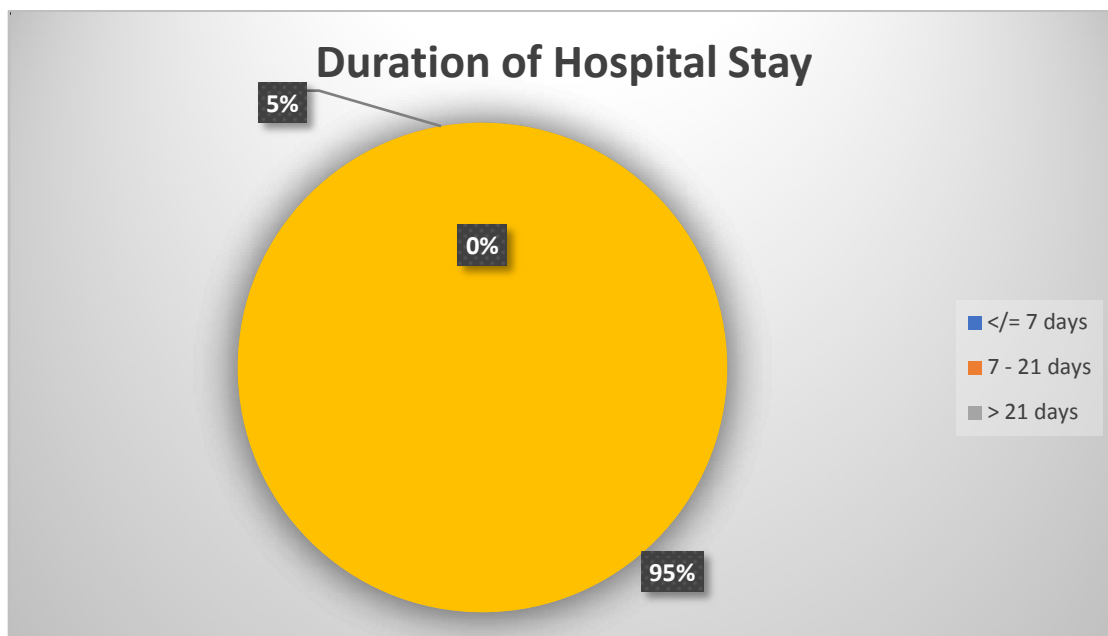


**7. Flap Necrosis:**

None of the patients had Flap necrosis as a complication over the six months follow up period.

**8. Duration of Hospital Stay:**

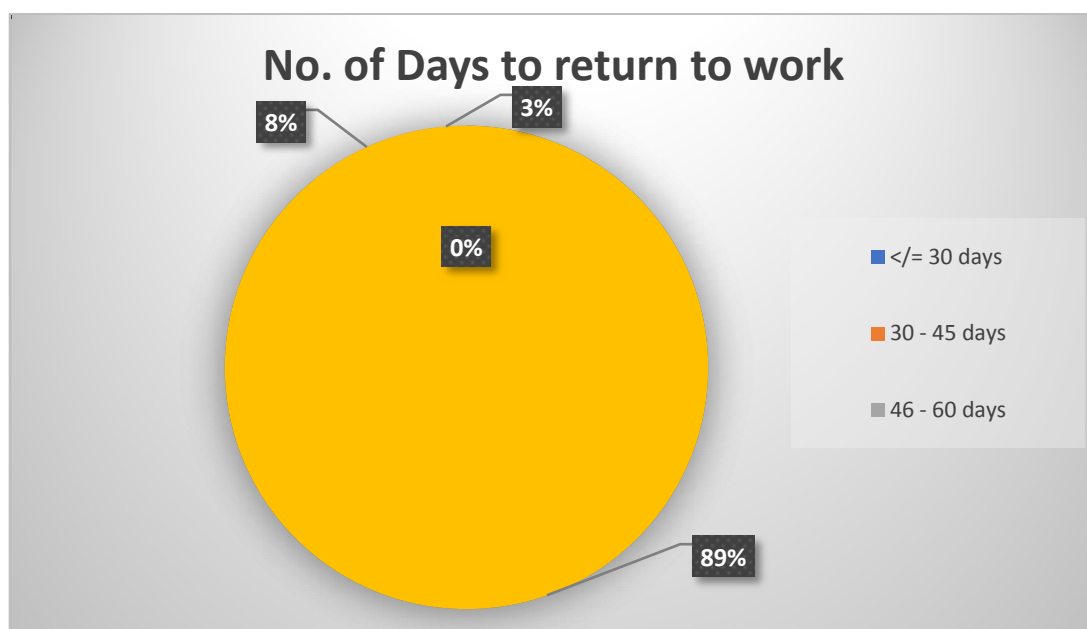
S No	Days	No. Of Patients
1	<= 7days	35
2	7-21 days	2
3	>21 days	0



The majority (95% - 35 patients) were discharged by 7 days , whereas 2 patients(5%) with wound infection were discharged within 21 days.

**9. Return to work:**

S No	Days to return	No. of patients
1	<= 30 days	33
2	31- 45 days	3
3	46 - 60 days	1



The majority (89% - 33 patients) returned to work within a month, whereas 3 patients took more than a month and 1 patient more than 45 days.

#### **10. Recurrence:**

**None of the patients had Recurrence of their Pilonidal disease at 6 months.**

### **VI. DISCUSSION**

- In our study comprising 37 patients with Chronic Pilonidal disease, most of the patients were in the age group of 18 – 40 years and most of the patients were males. As discussed above, Pilonidal disease is a disease of young, working males with excess body hair acting as a contributing factor.
- The average duration needed for Rhomboid excision of pilonidal disease and Limberg Flap in these patients was 85 mins.
- Majority of patients had Moderate pain at POD – 1, while all patients had only minor pain at POD – 5.
- None of the patients had haematoma collection and flap necrosis postoperatively. This implies that despite being an easy flap to perform, Limberg flap is a durable, well vascularized flap, that also has a suture line off of midline, conforming to the general principles of Pilonidal disease surgery.
- 2 patients had Superficial Surgical site infection. This is an acceptable rate for any surgery,
- All patients except these two patients with wound infection were discharged at 7 days. These 2 patients were discharged by 21 days.
- Most of the patients returned to work within 30 days. This is very important, as young males may be daily wage workers and sole breadwinners of their family and they need to return to their work as early as possible.
- None of the patients had recurrence in a follow up period of 6 months, implying that Rhomboid excision cures all existing pilonidal disease and Limberg Flap prevents further infection as it reduces the depth of the gluteal cleft and eliminates all risk factors.

### **VII. CONCLUSION**

Despite, many surgical procedures and approaches described for Chronic Pilonidal disease, treatment must be individualized to each patient according to their presentation. Also the importance of good personal hygiene can never be understated. Based on our study, it is safe to say that Rhomboid excision of Pilonidal disease and Limberg flap procedure in a single sitting is a safe, attractive and easy option with minimal complication rates. It can readily be afforded to patients with minimal morbidity and no reduction in QOL and earlier return to work and avoidance of future recurrent Pilonidal Disease.

### **REFERENCES**

- [1]. Shackelford's Surgery of the Alimentary Tract – Eight Edition ; Charles J. Yeo, - Chapter 153
- [2]. Bailey and Love's Short Practice of Surgery – 27<sup>th</sup> Edition – CRC Press
- [3]. Sabiston Textbook of Surgery – 21<sup>st</sup> Edition – Townsend; Beauchamp; Evers; Mattox
- [4]. Fischer's Mastery of Surgery – 7<sup>th</sup> Edition
- [5]. Farquharson's Textbook of Operative General Surgery – 10<sup>th</sup> Edition
- [6]. Bascom J. Pilonidal disease: origin from follicles. *Surgery*. 1980;87(5):567 – 572
- [7]. Bascom J, Bascom T. Utility of the cleft lift procedure in refractory pilonidal disease. *Am J Surg*. 2007;193(5): 606 – 609
- [8]. Karyadakis GE. New approach to the problem of pilonidal sinus. *Lancet*. 1973;2(7843): 1414 - 1415
- [9]. Davis KA, Mock CN, Versaci A et al. Malignant degeneration of pilonidal cysts. *Am Surg*. 1994;60(3): 200-204
- [10]. Bascom J. Pilonidal disease; long term results of follicle removal. *Dis Colon Rectum*. 1983;26(12):800-806
- [11]. Can MF, Sevinc MM, Hancerliogullari O, Yilmaz M, Yagci G. Multicenter prospective randomized trial comparing modified Limberg flap transposition, and Karyadakis flap reconstruction in patients with sacrococcygeal pilonidal disease. *Am J Surg*. 2010;200(3): 318 – 327
- [12]. Daphan C, Tekelioglu MH, Sayilgan C. Limberg flap repair for pilonidal sinus disease. *Dis Colon Rectum*. 2004;47(2):233-237
- [13]. McGuinness JG, Winter DC, O'Connell PR. Vacuum - assisted closure of a complex pilonidal disease. *Dis Colon Rectum*. 2003;46(2):274 – 276.