

# Limb Reconstruction System in Management of Compound Tibia Diaphyseal Fracture in Adults

Dr Om Prakash Kumar<sup>1</sup>, Dr Abhimanyu Kumar<sup>2</sup>, Dr Raju Kumar<sup>3</sup>.

<sup>1</sup>. Associate Professor, Department of Orthopaedics, NMCH, Patna.

<sup>2</sup>. Junior Resident, Department of Orthopaedics, NMCH, Patna.

<sup>3</sup>. Junior Resident, Department of Orthopaedics, NMCH, Patna.

## Abstract

**Background:** The fractures of the tibia are the most difficult fractures to treat effectively. The goal of operative management is to obtain anatomic realignment while providing enough stability to allow early motion. Hence this should be accomplished using techniques that minimize osseous and soft tissue devascularization. Compared to Illizarov LRS construct is less bulkier, easy to apply, post op dressing is easier and is less cumbersome to the patient.

**Methods:** A retrospective study conducted on the patients admitted between 2019-2021 on 12 patients admitted with compound tibia diaphyseal fracture and treated with LRS. 09 males and 03 females were included in this study with age ranging from 20-50 years. All patient had compound fractures of tibia.

**Results:** In our study, mean time of full weight bearing was  $12.04 \pm 2.09$  weeks and bone union time was  $24.67 \pm 3.3$  weeks. Pin tract infection was found in 2 (16%) cases. Loosening of pin was seen was observed in 3 (25%) cases. Joint stiffness was seen in 2 (16%) cases. ASAMI SCORE for bony outcome was excellent in 8 (66%) cases good in 2 (16%) cases and fair in 2 (16%) cases, for functional outcome excellent in 7 (58%) cases, good in 3 (25%) cases, fair in 1 (8%) case and poor in 1 (8%) case.

**Conclusion:** LRS is found to be a wonderful tool in the management of compound tibia fractures as primary and definitive mode because of its simplicity of application, adjustable geometry, good fracture stability, patient friendly and cost effectiveness.

Date of Submission: 03-09-2021

Date of Acceptance: 17-09-2021

## I. Introduction

High velocity trauma leading to open fractures is showing an increasing trend in today's motorized society. Open fractures are those in which a bone or joint structure is exposed to the environment due to disruption of soft tissues and overlying skin. Due to subcutaneous position of tibia, fractures of tibia more commonly results in open fracture than any other long bone. The frequency of open long bone fractures is approximately 11.5 per 100,000 persons per year. Majority of these fractures are open diaphyseal fractures of which 60% are Gustillo type III<sup>1</sup>.

- Usually a sequential protocol of treating compound fractures are initial debridement, external fixation and then intramedullary interlocking nail with reaming<sup>2</sup>.

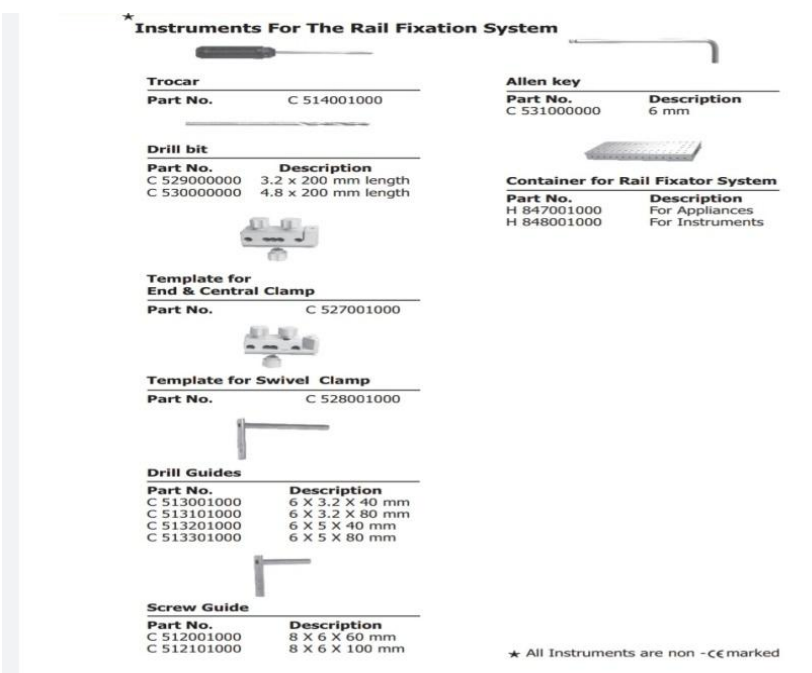
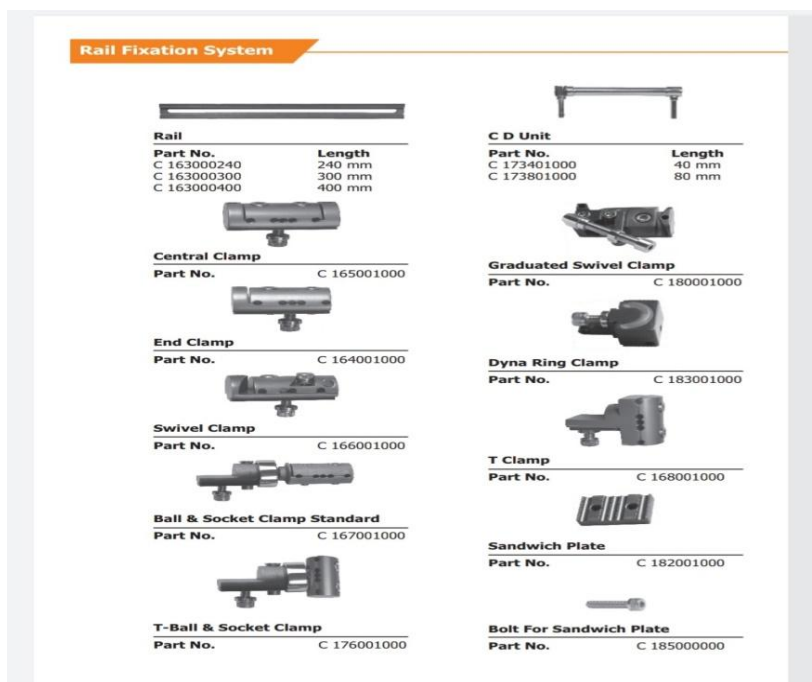
- The disadvantages of this technique are higher incidence of infection, need for several operative procedures, longer period of hospitalization and increased economic burden to the already poor patients<sup>3,4,5</sup>.

- External fixator is often the initial method of skeletal stabilization in these open tibial diaphyseal fractures. External fixation provides stable fixation, preserves soft tissue and bony vascularity, leaves wound accessible and reduces the amount of blood loss. Frame design provide uniplanar/multiplanar fixation and can be modified to allow axial compression with weight bearing, which stimulates fracture union<sup>6</sup>.

- The conventional AO external fixator can be now replaced with limb reconstruction system (LRS). Due to its anterior placement on tibia, LRS is more accessible to patient for pin tract care. LRS may be the better option in primary definitive management of compound tibia fracture in terms of initiation of early weight bearing, more rigid fixation. LRS has also been proven effective in treating the commonest complication following compound injury in tibia i.e non union, deformity correction, reconstructive procedure for gap nonunion using bone transport and limb lengthening<sup>7</sup>. LRS consists of an assembly of clamps (usually two or three) which can slide on a rigid rail and can be connected by compression distraction units to achieve bone transport.

- Hence to avoid application of multiple fixator system in same patient, LRS may prove single tool method to deal with primary definitive treatment tool to manage soft wound and bony discontinuity.

- Hence in this retrospective study we used LRS for primary definitive management of compound diaphyseal fractures for better fixation ,post operative effects on weight bearing , bone healing , functional recovery and rehabilitation to preinjury status



## II. Materials and methods

The present study was undertaken at Nalanda Medical College and Hospital ,patna from 2019-2021. All patients who were admitted through the orthopaedic department outdoor and orthopaedic department emergency during the above mentioned period with compound tibial diaphyseal fractures meeting the inclusion criteria.

❖ SAMPLE SIZE -12

❖ Inclusioncriteria

- Compound diaphyseal fractures of tibia type I,II,IIIA, IIIB, as classified by Gustillo Anderson grading.
- Compound diaphyseal fracture in the age group of 20-50 years.

3. Compound segmental fractures of tibia.
4. Patients willing to give written informed consent.
- ❖ Exclusion criteria
  1. Patients with closed fractures.
  2. Pathological fractures .
  3. Compound tibial fracture associated with ipsilateral fracture femur (floating knee).
  4. Very poor anaesthetic and general risk patients.
  5. Pediatric age group.

1. Each patient was subjected to thorough clinical and radiological examinations along with routine pathological investigations to rule out associated injuries and other co morbid conditions . Prophylactic administration of cephalosporins along with aminoglycosides and tetanus toxoid will be given . Unstable patients were stabilized first and salvageability of extremity will be assessed with mangled extremity severity score .Once the patient was hemodynamically stabilized primary wound debridement and thorough lavage with copious amount of saline was done . Primary splintage of fracture will be done by p.o.p and open fracture classified according to gustillo Anderson classification .

2. stable patients were subjected to all relevant preoperative investigations and were taken up for surgery as soon as they are fit for anaesthesia .

❖ **TECHNIQUE**

1. The patient was placed in supine position with bump under ipsilateral hip . C-arm will be placed on contralateral side . All patients were operated under spinal Anaesthesia .Once the patient is under the effect of spinal anaesthesia ,proper scrubbing with Betadine scrub (10%) and painting with Betadine solution (7.5%) done . Affected extremity were properly draped and then thorough debridement of wound and wound wash with 3-6 litres 0.9% normal saline was done **STEPS FOR LRS APPLICATION**

2. The proximal tapered threaded pins of LRS was inserted by longitudinal stab incision and separating the soft tissue down to the bone by blunt dissection on the anteromedial surface of tibia hence preventing the risk of neurological ,vascular or tendon injuries .

3. First the proximal most , tapered threaded pin was inserted by sequentially predrilling with an appropriate size bit , followed by manual insertion of the tapered threaded pin by the T handle ,which lowers the risk of thermal necrosis and pin loosening .The proximal pin was placed parallel to knee joint at least 15mm from the joint at the level of fibular head to avoid penetration of the joint capsule and avoid the pes tendons and patellar tendon . Then the distal most , tapered threaded pin inserted in the same manner 1cm above and parallel to ankle joint .

4. 3.The rod and assembly was connected over these proximal and distal pins maintaining the leg length and this definitive fixator was used as a guide to pass the rest of the pins . It was ensured that the rail is parallel to the long axis of of the bone and all the remaining screws on the bone , are in the same plane perpendicular to the long axis of tibia and parallel to the knee and ankle joints and alignment between tibial tuberosity and the second metatarsal . All tapered threaded pins was inserted under C-arm control so that not more than about 2mm could protrude beyond distal cortex . After putting all the pins and the fixator on the limb ,the pin holding nuts (clamps) were tightened .

5. In immediate post operative period , all patients were given limb elevation ,analgesics ,injections cefuroxime 1gm iv B.D with injection gentamycin 80mg iv bd with injection metronidazole 100cc iv tds for 5-14 days according to wound status . Repeat debridement was performed after 48 hours . All patient were taught quadriceps and hamstring strengthening exercises from second post operative day along with straight leg raising exercises to avoid joint contracture and muscle atrophy .

5. 5. Patients were followed up at monthly interval for a minimum of 6 months . Healing was defined radiologically by the presence of bridging callus . Union was defined clinically by the absence of pain and motion at fracture site . Final results for bone results and functional results was done using ASAMI score (Association for the study and application of the method of illizarov)

### **III. Results**

In the present study 12 cases of compound fractures of tibia were treated by limb reconstruction system as a definitive treatment . there were 9 male and 3 female patients ranging from 20-50 years of mean age 34 years . Higher incidence of compound fractures were seen in males RTA being the most common cause . in our study duration between injury and operation was between <12 hours in 3 ,12-24 hrs in 3 and >24 hours in 6 patients .

Among 12 patients 2 (16%)had grade 1 compound fracture , 3(25%) had grade II , 4(33%) had grade IIIA and 3(25%) had grade IIIB fractures .

Full weight bearing was achieved in 12.04±2.09 weeks and time for union was 24.67±3.3 weeks .

In our study pin tract infection was seen in 2(16%) , pin loosening in 3(25%) joint stiffness was seen in 2(16%). Delayed union , shortening and chronic osteomyelitis was seen in none of the patients . ASAMI score (Association for the study and application of the methods of Illizarov ) for bony outcome was excellent in 8(66%), good in 2(16%)and fair in 2(16%). Functional outcome was excellent in 7(58%) good in 3(25%) fair in 1 (8%) and poor in (8%).

#### IV. Discussion

Our study attempted to evaluate the results of LRS fixators in compound tibia fractures as a primary and definitive management .

LRS fixators provides easy accessibility for management of soft tissue injuries and early bone and soft tissue reconstruction significantly reducing the risk of infection , non union and amputation .

In our study mean age group of patients was 34 years with males accounting for 75% cases . this was in accordance to the study conducted by Thakur et al in 79 patients with mean age group of 38 years with male predominance (83.5%). Present study is also comparable to singh P , SINGH S K , GILL SPS et al with mean age of 35.5 years also to Mehtab et al , Beltsios et al and Shikari et al where mean age were 34.75 years ,36 years and 35.5 years respectively .

In this study RTA were the cause of injury in all cases . while in the study conducted by Adrover et al , rta was the major cause of injury in 81.9% cases where as in Thakur et al series 87.3%of patients with open fractures were caused by road traffic accidents.

In our study 4(33%) patients had Grade IIIA fractures and 3 ( 25%) had grade II fractures . It is comparable to the study by Tekan et al and fredrico Neto et al .

Mean bone union time in our study was 24.67±3.3 weeks which is comparable to studies of chandrprakash pal et al and Ajmera et al .

Results of bony and functional outcomes assessed by ASAMI score in our study were comparable to studies by Ajmera et al , patil et al and pal et al where they found excellent results in 76% , 67% and 68.5% respectively ; good results in 12%,25%and 18.75% respectively ; poor results in 8% , 4% and 2.5% respectively . in our study bony outcome was excellent in 66% , good in 16% patients and fair in 16% patients . Functional results were also comparable to above studies .

Characteristics		"n"	Percentage
Age(Mean = 34 yrs)	20-30	4	33%
	31-40	5	41%
	41-50	3	25%
Gender	Male	9	75%
	Female	3	25%
Mode of Injury	RTA	12	100%
Type of Fracture (Gustilo Anderson Classification)	I	2	16%
	II	3	25%
	III A	4	33%
	III B	3	25%
Time to Surgery	< 12	3	25%
	12-24	3	25%
	>24	6	50%

	Mean
Time of full Weight bearing	12.04±2.09 weeks
Time of Union	24.67±3.3 weeks
Follow up Period	6 MONTHS
Amount of Bone transport	
Secondary soft tissue procedures	

	"n"	Percentage
Pin tract infection	2	16%
Pin loosening	3	25%
Joint stiffness	2	16%

Delayed union	-	-
Non union	-	-
Shortening >2 cm	-	-
Chronic osteomyelitis	-	-

<b>Table 4: Bony and functional results as per ASAMI Score</b>		
<b>Bony outcome</b>	<b>“n”</b>	<b>Percentage</b>
Excellent	8	66%
Good	2	16%
Fair	2	16%
Poor	0	
<b>Functional outcome</b>		
Excellent	7	58%
Good	3	25%
Fair	1	8%
Poor	1	8%

## V. Conclusion

Limb reconstruction system is a very effective tool for management of compound tibia diaphyseal fracture as it allows ease of application, versatility, provides stronger fixation, allows early weight bearing and helps in early bone union. The fixator related complications are also much less. It is also a cost effective mode of treatment and also a simple technique with short learning curve compared to Ilizarov ring fixator.

## References

- [1]. Rajashekhara S, Dheenadayalan J, Devendra P, Ramesh P, Kulkarni GS, Babhulkar S. Open fractures. In textbook of orthopaedics and trauma. Vol 3. India: Jaypee; 2016. p.829-37
- [2]. Blachut PA, Meek RN, O'Brien PJ. External fixation and delayed intramedullary nailing of open fractures of the tibial shaft. A Sequential protocol. J Bone Joint Surg Am. 1990;72(5):729-35
- [3]. Reuss BL, Cole JD. Effect of delayed treatment on open tibial shaft fractures. Am J Orthop. 2007;36(4):215-20
- [4]. McGraw JM, Lim EV. Treatment of open tibial shaft fractures. External fixation and secondary intramedullary nailing. J Bone Joint Surg Am. 1988;70(6):900-11
- [5]. Maurer DJ, Merkow RL, Gustilo RB. Infection after intramedullary nailing of severe open tibial fractures initially treated with external fixation. J Bone Joint Surg Am. 1989;71(6):835-8.
- [6]. ST Canale, Frederick M Azar; James H Beaty; Willis C Campbell. Fractures of lower extremities. 13<sup>th</sup> edition in; Campbell's operative orthopedics; 2017. pp.2752-55
- [7]. Ajmera A, Verma A, Agrawal M, Jain M, Mukherjee A. Outcome of limb reconstruction system in open tibial diaphyseal fractures. Indian J Orthop. 2015;49(4):429-35
- [8]. Hiranya Kumar Seenappa, Manoj Kumar Shukla, Muralidhar Narasimhaiah. Management of complex long bone nonunions using limb reconstruction system. Indian J Orthop. 2013;47(6):602-607
- [9]. Chandra Prakash Pal et al. Comparative study of the results of compound tibial shaft fractures treated by Ilizarov ring fixators and limb reconstruction system fixators. Chinese J Traumatol. 2015;18:347-51
- [10]. Tekin AC, Daygili MS, Adas M, Cabuk H, Arsalan SM, Dedeoglu SS, et al. Outcome of type 3 open tibial diaphyseal fractures managed with a limb reconstruction system: analysis of a 49 patient cohort. Med Princ Pract. 2016;25:270-5
- [11]. Patil M. Definitive management of open tibia fractures using Limb Reconstruction System. J Clin Diagnosis Res. 2016;10(7):1-4
- [12]. Mahajan NP, Mangukiya HJ. Extended use of limb reconstruction system in management of compound tibia diaphyseal fracture as primary and definitive tool. Int J Res Orthop. 2017;3:1157-64
- [13]. Singh P, Singh SK, Gill SPS. Management of compound fractures of tibia by Limb reconstruction system (LRS) | Journal of Bone and Joint Disease [Jan-April 2020];35(1):29-34
- [14]. Gustilo RB, Mendoza RM, Williams DN. Problems in the management of type III open fractures. J Trauma. 1984;24:742
- [15]. Piwani M, Bhutto IA, Ahmed I. Evaluation of AO external fixator in the management of open diaphyseal fracture of tibia. Gustilo type IIIA and IIIB. Gomal J Med Sci. 2015;13(1):66-9.
- [16]. Tornetta P, Bergman M, Watnik N, Berkowitz G, Steyer J. Treatment of grade IIIb open tibial fractures. A prospective randomized comparison of external fixation and non-reamed locked nailing. J Bone Joint Surg Br. 1994;76:13-9
- [17]. Singh J, Dhillon MS, Dhatt SS. Single stage "Fix and Flap" gives good outcomes in grade 3b/c open tibial fractures: A Prospective Study. Malays Orthop J. 2020;14(1):61-73.

Dr Om Prakash Kumar, et. al. "Limb Reconstruction System in Management of Compound Tibia Diaphyseal Fracture in Adults." *IOSR Journal of Dental and Medical Sciences (IOSR-JDMS)*, 20(09), 2021, pp. 36-40.