

Our Experience with Oculosporidiosis-A Retrospective Study Report

Dr. (Asso. Prof.) Sarita Panda, Dr. Rutayani Dash, Dr. A. Bhoi, Dr. S.K. Padhi

Abstract

Background-Rhinosporidiosis is a localized infection of mucous membrane caused by Rhinosporidium seeberi. Ocular involvement occurs in 10% of infections. Common sites of ocular involvement includes conjunctiva, lacrimal sac, sclera & lid. As it thrives in hot and tropical climate its endemicity found in our locality.

AIM OF THE STUDY-To study the risk factors, modes of presentation, clinical features & treatment outcomes of oculosporidiosis.

MATERIAL&METHOD- Retrospective study conducted in dept. of ophthalmology & dept. of pathology for a period of 2 years. All oculosporidiosis cases both clinically diagnosed & confirmed by histopathology examination were included. Among total 68 cases, 78% (53 males) & 22% (15 females). They presented with symptoms of mass in the eye & adenexa 34%, along with foreign body sensation 34%, watering 30%, bloody discharge 2% & photophobia 4% cases. The sites of presentation-conjunctiva 90% & adenexa 10% cases. Excision done with thermo-cautery in all conjunctival cases & dacryocystectomy in adenexal cases. The recurrence noted in 4 cases. Overall recurrence rate was 5.9%. Conjunctival recurrence rate was 1.64% and lacrimal sac recurrence rate was 42.8%. The lacrimal sac recurrence rate was higher.

CONCLUSION- oculosporidiosis mostly occurs in rural areas with history of pond bathing in our locality. So public awareness plays utmost importance in prevention & recurrence of this disease. Thermo-cautery proves to be effective in preventing recurrence in almost all cases.

Keywords: Rhinosporidiosis, oculosporidiosis, DCT (Dacryocystectomy).

Date of Submission: 20-08-2021

Date of Acceptance: 05-09-2021

I. Introduction

Rhinosporidiosis is a chronic indolent infection caused by the protistan parasite *Rhinosporidium seeberi*¹. The Parasite is found in aquatic environment mainly in geographical location where the water is stagnant like, ponds.² Infection is acquired by taking bath in these water bodies. The infection is endemic in hot tropical climatic zones as in South India and Srilanka⁶. Sporadic occurrence has been reported from West Bengal, Chhattisgarh, Raipur, Rajasthan, Odisha, Bihar and Maharashtra. The state of Odisha lies on eastern coast of India and comes under tropical zone. Here we report 68 cases of oculosporidiosis in a tertiary care hospital in Southern Odisha. Ocular involvement occurs in 10% of *Rhinosporidium seeberi* infection.^{3,4} The organism enters through nasal mucosa, conjunctiva and rarely genital mucosa. It presents as Polypoidal strawberry like masses in eyes, nasal cavity and nasopharynx in both sexes. The sites of ocular involvement include conjunctiva, lacrimal sac, sclera and lid.⁵ Treatment is generally done by complete excision of the mass.

II. Materials And Methods

We studied 68 patients presenting with polypoidal growth in the eye and its adenexal area including 53 males and 15 females. The age ranged from 0-60 years belonging to rural, semi urban and urban areas and history of pond bathing was taken. It was a retrospective study from March 2019 to February 2021 and the study area being Department of Ophthalmology and Department of Pathology in SLN Medical College & Hospital. Our aim of the study was to study risk factors, laterality, residence and modes of presentation, clinical features and treatments outcomes of Oculosporidiosis. The inclusion criteria were all clinically diagnosed and histopathological confirmed Oculosporidiosis. The exclusion criteria included patients with doubtful ocular masses and histologically confirmed as other diseases, with nasal pathologies. In our study all cases presenting with polypoidal, pink, soft, vascular masses with grey white spots on the surface were clinically diagnosed as conjunctival rhinosporidiosis Fig-I, Fig-II. None of the patients complained of decrease of visual activity. However, the diagnosis in all cases were confirmed histo-pathological study. The histo-pathological study reported the presence of fibro-cellular elements covered by proliferating stratified epithelium containing numerous sporangia of all sizes Fig-IV. Surgical intervention was done by total removal of all the masses with

proper cautery of the bases. The patient with rhinosporidiosis involving the lacrimal system Fig-III underwent dacryocystectomy (DCT).

III. Results

All the medical reports of 68 patients studied and all the data were analysed. We found majority of patients that is 80% (54 in numbers) belonged to rural area and 17% (12 in numbers) belonged to semi-urban area and 5% (2 in numbers) belonged to urban area. The male/female ratio was found out to be 3.5:1, being males 78% (53 in numbers) and 22% females (15 in numbers). We noted rhinosporidiosis of eye and its adnexa were unilateral and right and left eye were affected in almost equal number in all cases. The condition was more common in patients belonging to 10-40 years. Rhinosporidiosis of the conjunctiva presented with polypoidal growth in different sites like lid, sclera, canaliculus and lacrimal sac area. In 42 cases the polypoidal growth was seen immersing from upper and lower palpebral fissure. In 1 case the polypus was found on the bulbar conjunctiva. In 9 cases it was seen protruding from upper fornix. In 7 cases it was seen in sulcus subtarsalis. In 2 cases were found in canalicular region. In 7 cases the lesion was found in lacrimal sac region. Hence 90% of rhinosporidiosis that is 61 in number involved conjunctiva and 10% that is 7 cases had lacrimal sac affection. These polypoidal growth were soft and pink in colour resembling strawberry and the surface was dotted with minute white spots and bled easily on touch and commonly seen on the mucus surface. In 7 cases lacrimal sac was infected and these patients reported with swelling of the lacrimal sac region which extended to the lower lid. The swelling was painless, soft, fluctuating to touch with history of epistaxis with partial obstruction in the lacrimal passage. All the patients with conjunctival involvement presented with symptoms of foreign bodies sensation 34% (23 in numbers) and watering 30% (20 in numbers) and photophobia 4% (3 in numbers). Patients with lacrimal sac affection presented with bloody discharge 27% (2 in numbers). All 60 cases gave history of pond bathing that is 88%. All conjunctival growths were excised with proper cauterization of the base. On opening the lacrimal sac we found pink vascularized growth with finger like projections and we performed dacryocystectomy in all cases taking special care to avoid spilling of spores. We encountered severe bleeding in all the cases. In 4 cases we recorded recurrence during the follow up period of 18 months out of which 3 sac cases recurred and 1 conjunctival case with bulbar involvement recurred. So, we found the overall recurrence rate was 5.9%. Conjunctival recurrence rate was 1.64% and lacrimal sac recurrence rate was 42.8%. The lacrimal sac recurrence rate was higher.

Conjunctival Involvement

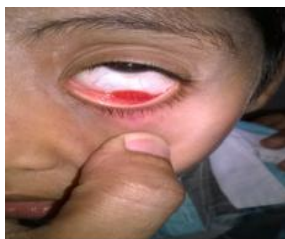

Fig I

Lacrimal Sac Involvement

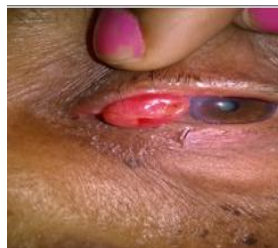

Fig II

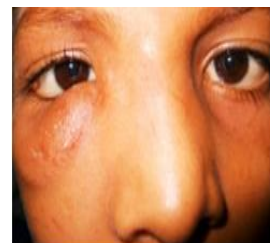

Fig III

HP Study

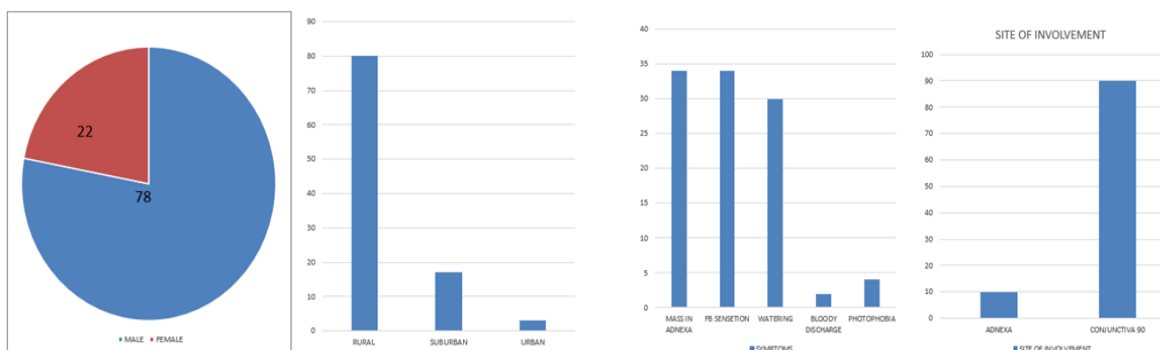
Histopathological (HP) study showing fibrous stroma with several thick wall sporangia at different stages of maturation containing numerous endospores.

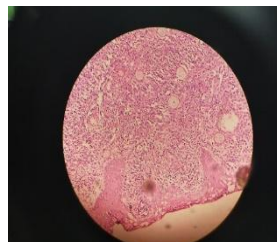

Fig IV

IV. Observation & Results

Clinical Profile of Patients with Oculosporidiosis				
Age in years	No of Males	No of Females	Conjunctival Involvement	Lacrimal sac Involvement
0-10	1	1	2	0
11-20	15	5	18	2
21-30	20	6	22	4
31-40	12	2	11	1
41-50	4	1	7	0
51-60	1	0	1	0
Total	53	15	61	7



V. Discussion

Rhinosporidiosis is a Chronic granulomatous disease caused by *Rhinosporidium seeberi* (first discovered by Seeber) categorised as microorganism protist of the class Mesomycetozoea through ribosomal DNA analysis. This fungus begins its lifecycle as a parasite measuring 8µ and grows by nuclear division to the size of 200 to 300µ and contains 4000 nuclei, which forms 16,000 spores. The mature parasite that is sporangium presents a double-contoured chitinous envelope with a germinal spore through which spores are discharged.¹⁵ The mode of transmission of the disease occurs through traumatised epithelium (transepithelial infection) when one comes in contact with rhinosporidiosis contaminated water/soil that is generally found in ponds (stagnant water),^{14,15}. The pond contains fish and weeds. So, it is possible that a close relationship appears to exist between *Ichthyosporidium* and *Rhinosporidium*, that the latter may also be a parasite or saprophyte of fish and man, equines and cattle obtain the infection through water in which fish, harbouring the parasite live.⁷ The Rhinosporidial growth are categorized into 3 types: Pedunculated, Sessile, Partially Pedunculated and Partially Sessile.⁷ Large lesions tend to recur and it is difficult to eradicate the infection after excision.

Summary of discussion in comparison with other studies done by DR R.K. Chowdhury et al published in *Indain Journal of Ophthalmology* and E.T. Kuriakose et al published in *British Journal of Ophthalmology* is given in the following table.

JOURNAL	BRIT.J.O[N=25]	IJO[2007][N=54]	OUR STUDY[N=68]
COMMON AGE GROUP	15-39 years	children < 10 years	10-40 years
VISUAL ACUITY	↓ VA in 1 case	Normal in all cases	Normal in all cases
SEX PREDOMINANCE	male	male	male
Ratio (M:F)	11.5:1	3:1	3.5:1
LATERALITY	Not Mentioned	Unilateral	Unilateral
SITE OF INFECTION	conjunctiva-64% lacrimal sac-24% sclera eyelid	conjunctiva-91% lacrimal sac-9%	conjunctiva-90% ocular adnexa-10%
PRESENTING SYMPTOMS	Mentioned	Conjunctiva lesion described but lacrimal sac lesion not mentioned	mass ff/b fb sensation,bloody discharge,watering,p hotophobia
RESIDENCE	Not Mentioned	Not Mentioned	most common in rural compared to semi urban, urban
MODE OF MANAGEMENT	simple excision of mass & silver nitrate cautery simple excision of mass & silver nitrate cautery	Excision of conjunctival mass & DCT in lacrimal sac affection	Excision of conjunctival mass & thermo cautery DCT in lacrimal sac affection.
Follow up Period	Not Mentioned	1 year	18 months
RECURRENCE	2	no recurrence	4
H/O OF POND BATHING	Not Mentioned	Present 90%	Present 88%

Discussion Table

Our study shows consistent findings with other studies except that we have added residence factor belonging to rural, semi urban and urban areas. Thermo cauterisation was done to all cases after excision of mass. Our follow up period was around more than 1 year as compared to other studies. We had 4 recurrences out of which 1 bulbar mass recurred and 3 lacrimal sac masses recurred. The larger bulbar mass may be cause of recurrence. In lacrimal mass lesion cause of recurrence may be due to profuse bleeding and spillage of spores during DCT. As our follow up period was longer so recurrence was noted. In our study there is a definite relationship with pond bathing as the fungus thrives in the stagnant water and causes affection in ocular region and adnexa.

VI. Conclusion

Proper Thermo Cauterisation along with meticulous simple excision proved to be very affective in our experience. During DCT we took extreme care to avoid spilling of spores which prevented recurrence in majority of cases. Rhinosporidiosis still continues be a common health problem in the rural areas, where pond bathing and agricultural exposure being common predisposing factors. Public awareness, eye hygiene and good bathing habits, avoiding contaminated pond water plays utmost importance in prevention & recurrence of this disease.

Reference

- [1]. Fredricks DN, Jolley JA, Leep PW, Kosek Jc, Relman DA. Rhinosporidium seeberi: a human pathogen from a novel group of aquatic protistan parasites. Emerg Infect Dis 2000; 6:273-82.
- [2]. Prakash M, Johnny JC. Rhinosporidiosis and the pond. J Pharm Bioallied Sci 2015; 7:S59-62.
- [3]. Cohen J, Carvalho RC, Guimaraes R, Curx AA. Oculosporidiosis. Arch Ophthalmol 1997; 115:1304-1.
- [4]. Arora R, Ramachandran V, Raina U, Mehta DK. Oculosporidiosis in Northern India. Indian Pediatr 2001;38:540-3.
- [5]. Ratnakar C, madhavan M, Sankaran V, Veliath AJ, Majumder NK, Rao VA. Rhinosporidiosis in Pondicherry. J Trop med Hug 1992; 95:280-3.
- [6]. Sood NN, Rao SN. Rhinosporidium granuloma of conjunctiva. Br J Ophthalmology 1967;51:61-4.
- [7]. Allen, F.R.W.K and Dave M.L. the treatment of rhinosporidiosis in man based on study of sixty cases. Ind. Med.Gaz 71:376-395
- [8]. Ashworth, j.h: on rhinosporidiosis seeberi(wernicke , 1903) with special reference to its sporulation and affinities. Trans Roy.Soc.Edin.53:part 2, 301-342
- [9]. Karunaratne, W A E: Rhinosporidiosis in man: university Of London(1964)
- [10]. Mandlik.G.S: A record of rhinosporidial polyp with observations on mode of infection. Ind Med Gaz. 72:143-147
- [11]. Rambo V.C:Rhinosporidiosis of the lacrimal sac , all-India Ophth. Soc 10;72-76
- [12]. Wright , R E: Rhinosporidiosis kinealy of the conjunctiva. Ind Med Gaz 57: 82-83 (1922)
- [13]. E.T. Kuriakose, Brit. J. Ophthal.(1963) 47,346., Government Ophthalmic Hospital, Trivandrum, S. India.
- [14]. Ravindra K Chowdhury, Sharmistha Behera, Debendranath Bhuyan; Gunasagar Das, Indian J Ophthalmol 2007; 55:299-301.
- [15]. Jacob P, Rose JS, Hoshing A, Chacko G. Tectonic corneal graft for conjunctival rhinosporidiosis with scleral melt. Indian J Ophtalmol. 201; 59:251-3.
- [16]. Kaimbo KW, Parys-Van GR. Conjunctival rhinosporidiosis: a casereport from a Congolese patient. Bull SocBelgeOphtalmol. 2008;(309-310):19-22.