

Purtscher-like Retinopathy in Systemic Lupus Erythematosus. Case Report.

Washington Chasipanta¹, Francisco Anda²

¹(Post graduate, Ophthalmology, Central University, Ecuador)

²(Post graduate, Ophthalmology, Central University, Ecuador)

Abstract: We report a 16-year-old female patient diagnosed 2 months ago with Systemic Lupus Erythematosus, hospitalized with anasarca, who also presented a progressive and painless decrease in visual acuity in both eyes for 1 and a half months of evolution, for which she was evaluated in the department of Ophthalmology at a third level Pediatric Hospital in Quito – Ecuador, where she comes through with signs compatible with Purtscher like retinopathy in both eyes in the posterior pole.

Key words: Systemic Lupus Erythematosus, decrease, visual acuity, Purtscher like retinopathy, posterior pole.

Date of Submission: 26-07-2021

Date of Acceptance: 11-08-2021

I. Introduction

Systemic lupus erythematosus (SLE) is a chronic, multisystemic autoimmune disease with unknown etiology that mainly affects women of childbearing age. Several factors are variably intertwined, such as environmental stimuli, genetic predisposition, and alterations of the immune system that mediate the involvement of various organs. (1)

There are several ocular complications of SLE that are associated with active systemic disease. The pathogenetic mechanism of retinal damage due to SLE has been attributed to an immune complex-mediated vasculopathy (2), this can occur in approximately 25 to 30% of cases and can lead to blindness. The two main forms of this retinopathy are large retinal vessel occlusion and Purtscher like retinopathy. (3)

Purtscher like retinopathy is a rare and serious ocular complication of SLE. The diagnosis is based on the medical history and fundus findings. (3)

II. Case Report

A 16-year-old female patient with a 3-month evolution of SLE with regular clinical management, who developed anasarca and was hospitalized for lupus nephropathy in a third-level pediatric hospital in Quito-Ecuador. The described condition was accompanied by a painless decrease in visual acuity in both eyes of 1 and a half months of evolution, for which reason the Ophthalmology service was consulted where the physical examination found eyelid edema in both eyes, uncorrected visual acuity in the right eye of 20/150 and in the left eye 20/100 + 1, the slit lamp examination was normal in both eyes. Transparent media, round papilla with defined margins, 0.2 cup, neuroretinal ring with slight pallor, central emergence vessels, tortuosity of arterial and venous vessels, Purtscher flecken, spots were found in the fundus of both eyes. cottony white and few peripapillary flame hemorrhages, radial lipid exudates in the macula and applied retina (Fig. 1).

The macular OCT (Fig. 2) showed thickening of the nerve fiber layer (CFN) at the level of the cottony white spots, hyperreflectivity areas in the external plexiform layer (EPC) at the level of the lipid deposits of the macula. The OCT of the optic nerve (Fig. 3) did not show alterations.

Clinical management was carried out with systemic corticosteroids, antihypertensives and diuretics, pulses of methylprednisolone, carvedilol 6.25 milligrams orally every 12 hours, amlodipine 5 milligrams orally every 12 hours, prednisone 60 milligrams orally every day, furosemide 40 milligrams IV each day and hydroxychloroquine 200 milligrams orally each day.

We carried out a new ophthalmological check-up at 15 days where uncorrected visual acuity was found in the right eye of 20/50 and in the left eye of 20/40. The fundus showed a slight pallor of the neuroretinal ring and a reduction in the size of the peripapillary cottony white spots as well as the macular lipid exudates was evidenced. (Fig. 3). Refraction under cycloplegia showed in the right eye: N -1.50 * 175 (20/30) and for the left eye -0.25-0.75 + 5 (20/30).

Subsequently, she presented a good evolution of her systemic pathology with strict clinical follow-up, we carried out a new control at 45 days where we observed an uncorrected visual acuity of the right eye of 20/50 and for the left eye of 20/25. In the fundus of the eye, the optic nerve showed a greater pallor than previously

described and there was a greater reduction in peripapillary white cotton wool spots and also in macular lipid exudates in both eyes.

Fig. 1 Fundus photograph: Purtscher like retinopathy A and B day zero, C and D day 15, E and F day 45.

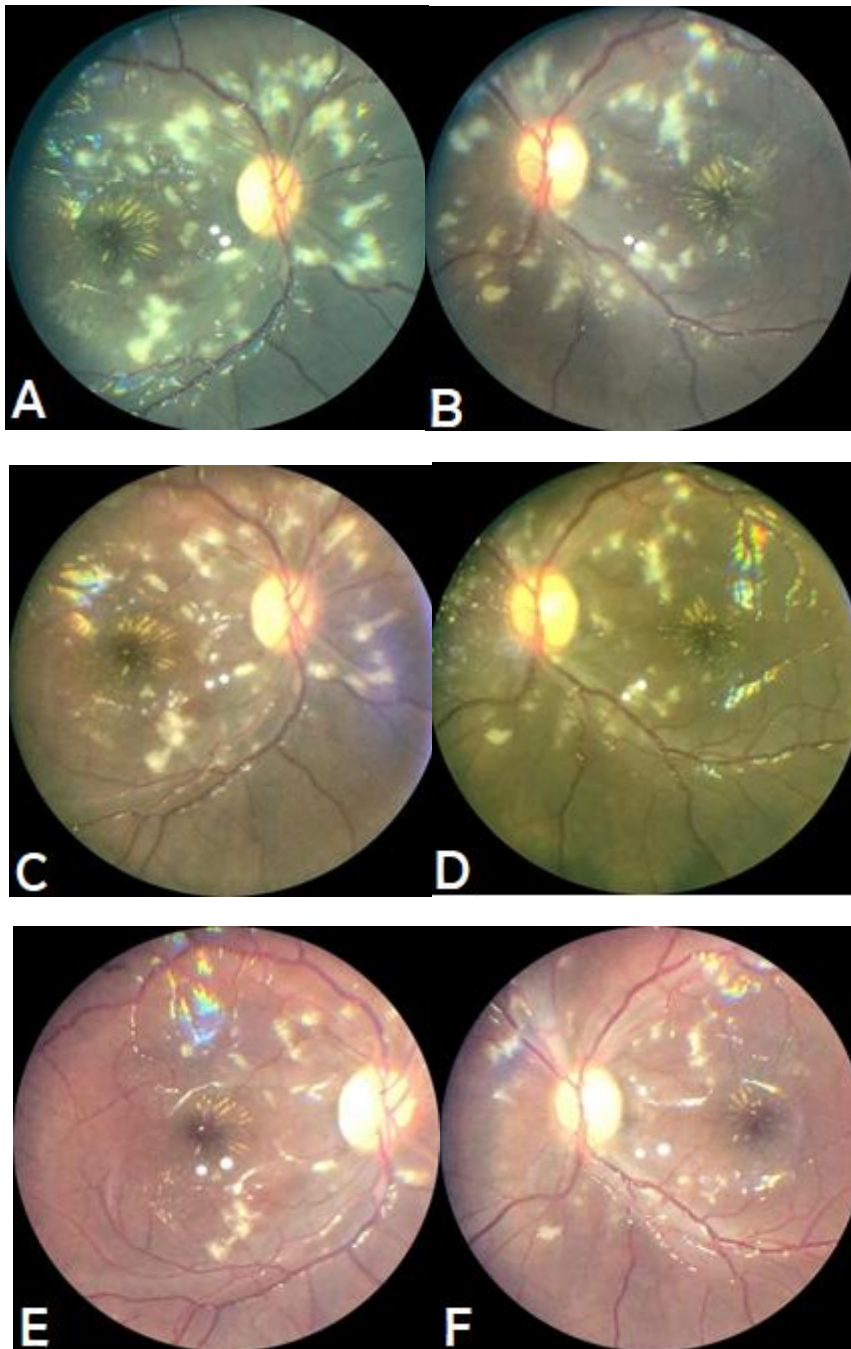


Fig. 2 Macular OCT: CPE with hyperreflective areas in relation to lipid deposits (red arrow), sectorial thickening of the CFN, greater at the level of the white-algodonous spots (yellow arrow)

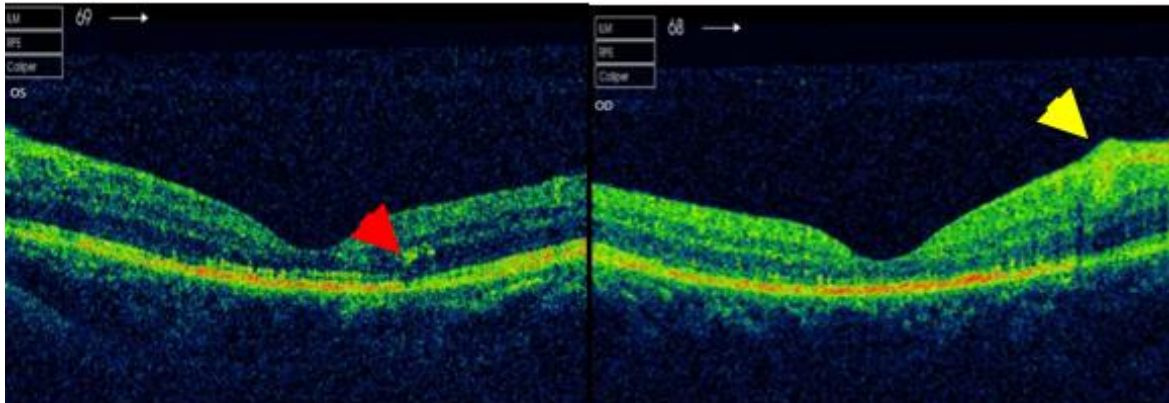
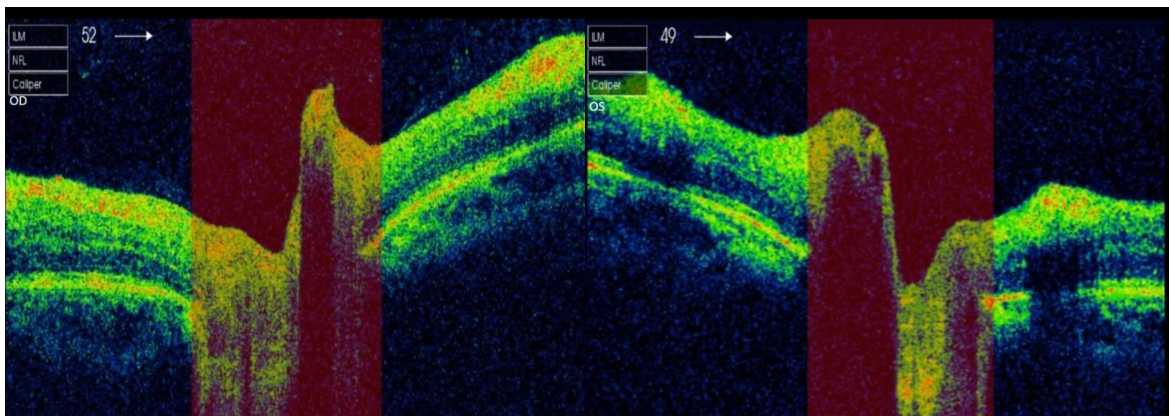


Fig. 3 Optic nerve OCT without alterations.



III. Discussion

In 1910 Otmar Purtscher described this retinopathy in patients suffering from sudden visual loss after severe head trauma, characterized by cotton-wool spots, retinal whitening, and superficial retinal hemorrhages. In this way, it is described that Purtscher retinopathy is mainly related to a traumatic etiology, which include: cephalic or thoracic compression, long bone fracture and crush injuries. Several cases with similar clinical characteristics have been described in patients with acute pancreatitis, collagen vascular diseases, renal failure, and HELLP syndrome, as well as in patients with multiple myeloma unrelated to trauma. These cases are grouped as Purtscher like retinopathy (4)

The pathogenesis is still unknown; however, hypotheses have been made about various mechanisms. The most widely accepted theory is precapillary arteriolar occlusion caused by microembolization and microvascular infarcts of the retinal nerve fiber layer. (4)

Purtscher like retinopathy is characterized mainly by Purtscher flecken, cotton wool spots, a few or moderate numbers of retinal hemorrhages, and occasionally optic disc edema. Purtscher flecken is a typical area of internal retinal whitening with a clear demarcation line between the adjacent normal retinal vessels and the affected retina. (5)

Purtscher like retinopathy could be present as the initial manifestation of SLE. Most of cases have been described in patients previously diagnosed with SLE. (5)

There is a more serious form of SLE retinopathy reported. This form of SLE retinopathy, although rare, has a poorer visual prognosis. The process is an arteriolar occlusion with a lack of extensive capillary perfusion. Following extensive ischemia, neovascularization may develop with fibroproliferative membranes causing traction retinal detachment or vitreous hemorrhage. (6)

The diagnosis is clinical by finding the characteristic lesions in the fundus; there is no specific treatment, and its prognosis depends on the severity of the disease (7)

Fluorescein angiography demonstrates loss of dye from the retinal capillaries, arterioles and venules. (8)

The involvement of multiple systems and the heterogeneous nature make treatment of SLE difficult, however, the general goals of therapy are to prevent relapses and induce and maintain remission of the disease. Precise management requires a team that may include specialists in the fields of nephrology, dermatology, rheumatology and ophthalmology. Treatment strategies for SLE include systemic corticosteroids, nonsteroidal anti-inflammatory drugs, hydroxychloroquine, immunosuppressive therapy, and biologics. (9)

Local treatment is also important in the treatment of intraocular inflammation. (9)

Regarding the treatment of Purtscher like retinopathy, there are no defined guidelines. Apart from the treatment of the systemic disease, many reports of treatment with high doses of intravenous steroids have shown good results. (10)

IV. Conclusion

Our report shows a young patient with a recent diagnosis of SLE who debuted with progressive edema until reaching anasarca and positive markers for lupus nephropathy who developed painless visual deficit in both eyes with signs in the posterior pole compatible with Purtscher like retinopathy and macular star in both eyes. With treatment and stabilization, this alteration showed spontaneous resolution, however the patient developed optic nerve pallor suggestive of optic atrophy.

Ocular involvement with retinal whitening, retinal hemorrhages, and multiple cotton wool spots with macular edema may lead to a misdiagnosis, if a complete laboratory investigations and systemic examination are not carried out under a multidisciplinary approach.

Ophthalmologists, internists, immunologists and rheumatologists must know the ocular manifestations of SLE, because these could be the initial presentation of the disease and in the same way, a late diagnosis and the consequent late start of adequate treatment can lead to permanent visual impairment.

References

- [1]. Dammacco, R. (2018). Systemic lupus erythematosus and ocular involvement: an overview. *Clinical and Experimental Medicine*, 18(2), 135–149.
- [2]. Kunavisarut, P., Pathanapitoon, K., & Rothova, A. (2016). Purtscher-like Retinopathy Associated with Systemic Lupus Erythematosus. *Ocular Immunology and Inflammation*, 24(1), 60–68.
- [3]. Kammoun, S., Frikha, F., Sellami, D., Ben Amor, S., Snoussi, M., Ben Salah, R., ... Feki, J. (2018). La rétinopathie lupique : à propos de 7 cas. *La Revue de Médecine Interne*, 39, A211.
- [4]. Wu, C., Dai, R., Dong, F., & Wang, Q. (2014). Purtscher-like retinopathy in systemic lupus erythematosus. *American Journal of Ophthalmology*, 158(6), 1335-1341.e1.
- [5]. Palkar A., Hossain M. , Majumder P. (2018). Purtscher-like retinopathy as presenting manifestation of systemic lupus erythematosus following high-grade fever with myalgia and arthralgia. *Indian Journal of Ophthalmology*, 66(9), 1317-1319.
- [6]. Cruz F., Chan I., Tee Ch., Gulay C., Dans L., Otadoy-Agustin J., Recto M. (2009). Retinopathy in a patient with systemic lupus erythematosus. *Philippine Journal of Ophthalmology*, 34(2), 66-69
- [7]. Torrente-Nieto, A., Gómez-Resca, M., & Castro-Guardiola, A. (2018). Purtscher-like retinopathy and systemic lupus erythematosus. *Medicina Clinica*, 151(12), 504–505.
- [8]. Alahmadi, R. M., Hashim, R. T., Almogairin, S. M., & Al-Asrar, A. M. A. (2016). Purtscher-like retinopathy as a first presentation of systematic lupus erythematosus. *Annals of Saudi Medicine*, 36(1), 85–88.
- [9]. Silpa-Archa, S., Lee, J. J., & Stephen Foster, C. (2016). Ocular manifestations in systemic lupus erythematosus. *British Journal of Ophthalmology*, 100(1), 135–141.
- [10]. Rathod, A. G. (2020). A curious case of Purtscher's-like retinopathy. *Indian Journal of Clinical and Experimental Ophthalmology*, 4(1), 157–160.

Washington Chasipanta, et. al. "Purtscher-like Retinopathy in Systemic Lupus Erythematosus. Case Report." *IOSR Journal of Dental and Medical Sciences (IOSR-JDMS)*, 20(08), 2021, pp. 23-26.