

# Anatomical and congenital variations of human dry sternum bone: its embryogenesis and clinical implications

Santosh Kumar<sup>1\*</sup>, Makardhaj Prasad<sup>1</sup>

Department of Anatomy Shahid Nirmal Mahto Medical College, Dhanbad India 826005

\*Corresponding Author: Dr. Santosh Kumar

Designation: Tutor, Department of Anatomy

Shahid Nirmal Mahto Medical College, Dhanbad, Jharkhand, India 826005

## Abstract

**Background:** The sternum is one of the skeleton parts with frequently detected variation in cross-sectional images or autopsy series. The anatomical or congenital variations of the sternum in the anterior chest wall may involve malignancies, injuries or severe traumas. The aim of the study was undertaken to evaluate the incidence of anatomical and congenital variations of human dry sternum bones.

**Methods:** This study was carried out on 120 dry human sternum bones irrespective of age and sex at Department of Anatomy, Shahid Nirmal Mahto Medical College, Dhanbad, Jharkhand. All the sternum bones were macroscopically inspected for the anatomical and congenital variations of human dry sternum bones. Photographs of the anatomical and congenital variations were taken for proper documentation.

**Results:** Complete sternal foramina in the body of the sternum were noted in 9 bones (7.5%), with an average vertical diameter of 17mm and transverse diameter of 16mm (The highest vertical diameter of 19mm and transverse diameter of 17mm was noted); Incomplete sternal foramina in the body of the sternum were noted in 4 bones (3.3%); Complete sternal foramina in the xiphoid process of the sternum were noted in 7 bones (5.8%) with an average vertical diameter of 6mm and transverse diameter of 8mm; Unusual complete sternal foramina in the body and incomplete sternal foramina in the xiphoid process of the sternum were noted in 8 bones (6.6%); Very rare longer xiphoid process (7.3 cm) with complete sternal foramina was noted in 7 bone (5.8%); Unusual Longer xiphoid process with an average length of 6.7cm with sharp bifid ends was noted in 8 bones (6.6%).

**Conclusions:** The knowledge of existence of anatomical variants and congenital foramina of sternum and xiphoid process found in our study is essential, especially for bone marrow sampling, radiology (X - ray, CT, MRI, and USG) reporting, pathology autopsy and forensic medicine post-mortem reporting and ptoacupuncture practice to avoid complications during various surgical procedures.

**Keywords:** Acupuncture, Stern brae, Sternum, Sternal foramina, Xiphoidalgia

Date of Submission: 10-08-2021

Date of Acceptance: 25-08-2021

## I. Introduction

The sternum or breastbone is a long vertical flat axial bone forming the anterior part of thoracic skeleton and thus helps to protect vital organs like heart, lungs and major blood vessels. The sternum average length in the adult is about 17cm and consists of three parts a cranial manubrium, an intermediate body and a caudal xiphoid process. The manubrium is broad and joins the body and forms projecting sternal angle or angle of Louis. The body or Gladiolus is the longest part of the sternum and the xiphoid process is a thin sword-shaped process and is the smallest and most variable part of the sternum; its caudal end is related to the central tendon of the diaphragm and inferior border of the heart. The anatomic or congenital variations in the anterior chest wall particularly sternum may involve malignancies, injuries or severe traumas. Congenital sternal foramina and clefts are openings or defects frequently manifesting at the inferior parts of the sternum which may leads to fatal cardiac tamponade and can be both a clinical, radiological and medico-legal challenge when encountered. Awareness of a sternal foramen is important in acupuncture practice and sternal marrow aspiration because of the major risks of heart damage.<sup>1,2</sup> Patients with enlarged xiphoid process with xiphisternal angle of less than 160 degrees are more likely to develop xiphoidalgia; these variations and abnormalities of sternum may influence clinical procedures and diagnosis such as intercostal nerve blocks, interpretation of sternal images and evaluation of chest trauma, among other thoracic procedures and diagnostics, accordingly the current study was aimed to evaluate the incidence of anatomical and congenital variations of human dry sternum bones.

## II. Methods


This study was carried out on 120 dry human sternum bones irrespective of age and sex at Department of Anatomy, Shahid Nirmal Medical College, Dhanbad, Jharkhand.. All the sternum bones were macroscopically inspected for the anatomical and congenital variations of human dry sternum bones. Photographs of the anatomical and congenital variations were taken for proper documentation.

Congenital or developmental variations like sternal foramen or xiphoid foramen measurements were made to the nearest 0.01mm using digital calipers.

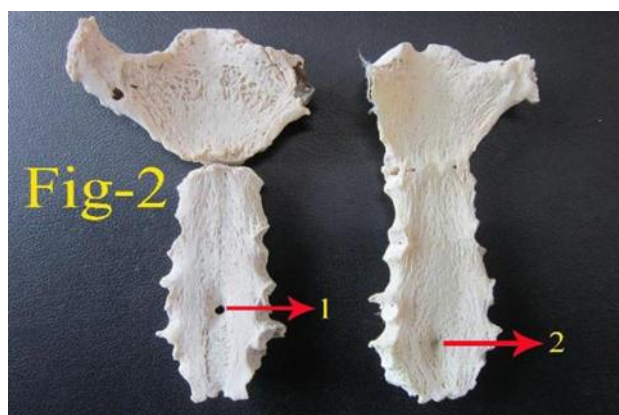
## III. Results

Out of 120 dry human sternum bones the following anatomical and congenital variations of human dry sternum bones were noted-

- Complete sternal foramina in the body of the sternum were noted in 9 bones (7.5%), with an average vertical diameter of 17mm and transverse diameter of 16mm (The highest vertical diameter of 19mm and transverse diameter of 17mm was noted) [Figure 1 and Figure 2],
- Incomplete sternal foramina in the body of the sternum were noted in 4 bones (3.3%) [Figure 1],
- Complete sternal foramina in the xiphoid process of the sternum were noted in 7 bones (5.8%), with an average vertical diameter of 6mm and transverse diameter of 8mm. [Figure 6],
- Unusual complete sternal foramina in the body and incomplete sternal foramina in the xiphoid process of the sternum were noted in 8 bones (6.6%); [Figure 5],
- Very rare long xiphoid process (with an average length of 7.3 cm) with complete sternal foramina was noted in 7 bones (5.8%); [Figure 4],
- Unusual Long xiphoid process with an average length of 6.7cm with sharp bifid ends was noted in 8 bones (6.6%); [Figure 4].



**Figure 1:** Anterior view of sternum showing sternal foramina on the body. 1-body of sternum; 2-complete sternal foramen.




**Figure 2:** Posterior view of sternum showing sternal foramina on the body. 1- Complete Sternal foramen; 2- Incomplete Sternal foramen.

All macroscopic measurements for sternal foramina were made to the nearest 0.01mm using digital calipers.

#### IV. Discussion


The anatomical or congenital variations of human skeletons are important for clinicians, radiologists and surgeons to distinction from pathologic changes for differential diagnosis. The sternum is one of the skeleton parts with frequently detected variation in cross-sectional images or autopsy series.



**Figure 3:** Body of the sternum showing large sternal foramen. 1- body of sternum. 2-Complete large sternal foramen.




**Figure 4:** Sternum showing unusual longer xiphoid process with sharp bifid ends and xiphoid foramen. 1- Longer xiphoid process with sharp bifid ends; 2-Longer xiphoid process with complete xiphoid foramen.



**Figure 5:** Sternum showing foramina on the body and xiphoid foramen. 1- Complete Sternal foramen on the body; 2- Incomplete xiphoid foramen.

The embryologic development of the sternum originally consists of two cartilaginous bars, situated one on either side of the median plane and connected with the cartilages of the upper nine ribs of its own side. These two bars fuse with each other along the middle line to form the cartilaginous sternum which is ossified from six centers: They appear between the articular facets for costal cartilages and divide the sternum into six transverse pieces.



**Figure 6:** Sternum showing xiphoid foramen. 1-Complete xiphoid foramen.

- One for manubrium: Appears at the sixth month and rarely unites with other centers except at the old age.
- Four for the body: The first of these four appears at sixth month, second and third at 7<sup>th</sup> month and fourth appears one year after birth. They unite with each other after puberty. Incomplete or irregular fusion of sternal bars in this region accompanied by eccentric centres of ossification account for the occurrence of rare sternal foramen or sternal fissure. One for the xiphoid process: It appears at 5<sup>th</sup> to 18<sup>th</sup> year of life but remains partly cartilaginous may persist into adult life. Xiphoid abnormalities are rare as compared to manubrial and gladiolal defects.<sup>3,4</sup>

Sternal foramina may be of various dimensions. They have been reported in manubrium, body and xiphisternum. Stark et al reported 4.3% incidence of sternal foramen on chest CT, 6.7% in autopsy cases by Cooper, 6.6% by Moore et al, 5.1% in Turkish population by Aktan et al, and 16.6% in cadavers and dry bones by Babinski et al.<sup>5-9</sup> Where as in our study we observed 14% of sternal foramen in the body of sternum. The size of sternal foramina ranged between 2 and 16mm, with mean of 6.5mm; Jitender Kumar et al reported sternal foramen with a length of 18.75mm and width 12.50mm.<sup>10</sup> Where as in our study we observed with an average vertical diameter of 17mm and transverse diameter of 16mm (The highest vertical diameter 19mm and transverse diameter of 17mm was noted). As per our knowledge such unusual sternal foramen has not been cited in the recent medical literature. The sternal foramen can lead to misinterpretation and wrong conclusions as bullet injuries which have serious consequences; they could also be confused with ante-mortem traumatic injuries. Posterior surface of lower two pieces of body of sternum related to the pericardium the defect in the body of sternum leaves only the skin separating heart from the surface at the affected site, thus any penetrating injury would easily cause more severe damage to the heart than would normally be. Several risk factors have been considered damage to the heart and great vessels through the foramina has occurred in transthoracic and abdominal penetration; seven cases of injuries to the heart and the pericardium have been described in scientific literature.<sup>11-</sup>

<sup>14</sup> Among which three were fatal, two of the fatal cases were caused by lack of awareness of the sternal foramen.<sup>15,16</sup> Knowledge of the existence of such anatomical variants is important to the clinician because infiltration, biopsy or acupuncture of this area may lead to fatal cardiac complications. With the increasing road traffic crash-related trauma, it is important for clinicians to be aware and suspicious of the aforementioned variations and anomalies so as to avoid misdiagnosis as fracture or traumatic fissure.

The xiphoid process is the smallest part of the sternum present in the epigastrium and it is continuous with the lower end of the body at xiphisternal joint. It is cartilaginous in youth but more or less ossifies in adults and may transform to a synostosis with the sternal body by the age of 40<sup>th</sup> year or remain unchanged even in old age. The xiphoid process gives origin to the diaphragm muscle an insertion for the rectus abdominis and

transverse abdominis muscles. The xiphoid process may be triangular with a pointed caudal end, broad and flat, bifid, perforated, deflected to one side or curved anteriorly. The inferior end lies at the level of T10 vertebrae. Unusual Long xiphoid process with a sharp bifid end noted in this study may damage the liver. Xiphoid process is clinically important because it is an important landmark with the junction with the body at xiphisternal joint indicates the anatomical end for anterior thoracic cage; this joint also site of the infrasternal or subcostal angle formed by the right and left costal margins. It also serves as a landmark for inferior border of the heart, superior limit of the liver and the central tendon of diaphragm. Shivakumar G et al reported the incidence of xiphoid foramen was 3.5%, 7% had elongated xiphoid process and that of bifid xiphoid process was 4.6% in dry sterni.<sup>17</sup> In cadaver study by El-Busaid et al reported the incidence of xiphoid foramen was 2.5% and bifid xiphoid process was 12.5%.<sup>18</sup> Where as in our study we noted the incidence of xiphoid foramen was 18.3% (complete and incomplete xiphoid foramen), bifid xiphoid process was 6.6% and longer xiphoid process was 12.5%. Very rare long and enlarged xiphoid process noted in our study may decrease the xiphisternal angle and more likely to develop xiphoidalgia or may be mistaken for an epigastric mass. Furthermore, unusual longer xiphoid process with sharp bifid ends noted in this study may misguide during cardiopulmonary resuscitation for a bony landmark to determine the location for administering chest compressions or may mistake for fractures during imaging. Such morphological variants of xiphoid process were important for cardiothoracic surgeons, physicians and radiologists to avoid misdiagnosis.

## V. Conclusion

Unusual sternal foramen noted in our study can lead to misinterpretation and wrong conclusions as bullet injuries which have serious consequences in addition the knowledge of this occurrence is important to avoid serious heart injury by needle insertion especially since this area holds a commonly used acupuncture point and sternal puncture. Xiphoid process is clinically important due to their proximity to heart, lungs, diaphragm, liver and stomach. Unusual longer xiphoid process with sharp bifid ends found in this study may misguide during cardiopulmonary resuscitation for a bony landmark to determine the location for administering chest compressions or may mistake for fractures during imaging. A sound knowledge of xiphoid foramen is very important during sternal bone marrow aspiration, radiological reporting, acupuncture and post mortem examination. Combination of such anatomical and congenital variations of human dry sternum bone has not been reported in literature to the best of our knowledge. Moreover, we believe that our data on the anatomical and congenital variations of human dry sternum bone will be enlightening, not only for anatomists, but also for radiologists, forensic experts, orthopedicians, paediatricians, cardiothoracic surgeons, physicians.

*Funding: No funding sources*

*Conflict of interest: None declared*

*Ethical approval: Not required*

## References

- [1]. Fokin AA. Cleft sternum and sternal foramen. *Chest Surg Clin North Am.* 2000;10:261-76.
- [2]. Gray R, Maharajh GS, Hyland R. Pneumothorax resulting from acupuncture. *Can Assoc Radiol J.* 199;42(2):139-40.
- [3]. Taylor HL. The sternal foramen: the possible forensic misinterpretation of an anatomic abnormality. *J Forensic Sci.* 1974;19(4):730-4.
- [4]. Kulkarni R. Multiple sternal foramina with associated anomalies: A case report. *Anatomica Karnataka.* 2010;4(2):42-45.
- [5]. Stark P. Midline sternal foramen: CT demonstration; *J Comput Assist Tomogr.* 1985;9:489-90.
- [6]. Cooper PD, Stewart JH, McCormick WF. Development and morphology of the sternal foramen. *Am J Forensic Med Pathol.* 1988;9(4):342-47.
- [7]. Moore MK, Stewart JH, McCormick WF. Anomalies of the human chest plate area: radiographic findings in a large autopsy population. *Am J Forensic Med Pathol.* 1988;9(4):348-54.
- [8]. AKTAN ZA, SAVAŞ R. Anatomic and HRCT demonstration of midline sternal foramina. *Turkish J Med Sci.* 1998;28(5):511-4.
- [9]. Babinski MA, Rafael FA, Steil AD, Sousa-Rodrigues CF, Sgrott EA, de Paula RC, et al. High prevalence of sternal foramen: quantitative, anatomical analysis and its clinical implications in acupuncture practice. *Int. J Morphol.* 2012;30(3):1042-49.
- [10]. Jakhar JK, Dagar T, Dhatarwal SK, Pal V. The sternal foramen: the possible forensic misinterpretation of an anatomic abnormality. *J Ind Acad For Med.* 2015;37(3):315-6.
- [11]. Peuker ET, White A, Ernst E, Pera F, Filler TJ. Traumatic complications of acupuncture: therapists need to know human anatomy. *Archives Family Med.* 1999;8(6):553.
- [12]. Nieda S, Abe T, Kuribayashi R, Sato M, Abe S. Case of a cardiac injury resulting from acupuncture. *Kyobu Geka.* 1973;26(12):881-3.
- [13]. Cheng TO. Pericardial effusion from self-inserted needle in the heart. *Eur Heart J.* 1991;12(8):958.
- [14]. Hasegawa J, Noguchi N, Yamasaki J, Kotake H, Mashiba H, Sasaki S, et al. Delayed cardiac tamponade and hemothorax induced by an acupuncture needle. *Cardiol.* 1991;78(1):58-63.
- [15]. Halvorsen TB, Anda SS, Naess AB, Levang OW. Fatal cardiac tamponade after acupuncture through congenital sternal foramen. *Lancet.* 1995;345(8958):1175.
- [16]. Schiff AF. A fatality due to acupuncture. *Med Times.* 1965;93:630-1.

- [17]. Shivakumar GL, Deepa G, Kadlimatti HS. Variations in the human sterna. *J Evolution Med Dent Sci*. 2013;2(2):99-104.
- [18]. El- Busaid H, Kaisha W, Hassanali J, Hassan S, Ogeng'o J, Mandela P. Sternal foramina and variant xiphoid morphology in a Kenyan population. *Folia Morphol (Warsz)*. 2012;71(1):19-22.

Santosh Kumar, et. al. "Anatomical and congenital variations of human dry sternum bone: its embryogenesis and clinical implications." *IOSR Journal of Dental and Medical Sciences (IOSR-JDMS)*, 20(08), 2021, pp. 55-60.