

Results after Valgus Osteotomy Using 120° Double Angled Barrel Plate in Delayed Presentation of Fracture Neck of Femur

Dr Gautam Mazumder¹, Dr Vishnu Pratap Singh², Dr. T. D. Bhattacharyya³

¹(Associate Professor, Department of Orthopaedics, Gauhati Medical College and Hospital, India)

²(Senior Resident, Department of Orthopaedics, Gauhati Medical College and Hospital, India)

³(Professor and Head, Department of Orthopaedics, Gauhati Medical College and Hospital, India)

Corresponding Author : Dr. Gautam Mazumder

Abstract

Background: The importance of fracture neck of femur has increased manifold because of its increasing incidence both among the ageing population and young adults. Its management is a great challenge to the orthopaedic surgeon as there is no single method of treatment which can consistently give successful results for this fracture. Moreover, in the younger population, management of this fracture is a really challenging task. In developing countries like ours, it still remains a major problem where the patients seek treatment after many weeks or months following the injury either because of poverty, lack of health infrastructure or faith in local bone-setters and quacks. In spite of recent advances, non-union is still reported in one-third of cases of femoral neck fractures with displacement.

Methodology: This was a prospective study of the functional outcome of 20 cases of valgus osteotomy in fracture neck of femur presenting late to the hospital from July 2018 to December 2019.

Results: Out of 20 cases, a total of 9(nine) cases were Pauwels grade II and 11(eleven) were grade III. The average duration of fracture was found to be 5.5 weeks. We achieved 100% union at the osteotomy site (average of 10 weeks). According to Harris Hip Score, 80% patients achieved excellent to good results with an average score being 85.4.

Conclusion: Due to socio-religious customs of our country, squatting and sitting cross legged are a part of our daily activities. In cases of neglected fracture neck of femur this can only be achieved with head preservation surgeries but not with hip arthroplasty. Among the various methods of head preservation surgeries, valgus osteotomy has proved to be cost effective with consistent and reliable results.

Keywords: Valgus osteotomy, neglected fracture neck of femur, double angled barrel plate

Date of Submission: 02-07-2021

Date of Acceptance: 16-07-2021

I. Introduction

Fracture neck of femur, in spite of recent advances, is still an unsolved fracture¹. It is because there is no single method of treatment which can give consistently good results. Moreover in the younger population, management of this fracture becomes a really challenging task.

Fracture neck of femur is more common in elderly people, as most of them are osteoporotic and majority of these fractures are due to low energy trauma. However, its incidence is increasing in the younger population due to rising number of road traffic accidents.

Only 15% of these fractures are undisplaced and are inherently stable, the rest are unstable. Due to its inherent precarious blood supply, fracture neck of femur causes circulatory disturbance leading to avascular necrosis and non-union. That is why every fracture neck of femur in younger patients should be treated as an emergency and it should be reduced anatomically and internally fixed. It is seen that undisplaced stable fractures tend to have a good prognosis whereas displaced unstable fractures often end with poor prognosis.

However, in developing countries like ours, it still remains a major problem where the patients report many weeks or months following the injury because of various reasons like poverty, lack of health infrastructure and faith in local bone-setters and quacks. In spite of recent advances in surgery, non-union is still reported in one-third of cases of femoral neck fracture with displacement². Apart from the above-mentioned factors, the other major cause of non-union is the angle of inclination of the fracture. It is seen that fractures with less than 30° of angle unite well and those with more than 30° may end in non-union even if treated with all the expertise. Among the head-retaining procedures in the younger population, various procedures such as fixation with muscle pedicle bone grafting, internal fixation with vascularised or free fibular grafting and various osteotomies with internal fixation are tried, showing inconsistent results. According to Pauwel, non-union of femoral neck fracture will consolidate if inclination of fracture is changed in such a way that the shearing forces are converted

into compressive forces which leads to endochondral ossification of the fibrocartilage resulting in fracture union.

The purpose of the present work was to critically examine and document the outcome of valgus osteotomy in above mentioned group of patients who reported late (>3 weeks) in our institution.

II. Materials And Methods

This prospective study is an analysis of the functional outcome, by clinical and radiological methods, of 20 cases of valgus osteotomy in fracture neck of femur presenting late, in the Department of Orthopaedics, at Gauhati Medical College & Hospital, Guwahati, between July 2018 and December 2019.

Inclusion Criteria

- Patients aged < 55yrs with fracture neck of femur and presenting late (>3 weeks)
- Patients < 55yrs with fracture neck of femur with failed primary fixation

Exclusion criteria:

- Patients aged >55yrs
- Patients with AVN changes of femoral head (on x rays or MRI)
- Proximal fragment < 2.5 cms
- Duration of fracture less than 3 weeks old

Pre- Operative Planning

To get excellent results by doing a valgus osteotomy for fracture neck of femur, a carefully done pre-operative planning is mandatory³. Antero-posterior views of the hip with the limb in traction and internal rotation of 10 - 20° were taken and limb lengths were measured for all cases preoperatively. We found pre-operative shortening in all the cases (range 0.5 – 2.5 cms).

A tracing of the acetabulum , head, neck and proximal third of femur is drawn on a tracing paper placed on the X ray. The angle of inclination of fracture is drawn, which is the Pauwel's angle or shear angle. Wedge is taken in such way to get a final post-op angle of less than 30°.

WEDGE ANGLE = PAUWEL ANGLE – POST OP DESIRED ANGLE (30°)

A horizontal line is drawn at the site for osteotomy at the level of upper border of the lesser trochanter, perpendicular to the anatomical axis of the femur. A 30° laterally based wedge is marked below that line.

Pin Insertion Angle: It is the angle formed between guide wire and lateral border of femoral cortex along which the compression screw (Richard's screw) is inserted.

PIN INSERTION ANGLE = IMPLANT ANGLE – WEDGE/ OSTEOTOMY ANGLE

All our patients were operated under spinal anesthesia. After a satisfactory anatomical reduction, an intertrochanteric osteotomy was performed at the upper level of the lesser trochanter under IITV guidance. We used a 120° double angled barrel plate (DABP) alone in 12 patients and in 8 cases we added a 6.5mm cannulated screw with the DABP for further compression. In our study, partial weight bearing was given at 6-8 weeks. All patients were followed up at 2 weeks and thereafter at 4 weekly intervals till union was achieved. We evaluated all our cases for limb length discrepancy at the time of functional assessment.

Fig1: Pre-operative templating

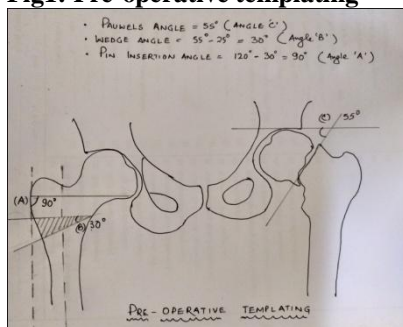


Fig 2: Double angled barrel plate

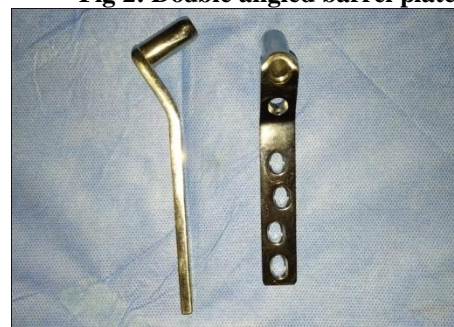

Fig 3: Insertion of K-wires

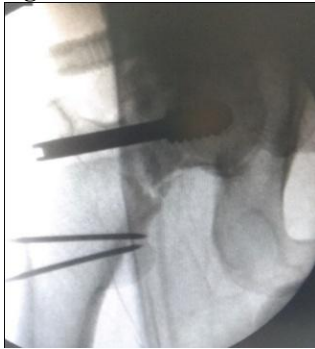

Fig 4 : Following wedge resection

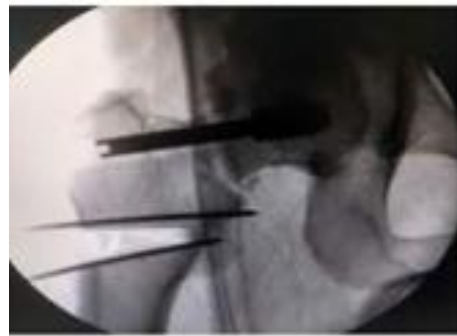

Fig 5: Wedge taken out

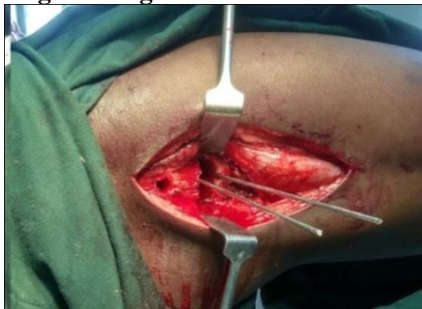
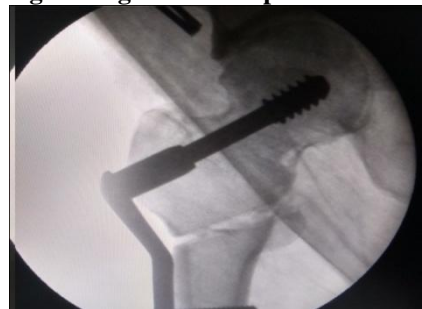
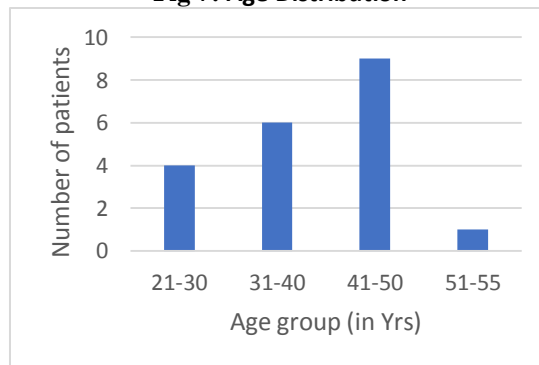
Fig 6: Valgisation and plate fixation



III. Results And Observations

The study was conducted over a period of 18 months from July 2018 to December 2019. During this period, we came across 20 cases of neglected and nonunion fracture neck of femur. We observed that the maximum number of cases were between 41-50 years of age. Of the 20 patients, 17 were male and 3 female.

Fig 7: Age Distribution



The commonest mode of injury in our patients was self-fall which was seen in 14 cases, Other modes of injury were road traffic accidents and fall from height. In this study of 20 patients, 9 patients were classified as Pauwels Grade II, 11 were as Pauwels Grade III. In this study, the average duration of fracture was found to be 5.5 weeks ranging from 3-20 weeks.

Table 1: Duration of fracture

Duration of fracture (in wks)	Number of patients
3	5
4-6	12
7-12	1
>12	2

Fig 8: Fracture Types (PAUWELS)

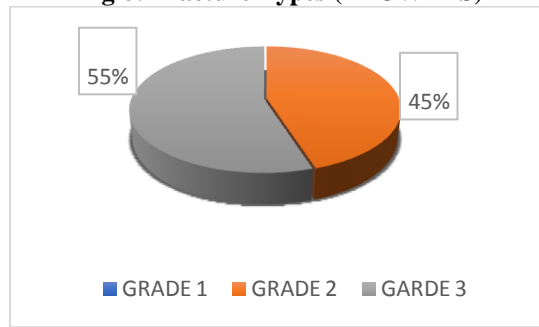
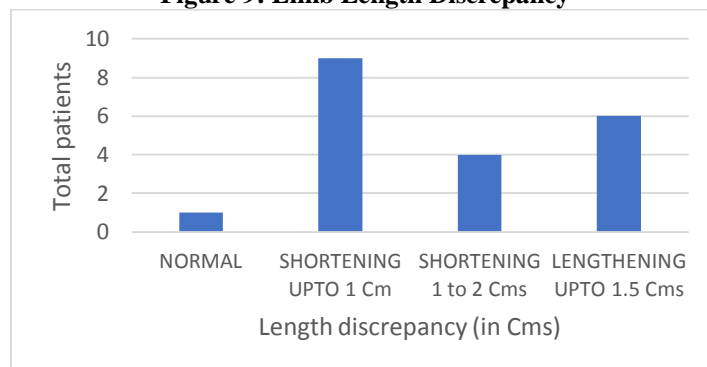


Figure 9: Limb Length Discrepancy



In our study, radiological union at the fracture site was noted in 18 out of 20 cases. Union was not achieved in 2 cases due to implant cut out. Average time taken for union was found to be 5.5 months (range 4-7 months). We achieved 100% union at the osteotomy site at an average of 10 weeks. Functional results were evaluated according to Harris Hip Score. 80% patients achieved excellent to good results with average score being 85.4.

In this study, recovery of 17 patients was found to be uneventful. 1 patient had superficial infection which was treated with debridement and antibiotics while 2 patients presented with implant cut out.

Fig 10: Pre-op X-ray

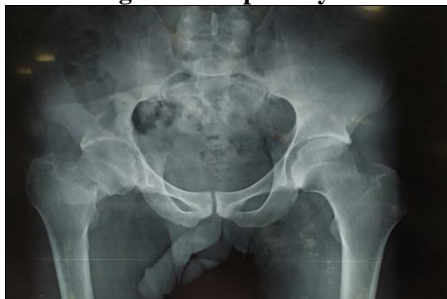

Fig 11: Post op Xray

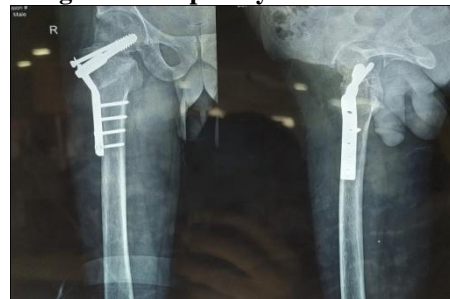

Fig 12: Patient sitting crosslegged

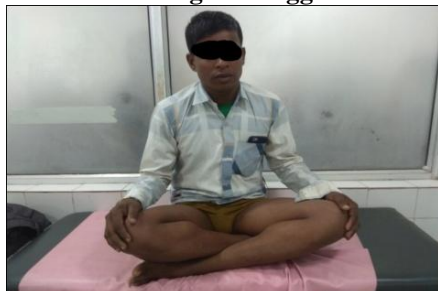

Fig 13: Patient squatting



Fig 14: Harris Hip Score

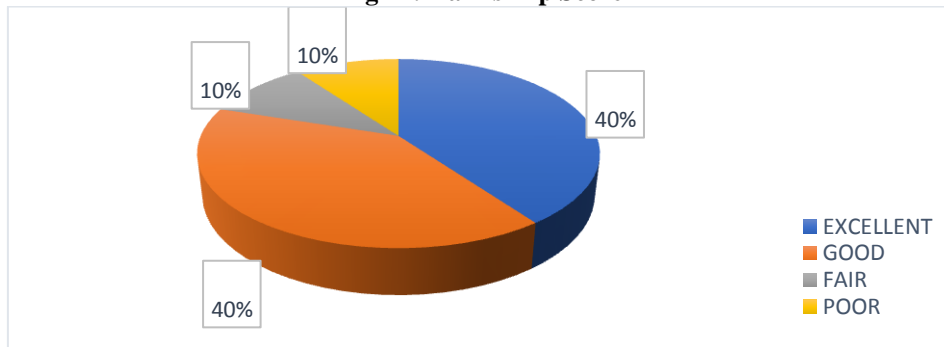


Table 2: Harris Hip Score

Excellent	8
Good	8
Fair	2
Poor	2

IV. Discussion

For elderly patients with osteoporosis, poor bone quality and long standing cases of fracture neck of femur with resorbed neck (> 50%) arthroplasty is the best available option. It completely differs in management of younger patients presenting with neglected fracture of neck of femur. For head preservation surgeries in younger adult patients, there are a myriad of procedures with variable and inconsistent outcomes.

El Zohairy MM et al⁴ compared outcome of various head preserving procedures in their metaanalysis of 725 patients and reported better functional outcome and union rate with osteotomy and internal fixation (union rate of 91.33%) than fractures fixed by internal fixation with muscle pedicle graft (union in 86.25%) and with free fibular graft (union rate of 88%). Internal fixation alone, in this study, used as an illustrative control group, was successful in 76.5%. In our study, we also got comparable union rate (90%).

The average age group in the study group of Khan et al⁵ was 36.4 years (range 20 – 60years), Magu et al⁶ study was 48.1 yrs (range 26 – 82 years). In our study average age group was 38.85 (range 22- 52 years) which was comparable to other studies.

Magu NK et al⁶ analysed a series of 48 patients and reported self-fall as most common mode of injury (43cases) and RTA being the second cause (5 cases).In our study of 20 cases, self-fall was most common mode of injury (14 cases) , followed by RTA and fall from height (3 cases each).In our study, we found 9 cases of Pauwels type II fracture and 11 cases of Grade III, that underwent valgus osteotomy for neglected fracture neck of femur.Magu NK et al⁶ reported 12 cases of Pauwels Grade II and 36 cases of Grade III out of 48 patients.

In our study, we got 100% union at osteotomy site at 10 weeks (average) which was found to be comparable to other studies , Khan et al⁵ reported at 10.3 weeks, Said GZ et al⁷ at 12 weeks, Taneja A et al⁸ at 8.6 weeks, Elshoura SA et al⁹ at 12 weeks.

In our series of 20 patients, union was achieved in 18 cases .Average time taken for union at fracture site in these 18 cases (which was assessed radiologically), found to be 5.5 months.This is comparable to a study conducted by Taneja et al⁸ , Siavashi B et al¹⁰ who found 5.5 months and 4.5 months respectively .Khan A Q et al⁵ in 2009 analysed a series of 16 patients with non-union fracture neck of femur treated with valgus osteotomy and 120° double angle barrel plate.They reported 87% union rate ,that was 14 out of 16 patients, the fracture went on to satisfactory union .Said GZ et al⁷ in 2010 reported union at fracture site in 35 patients (97%) in a series of 36 cases. Magu NK et al⁶ in 2009 retrospectively reviewed 48 cases of non-union neck of femur fracture treated with valgus osteotomy concluded that fracture union was achieved by 44 patients.Similarly others also reported union rate in same range, Taneja A et al⁸ reported 86%, Siavashi B et al¹⁰ 100%, Elshoura SA et al⁹ 90%. In our study in a series of 20 cases , we achieved union rate of 90% (18/20) which is comparable to other mentioned studies.

Based on Harris Hip Score functional outcome was evaluated after achieving union (average at 6 months after operation) Schwartsmann CR et al¹¹ in 2015 analysed a series of forty-two patients and reported good to excellent functional results in 80.9% (34/42) of the patients.Khan AQ et al⁵ in 2009 analysed a series of 16 patients with non-union fracture neck of femur treated with valgus osteotomy and 120° double angle barrel plate and reported average Harris hip score of 88 points (range 75–95 points). Taneja A et al⁸ in a series of thirty patients treated with valgus osteotomy and fixation with double angled blade plate, reported good to excellent Harris hip score in 80% of cases, fair in 7%, and poor in 13% of cases.Nayak C et al¹² in a series of

20 patients reported Excellent to good results in 70% patients. In our study 80% patients achieved good to excellent result, 10% fair and 10% of cases were with poor result. Average Harris Hip Score being 85.4, which was comparable to other similar studies.

Elshoura SA et al⁹ in a series of 20 cases reported 15 cases walk with no problem (75%), 15% (3 patients) had limping on long walk and 10% (2 cases) were unable to walk. In our series of 20 cases, 16 patients (80%) had no problem related to gait, while 2 cases (10%) reported with limp on long walk and on doing work for long hours, while 2 cases (10%) had significant limp and they needed walking aid. In our study of 20 cases, we did not encounter any case of Avascular Necrosis of femoral head. Said GZ et al⁷ in a study of 36 patients followed over period of 3 years, reported 1 case of AVN (3%). Siavashi B et al¹⁰ reported 2 cases of AVN out of 22 patients.

Khan A Q et al⁵ reported average post-operative limb length discrepancy as 1.2 cms (range 0 -1.6 cms), Siavashi B et al¹⁰ in a series of 22 patients reported, mean pre-operative limb shortening of 2 cms (1 - 3.5 cms) and post-operative discrepancy of 1 cm (0- 1.5 cms). In our study, we noted pre-operative limb length shortening in range of 0.5 – 3 cms with mean of 1.4 cms and post operative discrepancy in length was found to be 1 cm (average); range being 0-2 cms. Our findings are comparable to other similar studies.

In our study of 20 patients, 18 patients achieved union at fracture site after valgus osteotomy. 2 cases presented with non-union due to implant cut out. One of them presented with osteoarthritic changes in hip and planned for THR and other one is planned for revision surgery. Khan A Q et al⁵ reported 2 cases of implant cut out out of 16 cases. Schwartzmann CR et al¹¹ in a series of 42 cases reported 2 cases of implant cut out and 2 cases of secondary osteoarthritic changes. It may be due to inadequate reduction of fracture or due to premature weight bearing.

V. Conclusion

Due to socio-religious customs in our country, squatting and sitting cross legged are part of our daily activities. In case of neglected neck of femur fractures, this can be only achieved with head preservation surgeries and not with hip arthroplasty. However, hip replacement is a standard procedure in elderly patients or patients with marked osteoporosis and resorbed neck (>50%). But in young adult patients (< 55 yrs) with good bone stock, head preserving surgeries should always be given priority.

There are various methods for head salvaging surgeries but out of them valgus osteotomy has proven to be cost effective with consistent and reliable results. The other modalities of head preservation comes with increased morbidity and inconsistent results like fibular graft, muscle pedicle graft. With meticulous preoperative planning, anatomical reduction, and surgical expertise valgus osteotomy has proven to be the best option in such group of patients.

We conclude that in young adult patients (< 55 yrs) presenting late with fracture neck of femur, valgus osteotomy gives the best results and should be the choice of treatment in such group of patients.

References

- [1]. Shen M, Wang C, Chen H, Rui YF, Zhao S. An update on the Pauwels classification. *Journal of orthopaedic surgery and research*. 2016 Dec;11(1):1-7.
- [2]. Johnell O, Kanis JA. An estimate of the worldwide prevalence and disability associated with osteoporotic fractures. *Osteoporosis international*. 2006 Dec 1;17(12):1726-33
- [3]. Singh M, Nagrath A, Maini PS. Changes in trabecular pattern of the upper end of the femur as an index of osteoporosis. *JBJS*. 1970 Apr 1;52(3):457-67.
- [4]. ELzohairy MM, Eid AS. Meta analysis of different methods used for joint preserving procedures in the management of delayed, neglected and non-united femoral neck fractures in young adults. *Trauma*. 2016 Oct;18(4):245-9.
- [5]. Khan AQ, Khan MS, Sherwani MK, Agarwal R. Role of valgus osteotomy and fixation with dynamic hip screw and 120 double angle barrel plate in the management of neglected and ununited femoral neck fracture in young patients. *Journal of Orthopaedics and Traumatology*. 2009 Jun 1;10(2):71-8.
- [6]. Magu NK, Rohilla R, Singh R, Tater R. Modified Pauwels' intertrochanteric osteotomy in neglected femoral neck fracture. *Clinical orthopaedics and related research*. 2009 Apr 1;467(4):1064-73.
- [7]. Said GZ, Farouk O, Said HG. Valgus intertrochanteric osteotomy with single-angled 130 plate fixation for fractures and non-unions of the femoral neck. *International orthopaedics*. 2010 Dec 1;34(8):1291-5.
- [8]. Taneja A, Sharma H, Gupta JP. Evaluation of results of intertrochanteric valgus osteotomy in ununited fracture neck femur. *Journal of Clinical Orthopaedics and Trauma*. 2011 Jun 1;2(1):29-34.
- [9]. Elshoura SA. Treatment of nonunion of neck fracture of the femur in young patients with valgus osteotomy. *The Egyptian Orthopaedic Journal*. 2016 Apr 1;51(2):170
- [10]. Siavashi B, Savadkoobi D. Modified Valgus Osteotomy Of Proximal Femur For Treatment Of Femoral Neck Nonunion. In *Orthopaedic Proceedings* 2012 Sep (Vol. 94, No. SUPP_XXXVII, pp. 311-311). The British Editorial Society of Bone & Joint Surgery.
- [11]. Schwartzmann CR, Spinelli LD, Yépez AK, Boschin LC, Silva MF. Femoral neck non-union treatment by valgus intertrochanteric osteotomy. *Acta ortopedica brasileira*. 2015 Dec;23(6):319-22.
- [12]. Nayak C, Acharyya B, Jain M, Kamboj K. Valgus osteotomy in delayed presentation of femoral neck fractures using fixed angle simple dynamic hip screw and plate. *Chinese Journal of Traumatology*. 2019 Feb 1;22(1):29-33.