

## “Penetrating Injury of Chest and Abdomen: A Study on Investigations and Various Clinical Presentations”

Dr Nitika Bharti,  
MS General Surgery, Govt. Medical College, Jammu

Dr Sanjay Sharma,  
Associate Professor, Deptt. Of General Surgery, Govt. Medical College, Jammu

---

### **Abstract:**

**Background :** penetrating injuries are one of the commonest complains of patients attending a surgical emergency department of any hospital across India.

**Aim :** To study various clinical presentations of patients with penetrating torso trauma and the investigations done during their evaluation.

**Methods :** A prospective observational study was conducted on 71 patients of penetrating torso injury admitted in emergency department of Govt. Medical College Jammu (GMCJ) from October 2018 to September 2019. The patients were studied by clinical history, physical examination and investigations like Xray, CT scan, FAST & four quadrant peritoneal tapping (FQPT).

**Results :** It was observed that assault was the major mechanism of injury, abdomen was the most common site injured especially the left lower quadrant and pain was the most common presentation. Rib fractures, free fluid in peritoneum, intraabdominal injury were most common findings on Xray, FAST & CT scan respectively. All FQPT were haemorrhagic.

**Conclusion :** Findings of this study are suggestive that, both clinical examination and radiological investigations form an integral part in management of penetrating trauma patients.

**Keywords:** penetrating injury, torso, investigations, history, clinical examination, observations.

---

Date of Submission: 28-06-2021

Date of Acceptance: 12-07-2021

---

### **I. Introduction**

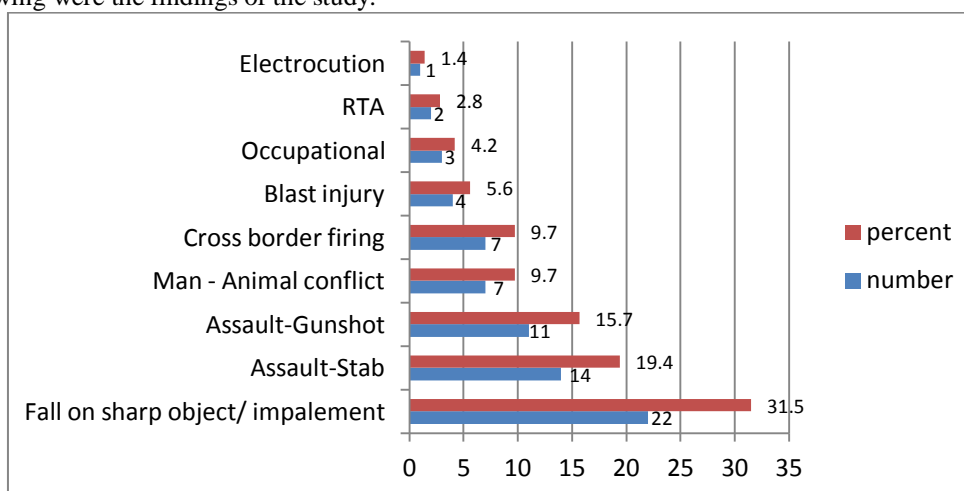
Trauma remains a major health problem in every country irrespective of the level of socio-economic advancement and it remains the most common cause of death for individuals between 1 and 44 years of age being the leading cause of disability in first four decades of life as well. Due to its anatomical position and dimensions, the thoraco-abdominal region is a major site of impact in any form of penetrating trauma. Abdomen is the third most frequently involved region in penetrating trauma requiring intervention in 25% of civilian cases<sup>1</sup> while chest is involved in 12.2% of all penetrating trauma patients. Since most of the deaths in penetrating injuries occur within minutes to hours hence it forms an important part of surgical emergencies<sup>2</sup>.

### **II. Material And Methods**

A prospective observational study was carried out over a period of one year w.e.f October 2018 to September 2019 in patients attending Government Medical College Jammu with history of penetrating injuries to chest and abdomen. All the patients irrespective of age admitted in all the general surgical units of GMC Jammu as suspected cases of penetrating thoracic/abdominal injury on the basis of history/clinical examination/radiological investigations were included in the study. Patients who presented as case of blunt thoracic/abdominal injury or who had incomplete records or died before resuscitation or who were discharged against medical advice or lost to follow up were excluded from the study. The patients included in the study were evaluated with a brief and relevant history, clinical examination and subsequently managed according to ATLS protocol.

### III. Observations And Results

The following were the findings of the study:



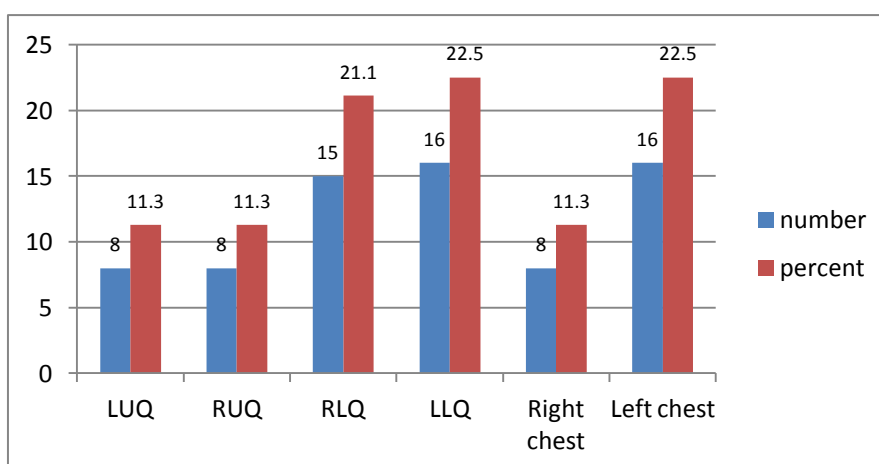
**Fig.1 Distribution of patients according to mechanism of injury**

In majority of the patients of penetrating injury, assault was the mechanism of trauma accounting for 25 (35.1%) patients with stab injury (19.4%) and gunshot (15.7%) being the main sub mechanisms.

**Table 1. Distribution of patients according to site of injury**

SITE OF INJURY	NUMBER	PERCENT
Abdomen	47	66.2%
Chest	19	26.7%
Abdomen+Chest	5	7.1%
Total	71	100%

Abdomen was the most common site of penetrating injury with 47 (66.2%) patients. Chest was the site of injury in 19 (26.7%) patients. Both chest and abdomen was involved in 5 (7.1%) patients only.



**Fig.2 Distribution of patients according to location of injury on chest and abdomen**

The most common location of penetrating injury to chest was the Left side (16 patients, 22.5%) while in abdomen LLQ (16 patients 22.5%) was the most common location. Right side of chest was involved in 8 cases while in abdomen LUQ and RUQ was involved in 8 cases each.

**Table 2: Distribution of patients according to clinical presentation on arrival**

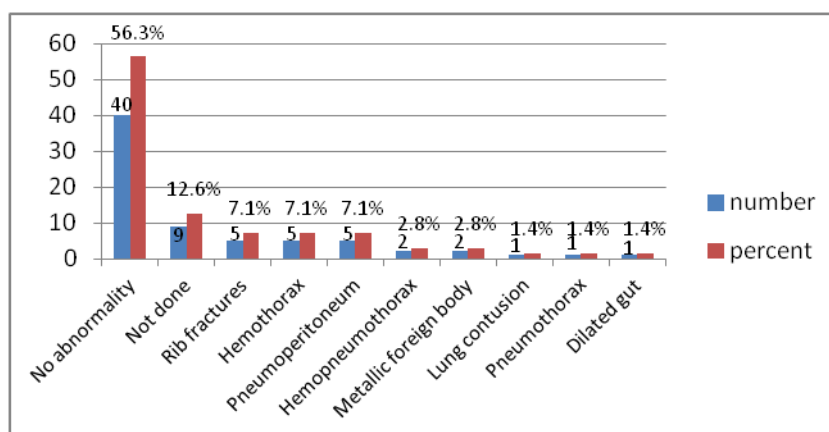
CLINICAL PRESENTATION	NUMBER (n=71)	PERCENT
Abdominal pain	17	23.90%
Evisceration of bowel/omentum	14	19.80%
Tachycardia >90	12	16.90%
Hypotension SBP<100	11	15.50%
Chest pain	8	11.30%
Breathlessness	6	8.40%
Abdominal distension	3	4.20%

Most common clinical presentation on arrival was pain abdomen, 17(23.9%) patients followed by evisceration of bowel/mesentery/omentum in 14 (19.8%) patients. Abdominal distension was the least common clinical presentation present only in 3 (4.2%) patients.

**Table 3: Distribution of patients according to associated injuries**

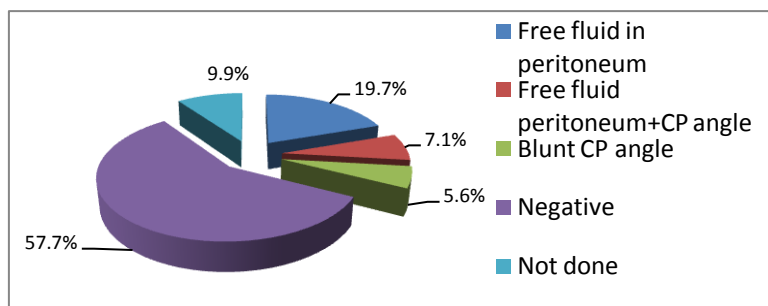
ASSOCIATED INJURIES	NUMBER (n=71)	PERCENT
ABSENT	55	77.50%
PRESENT	16	22.50%
Extremity injury	10	14.10%
Head injury	5	7.00%
Pelvic fractures	1	1.40%

Injuries apart from those to chest and abdomen were present in 16(22.5%) patients which included extremity injury in 10(14.1%) patients, head injury in 5(7.0%) patients and pelvic fractures in 1(1.4%) patient.



**Fig.3 Distribution of patients according to X-Ray findings**

X-ray of abdomen/chest were done in 62(87.4%) patients out of which findings were present in only 22(31.1%) patients. 5(7.1%) patients each had rib fractures, hemothorax and pneumoperitoneum on x-ray.



**Fig. 4 Distribution of patients according to findings of FAST**

FAST was done in 64(90.1%) cases and was positive in 23(32.4%) cases while negative in 41 (57.7%) cases. It could not be performed in 7 cases as the patients were hemodynamically unstable. FAST showed free fluid in peritoneum in 14(19.7%) patients, free fluid in peritoneum and CP angle in 5(7.1%) patients and blunting of CP angle in 4(5.6%) patients.

**Table 4: Distribution of patients according to findings of CECT abdomen and chest**

CECT	NUMBER (n=20)	PERCENT (out of 71)
<b>ABDOMEN</b>	10	14.0%
Intra-abdominal injury	5	7%
No intra-abdominal injury	5	7%
<b>CHEST</b>	10	14.0%
Intra-thoracic injury	7	9.8%
No intra-thoracic injury	3	4.2%

5(50 %) CECT abdomen were suggestive of intra-abdominal injury while 7 CECT chest (70%) showed intra-thoracic injury.

**Table 5: Distribution of patients according to Four Quadrant Peritoneal Tap (FQPT)**

FQPT	NUMBER	PERCENT
DONE(Haemorrhagic)	9	12.8%
NOT DONE	62	87.2%
TOTAL	71	100

FQPT was done in only in 9(12.8%) patients, all of which were haemorrhagic.

#### IV. Discussion

In majority of the patients of penetrating injury, assault was the mechanism of trauma accounting for 25 (35.1%) patients with stab injury (19.4%) and gunshot (15.7%) being the main sub mechanisms. Also abdomen was the most common site of penetrating injury with 47 (66.2%) patients. The findings were similar to studies by Dodia H and Sansia K (2015)<sup>3</sup> and Una J *et al.*, (2019)<sup>4</sup>. Most common clinical presentation on arrival was pain abdomen 17(23.9%) patients in our study which is in concordance with findings of study by Dodia H and Sansia K (2015)<sup>3</sup> and Panchal HA and Ramanuj AM (2016)<sup>5</sup> but not Gad MA *et al.*, (2012)<sup>6</sup> who reported breathlessness, tachycardia and hypotension in majority of patients. FAST was positive for fluid in chest or abdomen or both in 23(32.4%) cases while studies by Tayal VS *et al.*, (2004)<sup>7</sup> and Paydar S *et al.*, (2014)<sup>8</sup> FAST was positive in 16 out of 130 and 48 out of 318 patients of penetrating torso injury respectively. Chest/abdominal X-ray showed findings in 22(31.1%) patients mainly for rib fractures, haemothorax and pneumoperitoneum similar to findings by Varin D *et al.*, (2008)<sup>9</sup> but in contrast to those by Ramya C and Jayasree K (2017)<sup>10</sup>. CECT aided diagnosis of peritoneal or intrathoracic violation in 5 and 7 cases respectively out total 20 scans were performed which was somewhat similar to observations by Paydar S *et al.*, (2014)<sup>8</sup> and Filho ELM *et al.*, (2018)<sup>11</sup>.

#### V. Conclusion

The most important factor which influences outcome of patients with penetrating injuries is early recognition of intra-abdominal or intra-thoracic injuries and identifying need for surgery. Failure to promptly recognize and treat simple life threatening injuries is the tragedy of trauma and not the inability to handle the catastrophic or complicated injury. Time should not be wasted on investigations in a haemodynamically unstable patient and resuscitation should start early and exploration be planned according to injury. Haemodynamically stable patients and those without signs of peritonitis should be evaluated further via sonography or CT scan and thus facilities of CT scan should be available in emergency. This would result in shorter hospital stay and reduce mortality and morbidity associated with non-therapeutic surgical intervention.

### Bibliography

- [1]. **Hemmila MR, Wahl WL.** Management of the injured patient. In: Doherty GM, editor. *Current surgical diagnosis and treatment. Mc Graw Hill Medical*; 2008:227-8.
- [2]. **Kumar KR, Chandrakumar SVPL, Vijaylaxmi et al.** Penetrating injury abdomen: a study at government general hospital. *J Evidence based med healthcare.* 2015;2(17):2378-83.
- [3]. **Dodia H, Sansiya K.** A study of penetrating thoracic and abdominal injuries. *IOSR-JDMS.*2015;14(8):64-95.
- [4]. **Una J, Gudrun MJ, Bergos KJ et al.** Penetrating Stab Injuries in Iceland: A Whole Nation Study on Incidence and Outcome in Patients Hospitalised for Penetrating Stab Injuries. *Scandinavian J of Trauma, Resuscitation & Emergency Medicine.*2019;27:7-15.
- [5]. **Panchal HA, Ramanuj AM.** The study of abdominal trauma: patterns of injury, clinical presentation, organ involvement and associated injury. *Int Surg J.* 2016;3:1392-8.
- [6]. **Gad MA, Saber A, Farrag S et al.** Incidence, patterns and factors predicting mortality of abdominal injuries in trauma patients. *N Am J Med Sci.*2012;4(3):129-34.
- [7]. **Tayal VS, Beatty MA, Marx JA et al.** Focussed sonography in penetrating anterior chest trauma. *Ultrasound Med J.*2004;23:467-72.
- [8]. **Paydar S, Ravanfar P, Shakoori V.** Conservative Management of Anterior Abdominal Penetrating Trauma. *Ann Colorectal Res.*2014;2(4):e25741.
- [9]. **Varin D, Ringburg AN, Leishout MM et al.** Accuracy of conventional imaging of penetrating torso injuries in the trauma resuscitation room. *J of Trauma, Resuscitation & Emergency Medicine.*2008;56:350-66.
- [10]. **Ramya C, Jayasree K.** A profile of 96 cases of penetrating injury of abdomen. *Int J of Research in Medical Sciences.* 2017;5(7):2993-7.
- [11]. **Filho ELM, Guetter CR, Pimentel SK et al.** The role of computerized tomography in penetrating abdominal trauma. *Rev Col Bras Cr.*2018;45(1):1-7.

Dr Nitika Bharti, et. al. “Penetrating Injury of Chest and Abdomen: A Study on Investigations and Various Clinical Presentations.” *IOSR Journal of Dental and Medical Sciences (IOSR-JDMS)*, 20(07), 2021, pp. 12-16.