

## A Comparative Analysis of Mandibular Ramus and Mental Foramen in Sex Determination among the Population of Rajasthan Using CBCT Technology: An Institutional Study

Dr. Ghata Savoriya<sup>1</sup>, Dr. Shikha Saxena<sup>2</sup>, Dr. Krishna Sireesha Sundaragiri<sup>3</sup>,  
Dr. Bharat Sankhla<sup>4</sup>, Dr. Akshay Bhargava<sup>5</sup>, Dr. Nitesh Tyagi<sup>6</sup>

<sup>1</sup>(Department of oral pathology and microbiology, RUHS College of dental sciences/ Rajasthan University of Health Sciences, India)

<sup>2</sup>(Department of oral pathology and microbiology, RUHS College of dental sciences/ Rajasthan University of Health Sciences, India)

<sup>3</sup>(Department of oral pathology and microbiology, RUHS College of dental sciences/ Rajasthan University of Health Sciences, India)

<sup>4</sup>(Department of oral pathology and microbiology, RUHS College of dental sciences/ Rajasthan University of Health Sciences, India)

<sup>5</sup>(Department of oral pathology and microbiology, RUHS College of dental sciences/ Rajasthan University of Health Sciences, India)

<sup>6</sup>(Department of oral medicine and radiology, Rajasthan dental college and hospital, Rajasthan University of Health Sciences, India)

---

### Abstract:

**Background:** In medico-legal investigations, the identification of skeletal remains is critical. At the site of mass disasters and crimes, the hard tissue being tougher is often the sample from which sex is to be determined. The pelvis and skull are the most commonly studied skeletal components for gender determination, with the mandible being a useful component. Presence of a dense layer of compact bone makes it very durable and well preserved. Mandibular ramus can be used to differentiate between sexes and it also expresses strong sexual dimorphism.

**Materials and Methods:** Retrospective study was done comprising of a total sample size of 60 individuals classified into 2 groups comprising of 30 males and 30 females. Measurements were done on curved slicing or panoramic view of CBCT at 30.3 mm. In this study, two parameters were measured and compared; measurement of the mandibular ramus (maximum ramus breadth, minimum ramus breadth, condylar height, projective height of ramus and coronoid height) and the measurement of the distance from mental foramen (superior and inferior border) to the lower border of the mandible.

Measurements were made bilaterally, the average values calculated and the results were tabulated and statistically analyzed

**Results:** We observed that, the overall measurements of the mandibular ramus and mental foramen were larger in males than in females, and each variable of the mandibular ramus to be a significant predictor for gender determination.

**Conclusion:** The observations from the present study suggest that the mandibular ramus measurements and mental foramen parameters exhibit significant sexual dimorphism and the ramus can be used for gender determination for forensic analysis.

**Key Word:** Forensic dentistry, Mandible, Mandibular condyle, CBCT, Sexual dimorphism

---

Date of Submission: 28-06-2021

Date of Acceptance: 12-07-2021

---

### I. Introduction

Forensic odontology is a multidisciplinary branch that uses dental data to identify victims in mass tragedies, natural disasters, and jurisdictional disputes. The human dentition serves an important role in persons identification since it is resistant to most physical, thermal and chemical alterations. This entails a multi-tiered investigation, starting with a preliminary investigation.

Identification of skeletal remains is the initial crucial step in forensic investigation<sup>[1]</sup>. The human skeleton shows significant sex differentiation of which the most sexually dimorphic is the pelvis. The human skull is the second most common bone to be employed for sex determination, which has an accuracy rate of 92%.<sup>[2,3]</sup> Often at these sites the complete skull may not be available and the mandible being the largest and

most resilient bone of the face might be the remains that aid in sex determination.<sup>[4, 5]</sup> The maturation rate as well as the growth pattern of skeletal are differ between the sexes. In female, skeletal maturation occurring earlier than males. It indicates that sexual dimorphism of the skull including the mandible would manifest earlier in females.<sup>[5]</sup> The shape and size of the mandible exhibits dimorphism. The shape of the mandible is a result of sequential structural modelling as the bone increases in size.<sup>[6]</sup> Mandibular ramus houses several important anatomical structures, attaches various muscles and reflects age changes. These bear an impact on the morphology of the ramus which is characteristically different among males and females. Thus mandibular ramus measurements form an asset in the analysis of sexual dimorphism.<sup>[6]</sup>

The mandible has several important landmarks, of which the mental foramen is a stable landmark. Thus, the position of the mental foramen is compared in relation to the lower border of the mandible. This is a valuable tool in the identification of sex. Rotational panoramic radiography is widely used for obtaining a comprehensive overview of the maxillofacial complex. This forms an indispensable tool in forensic anthropology and forms an apt tool for measurement of the ramus and mental foramen.

Measurements were taken using a combination of dry bone tests and radiography. In the realm of medical scanning, new approaches are constantly being developed. Computer-assisted work approaches are currently becoming a growing trend in forensic science. Studies in the literature have shown that cone beam computed tomography (CBCT) has improved accuracy, reproducibility, and reliability over older methods<sup>[7,8]</sup>. CBCT imaging device can obtain undistorted three-dimensional (3D) images of good quality with a low radiation dose, which ensures exact localization and description of bone structures with a specific CBCT software<sup>[9]</sup>.

This study measures, compares and evaluates the various measurements of the mandibular ramus and analyses the position of the mental foramen as an aid in sex determination as observed on CBCT. This study establishes the baseline data of these parameters among the population of Rajasthan.

## **II. Material And Methods**

A retrospective study was carried out on patients of Department of oral medicine and radiology at RUHS college of dental sciences, Jaipur, Rajasthan. From July2019 to August 2019. A total 60 subjects (both male and females), between the ages of 20 to50 years were taken for in this study.

**Study Design:** Retrospective study

**Study Location:** This was a hospital based retrospective study was carried out on patients of Department of oral medicine and radiology at RUHS college of dental sciences, Jaipur, Rajasthan.

**Study Duration:** July2019 to August 2019.

**Sample size:** 60 patients.

### **Inclusion criteria:**

1. Ideal CBCT images of fully dentate patients.
2. Either sex
3. Between the ages of 20 to 50 years.

### **Exclusion criteria:**

- 1 Patients with impacted mandibular third molars.
- 2 Patients with dental caries/ periapical pathologies. (Periapical granuloma, periapical cyst etc.)
- 3 Patients with developmental anomalies.
- 4 Patients with fractures of the jaws
- 5 Edentulous patients.
- 6 Faulty radiographs.
- 7 Artefacts.

### **Procedure methodology**

Measurements were done on curved slicing or panoramic view of CBCT at 30.3 mm. All CBCT images were taken using carestream CS9300 imaging system(CS 3 D Imaging V3.5.7;carestream health ,Inc Newyork,USA) with the field of view (fov) of 17x11 cm or 17x13 cm. Voltage ranged from 68-90 kvp, tube current 4mA,Exposure time of 11.3 sec was used. Evaluation of the CBCT scans were done on the Dell precision workstation comprising of dual monitor (1920x1200 resolution)using CS 3D Software..(Fig 1)

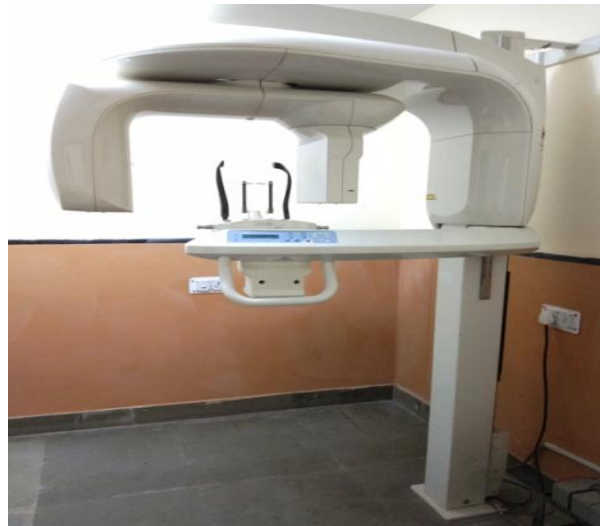

Fig.1 CBCT machine

Mandibular ramus measurements were carried out using Master View 3.0 software.

The following parameters were measured using mouse driven method (by moving the mouse and drawing lines using chosen points on the CBCT radiograph (Fig. 2)

1. Maximum ramus breadth: - The distance between the most anterior point on the mandibular ramus and a line connecting the most posterior point on the condyle and the angle of jaw.(A)
2. Minimum ramus breadth: - Smallest anterior–posterior diameter of the ramus.(B)
3. Condylar height: - Height of the ramus of the mandible from the most superior point on the mandibular condyle to the tubercle, or most protruding portion of the inferior border of the ramus(C)
4. Projective height of ramus: - Projective height of ramus between the highest point of the mandibular condyle and lower margin of the bone(D)
5. Coronoid height: - Projective distance between coronoid and lower wall of the bone.(E)

Measurements of the Mental Foramen: The mental foramen measurements were done bilaterally:

6.The distances were measured from the superior border of the mental foramen to the lower border of the mandible (S-L) .

(7) The inferior border of the mental foramen to the lower border of the mandible (I-L).

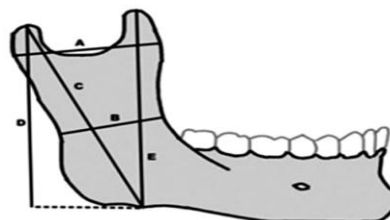


Fig 2: Diagram showing mandibular ramus measurements adapted from Saini et al<sup>[1]</sup>

### Statistical analysis

The data were analyzed using the discriminate procedure of the statistical package SPSS 24.0. Discriminate function analysis was used to determine variables that discriminate between male and female and is increasingly utilized for sex diagnosis from skeletal measurements. The level  $P < 0.05$  was considered as significance.

### III. Result

Descriptive statistics of different mandibular ramus measurements for both sexes are summarized in Table 1 and Graph 1. We observed that the maximum ramus breadth was significantly ( $p < 0.01$ ) differed between male and female and higher in male ( $39.89 \pm 0.66$ mm) compared to female ( $35.92 \pm 0.74$ mm).

Measurements of the minimum ramus breadth were  $31.41 \pm 0.59$ mm and  $28.35 \pm 0.61$ mm in male and female respectively. Statistical analysis of the comparison of the minimum ramus breadth between males and females were found significantly ( $p < 0.01$ ) higher in males than females.

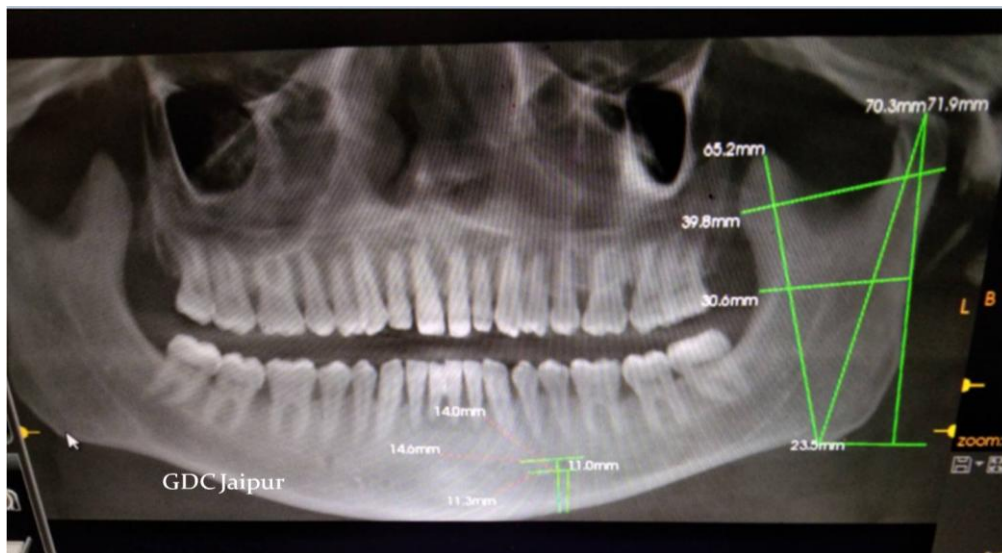
Measurements of the condylar height showed that the mean values of condylar height were  $69.27 \pm 1.1\text{mm}$  and  $61.71 \pm 0.75\text{mm}$  in male and female respectively. We noted that the Condylar height significantly ( $p < 0.01$ ) higher in males than females.

The mean values of Projective height of ramus were  $64.89 \pm 1.21\text{mm}$  and  $57.85 \pm 0.81\text{mm}$  in males and females respectively. On the basis of Statistically analysis, we found significant ( $p < 0.01$ ) difference between males and females.

The mean value of measurements of the coronoid height in males was found to be  $61.53 \pm 0.95\text{mm}$  and  $55.06 \pm 0.80\text{mm}$  in females. Comparison of the values between males and females concluded that the significantly ( $p < 0.01$ ) higher in males than females.

Measurements of the mental foramen were made from the superior border of the mental foramen to the lower border of the mandible and from inferior border of the mental foramen to the lower border of the mandible. The mean values of distance between (S-L) in males and females were  $14.85 \pm 0.36$  and  $13.43 \pm 0.28\text{mm}$ . We observed that the distance between (S-L) was significantly ( $p < 0.01$ ) higher in males compared to females.

The mean values of distance between (I-L) in males and females were  $12.3 \pm 0.37$  and  $11.17 \pm 0.25\text{mm}$ . Difference in values between males and females were found to be statistically significant (significance ( $p < 0.05$ ) in both sex.

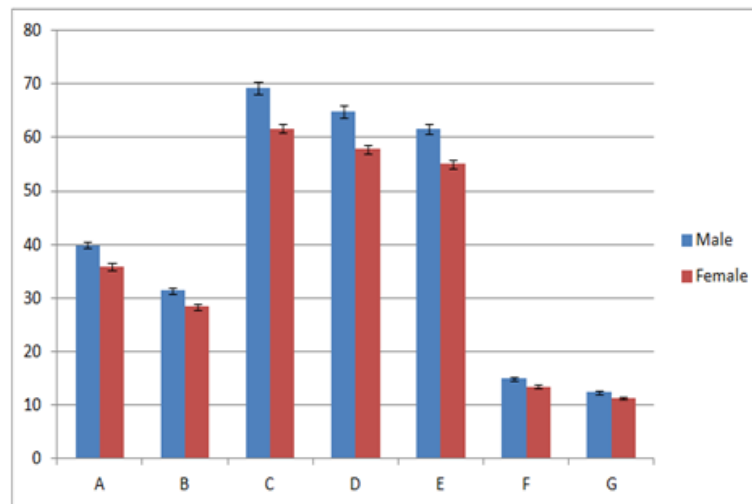


**Fig 3 showing various measurement done on OPG view OF CBCT**

**Table:1. Comparison of mean value and S.D. of ramus and mental foramen**

Parameters	Gender	N	Mean±S.E.(mm)	S.D.	Significance level
Max ramus breadth	Male	30	$39.89 \pm 0.66$	3.64	**
	Female	30	$35.92 \pm 0.74$	4.06	
Min ramus breadth	Male	30	$31.41 \pm 0.59$	3.27	**
	Female	30	$28.35 \pm 0.61$	3.35	
Condylar height	Male	30	$69.27 \pm 1.1$	6.06	**
	Female	30	$61.71 \pm 0.75$	4.08	
Projective height of ramus	Male	30	$64.89 \pm 1.21$	6.65	**
	Female	30	$57.85 \pm 0.81$	4.42	
Coronoid height	Male	30	$61.53 \pm 0.95$	5.23	**
	Female	30	$55.06 \pm 0.80$	4.37	
Distance between (S-L)	Male	30	$14.85 \pm 0.36$	1.98	**
	Female	30	$13.43 \pm 0.28$	1.55	
Distance between (I-L)	Male	30	$12.3 \pm 0.37$	2.01	*
	Female	30	$11.17 \pm 0.25$	1.35	

\*significance ( $p < 0.05$ ) \*\*significance ( $p < 0.01$ )



Graph 1. Comparison of mean value of ramus and mental foramen

#### IV. Discussion

The identification of sex from human remains is of fundamental importance in forensic medicine and anthropology, especially in criminal investigations as well as in the identification of missing persons and in attempts at reconstructing the lives of ancient populations. The human skeleton shows significant sex differentiation of which the most sexually dimorphic is the pelvis. Identification of sex from human skeleton is required accurate measurement of mandibular parameter. Various researchers use various technologies to identify sex, such as morphological measurement with vernier callipers, digital callipers, radiography, panoramic radiographs, and so on. CBCT technology is the most advanced of these technologies, providing greater accuracy than the others. With the use of a CBCT equipment, undistorted and high-quality 3D images can be obtained with less radiation.

In this study, it was purposed to measure the morphometric parameters of the 3D mandible models in the Rajasthan population and to evaluate the effectiveness of measurements in sex determination. We measured seven parameters of the mandible comprising of ramus and mental foramen by CBCT technology. We found that, all measurements of the mandibular ramus and mental foramen were significantly larger in males than in females. Various studies have investigated the sexual dimorphism of the mandibular ramus using different technology and observed significant difference between males and females mandibular ramus.

Saini et al 2011, carried out an anthropometric research using sliding calipers in mandibular ramus and conclude that the all measurement (Maximum and minimum ramus breadth, condylar height, projective height of the ramus and coronoid height) were larger in males than females.<sup>[10]</sup>

Datta A et al 2015 carried out a study on 50 random adult dry intact mandibles from Southern India and various morphometric parameters including ramus height and coronoid height were measured using a mandibulometer and digital calipers. They found the mean height of ramus to be more in males compared to females.<sup>[10]</sup>

Taleb et al 2015 carried out a study among Egyptians, where 191 Panoramic images were analysed for five mandibular ramus linear measurements, such as upper and lower ramus breadth, projective height, condylar and coronoid height. They found all the linear measurements were larger in males than females.<sup>[11]</sup>

Bhagwatkar T et al 2016 conducted a study on hundred subjects wherein the ramus was analysed on panoramic radiographs to evaluate its efficacy in sex determination. They observed that linear measurements of the mandible (maximum and minimum ramus breadth, projective height, and condylar and coronoid height.) were significantly larger in males than females.<sup>[12]</sup>

Malik et al 2016 carried out a radiographic study to evaluate the mental foramen as an indicator for sex determination and found that the average values of the distance from the superior and inferior borders of the mental foramen to the lower border of the mandible to be significantly higher in males than in females.<sup>[13]</sup>

Rani et al 2019 Morphometric assessment of mental foramen for gender prediction using panoramic radiographs and found that the distance between mental foramen to basal bone of mandible was significantly more in male than that to females on the bilateral aspect.<sup>[14]</sup>

Okkesima A and Erhamza, T S 2020 conducted a retrospective study to asses the mandibular ramus for sex determination using CBCT Technology and it observed that the maximum and minimum ramus breadth, condylar height, projective height and coronoid height were significantly differed between both sex.<sup>[15]</sup>

Skeletal morphology heavily influences the sexual identification of humans. This has been extensively proven by researches carried out across many geographic areas and ethnic communities in our country. All the studies mentioned are in concordance with the inference from our study, i.e., mandibular ramus and mental foramen measurements are significantly higher in males than in females and are vital indicators of sexual dimorphism.

## V. Conclusion

Mandibular ramus can be considered as a valuable tool in sex and age determination since it possesses resistance to damage and disintegration processes. We found that mandibular ramus measurements using CBCT technology were reliable for sex determination. Hence, we strongly suggest the use of mandibular ramus as an aid for sex determination in forensic analysis. In view of these findings, further studies on more diverse populations to assess the significance of these parameters are recommended.

## References

- [1]. Saini V, Srivastava R, Rai R K, Shamal S N, Singh T B, Tripathi S K. Mandibular ramus: An indicator for sex in fragmentary mandible. *Journal of forensic sciences*. 2011; 56(1): 13-16.
- [2]. Krogman W M. Introduction. In: *The human skeleton in forensic medicine*. 1st edition. Illinois, USA: Thomas Books; 1962.p.3-17.
- [3]. Giles E. Sex determination by discriminant function analysis of the mandible. *Am J Phys Anthropol*. 1964; 22: 129–35.
- [4]. Duric M, Rakocevic Z, Donic D. The reliability of sex determination of skeletons from forensic context in the Balkans. *Forensic Sci Int*. 2005; 147(2):159–64.
- [5]. Hu K S, Koh K S, Han S H, Shin K J, Kim H J. Sex determination using nonmetric characteristics of the mandible in Koreans. *J Forensic Sci*. 2006; 51(6):1376–82.
- [6]. Loth S R, Henneberg M. Mandibular ramus flexure: a new morphologic indicator of sexual dimorphism in the human skeleton. *Am J Phys Anthropol*. 1996; 99(3):473–85.
- [7]. Robinson C, Eisma R, Morgan B, et al. Anthropological measurement of lower limb and foot bones using multi- detector computed tomography. *J Forensic Sci*. 2008;53(6):1289–1295.
- [8]. Ramsthaler F, Kettner M, Gehl A, Verhoff M. Digital forensic osteology: morphological sexing of skeletal remains using volume-rendered cranial CT scans. *Forensic Sci Int*. 2010;195(1):148–152.
- [9]. Yamamoto K, Ueno K, Seo K, Shinohara D. Development of dento- maxillofacial cone beam X- ray computed tomography system. *Orthod Craniofac Res*. 2003;6(1):160–162.
- [10]. Datta A, Siddappa S C, Gowda V K, Channabasappa S R, Shivalingappa S B, Sriji D D. A Study of Sex Determination from Human Mandible Using Various Morphometrical Parameters. *Indian Journal of Forensic and Community Medicine*. 2015; 2(3):158-66.
- [11]. Taleb N S A, Beshlawy M E. Mandibular Ramus and Gonial Angle Measurements as Predictors of Sex and Age in an Egyptian Population Sample: A Digital Panoramic Study. *J Forensic Res*. 2015; 6 (5): 1-7.
- [12]. Bhagwatkar T, Thakur M, Palve D, Bhondey A, Dhengar Y, Chaturvedi S. Sex determination by using mandibular ramus - a forensic study. *Journal of Advanced Medical and Dental Sciences Research*. 2016; 4(2):1-6.
- [13]. Malik M, Laller S, Saini R S, Mishra R K, Hora I, Dahiya N. Mental foramen: An Indicator for Gender Determination - A Radiographic Study. *Santosh University Journal of Health Sciences*. 2016; 2(1):12-14.
- [14]. Rani A, Kanjani V, Kanjani D, Rajeshwari G. Annigeri | Morphometric assessment of mental foramen for gender prediction using panoramic radiographs in the West Bengal population – A retrospective digital study. *Journal of Advanced Clinical & Research Insights*. 2019; 6, 63–66.
- [15]. Alime Okkesima T, Erhamzab T. S. Assessment of mandibular ramus for sex determination: Retrospective study. *Journal of Oral Biology and Craniofacial Research*. 2020; 10(4):569-572.

Dr.Ghata savoriya, et. al “A Comparative Analysis of Mandibular Ramus and Mental Foramen in Sex Determination among the Population of Rajasthan Using CBCT Technology: An Institutional Study.” *IOSR Journal of Dental and Medical Sciences (IOSR-JDMS)*, 20(07), 2021, pp. 14-19.