

Acute Severe Vertigo- A Covid 19 Induced Labyrinthitis

Dr Shyoji Ram Meena*³ ;Dr Pranavkumar Bhat*¹; Dr Kashinath Pujari*²;

*3- Senior professor and unit cheif-dept of medicine; GMC Kota ; Rajasthan

*1 - junior resident ; dept of medicine;GMC kota; Rajasthan

*2- Junior resident ,dept of medicine; GMC Kota; Rajasthan

Abstract-

In March 2020 the World health organization (WHO) declared covid 19 as a pandemic. Since then the pathophysiology of the disease, clinical presentation of the patient, screening guidelines and management protocols of the disease has been ever evolving day by day.....

We present a case of 73 years old man from Rajasthan hadoti region who was diagnosed , treated ,symptomatically improved from covid 19 respiratory illness(moderate severity) and further home isolated patient presenting with acute intractable vertigo, nausea vomiting to the casualty which simulated the presentation of acute cerebrovascular accident. The pathophysiology of covid 19 induced labyrinthitis is similar to any other viral infections and early suspicion and diagnosis of such cases is important for proper isolation, treatment and avoiding unnecessary investigations.

Date of Submission: 24-06-2021

Date of Acceptance: 07-07-2021

I. Introduction

In the city of Wuhan , China, a novel type of coronavirus designated as COVID 19 was identified as a cause of cluster of pneumonias in December 2019(1) pneumonia appears to be the most common manifestation of the disease presenting as cough fever breathlessness (5). However the disease can affect many other systems including central and peripheral nervous system, cardiovascular system, as well as gastrointestinal. So Patients can present as acute diarrheal disease, myocarditis, deep venous thrombosis, retinal artery thrombosis, conjunctivitis or even as ischemic stroke. Number of studies , emerging daily from various parts of the world, have revealed that Among the nervous system manifestation dizziness is the most common symptom of COVID-19(2). There are also a few reports for COVID-19-induced or associated stroke, delirium, epileptic, and non-epileptic seizures, and non-specific neurologic syndromes presenting like encephalitis(6). More studies are required for understanding the pathophysiology of the disease. Yet it is not clear whether these neurologic presentations are a direct result of the nervous system infection by the virus or through an indirect or inflammatory response to the cytokine storm or vascular insults. More studies are required about latency of the virus in nervous system, post covid neurological manifestations etc.

We present a case of intractable nausea and vertigo in a patient who had recovered from COVID-19 respiratory infection, possibly a manifestation of acute vestibular neuritis /labrinthitis from COVID-19. The patient's identity has been kept confidential in the manuscript.

II. Case study

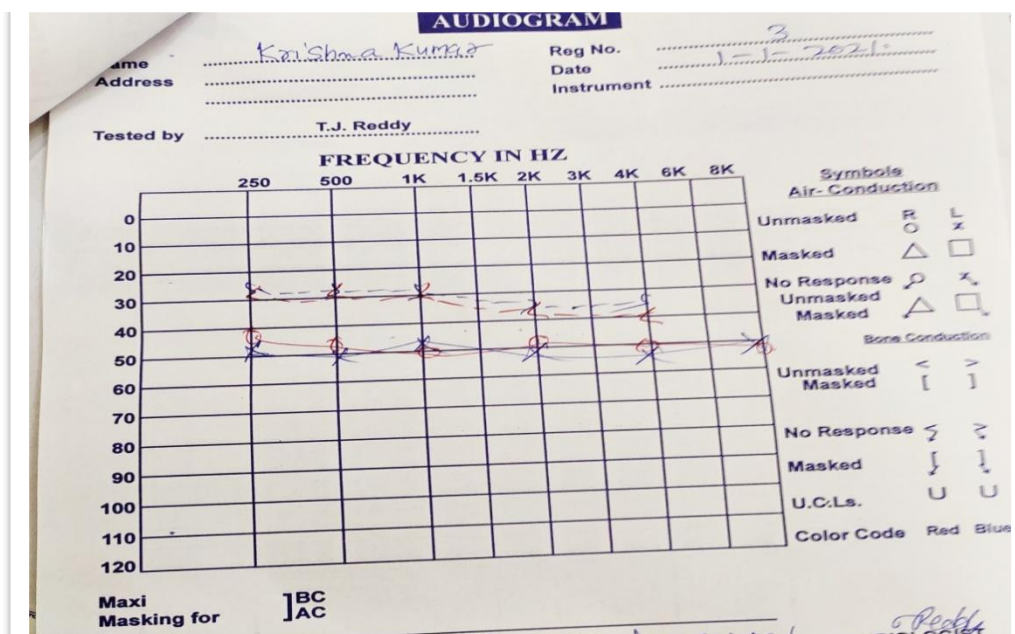
A 73 year old male patient, who is a retired government servant by occupation from Kota came with complaints of Vertigo and vomiting since morning. - Vertigo was acute in onset, non progressive continuous all through the day, not associated with head movements or positional changes. The patient was unable to get up due to vertigo. The vertigo is also associated with nausea and 3-4 episodes of vomiting. Vomitus was non projectile containing semi digested food particles, non-bilious in nature. Patient also complaints of tinnitus in his right ear, intermittent, no aggravating and relieving factors. No h/o headache, swaying to one side, tremors, weakness, blurring of vision, hearing abnormality.

Patient had a h/o cough, fever and breathlessness and diagnosed to be having covid 19 positive by RT-PCR test 15 days back and was admitted in new medical college hospital Kota, Rajasthan. He was treated with inj remdesivir (200mg on day 1 followed by 100mg for 4 days), inj LMWH, inj Dexamethasone, piperacillin and tazobactam, azithromycin. His CTSS was 12/25. He was discharged on 23/12/2020 and advised home isolation as patient is symptomatically better. Patient was taking symptomatic treatment for cough, fever and generalized body ache.

Patient was a known case of hypertension on T.amlong 5 mg OD. No h/o similar complaints in past. No h/o cerebrovascular accident, myocardial infraction, tuberculosis, diabetes or any ear and pharyngeal diseases. Patient's vision was normal.

On examination, the patient is conscious, oriented, with bp 126/84, pulse-90beats/min with normal character and rhythm, spo2 96% with room air, afebrile. His systemic examinations were normal. Horizontal Nystagmus was present, fast component towards the left year with rotational component. Further positional manuver like dik hallpike, head impulse test and gait could not be attempted due to acuity of illness. Routine investigations, CT scan and audiograms were normal.

Acute vestibular neuritis was the initial diagnosis and managed symptomatically with antiemetic, labyrinthine sedatives along with treatment of covid 19 as previously mentioned. Acute thromboembolic stroke was differential diagnosis. Patient improved in 7-8 days



III. Discussion

The manifestations of covid 19 were diverse and neurological symptoms are commonly seen in patients. Dizziness being the most common among them (2). There are also incidences of more severe and acute presentations like ataxia, seizures, impaired consciousness, etc. (7-9). Covid 19 even involves the peripheral nervous system and cranial nerves leading to impaired taste, smell, vision, and nerve pain (7-9). The Journal of American Medical Association (JAMA) published a case series of 214 patients with covid 19 from Wuhan china, in which 36.4%of patients were reported to have neurological symptoms. The neurological symptoms were more in patients with severe respiratory infections (45.5%) (7).

CNS manifestations are proposed to be due to neuroinvasive potential of SARS- CoV- 2 virus. There are several postulated mechanisms like direct invasion, hypoxia, hyper coagulopathy, as well as immune-mediated insult (4). According to a study conducted by Baig, et al, the virus enters the neural tissue from circulation and binds to the Angiotensin Converting Enzyme - 2 receptors found in the capillary endothelium.(3)

Vestibuloneuritis / peripheral vestibulopathy is a benign, self-limiting condition in which patient presents with nausea, vomiting, dizziness, and vertigo. It occurs due to inflammation and swelling of the vestibular nerve due to any insult, most commonly due to viral aetiology following upper respiratory tract infection. Other causes include bacterial infections and rarely, manifestations of systemic autoimmune diseases or HIV (16). In labyrinthitis along with vestibular part of 8th nerve there is also involvement of cochlear part leading to tinnitus and auditory disturbances. There are no specific diagnostic modalities to diagnose labyrinthitis / vestibular neuritis except the clinical tests like head impulse test which can't be done either, in acute presentation as in our patient. The symptomatology of the disease is similar to the patient which we had in our hospital.

The differential diagnosis in our case on presentation were cerebrovascular accident, presyncopal dizziness, and cerebellar infarct. There were no focal neurological signs, CNS examination including the plantars and cranial nerves were normal. On top of that, the neuroimaging showed no abnormalities which ruled out the probability of CVA although the imaging could carry upto 12% false-negative results in acute ischemia [17]. There was nystagmus which was horizontal in direction, spontaneous in nature, fast component towards the left side and stabilized by gaze fixation which suggested right sided ear pathology rather than cerebellar , since cerebellar nystagmus is directional and pendular in nature. Moreover, cerebellar signs were absent. Gait of the patient could not be assessed due to acuity of the disease. Audiometry was done to rule out local ear

pathology and any hearing problems which were normal. Presence of History of tinnitus suggested involvement of labyrinth too.

Based on the history , clinical examination, laboratory and imaging findings, covid 19 RT-PCR report and clinical course in the hospital we presumed that our patient had covid -19 induced labyrinthitis.

Irrespective of the cause of labyrinthitis the treatment is symptomatic and vestibular rehabilitation if needed (10). It includes anti emetic, anticholinergic , antihistaminic , and benzodiazepines. Corticosteroids can be used in severe cases. We used dexamethasone 6 mg od as covid 19 treatment protocol as of December 2020- January 2021.

IV. Conclusions

Vestibular neuritis is a common cause of vertigo, but this case reveals one of the manifestations of covid virus which adds valuable information to limited literature on covid 19 infection. Further studies are required to know about the latency of virus in nervous system, pathophysiology, various manifestations and treatment protocols

References

- [1]. World Health Organization. Coronavirus disease 2019 (COVID-19). Situation report-45 .
- [2]. (2020). Accessed: April 18, 2020: <https://www.who.int/emergencies/diseases/novelcoronavirus-2019/situation-reports>.
- [3]. Mao L, Jin H, Wang M, et al. Neurologic manifestations of hospitalized patients with coronavirus disease 2019 in Wuhan, China. *JAMA Neurol.* 2020;77(6):1-9.
- [4]. Baig A, Khaleeq A, Ali U, et al. Evidence of the COVID-19 virus targeting the CNS: tissue distribution, host-virus interaction and proposed neurotropic mechanisms. *ACS Neurosci.* 2020;11(7):995-998.
- [5]. Wu Y, Xu X, Chen Z, et al. Nervous system involvement after infection with COVID-19 and other coronaviruses. *Brain Behav Immun.* 2020;97:18-22.
- [6]. Zhu N, Zhang D, Wang W, et al.: A novel coronavirus from patients with pneumonia in China. *N Engl J Med.* 2020, 382:727-733. 10.1056/NEJMoa2001017
- [7]. Pinna P, Grewal P, Hall JP, et al.: Neurological manifestations and COVID- 19: experiences from a tertiary care center at the Frontline. *J Neurol Sci.* 2020, 415:[Epub].
- [8]. 10.1016/j.jns.2020.116969
- [9]. Mao L, Jin H, Wang M, et al.: Neurologic manifestations of hospitalized patients with coronavirus disease 2019 in Wuhan, China. *JAMA Neurol.* 2020, 77:683-690.10.1001/jamaneurol.2020.1127
- [10]. Gautret P, Lagier JC, Parola P, et al.: Hydroxychloroquine and azithromycin as a treatment of COVID- 19: results of an open-label non-randomized clinical trial. *Int J Antimicrob Agents.* 2020, 20:105949 [Epub]. 10.1016/j.ijantimicag.2020.105949
- [11]. Ning T, Bai H, Chen X, Gong J, Li D, Sun Z: Anticoagulant treatment is associated with decreased mortality in severe coronavirus disease 2019 patients with coagulopathy. *J Thromb Haemost.* 2020, 18:1094-1099. 10.1111/jth.14817
- [12]. Norrving B, Magnusson M, Holtås S: Isolated acute vertigo in the elderly; vestibular or vascular disease?. *Acta Neurol Scand.* 1995, 91:43-48. 10.1111/j.1600-0404.1995.tb05841.x
- [13]. McDonnell MN, Hillier SL: Vestibular rehabilitation for unilateral peripheral vestibular dysfunction. *Cochrane Database Syst Rev.* 2015, 13:005397. 10.1002/14651858.CD005397.pub2
- [14]. Thomson TL, Amedee R. vertigo; a review of common peripheral and central vestibular disorder. *Ochsner J.* 2009 spring; 9(1):20-6
- [15]. Kattah JC, Talkad AV, Wang DZ: HINTS to diagnose stroke in the acute vestibular syndrome. Three-step bedside oculomotor examination more sensitive than early MRI diffusion-weighted imaging. *Stroke.* 2009, 40:3504-3510.10.1161/STROKEAHA.109.551234

Dr Pranavkumar Bhat. "Acute Severe Vertigo- A Covid 19 Induced Labyrinthitis." *IOSR Journal of Dental and Medical Sciences (IOSR-JDMS)*, 20(07), 2021, pp. 55-57.