

## Periapical microgurgery : Clinical and Radiographic evaluation of a Periapical Lesion using combination of Biodentine; as a retrograde filling material , Hydroxyapatite Bone Graft , PRF and Amnion Membrane as a Regenerative Material ; (An In-Vivo Study)

Dr. Anil K Tomer<sup>1</sup>, Dr. Geetika Sabharwal<sup>2</sup>, Dr. Hysum Mushtaq<sup>3</sup>, Dr Ayush Tyagi<sup>4</sup>, Dr Tony Jose<sup>5</sup>, Dr Ayan Guin<sup>6</sup>

<sup>1</sup>Professor and Head, Department of Conservative Dentistry and Endodontics, Divya Jyoti College of Dental Sciences and Research, Modinagar, Uttar Pradesh.

<sup>2-6</sup>Postgraduate students, Department of Conservative Dentistry and Endodontics, Divya Jyoti College of Dental Sciences and Research, Modinagar, Uttar Pradesh.

Corresponding Author: Dr Geetika Sabharwal

### ABSTRACT

**INTRODUCTION:** Periapical surgery is an endodontist's last option for effectively treating periapical lesions caused by pulp necrosis. A variety of regenerative materials, such as bone grafts, growth factors, and membranes, influence the healing outcome of periapical surgery.

**PRESENTATION OF CASE :** The primary goal of the two cases presented here was to evaluate the potential benefits of a combination of bone graft, platelet-rich fibrin (PRF), and amnion membrane in terms of reduced post-operative discomfort and radiographic evidence of accelerated periapical bone healing. A case of radicular cysts treated with a combination of Sybograf®, PRF, and amnion membrane regeneration. The patient was evaluated for discomfort both immediately after surgery and a week later. For the next three months, the patient was recalled every month for radiographic evaluation of the periapical healing.

**DISCUSSION :** There are numerous articles in the literature that support the role of synthetic bone graft particles in enhancing regeneration. The rationale for combining Sybograf®, PRF, and amnion membrane was to maximise clinical and radiographic healing outcomes by combining the individual benefits of these materials.

**CONCLUSION:** The outcome of this case substantiates the credibility of combining amnion membrane with a bone graft and PRF to improve radiographic healing outcomes while reducing postoperative discomfort and presenting a viable regenerative treatment modality.

**KEYWORDS:** Amnion membrane , Bone graft , Periapical Lesion , Regeneration

Date of Submission: 13-07-2021

Date of Acceptance: 29-07-2021

### I. Introduction

Endodontic or a periapical surgery is considered where the orthograde treatment fails or where the retreatment is not feasible and if left untreated results in inflammation and resorption of mineralized tissue . The last resort left to save the tooth previous to extraction is the periapical surgery in the arsenal of an endodontist . Regeneration of periapical bone defects is of great challenge to endodontist, especially in case of large bony defects or through-and-through lesions .Efforts towards the conservation of maximum possible tooth structure and periodontal structures should be made as this can be justified by the fact that "**a mouth without teeth is like a mill without its stone, and a tooth must be worth more than a diamond**".The inability of most tissues and organs in humans to regenerate after damage has been a source of great frustration for physicians, dentists, and patients throughout history, but this has changed with the introduction of regenerative therapies that use growth factors and barrier membranes.

Incorporation of microsurgical instruments, ultrasonic tips and more biocompatible filling materials such as Biodentin , new various bone graft (autografts ,allografts ,alloplasts , xenografts ),growth factors (biologically active molecules like PRF , PRP ,PDGF,PTH,EMD,BMPs )and regenerative membranes have proved their abilities in periodontal regeneration along with huge success in periapical surgery<sup>1</sup>. **With technology advancing at a galloping rate, regenerative endodontic is no longer a fairy tale like idea but soon to become reality in endodontics** and created interest in membranes , as these membranes promote the regeneration of lost periodontal structures and conform to the surface contours of bone and root surfaces . Also acts as a reservoir of Stem Cells which enhances the healing process .

Aim of our present case is to evaluate the postoperative discomfort using visual analog scale (VAS ) and assess the regenerative potential in terms of radiographic evidence of accelerated periapical healing is accomplished through the use of a combination of bone graft and PRF to fill periapical osseous defects, as well as the use of amnion membrane as a mechanical barrier with the following properties: antiscarring, anti-inflammatory, antimicrobial, immunomodulatory, and so on<sup>2</sup>.

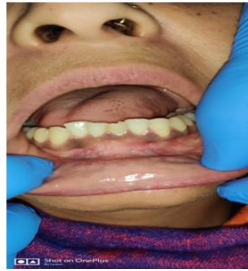

Fig1: Pre operative image

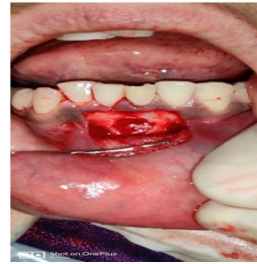

Fig2: Flap raised

## II. Case Report

A 26 years old patient reported with the chief complaint of dull pain and swelling in her lower front tooth region for the past 2 months and wanted to be treated .The patient gave a history of treatment in relation with 31 and 41 . Patient's medical history was non contributory .Patient gave a history that she has undergone dental treatment (private setup ) for the same tooth two months ago once she noticed discoloration of teeth and was suffering from intermittent pain .The patient was referred to The Department Of Conservative Dentistry And Endodontics for management .

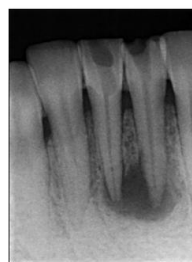

Fig3: Pre operative

On intraoral examination , slight swelling was seen in relation to 31 and 41 .The teeth 31 and 41 exhibited tenderness on percussion test and exhibited no mobility. The teeth were non responsive to thermal and electric pulp test .

The radiographic examination showed horizontal bone loss in both the mesial and distal aspects of 31 and 41 and showed access opening done irt 31 and 41 and also revealed the presence of large well defined periapical radiolucency in relation to the apices of 31 and 41 .

Case management was discussed with the patient with the primary treatment that comprised of Blood Tests (Bleeding Time , Clotting Time , Complete Blood Count ) , CBCT irt 31 and 41 , followed by a root canal treatment, but the necessity of a periapical surgery was also explained and an informed consent was obtained .

Root canal treatment was performed in relation to both 31 and 41. Throughout the visits, calcium hydroxide was used as an intra canal medicament for frequent dressings .Despite the use of an intra-canal medication, weeping canals were visible at each subsequent visit.As a result, in addition to root canal treatment, endodontic surgery was incorporated into the treatment plan to effectively treat the periapical lesion.Under proper isolation, the root canals were obturated using guttapercha (DentsplyMaillefer, Ballaigues, Switzerland) and Sealapexsealer (Kerr Endodontics ,Sybron endo , Scafati , Italy) prior to the surgery. A radiograph was taken to assess the root canal treatment.

### SURGICAL PROCEDURE :

Following anaesthesia with 2 % lignocaine, surgical intervention was facilitated via a crevicular incision aided by a unilateral posterior release. A bony window was created through the cortical bone after the full-thickness mucoperiosteal flap was reflected.This facilitated access to the cystic lining and granulation tissue, which were carefully curetted and sent for biopsy.The root ends were resected after the residual inflammatory connective tissue was curetted. Root end cavities were prepared with a low-speed bur and retrogradely filled with Biodentine . The surgical site was completely irrigated and isolated.

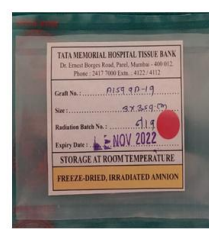
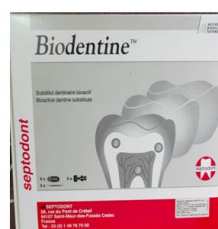
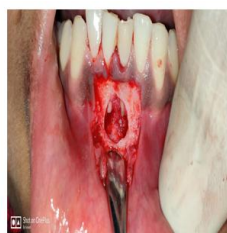
Fig4 : (a)Intra operative site of the lesion ,(b)Biodentine retrograde filling material (c)Freeze dried irradiated Amnion membrane

A xenograft bone graft material (SYBOGRAF™ - PLUS) (EUCARE PHARMACEUTICALS PRIVATE LTD , Chennai , India ) , synthetic bone graft .Platelet rich fibrin (PRF) preparation protocol described by Choukrounet.al was used

in the present report<sup>3</sup>. The PRF protocol included collecting a blood sample in 10 ml tubes without anticoagulant and immediately centrifuging it at 3000 rpm for 10 minutes in a table top centrifuge (REMI laboratories, Bombay, India).

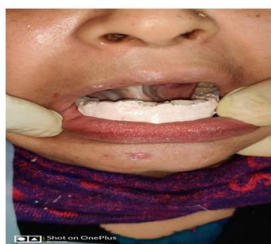After processing, the PRF clot was kept, while platelet-poor plasma (PPP) and exudates containing RBCs were discarded. To form a composite graft, the bone graft material was mixed with freshly prepared PRF. This was carefully inserted into the osseous defect. In our case reports, we used an amnion membrane from the Tata Memorial Hospital Tissue Bank in Mumbai, India. Following the grafting of the defects, the area was covered with an amnion membrane to act as a mechanical barrier. After achieving hemostasis, the mucoperiosteal flap was sutured back to its original anatomical position using 4-0 silk sutures.



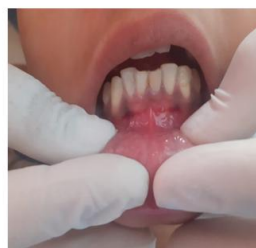
**Fig 4(a) Three layers obtained with prf in the middle ,(b) PRF ( c) Placement of PRF and amnion membrane**

### POST OPERATIVE INSTRUCTIONS

The patient was given post-operative instructions as well as antibiotics and analgesics. Plaque control was emphasised by using 0.2 percent chlorhexidine gluconate mouthwash twice a day for at least two weeks. A one-week post-operative visit revealed no adverse effects or allergic reactions to the material. The discomfort was scored using a VAS scale both immediately after surgery and at the patient's follow-up visit after a week. For the next six months, the patient was recalled once a month.



**Fig5 : Coe Pak dressing placed over surgical site**



**Fig 6: After 1 month**

### III. Result

Following three-months follow-up, radiographs revealed adequate bone healing in the periapical region. The histopathologic examination of the curetted lesion revealed a nonkeratinized stratified squamous epithelium lined with a mixed inflammatory infiltrate. These characteristics lend support to the diagnosis of anodontogenic radicular cyst (periapical cyst).

### IV. Discussion :

Most endodontists found it difficult to treat large periapical lesions with conventional surgery because healing resulted in connective tissue repair, which had a poor prognosis. Material science advances have resulted in new materials and membranes that have improved the regenerative capacity in such large periapical lesions, which is unquestionably beneficial to practitioners<sup>4</sup>.

We have used (SYBOGRAF™ - PLUS) (EUCARE PHARMACEUTICALS PRIVATE LTD, Chennai, India) as the bone graft material to fill the defects. There are numerous articles in the literature that support the role of bone matrix. Bone substitute materials are primarily used as fillers and scaffolds to aid in bone formation and wound healing. The xenografts show great similarity to natural bone and helps in bone regeneration. As a biomaterial, hydroxyapatite crystals have numerous advantages<sup>5</sup>. When placed in contact with fresh bone surface, it is extremely biocompatible and does not cause a foreign body reaction. The new bone is deposited directly onto the hydroxyapatite surface, with no intervening fibrous tissue. Hydroxyapatite does not simulate osteogenesis, but is osteoconductive, that is, when placed next to a viable bone, an advancing front of new bone grows into the porous matrix. Hydroxyapatite derived from xenogenic bone has several advantages over other bone grafts<sup>5</sup>. i.e : There is no need for a donor site, Maximum material supply, Simple procedure, There is no risk of disease transmission.

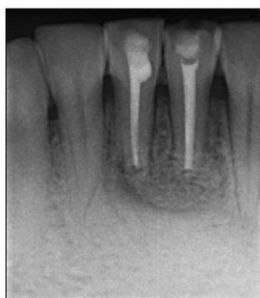Presence of blood clot is an important factor which is provided by our body's biological product, PRF, which stabilises the wound matrix. PRF is an autologous fibrin of the second generation gel made up of concentrated platelets that clump together during the centrifugation process<sup>6</sup>. The following facts explain the rationale for using PRF in conjunction with the bone graft in our case report. Through neo-angiogenesis, PRF acts as a matrix, preserving the integrity of the bone graft material and enhancing revascularization between the bone graft particles<sup>7</sup>. PRF fibrin matrix slowly resorbs and releases growth factors such as PGDF, TGF, and VEGF, which maintain a viable and long-lasting field to promote healing. Many studies have shown that the combination of bone graft and PRF has the potential to improve bone formation.<sup>8,9</sup>

PRP and PRF are platelet concentrates that have the potential to be a source of growth factors that are important in bone regeneration. We used PRF in our current case reports because it has a number of advantages over PRP. Advantages of PRF Over PRP : There is no biochemical handling of blood , A more straightforward and cost-effective procedure , No need for bovine thrombin or anticoagulants , Formalized paraphrase Slow polymerization promotes healing , Improved cell migration and proliferation , PRF has an anti-inflammatory effect on the immune system , Formalized paraphrase PRF aids in hemostasis<sup>10</sup> .

Endodontists have found the guided tissue regeneration technique with the use of various membranes to be a valuable tool in periapical surgeries performed in the aesthetic zone. The literature is replete with studies that have used GTR with various types of membranes in endodontic surgery, with varying degrees of success .<sup>11,12,13</sup>

According to the literature, combining a collagen membrane with a bone graft significantly improves alveolar bone preservation. First, amnion membrane, derived from the human placenta, is absorbable and contains a variety of growth factors with antiinflammatory and antimicrobial properties that are relatively easy to process and obtain..

In our reported case the amniotic membrane acts as a reservoir of Multi-Potent Stem cells, which aids in the acceleration of the healing process. It also has many advantages over other materials in properties such as immune modulatory effects, anti-scarring and anti-inflammatory properties, and so on. Pain has been reduced. The use of amniotic membrane in conjunction with bone graft increases the osteoinductive and osteoconductive properties, thereby enhancing alveolar bone formation. Amniotic membranes have many distinct properties when compared to traditional GTR membranes, placental barriers, and amniotic fluid . To begin with, the Amniotic membrane contains a variety of proteins that provide a bioactive matrix to aid in wound healing, such as collagen types I, III, IV, V, and VI, as well as laminin. Placental barriers, in addition to providing a bioactive matrix, have been shown in studies to have antibacterial properties and to reduce inflammation by inhibiting macrophages and polymorphonuclearneutrophils<sup>2</sup> . As a result, the use of a membrane reduces the likelihood of anterior tooth recession and provides the much-needed impetus for surgeons to perform surgeries in the aesthetic zone with confidence .



**Fig 7 : After 1 month (post operative)**

## V. Conclusion

There were some limitations; for example, obtaining a patient's own blood to prepare PRF is difficult with apprehensive patients and is associated with some morbidity. These preparations, when combined with bone graft materials, retained the wound healing properties of platelet-derived products without requiring the patient's blood and demonstrated excellent soft and hard tissue healing outcomes. To summarise, within the limitations of the study, the cases presented here show that amnion membrane combined with bone graft and PRF improved radiographic healing and reduced post-operative discomfort.

**FINANCIAL SUPPORT AND SPONSORSHIP:**Nil.

**CONFLICTS OF INTEREST:** There are no conflicts of interest.

## References

- [1]. Review and meta-analysis, *J. Endod.* 37 (2011) 1039–1045. [10] E. Deenadayalan, Ashok Kumar, Rajendra Kumar Tewari, Surendra Kumar Mishra, Humalftekhhar, Management of Large Periapical Lesion with the combination of second generation platelet extract and hydroxyapatite bone .
- [2]. Amniotic Membrane as Barrier Membrane in Endo-Perio Lesion – A Interdisciplinary Approach , RamnathElangovan , RamakrishnanTheyagarajan, MejallaMuthiahAmalaDhas , *J Dent Oral Health* 6: 1-7
- [3]. Choukroun J, Adda F, Schoeffler C, Vervelle A. Uneopportunit  en paro-implantologie: Le PRF. *Implantodontie* 2001;42:55-62.
- [4]. Combination of hydroxyapatite, platelet rich fibrin and amnion membrane as a novel therapeutic option in regenerative periapical endodontic surgery: Case series ,UdayKiranUppada,\*, ButchibabuKalakonda , PradeepKoppolub, Narendravarma, KiranPalakurthy , VenkateshManchikanti , Shilpa Prasad, Shereen Samar , Lingam Amara Swapna , / *International Journal of Surgery Case Reports* 37 (2017) 139–144 .
- [5]. Bone Regeneration Using Hydroxyapatite Crystals for Periapical Lesion , Dr.RohitArora, , Dr.Shalya Raj (IOSR-JDMS) , Volume 14, Issue 8 Ver. VII (Aug. 2015)
- [6]. al. Choukroun Jet, Platelet-rich fibrin(PRF): A secondgenerationplatelet concentrate. Part IV: Clinical effects on tissue healing, *Oral Surg. Oral Med. Oral Pathol. Oral Radiol. Endod.* 101 (2006) e56–60.
- [7]. A. Simonpieri, M. Del Corso, G. Sammartino, D.M. DohanEhrenfest, The relevance of Choukroun’s platelet-rich fibrin and metronidazole during complex maxillary rehabilitationsusing bone allograft. Part II: Implant surgery, prosthodontics, and survival, *Implant Dent.* 18 (3) (2009) 220–229.
- [8]. References [1] J.D. Bashutski, H.L. Wang, Periodontal and endodontic regeneration, *J. Endod.* 35 (2009) 321–328.
- [9]. A.R. Pradeep, P. Bajaj, N.S. Rao, E. Agarwal, S.B. Naik, Platelet-rich fibrin combined with a poroushydroxyapatite graft for the treatment of three wall intrabony defects in chronic periodontitis: a randomizedcontrolled clinical trial, *J. Periodontol.* 83 (12) (2012) 1499–1507
- [10]. Role of Platelet rich fibrin in wound healing: A critical review BaramNaik , P Karunakar , M Jayadev , V Rahul Marshal , *J Conserv Dent* 2013;16:284-93 .
- [11]. G. Pecora, S. Kim, R. Celletti, M. Davarpanah, The guided tissue regeneration principlein endodontic surgery: one-yearpostoperative results of large periapicallesions, *Int. Endod. J.* 28 (1) (1995) 41–46.
- [12]. J. Santamaria, A.M. Garcia, J.C. de Vicente, S. Landa, J.S. Lopez-Arranz, Bone regenerationafter radicular cyst removal with and without guided bone regeneration, *Int. J. Oral Maxillofac. Surg.* 27 (2) (1998) 118–120.
- [13]. H.J. Rankow, P.R. Krasner, Endodonticapplications of guided tissue regeneration in endodontic surgery, *Oral Health* 86 (12) (1996) 33–35.