

Nd:YAG membranotomy for preretinal hemorrhage secondary to valsalva retinopathy : about 2 cases

Bentouhami Mohammed Reda¹, Hidane Youness², Saadouni Choai³, Mchachi Adil⁴, Benhmidoune Leila⁵, Chakib Abderrahim⁶, Rachid Rayad⁷, El Belhadji Mohamed⁸

^{1,2,3} Resident doctor, ^{5,6,7,8} Associate professor

Department of ophthalmology, 20 Aout 1953 teaching hospital, Hospital university center Ibn Rochd, Casablanca, Morocco

Summary:

Premacular hemorrhage is a rare source of painless vision loss. The blood is believed to accumulate in the potential space under the internal limiting membrane especially for Valsalva related instances, or between the internal limiting membrane and hyaloid face. In this report, we describe 2 cases of successful use of Nd:YAG laser in the treatment of premacular hemorrhage due to Valsalva retinopathy. In both cases we were successful to use the Nd:YAG laser to drain the premacular hemorrhage. Nd:YAG laser treatment offers a simple, relatively safe, non-invasive treatment option for drainage of premacular hemorrhage.

Date of Submission: 10-07-2021

Date of Acceptance: 26-07-2021

I. Introduction:

Premacular hemorrhage is a rare source of painless vision loss. The blood is believed to accumulate in the potential space under the internal limiting membrane especially for Valsalva related instances, or between the internal limiting membrane and hyaloid face.

Spontaneous resolution can take several weeks or months depending on the thickness and total amount of blood present. The prolonged presence of blood may lead to the development of significant epiretinal tissue proliferation. Nd:YAG hyaloidotomy has been reported to be a relatively safe and effective method of draining premacular hemorrhage into the vitreous cavity.

In this report, we describe 2 cases of successful use of Nd:YAG laser in the treatment of premacular hemorrhage due to Valsalva retinopathy.

II. Case Reports:

Case 1:

A 28 year-old male patient presented to the ophthalmology emergency department with complaints of sudden painless vision loss in his right eye. He had constipation over the past 2 weeks. He experienced severe straining before vision loss.

On examination, his visual acuity was counting fingers OD and 10/10 OS. Intraocular pressure and anterior chamber examination were normal bilaterally. Dilated fundus examination of the right eye showed a large subhyaloid hemorrhage covering the macula

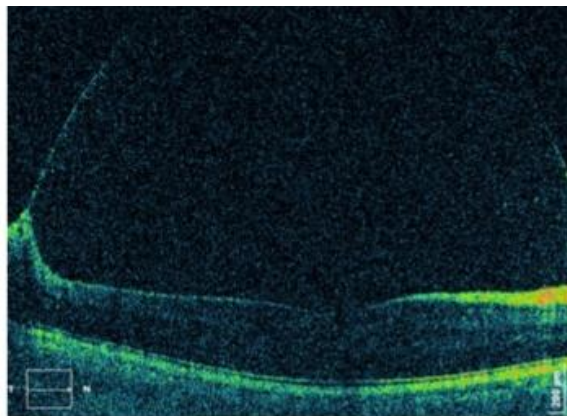
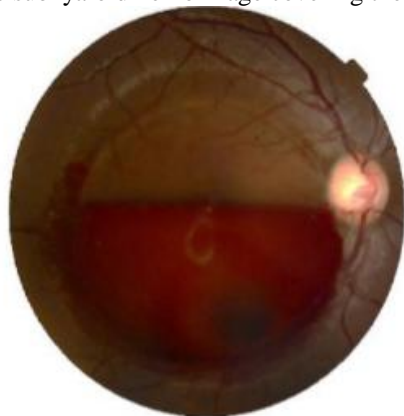


Figure1. Retinophotography and macular OCT showing preretinal hemorrhage

Nd:YAG was applied in single shots to the hyaloid face . The majority of blood immediately drained into the inferior vitreous with near complete recovery of vision.

One week after the procedure, the vision in the right eye was 10/10. Dilated fundus examination showed inferior vitreous hemorrhage with complete clearing in front of the macula.

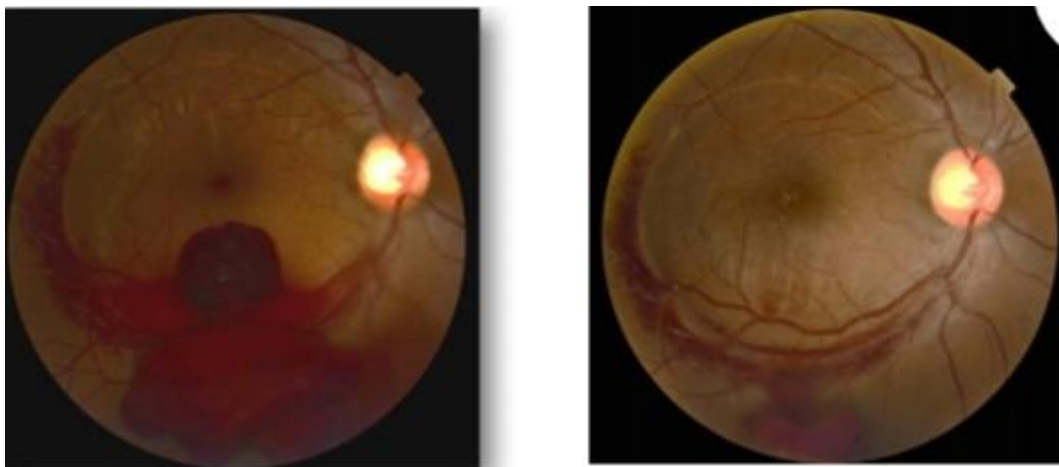


Figure 2: Preretinal hemorrhage evolution after Nd.YAG laser membranotomy

Case 2

A 45 year-old woman presented to the ophthalmology emergency department with a 5 day history of sudden painless loss of vision in her left eye which developed after an episode of emesis. The patient had no significant ocular history.

On examination, her corrected visual acuity was 9/10 OD and hand motion OS. Anterior segment examination was unremarkable bilaterally. Dilated fundus exam of the left eye showed a preretinal hemorrhage covering the macula .Due to the premacular hemorrhage, it was not possible to determine if subretinal hemorrhage extended under the central macula. OCT showed dense preretinal hemorrhag.

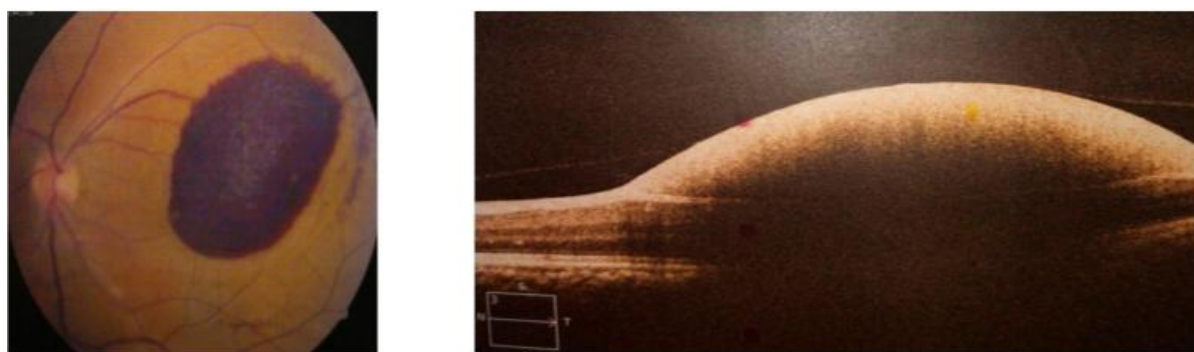


Figure3. Retinophotography and macular OCT showing preretinal hemorrhage

Given the classic clinical appearance, a diagnosis of valsalva retinopathy was made. The patient elected to observe initially. The patient returned after 6 weeks when her vision remained hand motion and posterior segment examination showed persistent hemorrhage. Nd:YAG was applied to the inferior portion of the hemorrhage with 2 shots. 6 weeks later the left eye visual acuity measured 8/10.

III. Discussion:

Valsalva retinopathy is a specific form of retinopathy characterized by pre-retinal hemorrhages secondary to raised intrathoracic pressure. Thomas Duane first described it in 1972 (1) . The mechanism of valsalva retinopathy is due to a sudden rise in intrathoracic or intra-abdominal pressure against closed glottis that may cause a rapid increase in venous pressure in the eye leading to spontaneous rupture of perifoveal retinal capillaries. Healthy young adults are a common age group that presented with valsalva retinopathy with history of valsalva-like maneuver such as heavy lifting, coughing, sneezing, vigorous sexual activity, bungee jumping, constipation, and also certain procedure that related to increase in intrathoracic or intra-abdominal pressure like fiberoptic gastroenteroscopy(2-5) .

Valsalva retinopathy can be treated by observation, Nd:YAG laser, and vitrectomy . Treatment choice depends on the duration, location, and the amount of the hemorrhage. It is a self-limited event, and in most cases, the hemorrhage resolves within a month without any complications. The primary potential complication of wait and watch management is prolonged exposure of the retina to hemoglobin and iron. It can cause irreversible retinal damage and visual loss(6)

Nd:YAG membranotomy was first described by *Faulborn* in 1988 to drain premacular subhyaloid hemorrhage into the vitreous cavity. Since, there have been many case reports and series in the literature describing similar Nd:YAG membranotomy, with energy levels ranging from 2.5 to 50 mJ, with relatively good success(7).

The optimum energy level is not clear because of the density of the premacular hemorrhage and the broad range of the energy levels. *Kuruville et al.* started with 1.7 mJ laser power, titrated through 2.9 mJ, and achieved the appreciable effect at 3.8 mJ(7). *Gabel et al.* reported energy levels up to 50 mJ were used with no retinal injury(8) They postulated that the preretinal blood is thought to provide a buffer that protects the underlying retina from the laser energy. However Nd:YAG laser therapy has broken down mediated effect meaning that low pulse energies, below the break down threshold, may cause inadvertent retinal damage by its photodisruptive effect. Therefore it is critical to determine the optimum energy level for effective therapy.

The long-term complications of Nd:YAG laser include macular hole, retinal detachment and epiretinal membrane formation. *Sharma et al.* have reported using a combination of argon green-Nd:YAG laser for hyaloidotomy utilizing subthreshold energy levels of Nd:YAG laser of 2.0 mJ to reduce energy-related complications(7).

Goker et al concluded that Nd:YAG therapy can only be considered in premacular hemorrhages of at least 3 disc diameters in size. For an effective and safe laser treatment, three important criteria were crucial: location, energy level, and the choice of the lens(6). First is to choose the most appropriate position to facilitate evacuation of the blood into the vitreous at the inferior aspect of the fluid pocket. Secondly they suggest beginning with 1.5-2.0 mJ energy level with clear media titrating upwards gradually with 0.5 mJ intervals as required. And the third is to choose the proper contact macular lens.

IV. Conclusion:

We described the successful use of the Nd:YAG laser to drain two cases of premacular hemorrhage due to valsalva retinopathy. Nd:YAG laser treatment offers a simple, relatively safe, non-invasive treatment option for drainage of premacular hemorrhage.

CONFLICT OF INTEREST

The authors declare no conflict of interest.

Contribution of the authors:

All the authors participated in the care of the patient and the writing of the manuscript. All authors have read and approved the final version of the manuscript.

Reference;

- [1]. Duane TD. Valsalva hemorrhagic retinopathy. *Trans Am Ophthalmol Soc.* 1972;70:298–313.
- [2]. Roberts DK, MacKay KA. Microhemorrhagic maculopathy associated with aerobic exercise. *J Am Optom Assoc.* 1987 May;58(5):415–8.
- [3]. Friberg TR, Braunstein RA, Bressler NM. Sudden visual loss associated with sexual activity. *Arch Ophthalmol Chic Ill* 1960. 1995 Jun;113(6):738–42.
- [4]. Choi S, Lee S, Rah S. Valsalva retinopathy associated with fiberoptic gastroenteroscopy. *Can J Ophthalmol J Can Ophtalmol.* 2006 Aug;41(4):491–3.
- [5]. Mukherjee C, Kumar A, Mitra A. Valsalva maculopathy: To treat or not to treat. *Oman J Ophthalmol.* 2018;11(1):78–81.
- [6]. Goker YS, Tekin K, Ucgul Atilgan C, Kosekahya P, Yilmazbas P. Full Thickness Retinal Hole Formation after Nd:YAG Laser Hyaloidotomy in a Case with Valsalva Retinopathy. *Case Rep Ophthalmol Med.* 2018 Jun 3;2018:e2874908.
- [7]. Kuruville O, Munie M, Shah M, Desai U, Miller JA, Ober MD. Nd:YAG membranotomy for preretinal hemorrhage secondary to valsalva retinopathy. *Saudi J Ophthalmol.* 2014 Apr;28(2):145–51.
- [8]. Gabel V-P, Birngruber R, Gunther-Koszka H, Puliafito CA. Nd:YAG Laser Photodisruption of Hemorrhagic Detachment of the Internal Limiting Membrane. *Am J Ophthalmol.* 1989 Jan 1;107(1):33–7.

Bentouhami Mohammed Reda, et. al. “Nd:YAG membranotomy for preretinal hemorrhage secondary to valsalva retinopathy : about 2 cases.” *IOSR Journal of Dental and Medical Sciences (IOSR-JDMS)*, 20(07), 2021, pp. 38-40