

Methanol Induced Toxic Optic Neuropathy: Case Report

Raid Soumaya¹, Chajia Zakaria², Mchachi Adil³, Benhmidoune Leila⁴, Chakib Abderrahim⁵, Rachid Rayad⁶, El Belhadji Mohamed⁷

^{1, 2} Resident doctor, ^{4, 5, 6, 7} Associate professor

Department of ophthalmology, 20 Aout 1953 teaching hospital, University hospital center Ibn Rochd, Casablanca, Morocco

Summary:

Methanol poisoning may lead to severe complication such as severe visual dysfunction, metabolic disturbances, permanent neurological dysfunction and even death. We report the case of toxic optic neuropathy induced by inhalation abuse of methanol as an uncommon route of intoxication. The diagnosis of methanol poisoning was made on the basis of methanol inhalation abuse, metabolic acidosis, visual dysfunction and MRI findings. . Intravenous methylprednisolone was administered 8 days after the intoxication due to delay of consultation without significant improvement. Steroids seem to have an effect on established ocular inflammation which is the well-reported mode of presentation in cases of acute methanol poisoning and should be introduced as early as possible.

Key words: methanol, optic nerve, intoxication, Inhalation, diluent, steroids.

Date of Submission: 08-07-2021

Date of Acceptance: 23-07-2021

I. Introduction :

Methanol (CH₃OH) is a toxic volatile alcohol that is found in various household and industrial agents. Methanol intoxication may occur as a result of accidental consumption of methanol-contaminated alcoholic beverages, deliberate or accidental ingestion of methanol containing products and rarely inhalation of methanol fumes in chemical industries or inhalation abuse. Several symptoms and signs may arise, with the most common ones being related to the central nervous system, the eyes and the gastrointestinal tract. Methanol poisoning may lead to severe complication such as severe visual dysfunction, metabolic disturbances, permanent neurological dysfunction and even death. Death from methanol toxicity has been reported to range between 8-36% and permanent loss of vision has been observed in another 20-40% of patients who survive the acute injury.

We report the case of toxic optic neuropathy induced by inhalation abuse of methanol as an uncommon route of poisoning.

II. Case Report:

A 22-year-old patient presented to the ophthalmology emergency department with 8 days history of fatigue, headache and progressive, painless loss of vision in both eyes after inhaling a rag soaked with carburetor cleaner for several hours.

She had a history of chronic solvent abuse for four years, alcohol ingestion and tabagism, but denied other substances abuse.

The physical examination and vital data were normal. The neurological evaluation including motor, sensory, and cerebellar system examination showed generalized hyperreflexia and severe reduction of the direct and consensual photo motor reflex responses.

On examination, visual acuity was light perception in both eye with bilateral mydriasis. The fundus exam revealed stage three papilledema in both eyes with mild tortuosity of retinal vessels at posterior pole.

Magnetic resonance imaging showed bilateral symmetric T2 signal hyperintensity with contrast enhancement of the optic nerves (figure1).

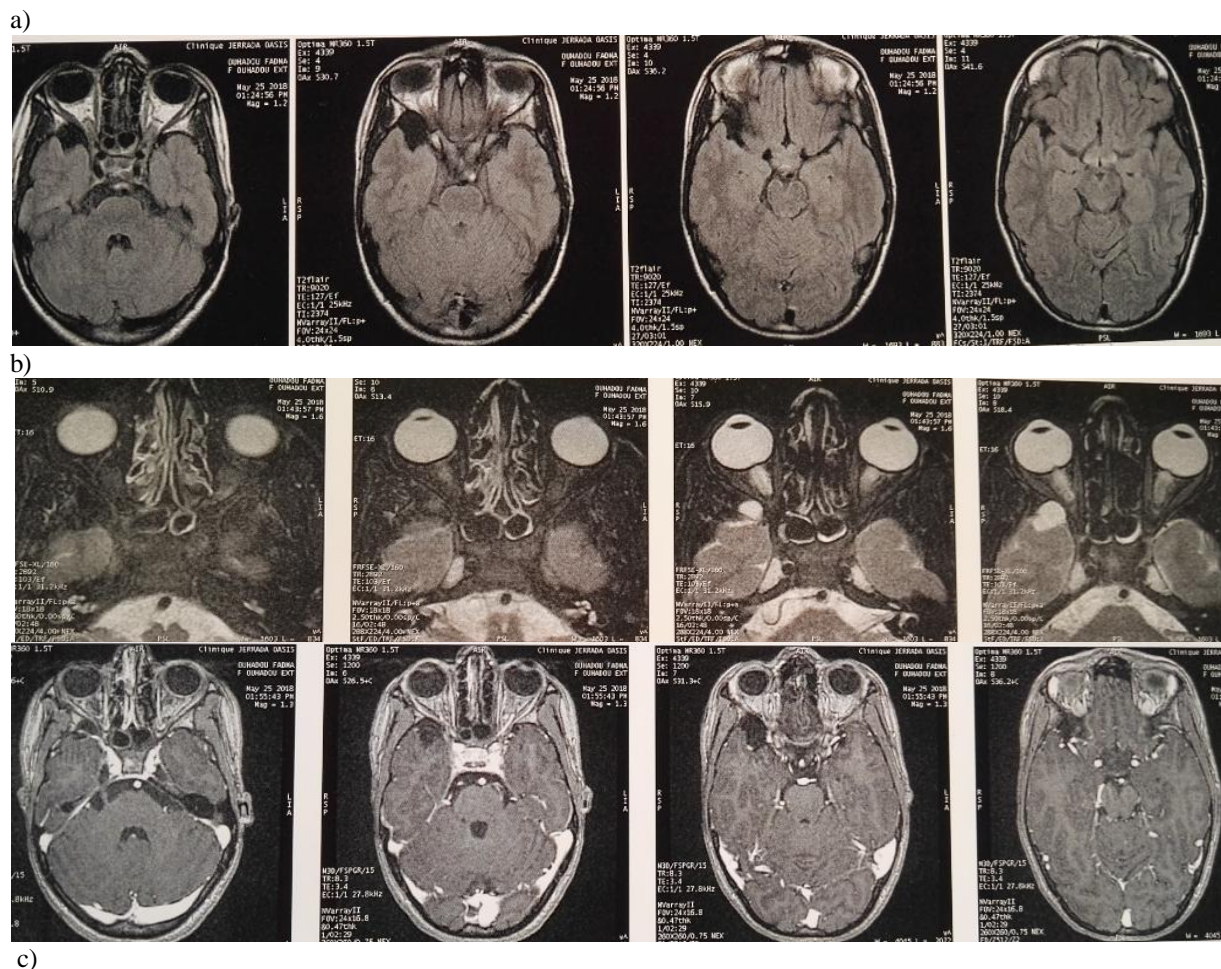


Figure 1: Cranio orbital MRI scans :a) T1 weighted b) T2 weighted c) Contrast dye injection

The patient had arterial gasometry and acidotic respiratory pattern revealing a pH at 7.28, a PCO_2 at 20 mmHg and HCO_3^- at 9 mEq/L.

The diagnosis of methanol poisoning was made on the basis of methanol inhalation abuse, metabolic acidosis, visual dysfunction and MRI findings. The methanol level in blood was not checked because of the non-availability of standardized protocol and equipments.

The antidote Fomepizol or ethanol was unavailable. The patient received sodium bicarbonate and vigorous venous hydration. Intravenous methylprednisolone 1g once-daily was administered for 3 consecutive days continued with oral prednisone at 1 mg/kg along with neurotrophic and vasodilation drugs.

The best corrected visual acuity was 2.00 logMar in both eyes after 1 month of treatment. The visually evoked potential was abnormal with a delay of the P100 at 150.10 ms on the right eye and 154.2ms on the left eye.

The dosage of prednisone was tapered gradually without further visual improvement. An inhalant-specific treatment programs were required for detoxification.

III. Discussion:

The vast majority of methanol intoxications are due to ingestion. Inhalation is the most important route during labor exposure. The inhalation abuse represents an uncommon route for intoxication. More than 1,000 products, some of which contain methanol, are available for abuse as inhalants and can produce varying degrees of toxicity, although methanol toxicity is rare(1).

Clinical manifestations of pure methanol toxicity initiate within 0.5–4 h after exposition and include gastrointestinal disorders (nausea, vomiting, and abdominal pain) and central nervous system suppression (confusion and drowsiness). Depending on the absorbed dose, after a latent period of 6–24 h, decompensated metabolic acidosis occurs with blurred vision, photophobia, diplopia and early or late blindness(2).

In a comprehensive experimental study by Hayreh et al., it was shown that methanol optic neuropathy is a toxic neuropathy resulting from swelling of the cytoplasm of oligodendroglial in contact with the axons and of the astrocytes in the retrolaminar optic nerve and the intraorbital optic nerve without any vascular lesion. The

combination of metabolic acidosis and formic acid inhibition of cytochrome c oxidase in the optic nerve results in histotoxic hypoxia, which is responsible for the ocular and central nervous system toxicity of methanol(3).

Ocular toxicity results in visual defects, ranging from blurred vision to “snowfield vision” or total blindness in severe poisoning(2). Visual disorders caused by formate metabolites may occur up to 72 h after ingestion (4). Vision loss may not be symmetric. Central scotoma, hyperemia, pallor of the optic disc, papilledema, and an afferent papillary defect are described as the most common findings. Electroretinography may demonstrate a diminished b-wave(5,6). Additionally, optical coherence tomography, may demonstrate peripapillary nerve fiber swelling and intraretinal fluid accumulation(7)

The specific diagnosis of methanol intoxication is given by the measurement of this alcohol in the blood. However, such practice is not available in the clinical routine. In the absence of clinical history, the diagnosis is supported by metabolic acidosis with Gap anion and increased osmolar Gap, that is, the osmolality measured is greater than the one calculated(8) In the patient above the diagnosis was facilitated by the clinical history and laboratory findings.

Treatment recommendations for methanol toxicity include intravenous sodium bicarbonate and folic acid. Guidelines indicate that an antidote, preferably fomepizole (rather than ethanol) should be given when the serum methanol concentration is ≥ 20 mg/d. Hemodialysis along with an antidote should be initiated when the serum methanol concentration is ≥ 50 mg/d(8,9).

Some authors have suggested that lower levels of serum methanol are achieved through inhalation versus ingestion, thus resulting in lower rates of complications. However, serum methanol levels ≥ 50 mg/dL were seen in 28% of patients included in a study regarding methanol toxicity secondary to inhalant abuse in adult men(10). No permanent sequelae were observed in these patients despite the fact that seven patients did not receive hemodialysis, which was indicated according to current treatment guidelines.

The treatment regimens including the use of ethanol, fomepizole, folic acid, sodium bicarbonate, and hemodialysis, etc. prevent the formation of formic acid and further toxicity, but do not have any effect on established ocular inflammation which is the well-reported mode of presentation in cases of acute methanol poisoning(11). In a report, Shukla et al. used intravenous methylprednisolone for 3 days followed by oral prednisolone, which resulted in a significant visual improvement in all of the patients except one (11).

A retrospective cohort study included 8 consecutive patients seen at the Beijing Tongren Hospital of Capital Medical University, Beijing, China presenting with optic neuritis due to methanol intoxication who were treated with intravenous methylprednisolone 1000 mg for 3 days, 500 mg for 3 days, followed by oral prednisolone and B vitamins. The visual function of 10 eyes in 5/8 patients got improved and 6 eyes in 3/8 patients had no improvement in visual function after the above treatments(12). Longer methanol-contact time (>5 years), elderly (61-year-old), and delayed treatment (> 1 month) were associated with poor visual outcome.

Abrishami et al. propose the use of high-dose IV corticosteroid for preventing the toxic effects of methanol optic neuropathy. The treatment seems to inhibit the demyelination process and may prevent blindness, without the use of other treatments such as ethyl alcohol and vitamin B1 or B6. It also prevents retinal atrophy(13). Initiating treatment as soon as possible is very important, because it was shown that after 6 days the treatment has no efficacy. In our case, despite the steroid therapy, only a slight functional improvement was noted probably due to the delay of consultation and therefore therapeutic management.

IV. Conclusion:

Intentional inhalation of methanol fumes may produce toxicity. Clinicians need to thoroughly question patients, regarding their possible toxic habits while investigating cases of optic neuritis. Intravenous steroids should be quickly introduced while managing optic nerve methanol toxicity as it seems to have promising results.

References:

- [1]. Johnson LD, O'Malley PM, Bachman JG. Monitoring the Future: National Results on Adolescent Drug Use: (400412005-001) [Internet]. American Psychological Association; 2003 [cited 2021 Jul 3].
- [2]. Nekoukar Z, Zakariaei Z, Taghizadeh F, Musavi F, Banimostafavi ES, Sharifpour A, et al. Methanol poisoning as a new world challenge: A review. *Ann Med Surg.* 2021 Jun 2;66:102445.
- [3]. Sharpe JA, Hostovsky M, Bilbao JM, Rewcastle NB. Methanol optic neuropathy: A histopathological study. *Neurology.* 1982 Oct 1;32(10):1093–1093.
- [4]. Newman N, Biousse V. Diagnostic approach to vision loss. *Contin Minneap Minn.* 2014 Aug;20(4 Neuro-ophthalmology):785–815.
- [5]. Bennett IL, Cary FH, Mitchell GL, Cooper MN. Acute methyl alcohol poisoning: a review based on experiences in an outbreak of 323 cases. *Medicine (Baltimore).* 1953 Dec;32(4):431–63.
- [6]. Onder F, Ilker S, Kansu T, Tatar T, Kural G. Acute blindness and putaminal necrosis in methanol intoxication. *Int Ophthalmol.* 1998 1999;22(2):81–4.
- [7]. Fujihara M, Kikuchi M, Kurimoto Y. Methanol-induced retinal toxicity patient examined by optical coherence tomography. *Jpn J Ophthalmol.* 2006 Jun;50(3):239–41.
- [8]. Barceloux DG, Bond GR, Krenzelok EP, Cooper H, Vale JA, American Academy of Clinical Toxicology Ad Hoc Committee on the Treatment Guidelines for Methanol Poisoning. American Academy of Clinical Toxicology practice guidelines on the treatment of methanol poisoning. *J Toxicol Clin Toxicol.* 2002;40(4):415–46.

- [9]. Kraut JA, Kurtz I. Toxic alcohol ingestions: clinical features, diagnosis, and management. *Clin J Am Soc Nephrol CJASN*. 2008 Jan;3(1):208–25.
- [10]. Wallace EA, Green AS. Methanol toxicity secondary to inhalant abuse in adult men. *Clin Toxicol Phila Pa*. 2009 Mar;47(3):239–42.
- [11]. Shukla M, Shikoh I, Saleem A. Intravenous methylprednisolone could salvage vision in methyl alcohol poisoning. *Indian J Ophthalmol*. 2006 Mar;54(1):68–69.
- [12]. Ma Z, Jiang H, Wang J. Clinical analysis of severe visual loss caused by inhalational methanol poisoning in a chronic process with acute onset: a retrospective clinical analysis. *BMC Ophthalmol*. 2019 Jun 7;19(1):124.
- [13]. Abrishami M, Khalifeh M, Shoayb M, Abrishami M. Therapeutic Effects of High-Dose Intravenous Prednisolone in Methanol-Induced Toxic Optic Neuropathy. *J Ocul Pharmacol Ther*. 2011 Jun 1;27(3):261–3.

CONFLICT OF INTEREST

The authors declare no conflict of interest.

Contribution of the authors:

All the authors participated in the care of the patient and the writing of the manuscript. All authors have read and approved the final version of the manuscript.

Raid Soumaya, et. al. "Methanol Induced Toxic Optic Neuropathy: Case Report." *IOSR Journal of Dental and Medical Sciences (IOSR-JDMS)*, 20(07), 2021, pp. 32-35.