

Oral lichen planus mimicking herpes associated erythema multiforme on the lips: A case report

Nelly Nainggolan¹, Wahyu Hidayat², Dewi Kania Intan Permatasari¹

¹Resident, Department of Oral Medicine, Universitas Padjadjaran, West Java, Indonesia

²Lecturer, Department of Oral Medicine, Universitas Padjadjaran, West Java, Indonesia

Abstract:

Oral Lichen Planus (OLP) is a chronic mucocutaneous inflammatory disease that often affects the bilateral buccal mucosa, tongue, and gingiva, but rarely occurs on the palate and lips. This case report aims to describe the occurrence of OLP on the lips in a 49-year-old woman, which occurred for about 3 months before, and clinically appear to be similar with Herpes Associated Erythema Multiforme (HAEM). On examination, there were erosive lesions with crusting on the lips and erosive lesions on the buccal mucosa. The patient received systemic and topical corticosteroid and multivitamin. After 2,5 months, lesions on the lips experienced significant healing. OLP on the lips is a rare case, making it harder to recognise, difficult to detect, and causing misdiagnosis. HAEM was ruled out due to the chronicity of lesions, no history of fever, and after the lesions on the lips had healed, there was a white striae appearance on the upper and lower lips. Correct identification of the lesions on the lips is very important because several lesions similar to other diagnoses such as HAEM that it will determine the acceleration of healing and prevent the development of malignancy.

Key Words: Oral lichen planus; Lips; Herpes associated erythema multiforme; Mimicking.

Date of Submission: 05-06-2021

Date of Acceptance: 18-06-2021

I. Introduction

Oral Lichen Planus (OLP) is a chronic inflammatory disease that affects the stratified squamous epithelium in the oral cavity with an unknown etiology and a result of autoimmune process¹⁻⁵. The prevalence of OLP in the general population is around 0.1% - 4% and more common in perimenopause women. OLP has the tendency to occur in 30 – 60-year-olds, although it can affect individuals of any age⁴.

Erythema multiforme (EM), is an acute, recurrent, self-limited mucocutaneous inflammatory disease, manifesting on the skin, most commonly on the oral mucosa⁶. EM can be triggered by several factors, including the herpes simplex virus (HSV) causing herpes associated erythema multiforme (HAEM) and due to drugs, known as drug induced erythema multiforme (DIEM)⁷. EM usually affects young adults aged 20-40 years, however 20% of cases occur in children. Viral infection can reach up to 70% of cases⁸.

The occurrence of OLP in the oral cavity generally affects the bilateral buccal mucosa, tongue and gingiva, but rarely affects the palate and the lips¹. OLP incidence on the lips is unknown^{9,10}, other than those limited to case reports¹⁰. The results of a literature review conducted by Hasan from 1937 – 2017 only provides 26 case reports with the total of 30 people showing OLP on the lips. Among those, 23 patients had OLP on the lower lip, 3 on the upper lip, 3 on the lower and upper lips and 1 patient on unmentioned site. As for the gender, 18 patients were men, 8 were women, and 4 of undisclosed gender⁴. OLP on the lips has also been reported by Rekha *et al.* (2018) on the upper and lower lips⁵. Chintagunta *et al.* (2018), Mathur *et al.* (2018), Gupta *et al.* (2019) each reports 9, 1 and 1 case involving only the lower lip¹⁰⁻¹². The prevalence on buccal mucosa is usually around 80-90% of OLP cases¹³, whereas on the lips it ranges between 0.5 to 8.9% and among the six clinical variations of OLP, the atrophic and erosive types are the most common types to appear on the lips^{1,10}.

This prevalence indicates that OLP on the lips is a rare case and even when it occurs more frequently appear on lower lip, followed by lesions appearing almost simultaneously on the both of the lips, and only on the upper lip^{4,9,10}. This case report aims to describe the rare occurrence of OLP on the lips, in a 49-year-old woman, which clinically appear mimicking HAEM.

II. Case Report

A-49-year-old woman patient came to the Dental and Oral Hospital, with a chief complaint of ulceration and pain on the lips since about 3 months before. The patient had a history of burning pain when consuming spicy food, history of diabetes mellitus and regularly took metformin. She had no history of fever, hypertension, taking medication before onset of the lesions. The patient used betel leaf decoction but there was no improvement and instead it got more widespread.

On extra-oral examination, the upper lip was dry and there were painless white striae. On the lower lip there was a painful erosive lesion with crusts of size 1 cm x 0.5 cm and 3 cm x 1.5 cm approximately. Intra oral examination showed erosive lesions surrounded by white striae, 3 cm x 1.5 cm and 1.5 cm x 1 cm in size on the left and right buccal mucosa. There was a single 0.5 cm, painless white striae on the right side of the tongue (Figure 1). This case was initially diagnosed as erosive lichen planus on the buccal mucosa and suspected HAEM on the lips with a differential diagnosis of DIEM. Patient was then recommended to be tested for HSV-1 IgG and showed reactive result. Initial therapy was given in the form of topical corticosteroids for the oral cavity and lips and compressed the lips with 0.9% sodium chloride (NaCl).

At the 4th visit, (5 weeks later) there was hemorrhagic crust on the lower lip and erosive lesions of the buccal mucosa were expanding (Figure 2). Due to these conditions, systemic corticosteroid therapy was given. On the 10th week, the erosive lip lesions healed and improved (Figure 3). However, the white striae on the upper and lower lips were still apparent. The erosive lesions on the buccal mucosa began to heal after approximately 3 months of treatment.

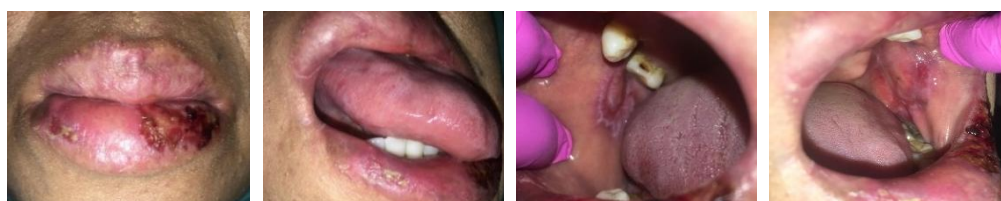


Figure 1: Clinical features of lips and buccal mucosa at the first visit.

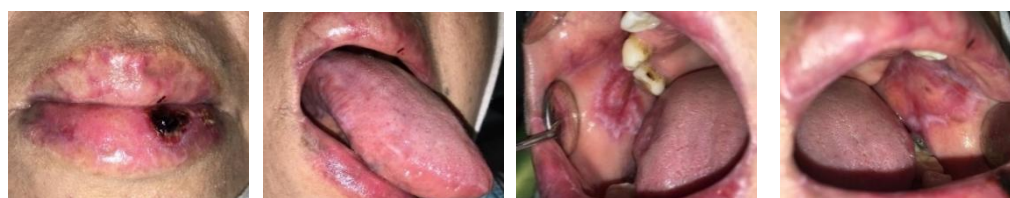


Figure 2: Clinical appearance of lips and buccal mucosa at fifth week.

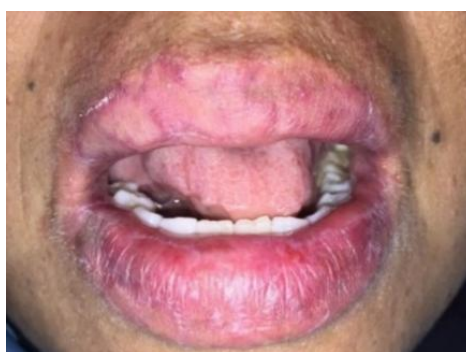

Figure 3: Clinical features showed a white striae on the lips at tenth week.

III. Discussion

Lichen planus (LP), first reported in 1869 by Dr. Erasmus Wilson and is related to a T-cell mediated immune response^{12,13}. The etiology of LP is unknown. However, several predisposing factors such as drugs (anti-malaria, diuretics, antiretrovirals, ACE inhibitors, NSAIDs), dental restorative materials (dental amalgams, composite and resin based materials, metals), immune system conditions, (chronic hepatitis), infectious agent (herpes simplex virus, Epstein Barr virus, cytomegalovirus, hepatitis C virus), irritants (alcohol, smoking, tobacco chewing), genetics, diabetes mellitus and hypertension, hypothyroidism and bowel diseases, and also stress may cause LP^{2,3,5,14}. In this patient, there was history of diabetes mellitus and consumed metformin regularly. Patient also admitted that she was under stress condition, which is considering to be the cause of OLP. According to Rekha *et al.*, OLP shows a high prevalence caused by diabetes mellitus and the use of antidiabetic drugs also plays a role in the occurrence of OLP⁵. Stress is known to be the most common cause of acute exacerbation of the disease¹⁴.

There are several types of OLP, reticular, papular, plaque-like, erosive, atrophic and bullous types¹⁴. The reticular type is usually asymptomatic, while the erythematous and erosive types may cause pain and

discomfort¹⁴. In this case, the clinical examination was found in the form of erosive lesions surrounded by white striae, indicative of erosive type on the buccal mucosa along with erosive lesions with crusts surrounded by white striae on the lips. Erosive lesions surrounded by reddish areas and covered with hemorrhagic crusts on the lower lip have also been reported by Hasan,⁴ and Chintagunta *et al.*,¹⁰.

OLP is usually diagnosed based on clinical and historical examination and should be confirmed by biopsy, if suspected. However, in classic lesions, i.e. bilateral reticular type, it is possible to make diagnosis based on clinical appearance alone¹⁵. In this case, the patient refused having biopsy. Manifestation of erosive type OLP on the lips is often difficult to diagnose since it sometimes has similar picture with other lesions. This lesion can be diagnosed differentially as herpes simplex lesions, actinic cheilitis, oral lichenoid lesions, discoid lupus erythematosus, autoimmune blistering diseases and early carcinoma *in situ*^{4,12}. Most of these abnormalities on the lips may show certain characteristics and can sometimes be easily identified. However, the occurrence of similar lesions on the lips may cause diagnosis and therapeutic dilemma for dentists. Early identification and diagnosis can be made with a history of the lesion, previous symptoms, and associated habits¹⁶.

Herpes simplex virus (HSV) causing EM, known as HAEM may present a feature of oral lesions of erythematous macules followed by epithelial necrosis, multiple bullae and superficial ulcerations lined with yellow fibrinous pseudomembrane, with irregular borders, halo of inflammation, and bleeding that can be seen on the lips¹⁷. In this patient, the appearance of lesions on the lips in the form of crusts gave a similar feature with EM where crust-like appearance on the lips is also seen. Patient showed no history of taking medication before the appearance of the lesions. Patient was then recommended to be tested for HSV-1 IgG. This examination showed an increase in titer, causing dilemma when establishing a diagnosis of lesions on the lips. In a study conducted by Park *et al.*, that studied the relevance of HSV infection to OLP, 30 patients diagnosed with OLP showed increase in HSV-1 and HSV-2 IgG serum level, but HSV DNA was not detected in PCR biopsy specimens¹⁸. Based on these findings, the increase of HSV-1 IgG titer in OLP does not always indicate the presence of HSV virus in the lesion. This is a contrast with EM, where HSV DNA is found in erythema multiforme tissue¹⁸. EM begins with an acute onset and usually mild or without any prodromal symptoms, in contrast to OLP which is chronic and rarely resolve on their own if lesions occur^{4,8,19}. HAEM was ruled out based on the anamnesis because the lesions on the lips occurred without history of fever, the chronicity of lesions (5,5 months duration) and after the erosive lesions healed, white striae on the upper and lower lips were still apparent.

OLP treatment aims to relieve pain symptoms, minimize the effects of the disease and the risk of oral cancer, maintain good oral hygiene, and eliminate the local exacerbating factors as preventive measures⁵. Treatment options are usually based on professional experience and consideration the severity and extent of the lesion. The erosive lesion is one of lesions that require drug therapy because of severe pain²⁰. The goals and importance of diagnosis and treatment of lip lesions are not limited to preventing morbidity and mortality, but also associated with aesthetic problems and to maintain patients' social acceptance and self-esteem¹⁶. The patient was treated with topical corticosteroids, followed by systemic corticosteroids due to the widespread lesions, to act as anti-inflammatory and immunosuppressant⁵, while the use of NaCl on the lips and the administration of multivitamin aims to accelerate healing in lesions. In addition to the use of drugs, in connection with the exacerbation of OLP, stress and anxiety management are recommended, along with psychological counselling when necessary⁵.

The presence of erosive type of OLP on the lips must be aware because the erosive and atrophic forms have a higher potential for malignant transformation²¹. Therefore, proper diagnosis and management of the lesions are necessary^{1,12}.

IV. Conclusion

OLP on the lips is a rare condition and it is sometimes hard to detect, leading to misdiagnosis. The clinical appearance of erosive lesions with crusts on the lips mimics the appearance of HAEM. The chronicity of the lesions, no history of fever, and the presence of white striae after healing lead to the diagnosis of OLP. Correct identification of lesions on the lips are very important because there are several lesions that are similar to HAEM and proper diagnosis will determine the speed of healing and prevent the development of malignancy.

References

- [1]. Nuzzolo P, Celentano A, Bucci P, Adamo D, Ruoppo E, Leuci S, et al. Lichen planus of the lips: an intermediate disease between the skin and mucosa? Retrospective clinical study and review of the literature. *Int J Dermatol*. 2016;55(9):e473–81.
- [2]. Samal DK, Behera G, Gupta V, Majumdar K, Khurana U. Isolated Lichen Planus of Lower Lip: A Case Report. *Indian J Otolaryngol Head Neck Surg*. 2015;67(Suppl 1):S151–3.
- [3]. Asthana A, Singh AK, Pathak AK. A Review of Lichen Planus : Etiopathogenesis and management. *Int J Sci Res*. 2019;8(6):24–7.
- [4]. Hasan S. Lichen Planus of Lip- Report of a rare case with review of literature. *J Fam Med Prim Care*. 2019;8(3):1269–75.
- [5]. Rekha SM, Annigeri AB, Galgali SR, P J. Multivariant lichen planus of lips and gingiva : Report of a case and a review. *Int J Oral Heal Sci*. 2018;8:109–15.

- [6]. Shrihari TG, Shetty SR. Erythema Multiforme : A Mysterious Lesion! Indian J Med Paediatr Oncol. 2018;39:363–7.
- [7]. Challacombe SJ, Setterfield JF. Oral Vesicular and Bullous Lesions. In: Contemporary Oral Medicine. 2019. p. 1106–11.
- [8]. Issrani R, Prabhu N. Etiopathogenesis of Erythema Multiforme - A Concise Review. Adv Dent Oral Heal. 2017;5(4):1–5.
- [9]. Nico MM, Fernandes JD, Lourenco SV. Lichen Planus Affecting the Lips. J Clin Exp Dermatol Res. 2015;06(06):1–4.
- [10]. Chintagunta SR, Sana SN, Gopidi PJ. Ulcerative lichen planus of lower lip- Case series. J DrNTR Univ Heal Sci. 2018;7:288–91.
- [11]. Mathur M, Acharya P, Karki A, Nisha KC, Shah J, Jha A. Isolated lichen planus of lip: Diagnosis and treatment monitoring using dermoscopy. Clin Case Reports. 2019;7:146–8.
- [12]. Gupta P, Dhanta A, Mainra A. Lichen Planus Mimicking Actinic Cheilitis : A Case Report . IOSR J Dent Med Sci. 2019;18(8):74–7.
- [13]. Gorouhi F, Davari P, Fazel N. Cutaneous and Mucosal Lichen Planus : A Comprehensive Review of Clinical Subtypes , Risk Factors , Diagnosis , and Prognosis. Sci World J. 2014;2014:1–22.
- [14]. Moraes M de, Matos FR, Pereira J dos S, Medeiros AMC, Silveira EJD. Oral lichen planus : two case reports in male patients. Rev Odonto Ciênc. 2010;25(2):208–12.
- [15]. Alrashdan MS, Cirillo N, McCullough M. Oral lichen planus: a literature review and update. Arch Dermatol Res. 2016;308(8):539–51.
- [16]. Patil S, Maheshwari S. Prevalence of lip lesions in an Indian population. J Clin Exp Dent. 2014;6(4):374–8.
- [17]. Kamala K., L. A. Annigeri RG. Herpes associated erythema multiforme. Contemp Clin Dent. 2011;2(4):372–5.
- [18]. Park S-Y, Choi EH. Relevance of Herpes Simplex Virus Infection to Oral Lichen Planus. Univers J Med Sci. 2014;2(3):25–30.
- [19]. McCullough M., Alrashdan M., Cirillo N. Oral lichen planus. In: Contemporary Oral Medicine. Springer Nature Switzerland AG; 2019. p. 1043–82.
- [20]. Farhi D, Dupin N. Pathophysiology, etiologic factors, and clinical management of oral lichen planus, part I: facts and controversies. Clin Dermatol. 2010;28:100–8.
- [21]. Chebil RB, Eya M, Zakhama A, Hamdi H. Malignant Transformation of Labial Lichen Planus : A Rare Case Report. South Asian Res J Oral Dent Sci. 2019;1(1):19–23.

Nelly Nainggolan, et. al. “Oral lichen planus mimicking herpes associated erythema multiforme on the lips: A case report.” *IOSR Journal of Dental and Medical Sciences (IOSR-JDMS)*, 20(06), 2021, pp. 15-18.