

## Dexmedetomidine as an adjuvant to ropivacaine in ultrasound-guided supraclavicular brachial plexus Block: A randomized controlled trial

Nusrat Jehan<sup>1</sup>, Mubasher Ahmad<sup>2</sup>, Arshi taj<sup>3</sup>

<sup>1,3</sup>(Associate Professor, Department of Anaesthesiology and Critical Care, GMC Srinagar, J&K India)

<sup>2</sup>(Assistant Professor, Department of Anaesthesiology and Critical Care, GMC Srinagar, J&K India)

---

### Abstract

**Background:** Adjuvants are frequently added to local anaesthetics to prolong analgesia following peripheral nerve blockade. The present study evaluated the effect of adding dexmedetomidine as an adjuvant to 0.5% ropivacaine for ultrasound guided supraclavicular brachial plexus block(SCB) in patients undergoing upper limb orthopaedic surgeries.

**Material and Methods:** The 72 eligible patients randomised into two groups of 36 each by flipping the coin. Those getting heads on the coin received block with dexmedetomidine 1 µg/kg (1 mL) with 25 mL ropivacaine 0.5% and those getting tails received 25 mL ropivacaine 0.5% only with 1 mL normal saline. All the patients received Ultrasound guided supraclavicular block under all the aseptic precautions. The various parameters noted were onset of sensory block, onset of motor block, total duration of block and time for first rescue analgesia. The parametric data were expressed as means ± standard deviation and one way student t-test was utilised to compute the p-value. A p-value of < 0.05 was taken as significant.

**Results:** The duration of sensory and motor block were significantly prolonged in group RD (556.61 ± 31.18 min and 516.43 ± 25.21 min) as compared to group R (512.14 ± 33.16 min and 482.19 ± 27.24 min) P < 0.05. The total duration of analgesia was significantly prolonged in group RD (597.92 ± 41.17 min) and the total analgesic consumption was also lesser in group RD (112.82 ± 11.19 mg) p < 0.05.

**Conclusion:** Dexmedetomidine as an adjuvant to 0.5% ropivacaine in supraclavicular block significantly prolongs the duration of analgesia.

**Key Words:** Dexmedetomidine, Ropivacaine, Ultrasound

---

Date of Submission: 30-05-2021

Date of Acceptance: 13-06-2021

---

### I. Introduction

Supraclavicular approach is considered to be the most effective approach to block brachial plexus for upper limb surgeries. with the advent of ultrasound (US) guidance which provides real time view of brachial plexus and block which in turn not only increased the success rate but also brought down the complications<sup>1</sup>.

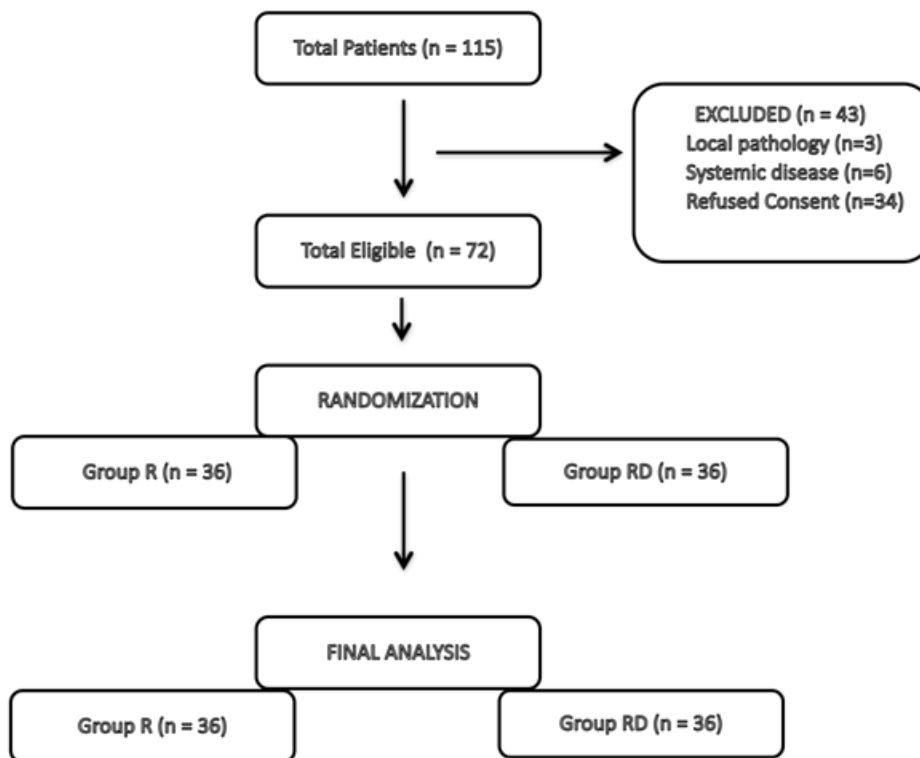
Adjuvants are frequently added to local anaesthetics to prolong analgesia following peripheral nerve blockade. α<sub>2</sub> adrenergic receptor agonists have been the focus of interest for their sedative, analgesic perioperative sympatholytic and cardiovascular stabilising effects with reduced anaesthetic requirements<sup>2</sup>. Dexmedetomidine a potent α<sub>2</sub> adrenoceptor agonist has shown to prolong the duration of block and postoperative analgesia when added to local anaesthetics in various regional blocks<sup>3</sup>.

In our study we evaluated the effect of adding dexmedetomidine as an adjuvant to 0.5% ropivacaine for ultrasound guided supraclavicular brachial plexus block(SCB) in patients undergoing upper limb orthopaedic surgeries. The primary outcome was the duration of analgesia. Secondary outcomes include the time to onset of and duration of sensory and motor blockade, and side-effects, if any.

### II. Materials & Methods

This study was carried out in a tertiary care hospital over a period of 12 months from January 2018 to January 2019. Ours was a prospectively randomised controlled study on patients undergoing upper limb surgical procedures under regional supraclavicular block. A prior ethical committee clearance was obtained for the study (GMC-093/18). Inclusion criteria included American Society of Anaesthesiologists (ASA) physical status I and II patients of either sex, aged 18 – 60 years, weighing 45 – 85 kg who underwent various elective surgeries on the upper

**FIGURE 1. THE CONSORT FLOW DIAGRAM OF THE SELECTED PATIENTS**



extremities below the mid-humerus level. Patients who had local pathology at the site of injection, pre-existing peripheral neuropathy of upper limb, suspected brachial plexus injury, history of any systemic disease, convulsion, known hypersensitivity to the study drugs, bleeding disorders, pregnant women, and psychiatric patients were excluded from the study. Those patients who did not cooperate or refused to participate in the study were also excluded. A written and informed consent was obtained from the patients on preanesthetic check up after complete explanation of the study protocol and the procedure.

During the study period a total of 115 patients underwent upper limb surgical procedures under supraclavicular block. Out of these 72 were found eligible for the study. The CONSORT flow diagram of the study is shown in Figure 1. The eligible patients were randomised into two groups of 36 each by flipping the coin. Those getting heads on the coin received block with dexmedetomidine 1 µg/kg (1 mL) with 25 mL ropivacaine 0.5% and those getting tails received 25 mL ropivacaine 0.5% only with 1 mL normal saline. The patients were placed in supine position with head turned to the opposite side and the ipsilateral arm adducted. All the patients received US (SonoSite M Turbo high frequency 6-13Hz linear probe) guided supraclavicular block under all the aseptic precautions. All the blocks were given by experienced anaesthesiologists who did not play any role in assessing the patients intra and postoperatively.

The various parameters noted were onset of sensory block, onset of motor block, total duration of block and time for first rescue analgesia (diclofenac 75 mg), which was administered when VAS score was more than 4 or on patient's demand. Patients were evaluated for onset of sensory block every 3 min after completion of injection till 30 minutes and then every 30 min after the end of surgery till the first 12 hours, and thereafter, hourly until the block had completely worn off. The sensory block was assessed by the pinprick sensation with a blunt 25G hypodermic needle in all dermatomes innervated by the brachial plexus (C5 - T1) in the distribution of median, radial, ulnar, and musculocutaneous nerves. Sensory block was graded as: Grade 0 = Sharp pin sensation felt, Grade 1 = Analgesia, dull sensation felt, Grade 2 = Anaesthesia, no sensation felt. The onset time of the sensory block was taken as the time from injection of local anaesthetic into the brachial plexus to obtunding of pinprick sensation, i.e., sensory block grade 1. Duration of sensory block was defined as the time interval between the end of administration of local anaesthetic and complete recovery from anaesthesia in all dermatomes.

Motor blockade was assessed using Modified Bromage scale (MBS) for upper extremities: Grade 0 – able to raise the extended arm to 90° for a full 2 s; Grade 1 – Able to flex the elbow and move the fingers but unable to raise the extended arm; Grade 2 – Unable to flex the elbow but able to move the fingers; Grade 3 – Unable to move the arm, elbow, or fingers. The onset of motor block was defined as the time from injection to motor paralysis equivalent to Bromage score 2. The duration of motor block was defined as the time between onset of motor block to complete return of motor power, i.e., Bromage 0. Patient’s perception of pain was assessed using VAS (0–10), with 0 being no pain at all and 10 being the worst pain imaginable.<sup>[6]</sup> VAS score was measured at 6, 12, and 18 hours.

Intraoperative parameters that were measured included heart rate, noninvasive blood pressure, and partial pressure of oxygen were monitored throughout the procedure and also during the postoperative period. Hypotension was defined as 20% decrease in systolic blood pressure from the baseline. Bradycardia was defined as heart rate < 60 beats/min. Tachycardia was defined as heart rate > 100 beats/min.

The data thus obtained was tabulated and analysed by SPSS ver 22 for Mac (IBM Inc., Chicago, IL). The parametric data were expressed as means ± standard deviation and one way student t-test was utilised to compute the p-value. Chi-squared test was used to calculate the p-value for proportional data. A p-value of < 0.05 was taken as significant.

### III. Results

During study period 72 patients were randomised into two groups( Group R and Group RD) of 36 each.Both groups were comparable in terms of demographic profiles i.e; age, gender, ASA grade, weight, height & BMI and operative data ( duration of surgery and tourniquet time) Table 1.

**Table no 1**

VARIABLE	GROUP R (n=36)	GROUP RD (n=36)	P Value
Age	32.34 ± 3.56	31.36 ± 4.16	0.7812
Gender (M/F)	23/13	22/14	0.9191
ASA Grade (I/II)	32/4	31/5	0.6734
Weight (kg)	62.54 ± 7.56	60.13 ± 6.17	0.8675
Height (cm)	168.84 ± 13.56	165.61 ± 11.18	0.9123
BMI (kg/m <sup>2</sup> )	21.34 ± 1.12	21.12 ± 1.16	0.8789
Duration of Surgery (min)	68.14 ± 10.56	66.34 ± 13.14	0.7812
Torniquet time (min)	70.19 ± 11.27	69.82 ± 11.19	0.9132

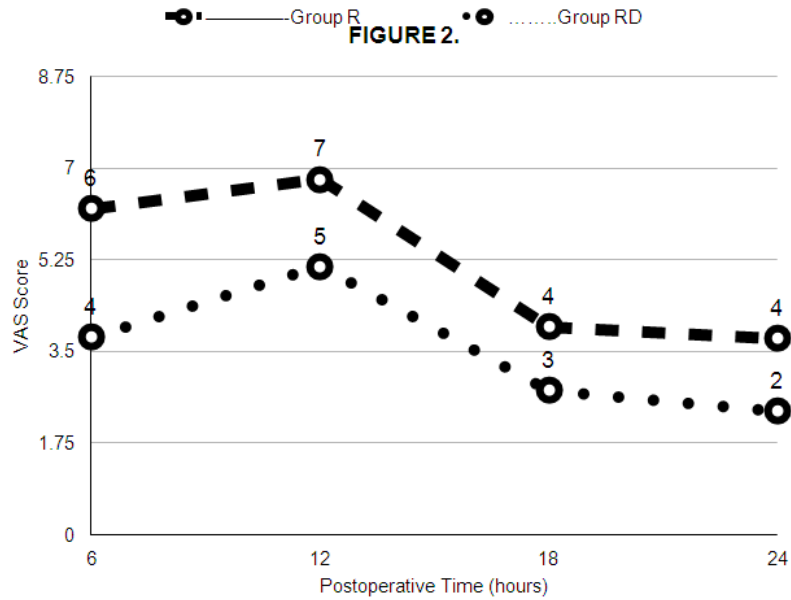
The sensory and motor block onset was shorter in group RD (5.06 ± 0.32 min and 9.23 ± 0.81 min) compared to group R (6.14 ± 0.51 min and 10.27 ± 0.93 min) P < 0.05 [ Table 2]. The duration of sensory and motor block were significantly prolonged in group RD (556.61 ± 31.18 min and 516.43 ± 25.21 min) as compared to group R (512.14 ± 33.16 min and 482.19 ± 27.24 min) P< 0.05 [ Table 2]. The total duration of analgesia was significantly prolonged in group RD ( 597.92 ± 41.17 min) and the total analgesic consumption was also lesser in group RD ( 112.82 ± 11.19 mg) and the difference was statistically significant between the two groups (P< 0.05) [Table 2].

**Table no 2**

VARIABLE	GROUP R (n=36)	GROUP RD (n=36)	P Value
Duration of Analgesia (min)	532.11 ± 39.29	597.92 ± 41.17	0.0001
Duration of motor block (min)	482.19 ± 27.24	516.43 ± 25.21	0.0212
Duration of sensory block (min)	512.14 ± 33.16	556.61 ± 31.18	0.0314
Onset of motor block (min)	10.27 ± 0.93	9.23 ± 0.81	0.0001
Onset of sensory block (min)	6.14 ± 0.51	5.06 ± 0.32	0.0011

Table no 2

VARIABLE	GROUP R (n=36)	GROUP RD (n=36)	P Value
Total analgesic consumption (mg)	148.32 ± 11.27	112.82 ± 11.19	0.0001



Comparison of mean VAS scores between the two groups showed statistically significant difference  $P < 0.05$  [Figure 2].

The only complication which was seen in both the groups was Horner's syndrome but the incidence was statistically insignificant ( $P > 0.05$ ). [Table 3]

Table no 3

Side effect/ Complication	Group R (N =36)	Group RD (N=36)	P value
Nausea	0	0	-
Vomiting	0	0	-
Dryness of mouth	0	0	-
Bradycardia	0	0	-
Hypotension	0	0	-
Horner's Syndrome	6 (16.67%)	7(19.44%)	0.0763
Hematoma	0	0	-
Pneumothorax	0	0	-
Local Anaesthetic systemic toxicity	0	0	-
Post Block Neuropathy	0	0	-

#### IV. Discussion

To date, there has been an increasing use of adjuncts (e.g., opioids and  $\alpha_2$ -adrenoreceptor agonists) to local anesthetics to improve the block quality. Many authors favour the hypothesis that dexmedetomidine prolongs the effect of local anesthetic by blocking the hyper-polarisation activated cation current<sup>4</sup>. In our study we evaluated the effectiveness of adding dexmedetomidine as an adjuvant to 0.5% ropivacaine for USG-guided

supraclavicular brachial plexus. We performed the block with 25 ml of 0.5% ropivacaine compared to 30 ml of 0.75% by Rashmi et al<sup>5</sup> and Mangal et al<sup>6</sup> so as to decrease the risk of increased total dose of local anesthetics. We used 1 µg/kg dexmedetomidine along with ropivacaine which is supported by the study reported by Moore et al<sup>7</sup>.

In our study, patient populations were comparable in both the groups [Table 1]. We found that using dexmedetomidine as an adjuvant to 0.5% ropivacaine in SCB had a significant influence on the onset of sensory and motor block [Table 2 and Figure 3]. Esmoglu et al.<sup>[8]</sup> also found that sensory and motor block time were significantly shorter in dexmedetomidine group than in the control group ( $P < 0.05$ ) in axillary plexus block using levobupivacaine. Similarly, Ammar and Mahmoud<sup>[9]</sup> used dexmedetomidine as an adjuvant to bupivacaine for ultrasound-guided infraclavicular block and found onset of sensory and motor block was significantly faster in dexmedetomidine group than in control group ( $P = 0.003$ ). While Swami et al.<sup>[10]</sup> also observed that onset of sensory and motor block was faster in dexmedetomidine group compared to clonidine group, but the difference was not statistically significant ( $P = 0.083$ ). The mean duration of analgesia in dexmedetomidine-ropivacaine group was significantly longer than duration in ropivacaine only group, which is supported by the study done by Bharti et al<sup>11</sup>. In their study, dexmedetomidine at 1µg/kg provided analgesic effect that lasted long as 17 hours which is 5 hours more than the duration of control group.

None of the patients had hypotension and maintained the hemodynamic parameters well within the normal range, which is similar to study conducted by Das et al<sup>12</sup> and Agarwal et al<sup>13</sup>. In our study none of the patients had bradycardia which was observed in studies conducted by Das et al<sup>12</sup> and Mangal et al<sup>6</sup> which can be explained due to different patient population and the use of lesser dose of ropivacaine in our study. Horner's syndrome was noted in both the groups but the difference was statistically insignificant ( $p > 0.05$ ) which is similar to study by Mangal et al<sup>6</sup>. There was no episode of hypoxemia or respiratory depression or pneumothorax during 24 hour postoperative period.

Our study may be criticised on the plea that we did not perform sedation scoring of the patients in the postoperative period. We did not do so as it was outside our study protocol and our primary aim was to see the onset and duration of the motor blockade. One of the limitations of our study is that it was not a blinded one, however, it was partially blinded as the pain scores were observed by the nursing staff in the postoperative ward, who were unaware about the study.

## References

- [1]. Halstead C. Great moments in the history of anaesthesiology. In: A Practice of Anesthesia. 7<sup>th</sup> ed. London, UK: Lloyd-Luke; 2003. p. 5.
- [2]. Murphy DB, McCartney CJ, Chan VW. Novel analgesic adjuncts for brachial plexus block: a systematic review. *Anesth Analg* 2000;90:1122-8.
- [3]. Rutkowska K, Knapik P, Misiolok H. The effect of dexmedetomidine sedation on brachial plexus block in patients with end-stage renal disease. *Eur J Anaesthesiol* 2009;26:851-5
- [4]. Brummett CM, Norat MA, Palmisano JM, Lydic R. Perineural Administration of Dexmedetomidine in Combination with Bupivacaine Enhances Sensory and Motor Blockade in Sciatic Nerve Block without Inducing Neurotoxicity in the Rat. *Anesthesiology*. 2008;109:502–11.
- [5]. Rashmi HD, Komala HK. Effect of Dexmedetomidine as an Adjuvant to 0.75% Ropivacaine in Interscalene Brachial Plexus Block Using Nerve Stimulator: A Prospective, Randomized Double-blind Study. *Anesth Essays Res*. 2017;11:134–9.
- [6]. Mangal V, Mistry T, Sharma G, Kazi Md, Ahuja N, Kulshrestha A. Effects of dexmedetomidine as an adjuvant to ropivacaine in ultrasound-guided supraclavicular brachial plexus Block: A prospective, randomized, double-blind study. *J Anaesthesiol Clin Pharmacol*. 2018 Jul-Sep; 34(3): 357–361.
- [7]. More P, Basavaraja, Laheri V. A comparison of dexmedetomidine and clonidine as an adjuvant to local anaesthesia in supraclavicular brachial plexus block for upper limb surgeries. *JMR*. 2015;1:142–7.
- [8]. Esmoglu A, Yegenoglu F, Akin A, Turk CY. Dexmedetomidine added to levobupivacaine prolongs axillary brachial plexus block. *Anesth Analg* 2010;111:1548-51
- [9]. Ammar AS, Mahmoud KM. Ultrasound-guided single injection infraclavicular brachial plexus block using bupivacaine alone or combined with dexmedetomidine for pain control in upper limb surgery: A prospective randomized controlled trial. *Saudi J Anaesth* 2012;6:109-14.
- [10]. Swami SS, Keniya VM, Ladi SD, Rao R. Comparison of dexmedetomidine and clonidine ( $\alpha_2$  agonist drugs) as an adjuvant to local anaesthesia in supraclavicular brachial plexus block: A randomised double-blind prospective study. *Indian J Anaesth* 2012;56:243-9.
- [11]. Bharti N, Sardana DK, Bala I. The Analgesic Efficacy of Dexmedetomidine as an Adjunct to Local Anesthetics in Supraclavicular Brachial Plexus Block: A Randomized Controlled Trial. *Anesth Analg*. 2015;121:1655–60.
- [12]. Das A, Majumdar S, Halder S, Chattopadhyay S, Pal S, Kundu R, et al. Effect of dexmedetomidine as adjuvant in ropivacaine-induced supraclavicular brachial plexus block: A prospective, double-blinded and randomized controlled study. *Saudi J Anaesth*. 2014;8(Suppl 1):S72–7.
- [13]. Agarwal S, Aggarwal R, Gupta P. Dexmedetomidine prolongs the effect of bupivacaine in supraclavicular brachial plexus block. *J Anaesthesiol Clin Pharmacol*. 2014;30:36–40.