

## Pigmented Villonodular Synovitis of Wrist

Dr. Ankur Kumar\*,

Assistant professor, Department of Orthopedics, Dr. D. Y. Patil Medical College, Hospital & Research, Pune

Dr. Purvam Jivrajani\*\*

Junior Resident, Department of Orthopedics, Dr. D. Y. Patil Medical College, Hospital & Research, Pune.

*Pigmented villonodular synovitis (PVNS) is a benign but locally aggressive lesion that may be located in joints, tendon sheaths, or bursae. These accounts for about 75 percent of cases. Other joints of the extremities have been reported, but with a lower incidence. The etiology of PVNS is controversial. Here we are reporting a case of pigmented villonodular synovitis of the wrist and its recurrence after excision surgery, which is common, sometimes leading to arthrodesis, arthroplasty and even radiation therapy. First approach is conservative surgical treatment with total synovectomy. The sensitivity of MRI permits early detection of the process and may obviate the need for radical management options in PVNS.*

Date of Submission: 10-06-2021

Date of Acceptance: 25-06-2021

### I. Case Report :

A 52 Year old male, truck-driver by profession, presented with complaints of pain and restricted movement of the right wrist since 1 year. The pain is radiating to the 2nd and 3rd finger and had gradually worsened and the patient was at times unable to sleep. The wrist was swollen and Phalen's maneuver and Tinel's sign were positive. Laboratory findings, ESR, leukocyte counts and C-reactive protein were normal. However, radiographs showed cystic lesions in the scaphoid, capitate and hamate bones (Fig.1). Electromyography showed signs of median nerve entrapment. A Tc-99 bone scan revealed increased uptake in the right wrist; on MRI (Fig. 2), joint effusion and volar hypertrophy of the synovial membrane were noted. The patient underwent carpal tunnel release and synovectomy; the synovial membrane was hypertrophied and dark brown. Histopathological examination identified the lesion as pigmented villonodular synovitis. Although symptoms improved over the next few days, but 5 months later the patient was readmitted, complaining of pain and severely limited wrist movement. Arthrodesis of the wrist was performed. Now 1 year later, the patient is almost free of pain, but wrist movement is still limited.

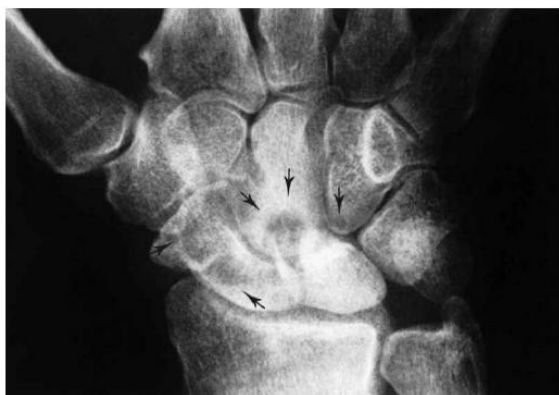

Fig. 1

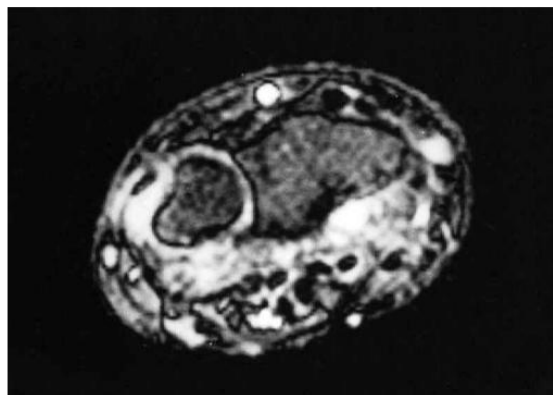


Fig. 2

### II. Discussion:

Jaffe, Lichtenstein, and Sutro coined the term pigmented villonodular synovitis in 1941<sup>3,6</sup>. They identified its characteristics and relationship to other pathologic states. The synovial or diffuse form is most commonly located in the knee with a slightly smaller incidence in other joints of the lower extremity. Rarely is the upper limb involved. The tenosynovial or nodular form is very common in the hand.

Pigmented villonodular synovitis involving the wrist joint is an unusual lesion. Eighteen cases have been reported in the English literature. Lewis<sup>9</sup>, Patel and Zinberg<sup>8</sup>, Schajowicz and Blumenfeld<sup>9</sup>, Moynagh<sup>5</sup>,

Breimer and Freiburger<sup>1</sup> and Pandey<sup>7</sup> each described one case. In a series of 118 cases reviewed by Jones, Soule, and Coventry<sup>4</sup>, four were located in the wrist. Nilsonne and Moberger<sup>1</sup>, reported two cases involving the carpus in a series of twenty-nine lesions. Smith and Pugh<sup>1</sup> discussed four cases while Byers, et al.<sup>2</sup>, reported two involved the carpus. Invasion and erosion of bone in the nodular form is common in circumscribed lesions involving the tendon sheaths. In the diffuse form, bone and intra-articular involvement is much less common<sup>1,9</sup>. Intra-osseous extension of the articular form occurs through the articular<sup>5,7</sup> cartilage and cortex at the chondro-osseous junction. Excessive pressure from the synovial overgrowth may be responsible for the bony lesions with articular cartilage and cortical bone erosion as well as cystic degeneration in the cancellous bone. These osseous changes are reflected in a characteristic radiographic appearance<sup>1,2,10</sup> :

- 1) well circumscribed cortical erosions with sclerotic margins and irregular articular surfaces,
- 2) cystic changes in the carpus,
- 3) lobular tumefaction surrounding the carpal bones,
- 4) normal mineralization despite extensive wrist involvement, and
- 5) absence of calcification in the synovial swelling.

The incidence of pigmented villonodular synovitis involving joints other than the knee and hip is too small to indicate specific principles of clinical diagnosis<sup>6</sup>. Therefore, the diagnosis is usually made at surgical exploration.

Most authorities agree that nodular lesions of the upper extremity should be treated by local excision, despite the reported recurrence rate of 8 per cent of 48 per cent<sup>2</sup>. Radiotherapy has been utilized both alone and in combination with synovectomy. Satisfactory long term results have been reported even if the disease has not been completely eradicated<sup>2</sup>. The incidence of recurrence may be decreased if a complete dorsal and volar wrist synovectomy is performed at the initial surgical procedure, which may have been beneficial in our patient

#### References :

- [1]. Breimer, C.W; and Freiburger, R. H.: Bone Lesions Associated with Pigmented Villonodular Synovitis. Am. J. Roentgenol. Rad. Ther. Nuc. Med., 79:618-629, 1958.
- [2]. Byers, P.D.; Cotton, R. E.; Deacon, O.W.; Lowy, M.; Newman, PRH.; Sissous, H.; and Thomson, A.D.; Diagnosis and Treatment of Pigmented Villonodular Synovitis. J. Bone and Joint Surg 50B: 290-305, 1968.
- [3]. Crawford, G. R; and Offerman, R.J.: Pigmented Villonodular Synovitis in the Hand. Hand, 12(3):282-287, October, 1980.
- [4]. Jones, F.E.; Soule, E.H.; and Coventry, M.D.: Fibrous Xanthoma of Synovium. A Study of 118 Cases. J. Bone and Joint Surg. 51A: 76-86, 1969.
- [5]. Moynagh, RD.; and Lettin, A.W.: Pigmented Villonodular Synovitis of the Wrist Joint. Proc-R-Soc.-Med., 61(7):670-672, July, 1968.
- [6]. Nilsonne, V.; and Moberger, G.: Pigmented Villonodular Synovitis of Joints. Acta. Orthop. Scand., 40:448, 1969.
- [7]. Pandey, S.; and Pandey, A.K.: Pigmented Villonodular Synovitis with Bone Involvement. Arch. Orthop. Trauma Surg., 98(3):217-223, 1981.
- [8]. Patel, M. R.; and Zinberg, E.M.: Pigmented Villonodular Synovitis of the Wrist Invading Bone-Report of a Case. J. Hand Surg.(6):854,858, 1984.
- [9]. Schajowicz, F.; and Blumenfeld, I.: Pigmented Villonodular Synovitis of the Wrist and Penetration into Bone. J. Bone and Joint Surg. 50B:312-317, 1968.
- [10]. Smith, J.H.; and Pugh, D. G.: Roentgenographic Aspects of Articular Pigmented Villonodular Synovitis. Am. J. Roentgenol. Rad. Ther. Nuc. Med., 87:1146-1156, 1962.

Dr. Ankur Kumar, et. al. "Pigmented Villonodular Synovitis of Wrist." *IOSR Journal of Dental and Medical Sciences (IOSR-JDMS)*, 20(06), 2021, pp. 57-58.