

Interaction between the Orthodontist and the Pediatric Dentist – An Overview

Liliya Angelova¹, Krasimir Hristov²

¹ Private Practice, Sofia, Bulgaria

² Assistant Professor, Department of Pediatric dentistry, Faculty of Dental Medicine, Medical University –Sofia, Bulgaria

Abstract:

Background: The pediatric dentist and orthodontist have many professional interests in common. A successful collaboration between Orthodontics and Pediatric Dentistry during the stages of primary and mixed dentition is important for making an early diagnosis of dental alterations and malocclusions, which allows less complex early treatment and a better prognosis. A pediatric dentist provides valuable assistance to the orthodontist by reducing the complexity of certain cases and by encouraging greater cooperation from the patient. The treatment provided by both specialties often has profound effects upon the function and esthetics of young patients. Individual patient care is at its best when a synergistic collaboration of the pediatric dentist and orthodontist is fully realized. Sharing information between both specialties is critical, as is coordination of pediatric dental and orthodontic treatment. New and more profoundly effective avenues of communication and interaction between the orthodontist and pediatric dentist need to be established and maintained if individual patients are to benefit from modern orthodontic and pediatric dental care. This article explores commonly encountered problems and suggests some collaboration guidelines. It is important to explore the aspects of this inter-specialty interactivity and communication in different clinical situations to optimize treatment coordination.

Key words: Interdisciplinary collaboration, orthodontics, pediatric dentistry;

Date of Submission: 05-05-2021

Date of Acceptance: 18-05-2021

I. Introduction

The pediatric dentist and orthodontist have many professional interests in common as they both are treating the same patient often at the same time. A successful collaboration between Orthodontics and Pediatric Dentistry during the stages of primary and mixed dentition is important for making an early diagnosis of dental alterations and malocclusions, which allows less complex early treatment and a better prognosis¹. The treatment provided by both specialties often has profound effects upon the function and esthetics of young patients. Moreover, this integrated approach allows the implementation of interceptive orthodontics with relatively low cost and the use of preventive programs with maximum benefit for the oral health of young patients. Individual patient care is at its best when a synergistic collaboration of the pediatric dentist and orthodontist is fully realized.

The pediatric dentist is both a primary care dental health provider and a specialist who is able to diagnose, prevent, treat and control oral health problems from babies to adolescents. The pediatric dentist will most likely interface with the orthodontist on a daily basis far more than any other dental clinician. The pediatric dentist provides guidance for parents/guardians of young people's oral health; raises awareness and teaches good dental habits to young people; detects possible deviations with repercussion in the dental structures; identifies risk factors and develops preventive strategies and last but not least refers the patient to the appropriate dental specialists when a certain problem should be treated.

Malocclusions can affect the health of oral tissues and may cause psychological and social problems². The common goal of all orthodontic treatment methods is to ensure that the teeth are aligned properly on the jaws, as well as in harmony with each other. A balanced soft tissue appearance and an esthetic smile are the optimal goal of the orthodontists. Fixed or removable orthodontic treatment appliances used for this purpose may cause some undesirable side effects, as it may be seen in every treatment process. Orthodontics also can provide some additional benefits for the overall oral health in cases ectopic and impacted teeth, in cases where extraction of permanent teeth is necessary due to complicated caries or for other reasons, in cases of hypodontia and as adjunctive therapy in complex situations like dental trauma.

It is important to explore the aspects of this inter-specialty interactivity and communication in different clinical situations to optimize treatment coordination. Several clinical scenarios are presented to illustrate commonly encountered problems as well as to suggest some collaboration guidelines.

II. Relationship between orthodontic treatment and dental caries

Both fixed and removable orthodontic appliances affect the oral microbiota^{3,4}. Their surfaces are retention areas for bacterial biofilm. During the orthodontic treatment the mechanical self-cleaning process providing by saliva and musculature movement is limited by the presence of the appliances in the oral cavity. In result the pH value of dental biofilm drops, especially in the presence of fermentable carbohydrates⁵.

Oral hygiene in children treated with removable orthodontic appliances was found to be as good as the oral hygiene of children with no orthodontic treatment⁶. This treatment option was found to be safer, especially in patients with poor oral hygiene control⁴.

On the other hand, in fixed orthodontic treatment bands, and brackets, ligatures increase the number of plaque retention areas and pose a significant risk due to poorer oral care³. With the start of the fixed orthodontic treatment there is a significant increase in the amount of *Porphyromonas gingivalis*, *S. mutans*, *Streptococcus sobrinus* (*S. sobrinus*), *Lactobacillus casei* (*L. casei*), and *Lactobacillus acidophilus* (*L. acidophilus*) in the oral cavity³. There is a high risk of caries development around a brackets on the buccal tooth surfaces⁷. Even though improvements in materials and preventive efforts are being developed constantly, demineralization may occur in these places after only one month⁸. In addition, children between 11 and 14 years, when comprehensive orthodontic treatment is usually necessary, are considered to be in the high caries risk group⁹. Patients with a high pretreatment DMFS score, especially in the first molar teeth and the second premolar teeth, must be included in special prophylaxis programs¹⁰.

The orthodontist should assist the pediatric dentist in ensuring that all patients are receiving regularly scheduled pediatric dental appointments during orthodontic treatment. Coordinating orthodontic and pediatric dental appointments is crucial so that the pediatric dentist motivates the patient and his parents for proper oral hygiene habits, diagnoses tooth decay and treats it on time. So pediatric dental recall visit schedule for patients undergoing orthodontic treatment should be established according to the individual patient caries risk, age and the type of orthodontic treatment. And the orthodontist must be aware if the patient keeps their appointments regularly. It is a common misunderstanding of parents who mistakenly confuse monthly visits to the orthodontist as substitutes for semi-annual or annual visits to the pediatric dentist while their child is undergoing orthodontic treatment.

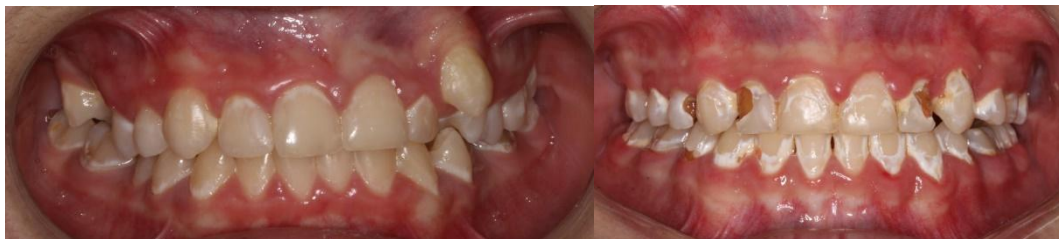

Figure 1. 13-year old patient with poor oral hygiene, high DMFT, high caries risk underwent orthodontic treatment and did not cooperate with the pediatric dentist appointments nor with the instructions for oral hygiene , given by the orthodontist. In the end the teeth were aligned, the orthodontic treatment was prematurely interrupted, the result for the overall oral health was devastating.

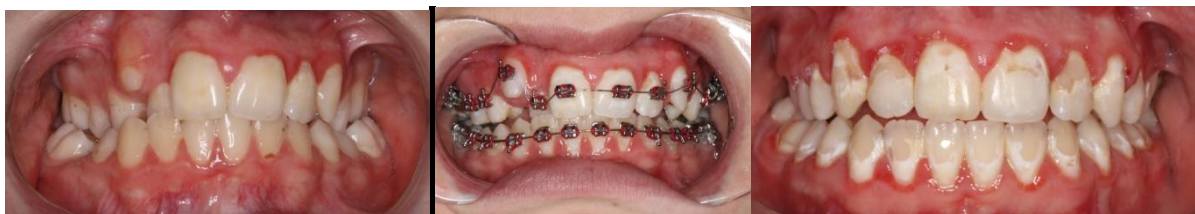

Figure 2. 11-year old patient with poor oral hygiene, who underwent orthodontic treatment and did not cooperate with the pediatric dentist appointments, nor with the instructions for oral hygiene , given by the orthodontist.

III. White spot lesions during orthodontic treatment

Iatrogenic decalcification of tooth enamel, the formation of white spot lesions (WSL) and incipient caries are typical undesirable side effects of orthodontic treatment with fixed appliances¹¹. This undermines the aesthetic appearance even though orthodontic correction of the malocclusion is achieved. It has been reported

that white spot lesions occur in 73 %¹² of subjects treated with fixed orthodontic appliances. This is most probably due to poor oral hygiene in the presence of brackets and wires^{13,14}. This early decalcification may progress to carious lesions¹³. White spot lesions may form within only a few weeks¹⁵, and the first six months in a fixed orthodontic treatment require special attention on this problem¹⁶. Preventive strategies including fluoride-releasing sealants, or daily rinsing with sodium fluoride mouth rinse¹⁷ can be helpful. Restorative techniques for enamel lesions should be applied only in cases with cavitations. Remineralizing therapy should be used for non-cavitated lesions¹⁸.

Most of the times once the WSL occurs correction of brushing habits and provision of local fluoridation and even bracket removal can make the enamel smooth and harder, but does not improve the aesthetic appearance¹⁹. These lesions are visible as they do not reflect the light but instead are scattering it. Different treatment options are available: topical fluoride gels, toothpastes, mouthwashes, varnishes, acid-pumice microabrasion and esthetic restorations, enamel decalcification. The technique of WSL infiltration with low-viscosity light-curing resins (infiltrants) has been established as a new way of stopping the progression and reducing visibility of the infiltrated lesions²⁰. When using fixed orthodontics, the orthodontist must inform the patient and his/her parents about potential side-effects of the treatment, such as WSLs. It is also necessary to provide an adequate prophylaxis regime and a strategy to treat WSLs present in spite of prophylactic measures taken. That is where the pediatric dentist comes. Evidence of decalcification can persist 5 years post-treatment. If left untreated enamel decalcification can lead to cavitation and caries formation²¹.

Infiltration should be performed at the ideal time - right after bracket debonding. This facilitates the treatment and improves the esthetic outcomes as remineralisation and hardening of surfaces by daily tooth brushing are prevented. Fresh and more superficial lesions have been reported to be easier to treat with infiltration than older, deeper lesions with thicker pseudo-intact surface. Treating older lesions or brown spots with infiltration requires using etching agent several times²².

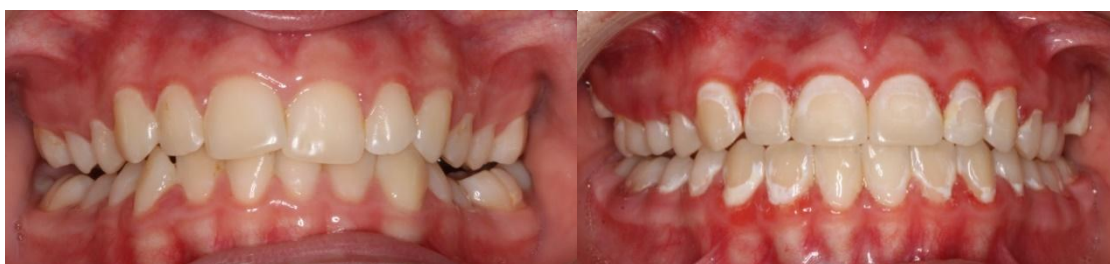

Figure 3. White spot lesions occurred due to fixed orthodontic treatment and poor oral hygiene.

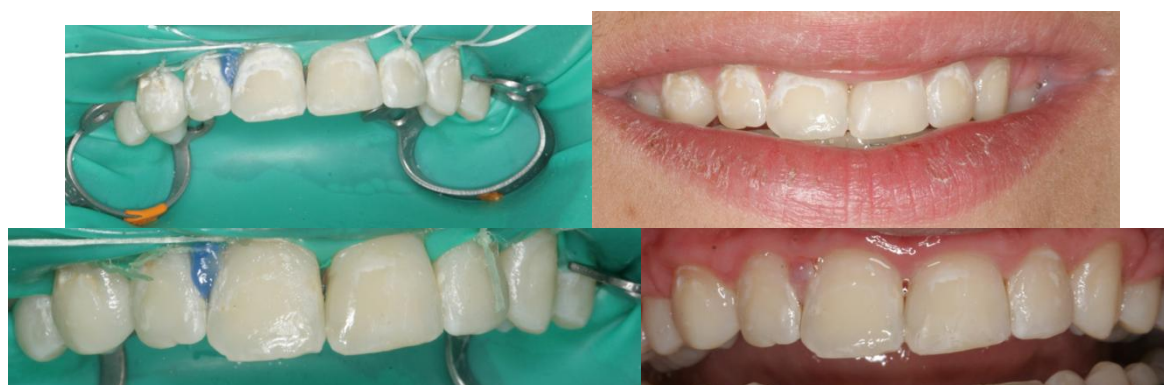

Figure 4. White spot lesions occurred due to fixed orthodontic treatment and poor oral hygiene, treated by the pediatric dentist with ICON.

IV. Methods for preventing caries during orthodontic treatment

Caries preventive methods used in orthodontic patients are divided in three large groups : 1. plaque removal and plaque control; 2. increasing tooth resistance; 3. diet control;

Mechanical methods of plaque control include tooth brushing and interdental cleaning. Studies show that the use of a powered toothbrush with an orthodontic brush head removes 9% more plaque than does the regular brush head and so it is better in promoting gingival health for orthodontic patients with fixed appliances²³. Chemical methods include toothpastes and mouth rinses²⁴. Toothpastes containing fluoride reduce caries by 20%. The fluoride concentration should be over 1000 ppm. Daily use of fluoride toothpastes reduces the formation of enamel lesions during orthodontic treatment with fixed appliances²⁵. Additional daily use of fluoride mouthwashes with 0.05% sodium fluoride for 1 min provides a 50% tooth decay reduction²⁶. Other

commonly used chemical agents, effective in reduction of plaque accumulation are chlorhexidine, cetylpyridinium chloride, listerine, and triclosan

With the application of topical fluorides, used by dentists in the form of solutions or gels, tooth decay can be reduced by 40%²⁷. Fluorinated varnishes harden when they come into contact with moisture, so they are safer, easier to apply, and have more fluoride concentration on the enamel surface compared to other topical fluoride applications²⁸. All methods for fluoride application are somewhat effective and clinicians should choose the proper combination for each patient according to his co-operation status, age, decay history, general health, and oral hygiene.

Casein phosphopeptides amorphous calcium phosphate (CPP-ACP) is a product with proven anticariogenic activity. Monthly application of CPP-ACP paste on the teeth during the orthodontic treatment decreases the number of WSL²⁹. CPP-ACP is available as a paste and in the form of varnish in combination with fluoride, chewing gum, mouth rinses, lozenges, dentifrices, spray, and energy drinks.

The dentist should provide: guidance, information, and motivation to all patients for whom dietary modification is needed. The patients with fixed orthodontic appliances should be advised to avoid foods such as cakes, pastries, carbonated beverage, which are high in simple sugars and fats in their diet, and also to reduce the frequency of their consumption³⁰. The frequent intake of these foods allows the colonization of *S. mutans* and increases the caries activity.

All of these methods can be prescribed both by the orthodontist and the pediatric dentist, but the pediatric dentist is the specialist in diagnosing the caries process and is proficient in different preventive strategies. So getting his expertise is of benefit for the patient's oral health. Also more often than not, the orthodontist doesn't have enough time and the right means for patient instruction and motivation. Taking this into consideration, the pediatric dentist is capable of improved prophylactic measures, possibly including more office protocols such as fluoride varnish application and etc.³¹ That is why high risk patients should be referred by the orthodontist to the pediatric dentist for motivation and preventive procedures.

The orthodontist should discuss oral hygiene concerns or any unusual in-treatment findings directly with the pediatric dentist. This protocol will greatly improve oral hygiene efforts and decrease the incidence of white spot lesions and any associated liability during orthodontic treatment, as the orthodontist, pediatric dentist, patient, and parent are informed of any adverse conditions during orthodontic treatment, and appropriate strategies can be administered on a regular and coordinated basis.

V. Management of ectopic and impacted teeth

Both the pediatric dentist and the orthodontist as dental professionals must be aware of the patterns and stages of growth and development, especially the average age of eruption and exfoliation. This age can vary from child to child and even between children of the same family. The dentist should be aware that delayed eruption and/or lack of symmetry can be the first indication that something is wrong. Often during examination, the pediatric dentist would see an intraoral view of a patient in the mixed dentition with seemingly unremarkable orthodontic issues that would suggest rather later orthodontic treatment in the permanent dentition than earlier in the mixed dentition stage. However, sometimes the screening panoramic radiograph suggests otherwise. The overall pediatric dental and orthodontic management of patients with ectopic and impacted teeth can be considerably helped by the recognition of the benefits of panoramic 'screening' radiographs obtained in the mixed dentition for pediatric dental patients. It is important that the pediatric dentist is aware and alert for any notable changes in the path of eruption of the canines, first permanent molars, second premolars, and other teeth. The incidence of tooth impaction has been reported to vary from 5.6 to 18.8 percent of the population³². The maxillary canine, with the exception of the third molars, is the most frequently impacted tooth. However, any permanent tooth may become impacted³². If there is any suspicion that a tooth might be impacted, the pediatric dentist should refer the patient for orthodontic evaluation.

The evidence suggests that most of ectopically developing maxillary canines are predisposed to become impacted. However, an early orthodontic intervention can help for the conservative management of these teeth³³. Sometimes interceptive treatment by removal of the deciduous canine is enough. Other times comprehensive treatment that includes maxillary expansion, removal of the maxillary primary canines, and fixed orthodontic appliances are needed.

The ectopic eruption of the first permanent molar varies between 1% and 5%³⁴, and can occur when there is an altered path of eruption in a mesial direction. In these cases, the permanent molar erupts under the distal root of the second primary molar. This may result in the impaction of the second premolar³⁵. An interceptive orthodontic treatment is often needed. It can vary from simple follow-up, to the extraction of the deciduous second molar, to the distalization of the impacted molar with different means³⁵.

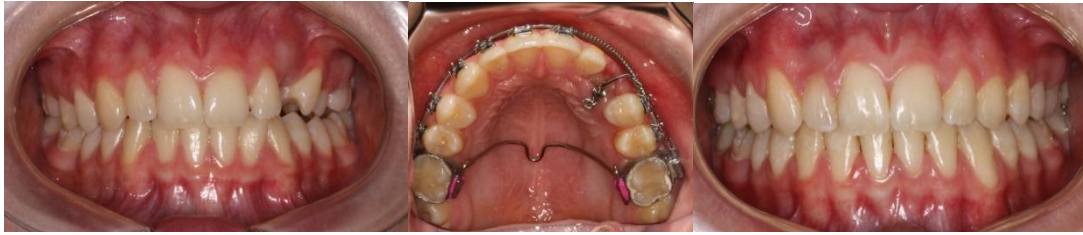

Figure 5. Treatment of impacted canine, the patient was diagnosed during a routine checkup by the pediatric dentist.

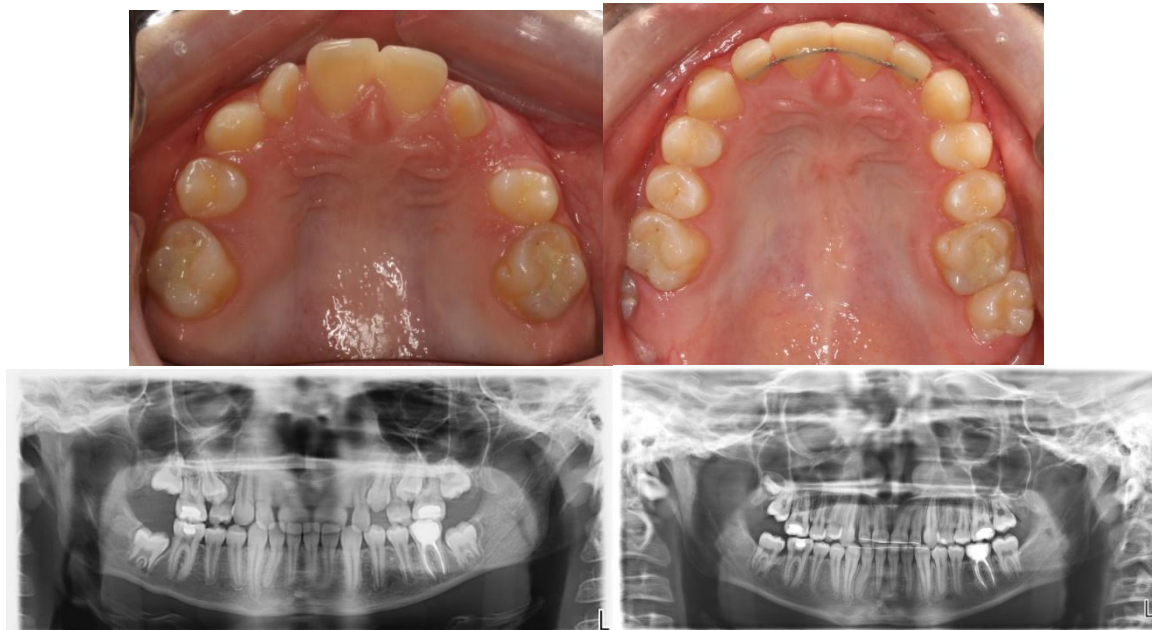


Figure 6. Treatment of impacted second premolars and ectopic upper molars, the patient was diagnosed during a routine checkup by the pediatric dentist.

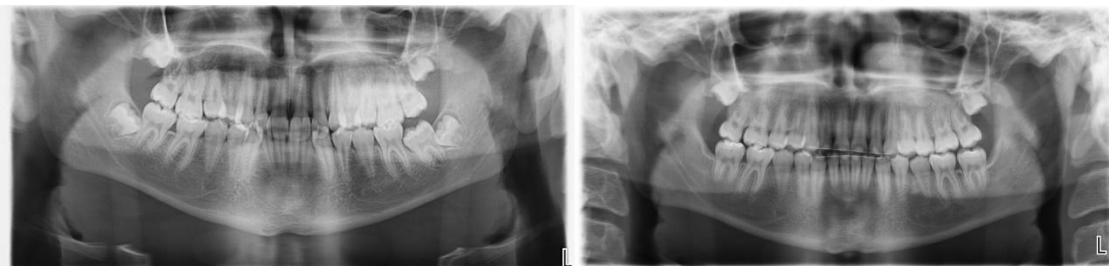


Figure 7. 12-year-old patient with retention of 37 due to lower third molar position. Spontaneous eruption of 37 after the extraction of 38.

VI. Proper timing of orthodontic treatment

The pediatric dentist is often the first clinician to recognize functional changes such as cross bites and open bites in the deciduous dentition phase or malocclusions in the mixed dentition. Often the pediatric dentists use special charts that allow them to assess quickly any deviations from the norm and are useful for later referral to the orthodontist. The pediatric dentist also should obtain a panoramic radiograph if necessary as a screening image for missing, supernumerary, ectopic teeth, or other pathology. Radiographs obtained either by the pediatric dentist or orthodontist need to be shared. In the modern digital age it should be easy for both clinicians to communicate and use standard mutual protocols for information exchange.

Orthodontic treatment in 6- and 7-year-old children is known as preventive orthodontics. Interceptive orthodontics is performed to correct a developing malocclusion and it is often the first phase. The second phase begins between the ages of 12 and 14, and tend to have a shorter duration, as there will be smaller corrections to be made. In this phase, skeletal development problems are corrected. It has been suggested that developing problems in the mixed dentition could be fully corrected with simple interceptive treatment in 15% and improved in 49% of cases³⁶. Definitive orthodontic treatment usually starts in the late mixed or early permanent

dentition. Therefore, simple interceptive measures can be efficient and cost-effective for the patients. The pediatric dentist can perfectly identify developing occlusal problems and if needed to refer patients for correct treatment in a timely manner.

Problems that the pediatric dentist should look for in the developing dentition in relation to timing of orthodontic treatment.

- Early mixed dentition: Delayed eruption of permanent incisors; Supplemental incisors; Early loss of deciduous teeth; Congenital absence of incisors; One or more incisors in crossbite; Impaction of first permanent molars; Severe crowding; Severe skeletal discrepancy; Posterior crossbites³⁷.
- Late mixed dentition: Severe skeletal problems; Unfavorably positioned canines or other teeth; Congenitally absent permanent teeth; Poor-quality first permanent molars; Traumatic overbites.³⁷
- Early permanent dentition: Severe skeletal problems; Impacted teeth; Crowding; Hypodontia.³⁷

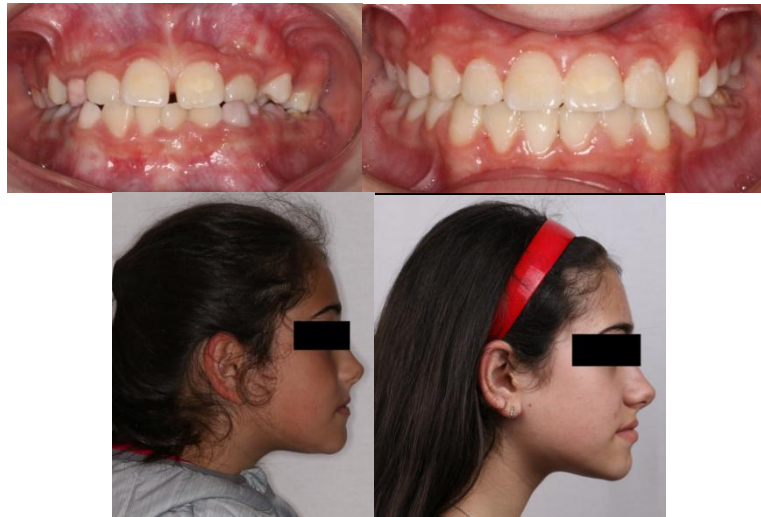

Figure 8. Early treatment of a class III in a 10-year-old patient that lasted 1,5 years.

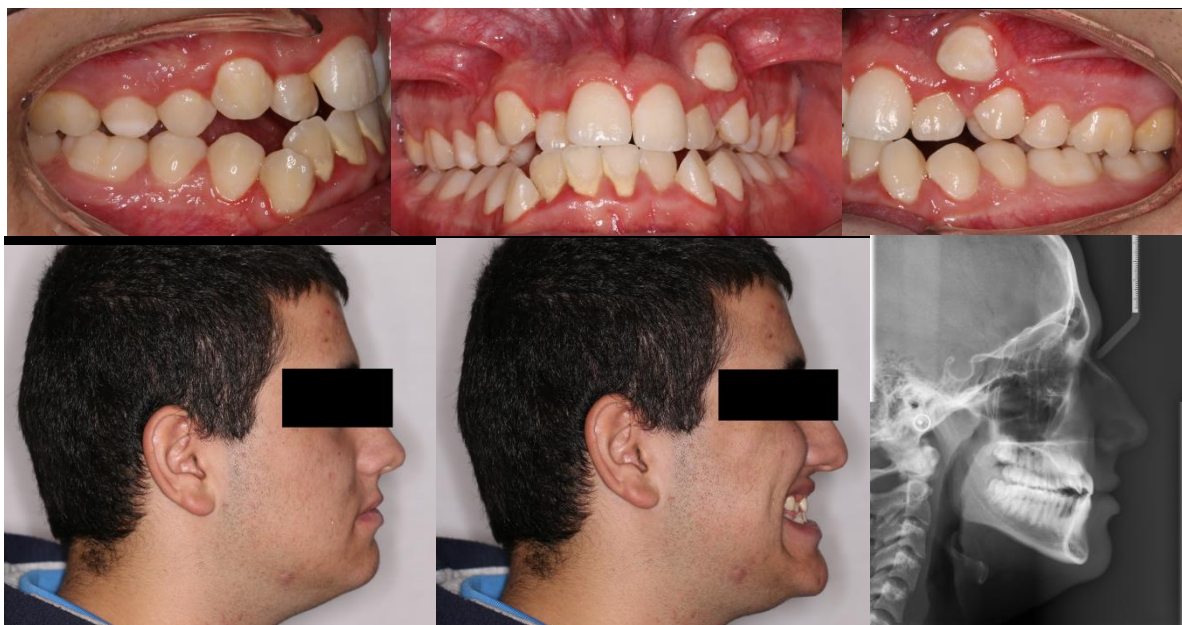

Figure 9. This is the brother of the previous patient (Figure 8). He was referred for orthodontic treatment at the age of 17 with severe class III. The orthodontic malocclusion is the same as his sister's but at this age it requires a combined orthodontic and orthognathic surgery treatment.

VII. Benefit of extraction strategies and orthodontic treatment

Extensively decayed FPM in young children pose serious problem and that is why there is no consensus in the literature for their treatment. These teeth are the first permanent teeth to erupt and are often damaged by caries. 6% to 10-19% of first permanent molars have hypoplasia³⁸. According to some clinicians early extraction of these teeth is necessary because they are more likely to have a poor prognosis in time³⁹. Others prefer to restore badly decayed FPM. Extraction of these teeth may be highly beneficial or not depending on individual characteristics of the patient and the expected treatment outcomes⁴⁰.

Deeply decayed first permanent molars in a child pose real challenge for the pediatric dentist because of the need for a long and difficult treatment under local anesthesia, the degree pulp maturation, and the significant destruction of the crown.

These cases are difficult for the orthodontist as well. The first permanent molar has major role in the masticatory function and the dentofacial harmony. Moreover, children who are candidates for FPM s extraction have poor oral hygiene and often are not good candidates for future orthodontic treatment³⁸.

That is why in order to solve this complex problem the pediatric dentist, and the orthodontist must work as a team, and decide on a proper treatment plan, considering different factors like: the long-term prognosis of the endodontic treatment and the restoration; the overall oral health of the patient; the dental age of the patient; the type of malocclusion; the degree of crowding; presence and position of third molars; the skeletal pattern of growth.

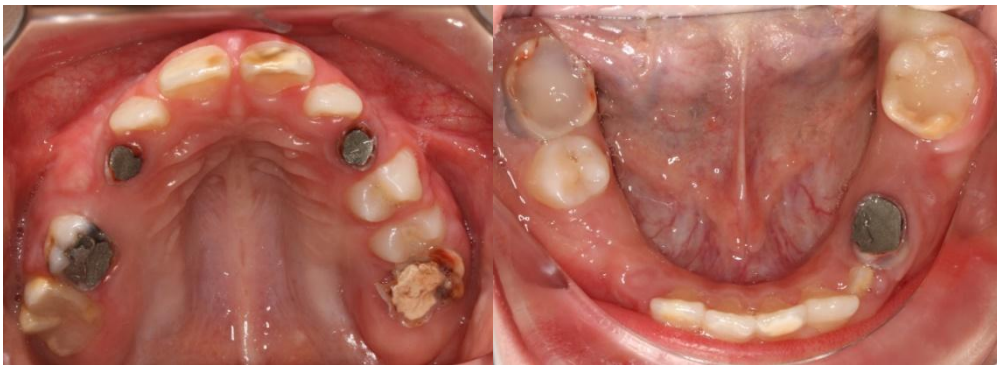

Figure 10. 9-year-old patient with MIH and poor long-term prognosis for the survival of the permanent first molars.

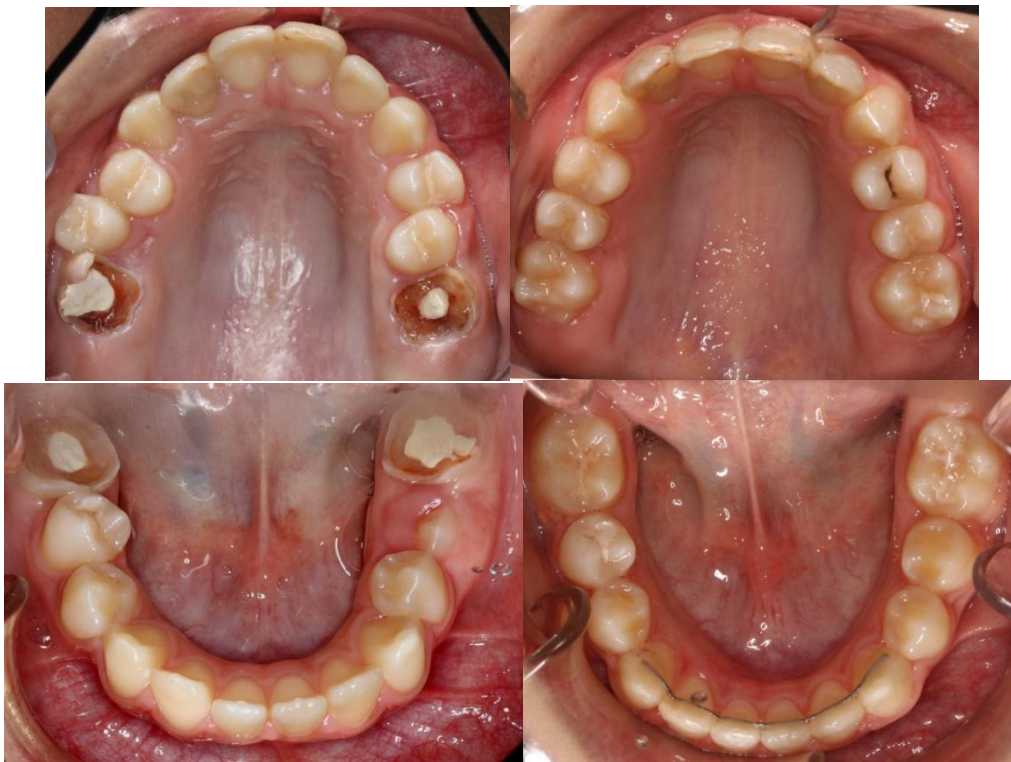


Figure 11. Orthodontic treatment of 11-year old patient after extraction of non-restorable first permanent molars in early permanent dentition.

VIII. Management of dental trauma

Dental injuries are often seen as a result of sports, traffic accidents, and fights. They vary from simple enamel fractures to complicated fractures and require emergency intervention⁴¹. The pediatric dentist has the required knowledge and skills to perform this first treatment, which is extremely important on prognosis⁴². Often patients with trauma also need orthodontic treatment. The orthodontist should consider the long-term prognosis of these teeth before starting treatment and plan dental movements accordingly. More often than not, a multidisciplinary team is needed to obtain optimal treatment results in trauma patients⁴³. Standard treatment guidelines may not be applicable for every patient with dental trauma. It is important to decide whether orthodontic force can and should be applied to traumatized teeth. Excessive amount of orthodontic force may have adverse effects such as root resorption⁴⁴.

Crowns and crown-root fractures without pulp, when treated appropriately, need a 3-month observation before the orthodontic treatment. For crown and crown-root fractures containing the pulp 3 months after partial pulpectomy is a sufficient period⁴⁵.

Fractures that include enamel, dentin, and cement with or without pulp involvement in certain circumstances can be treated with orthodontic extrusion to expose the subgingival fracture line⁴⁶. Injuries like confusion and subluxation require at least a 3-month observation period. After autotransplantation of immature teeth calcification of the root canal is a common side effect and these teeth can be moved in a limited manner⁴⁵. The tooth should be observed for 3–4 months before orthodontic movement. In the avulsion injuries orthodontic movement of the tooth is not recommended at least for 6 months until the periodontal recovery is complete. In intrusion injuries, ankylosis, pulp necrosis, and pulp calcification may occur. Orthodontic treatment of these teeth requires special attention.

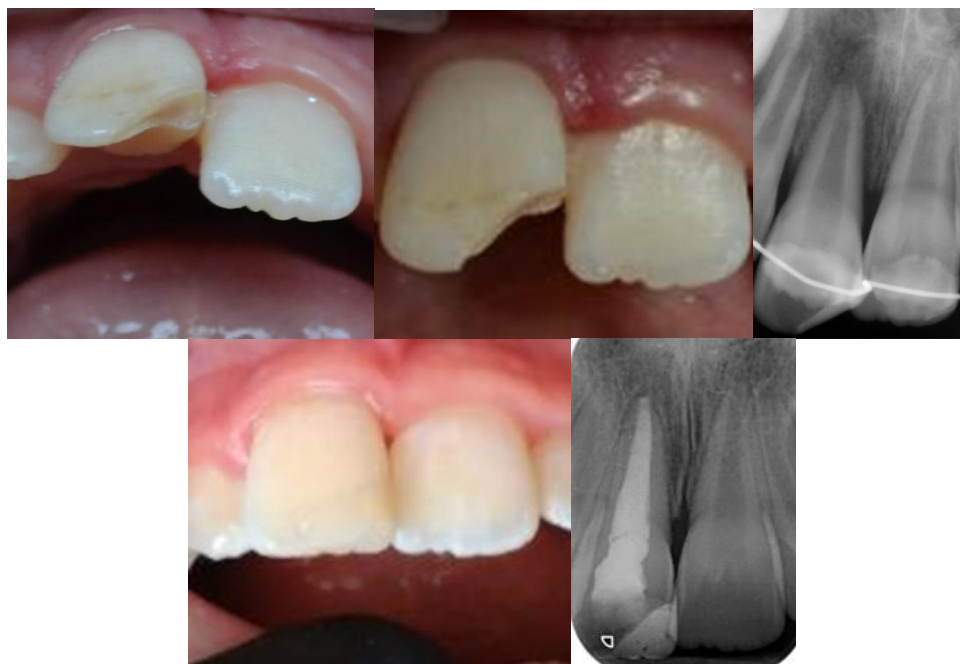

Figure 13. Treatment of 11-year-old patient with trauma of tooth 11, which led to malposition of the tooth, which could not be repositioned in its original place. This patient is referred for further orthodontic treatment after healing period of 6 months.

IX. Treatment options in cases of missing permanent teeth

Congenitally missing teeth are common dental anomalies that need quite complex and expensive multidisciplinary treatment⁴⁷. Hypodontia might affect adversely the esthetics, the function, and the self-esteem of the patients⁴⁸. Patients with missing permanent teeth often suffer from complications like malocclusion, reduced chewing ability, periodontal damage, lack of alveolar bone growth, problems with pronunciation, and changes in skeletal relationships⁴⁹. Hypodontia is a common problem seen by the pediatric dentist and affecting between 3 and 8% of the population. The pediatric dentist is often the first one that diagnoses the patient with the help of screening images and usually refers the patient to the orthodontist⁵⁰. The pediatric dentist also assesses the etiology of the condition and takes care for the overall health of the patient and takes part in the restorative treatment if one is needed. The orthodontist should consider the amount of crowding, type of malocclusion, facial profile, age of the patient, periodontal conditions, bone volume in alveolar process, vertical or horizontal growth pattern, craniofacial morphology and the number of missing teeth

when deciding to open or close space in the dentition. Space can be reopened for implant placement, autotransplantation or prosthetic restoration. The other treatment plan is space closing which can be done by fixed orthodontics. Each of these two treatment plans has their advantages and disadvantages. Treatment planning needs an interdisciplinary approach including operative dentistry, pediatric dentistry, orthodontics, and prosthodontics.

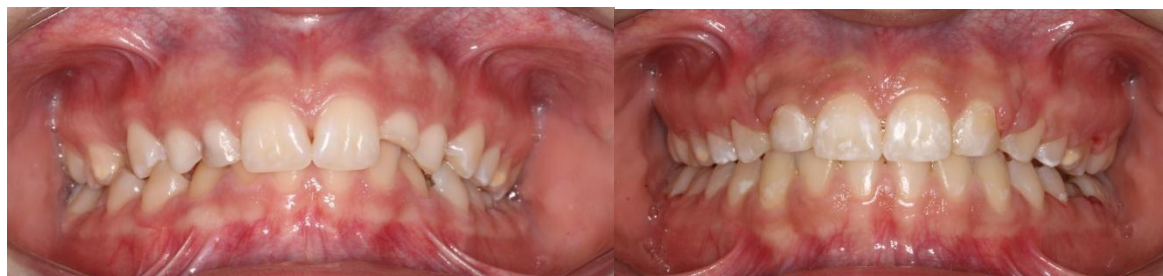

Figure 14. Management of congenitally missing maxillary lateral incisors with canine substitution in 14-year-old patient.

X. Conclusion

Pediatric dentistry is one of the indispensable components in a multidisciplinary team that cares for children. It intervenes on different levels: diagnosis, prevention, oral treatments and follow-up of dental procedures during the comprehensive orthodontic treatment of these patients. A pediatric dentist provides valuable assistance to the orthodontist by reducing the complexity of certain cases and by encouraging greater cooperation from the patient. Sharing information between both specialties is critical, as is coordination of pediatric dental and orthodontic treatment. New and more profoundly effective avenues of communication and interaction between the orthodontist and pediatric dentist need to be established and maintained if individual patients are to benefit from modern orthodontic and pediatric dental care.

Acknowledgements

None.

Conflict of interest

There is no conflict of interest to declare.

References

- [1]. Mendes ACS, Costa AA, Nemr K. O papel da Fonoaudiologia na Ortodontia e na Odontopediatria: avaliação do conhecimento dos Odontólogos especialistas. *Rev CEFAC*. 2005;7(1):60-7.
- [2]. Taylor KR, Kiyak A, Huang GJ, Greenlee GM, Jolley CJ, King GJ. Effects of malocclusion and its treatment on the quality of life of adolescents. *American Journal of Orthodontics and Dentofacial Orthopedics*. 2009;136:382-392.
- [3]. Liu H, Sun J, Dong Y, et al. Periodontal health and relative quantity of subgingival *Porphyromonas gingivalis* during orthodontic treatment. *Angle Orthodontist*. 2011;81(4):609-615.
- [4]. Petti S, Barbato E, Simonetti D'AA. Effect of orthodontic therapy with fixed and removable appliances on oral microbiota: a six-month longitudinal study. *New Microbiologica*. 1997;20(1):55-62.
- [5]. Pithon MM, Santos RLD, Alviano WS, Ruellas ACDO, Araujo MTDS. Quantitative assessment of *S. mutans* and *C. albicans* in patients with Haas and hyrax expanders. *Dental Press Journal of Orthodontics*. 2012;17(3):1-6.
- [6]. Krupinska-Nanys M, Zarzecka J. An assessment of oral hygiene in 7-14-year-old children undergoing orthodontic treatment. *Journal of International Oral Health*. 2015;7(1):6-11.
- [7]. Øgaard B. Prevalence of white spot lesions in 19-year-olds: a study on untreated and orthodontically treated persons 5 years after treatment. *Am J Orthod Dentofacial Orthop*. 1989;96:423-427.
- [8]. O'Reilly MM, Featherstone JDB. Demineralization and remineralization around orthodontic appliances: an in vivo study. *Am J Orthod*. 1987;92:33-40.
- [9]. Axelsson P. An introduction to risk prediction and preventive dentistry. Carol Stream, Quintessence Publishing. 1999; 107-111.
- [10]. Soumas V, Kiliaridis S, Staudt CB. Is caries in the early mixed dentition associated with caries development during orthodontic treatment? *Journal of Biosciences and Medicines*. 2015;3:25-32.
- [11]. McCarthy KA. Patient-specific decalcification risk. *AJODO*. 2005; 127(1): 3-12.
- [12]. Richter AE, Arruda AO, Peters MC, Sohn W. Incidence of caries lesions among patients treated with comprehensive orthodontics. *Am. J. Orthod. Dentofacial Orthop*. 2011;139(5):657-64.
- [13]. Bishara SE, Ostby AW. White spot lesions: Formation, prevention, and treatment. *Semin. Orthod*. 2008;14(3):174-82.
- [14]. Heymann GC, Grauer DA. Contemporary review of white spot lesions in orthodontics. *J. Esthet. Restor. Dent*. 2013; 25(2):85-95.
- [15]. Melrose CA, Appleton J, Lovius BB. A scanning electron microscopic study of early enamel caries formed in vivo beneath orthodontic bands. *Br. J. Orthod*. 1996; 23(1):43-7.
- [16]. Tufekci E, Dixon JS, Gunsolley JC, Lindauer SJ. Prevalence of white spot lesions during orthodontic treatment with fixed appliances. *Angle Orthod*. 2011; 81(2):206-10.
- [17]. Benson PE, Parkin N, Dyer F, Millett DT, Furness S, Germain P. Fluorides for the prevention of early tooth decay (demineralised white lesions) during fixed brace treatment. *Cochrane Database Syst. Rev*. 2013;12:CD003809.

- [18]. Stahl J, Zandona AF. Rationale and protocol for the treatment of non-cavitated smooth surface carious lesions. *Gen. Dent.* 2007;55(2):105-11.
- [19]. Shungin D, Olsson AI, Persson M. Orthodontic treatment-related white spot lesions: a 14-year prospective quantitative follow-up, including bonding material assessment. *Am. J. Orthod. Dentofacial Orthop.* 2010;138(2):136.e1-8.
- [20]. Tinanoff N, Coll JA, Dhar V, Maas WR, Chhibber S, Zokaei L. Evidence-based update of pediatric dental restorative procedures: Preventive Strategies. *J. Clin. Pediatr. Dent.* 2015;39(3):193-7.
- [21]. Zimmer BW, Rottwinkel Y. Assessing patient-specific decalcification risk in fixed orthodontic treatment and its impact on prophylactic procedures. *AJODO.* 2004; 126(3): 318-24.
- [22]. Knösel M, Eckstein A, Helms HJ. Durability of esthetic improvement following Icon resin infiltration of multibracket-induced white spot lesions compared with no therapy over 6 months: a single-center, split-mouth, randomized clinical trial. *Am. J. Orthod. Dentofacial Orthop.* 2013; 144(1):86-96.
- [23]. Erbe C, Klukowska M, Tsaknaki I, Timm H, Grender J, Wehrbein H. Efficacy of 3 toothbrush treatments on plaque removal in orthodontic patients assessed with digital plaque imaging: A randomized controlled trial. *American Journal of Orthodontics and Dentofacial Orthopedics.* 2013;143(6):760-766.
- [24]. Haas AN, Pannuti CM, Andrade AK, et al. Mouthwashes for the control of supragingival biofilm and gingivitis in orthodontic patients: Evidence-based recommendations for clinicians. *Brazilian Oral Research.* 2014;28(spe):1-8.
- [25]. Sonesson M, Twetman S, Bondemark L. Effectiveness of high-fluoride toothpaste on enamel demineralization during orthodontic treatment—a multicenter randomized controlled trial. *European Journal of Orthodontics.* 2014;36(6):678-682.
- [26]. Newbrun E. *Cariology.* 3rd ed. Chicago: Quintessence; 1989.
- [27]. Newbrun E. Topical fluorides in caries prevention and management: A north American perspective. *Journal of Dental Education.* 2001;65(10):1078-1083.
- [28]. Staley RN. Effect of fluoride varnish on demineralization around orthodontic brackets. *Seminer in Orthodontics.* 2008;14:194-199.
- [29]. Esenlik E, UzerCelik E, Bolat E. Efficacy of a casein phosphopeptide amorphous calcium phosphate (CPP-ACP) paste in preventing white spot lesions in patients with fixed orthodontic appliances: A prospective clinical trial. *European Journal of Paediatric Dentistry.* 2016;17(4):274-280.
- [30]. Maheshwari S, Tariq M, Gaur A, Jiju M. A systematic nutritional and dietary guideline for orthodontic and orthognathic surgery patients. *Indian Journal of Orthodontics and Dentofacial Research.* 2017;3:136-140.
- [31]. Enaia M, Bock N, Ruf S. White-spot lesions during multibracket appliance treatment: A challenge for clinical excellence. *American Journal of Orthodontics and Dentofacial Orthopedics.* 2011;140(1):e17-e24.
- [32]. Grover PS, Lorton L. The incidence of unerupted permanent teeth and related clinical cases. *Oral Surg Oral Med Oral Pathol.* 1985;59:420-5.
- [33]. Baccetti T, Mucedero M, Leonardi M, Cozza P. Interceptive treatment of palatal impaction of maxillary canines with rapid maxillary expansion: a randomized clinical trial. *Am J Orthod Dentofacial Orthop.* 2009;136(5):657-61.
- [34]. Barberia-Leache E, Suarez-Clúa MC, Saavedra-Ontiveros D. Ectopic eruption of the maxillary first permanent molar: characteristics and occurrence in growing children. *Angle Orthodontist.* 2005; 75(4):610-15.
- [35]. Seehra J, Winchester L, DiBiase AT, Cobourne MT. Orthodontic management of ectopic maxillary first permanent molars: a case report. *Aust Orthod. J.* 2011; 27(1):57-62.
- [36]. Ackerman JL, Proffit WR. Preventive and interceptive orthodontics: a strong theory proves weak in practice. *Angle Orthod.* 1980; 50: 75– 87.
- [37]. DiBiase A. The Timing of Orthodontic Treatment. *Dental Update.* 2002; 29(9), 434–441.
- [38]. Ong DC, Bleakley JE. Compromised first permanent molars: An orthodontic perspective. *Aust Dent J.* 2010;55:2–14.
- [39]. ElSheikh M, Ali A. Planned extraction of first permanent molars during late childhood: a clinical note and mini-review. *Dent Oral Craniofac Res.* 2015;1(3):77–80.
- [40]. Gill DS, Lee RT, Tredwin CJ. Treatment planning for the loss of first permanent molars. *Dent Update.* 2001;28(6):304–8.
- [41]. Glendor U. Epidemiology of traumatic dental injuries a 12 year review of the literature. *Dental Traumatology.* 2008;24:603-611.
- [42]. Al-Nazhan S, Andreasan JO, Al-Bawardi S, Al-Roug S. Evaluation of the effect of delayed management of traumatized permanent teeth. *Journal of Endodontia.* 1995;21:391-393.
- [43]. Kindelan SA, Day PF, Kindelan JD, Spencer JR, Duggal MS. Dental trauma: An overview of its influence on the management of orthodontic treatment. Part 1. *Journal of Orthodontics.* 2008;35:68-78.
- [44]. Poi WR, CardosoLde C, de Castro JC, Cintra LT, Gulinelli JL, de Lazari JA. Multidisciplinary treatment approach for crown fracture and crown root fracture a case report. *Dental Traumatology.* 2007;23:51-55.
- [45]. Andreasen J, Andreasen F, Andersson L. *Traumatic Injuries to the Teeth.* 4th ed. Copenhagen: Blackwell publishing Company; 2007
- [46]. Bach N, Baylard JF, Voyer R. Orthodontic extrusion: Periodontal considerations and applications. *Journal of the Canadian Dental Association.* 2004;70(11):775-780.
- [47]. De Coster PJ, Marks LA, Martens LC, Huysseune A. Dental agenesis: Genetic and clinical perspectives. *J Oral Pathol Med.* 2009;38:1–17.
- [48]. Goya HA, Tanaka S, Maeda T, Akimoto Y. An orthopantomographic study of hypodontia in permanent teeth of Japanese pediatric patients. *J Oral Sci.* 2008;50:143–50.
- [49]. Khosravanifard B, Ghanbari-Azarnir S, Rakhshan H, Sajjadi SH, Ehsan AM, Rakhshan V. Association between orthodontic treatment need and masticatory performance. *Orthodontics (Chic)* 2012;13:e20–8.
- [50]. Jamilian A et al. Hypodontia and supernumerary and impacted teeth in children with various types of clefts. *American Journal of Orthodontics and Dentofacial Orthopedics.* 2015;147(2):221-225.

Liliya Angelova, et. al. “Interaction between the Orthodontist and the Pediatric Dentist – An Overview.” *IOSR Journal of Dental and Medical Sciences (IOSR-JDMS)*, 20(05), 2021, pp. 22-31.