

Evaluation of Treatment of Degenerative Disc Disease by Posterior Lumbar Interbody Fusion with Cage and Bone Graft

Md. Alamgir Hossain¹, Md. Jamal Uddin², Md. Taimur Rahman³, Mohammad Kamrul Islam⁴, M. A. Faisal⁵

¹Junior Consultant, Orthopedic Surgery, General Hospital (Victoria), Narayangang, Bangladesh

²Junior Consultant, Orthopedic Surgery, Upazilla Health Complex, Anwara, Chattogram, Bangladesh

³Junior Consultant, Orthopedic Surgery, Adhunik Sadar Hospital, Natore, Bangladesh

⁴Junior Consultant, Orthopedic Surgery, Upazilla Health Complex, Bhaluka, Mymensingh, Bangladesh

⁵Associate Professor, Department of Orthopedic, Bangabandhu Sheikh Mujib Medical University (BSSMU), Dhaka, Bangladesh

Corresponding Author: Md. Alamgir Hossain

Abstract

Background: Degenerative disk disease entails gradual disc space collapse and concurrent discogenic or facet mechanical pain and possible compression radiculopathy. Surgical treatment should aim to re-expand the intervertebral space and to stabilize the involved segment in balanced alignment until fusion is complete. In the posterior lumbar interbody fusion techniques that prevail, installation of large fixed size cages dictate extensive exposure that requires stabilizing the posterior structures. **Objectives:** To see the efficacy of using cage with bone graft in posterior lumbar interbody fusion for the treatment of degenerative disc disease. Purpose of the study are relief of low back pain, instability, radiculopathy, neurological deficiency in degenerative disc disease and return back to his previous work. **Methods:** This is the interventional prospective study. Subjects were evaluated with regard to intra-operative difficulties and complication, radiological fusion and clinical outcome was scored by pre and post-operative questionnaires. **Results:** In our series we did Posterior Lumbar Interbody Fusion with cage in 20 patients and got clinical outcome according to inoue's criteria, excellent- 8 (40%), good- 11 (55%), fair- 1 (5%). So, functional outcome is satisfactory in 19 cases (95%) and non-satisfactory 1 (5%) 1 cases.

Conclusion: There was a markedly higher incidence of fusion rate in patients who underwent Posterior Lumbar Interbody Fusion with cage, bone graft and pedicle screw fixation in Degenerative Disc Disease.

Key Words: Degenerative disc; Posterior lumbar; Cage and bone graft

Date of Submission: 29-04-2021

Date of Acceptance: 13-05-2021

I. Introduction

Degenerative disc disease is manifested by progressive collapse and consequent bulging of the redundant disc surface, the ligamentum flava and the posterior longitudinal ligament, Narrowing of the intervertebral space causes spondylolisthesis and eventual arthrosis of the facet joints. Moreover the involved unstable segment may slip forwards (Spondylolisthesis) or backwards (retrolisthesis). These mechanical alternations may cause discogenic or facet induced pain and possible compressive radiculopathy^[1]. Structural solution of the problem requires reversing the process that is re-expansion of the disc space and immediate stabilization of the segment in a balanced alignment to ensure gradual intervertebral welding. Posterior lumbar interbody fusion (PLIF) is biomechanically sound as it ablates the degenerated disc, restores the normal intervertebral height and dynamically decompressing foraminal stenosis and positions the bone graft along the weight bearing axis^[2]. The immediate initial stability is provided through the tension it exerts upon the annulus fibrosus and inter-spinal ligaments. Moreover, a device enables fusion by a relatively small volume of bone graft, thereby minimizing donor site morbidity. Application of this promising concept was pioneered by Briggs in 1944 and popularized by Cloward shortly thereafter. However, the clinical reviews reported a high rate of graft failure (resorption, migration, nonunion) and donor site morbidity^[3].

In 1988 Bagby introduced the concept of cage support designed to neutralize the compressive forces and to provide immediate (three dimensional) stability essential for successful incorporation of the fragile, cancellous bone graft housed within. More recently, many authors recognize PLIF as providing stability in the central axis of the vertebral segment and thus a preferred method for lumbar interbody fusion^[6]. Furthermore, the importance of maintaining the disc height is increasingly emphasized. In degenerative disc disease or after

discectomy, segmental stenosis occurs due to a combination of disc herniation, posterior spur formation, facet overriding and hypertrophy and infolding of the ligamentum flava. A PLIF with the fusion cage ensures immediate stability while long term disc space maintenance is provided by the resistance of the materials [4]. Surgery for degenerative disc disease has involved two main components: removal of what's causing pain and then fusing the spine to control movement. When removes tissue that's pressing on a nerve, it's called a decompression surgery. Fusion is a stabilization surgery, and often, a decompression and fusion are done at the same time. Facetectomy, foraminotomy, laminectomy, laminotomy, discectomy. After facetectomy, foraminotomy, laminectomy and part of a disc has been taken out, spine may be unstable, meaning that it moves in abnormal ways. That makes more at risk for serious neurological injury. There will need to stabilize spine.

In spine stabilization by fusion, creates an environment where the bones in spine will fuse together over time uses a bone graft and spinal instrumentation—wires, cables, screws, rods, and cage to increase stability as the bones fuse. The fusion will stop movement between the vertebrae, providing long-term stability [5]. Degenerative disc disease is one of the common spinal disabling cause in working age of the people. In our country large number of patients are suffering from degenerative disc disease but lack of facilities and expertise; early diagnosis and treatment are not possible in most of the cases. Due to this detrimental consequence most of the patients become disabled, unemployed, and unproductive; become burdens to the family and to the society. Posterior lumbar interbody fusion by bone graft and cage is the treatment of choice of degenerative disc disease has been done by various center of the world. This operation is also done by few spinal centers in our country but this type of study was not carried out in our country. Outcome of this study may highlight the treatment option of degenerative disc disease. I carried out this study to evaluate the treatment of degenerative disc disease by posterior lumbar interbody fusion with cage and bone graft in our series by comparing with other series. In due course of time, the bone creates a solid bony bridge across the two vertebrae. By doing away with movement, previously painful segment is made pain free [13].

II. Objectives

General Objective:

To see the efficacy of using cage with bone graft in posterior lumbar interbody fusion for the treatment of choice of degenerative disc disease.

Specific Objectives:

To see the relief of low back pain

To see Improvement of neurological involvement

III. Literature Review

This concept first introduced Briggs in 1944 he first reported chip fusion of the low back following exploration of the spinal canal. Shortly thereafter Dr. Ralph Cloward of Honolulu in May 1945 he reported new treatment of ruptured intervertebral disc at fusion-report of 100 cases. In September 1953 Dr. Ralph Clowards first definitive paper on the technique of posterior lumbar interbody fusion (PLIF) entitled. Lin 1983 presented 465 cases treated by PLIF. He got satisfactory result 82%. Dr. Ramani 1996 presented an analysis of 450 cases treated by PLIF. Among them 83.6% give satisfactory result. In 1988 first introduced the using of cage (Stainless steel) containing autogenous bone graft [6]. Young Soo Kim 1992-1996 used cages in 1107 cases for lumbar interbody fusion among them 93.2% gives satisfactory result [12]. Implantation of a single titanium closed box cage in an instrumented PLIF seems to be adequate in case of degenerative lumbar spinal disease. Ray, Charles Dean 1997- Threaded titanium cages for lumbar interbody fusions [11]. This study evaluated safety, fusion success rate and clinical outcome of a new lumbar interbody fusion, threaded titanium fusion cage in a multicenter, prospective 236 case program adhering to a United States Food and Drug Administration Investigation Device Exemption controlled protocol. Segments fused rapidly 96% of the 208. Paired Cylindrical interbody cage fit and facetectomy in posterior lumbar interbody fusion in an Asian population [10]. Among the three lumbar segments (L₃/L₄, L₄/L₅ and L₅/S₁ studied L₅/S₁ had the highest proportion of segments that could accommodate paired cages and at the same time restore intervertebral height. [16]. Bioinechanical comparison of posterior lumbar interbody fusion cages; This study revealed the two cages to have similar biomechanical characteristics immediately after posterior insertion and warrant further clinical studies [17]. Posterior lumbar interbody fusion with bioabsorbable spacers and local autograft in a series of 27 patients [9]. Overall, successful fusion was achieved according to radiographic images at 95.5%.

ANATOMY

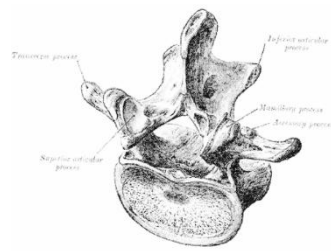


Figure-1: Showing the lumbar vertebrae. (After Grays anatomy 1989)

The largest segments of the movable part of the vertebral column. They are designated L1 to L5, starting at the top. Vertebral body, Vertebral arch. The vertebral arch, consisting of a pair of pedicles and a pair of laminae, encloses the vertebral foramen (opening) and supports seven processes. The body of lumbar vertebra is large, wider from side to side than from front to back, and a little thicker in front than in back.

DISC ANATOMY AND NEUROLOGY

(After D. Gillard 2007), The Nucleus Pulposus (1), Gelatinous center of the disc, The Anulus Fibrosus (2) Outer fibrous structure that of the nucleus pulposus [8]

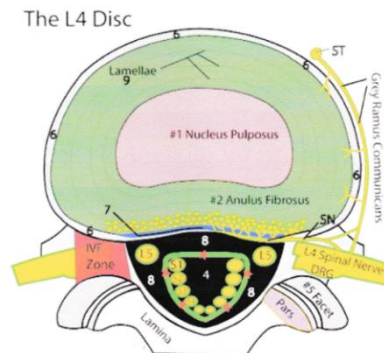


Figure-2: Showing disc anatomy and neurology. (After D. Gillard 2007)

The lamellae are arranged in a special configuration which makes them extremely strong and easily able to contain that pressurized nucleus pulposus. The Spinal Nerves Roots (yellow and labeled L5, S1, S2, S3, S4) Spinal Nerves (L4 yellowy) are extensions of the brain and spinal cord. The nerve roots exit the spine through bony holes called the Intervertebral Foramen (Red Zone).

DISC PHYSIOLOGY (After D. Gillard 2007)

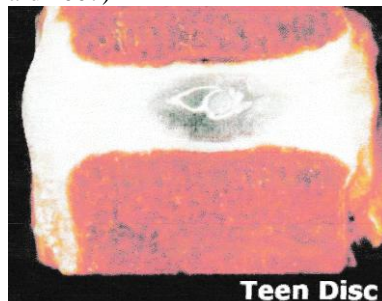


Figure-3: Showing disc physiology. (After D. Gillard 2007)

The largest avascular structure in the human body, Made up of proteoglycan and collagen (type I and type II).

Nucleus is made mostly of proteoglycan, collagen and elastin fibers, Proteoglycans are produced by disc cells that resemble chondrocytes, Both the disc and anulus are comprised mainly of water, the nucleus is 80% water, and the anulus is 65% water. Proteoglycans are building blocks of aggrecan molecule are the true 'water trap' of the disc. In fact a well hydrated disc is often even stronger than the bony vertebral body.

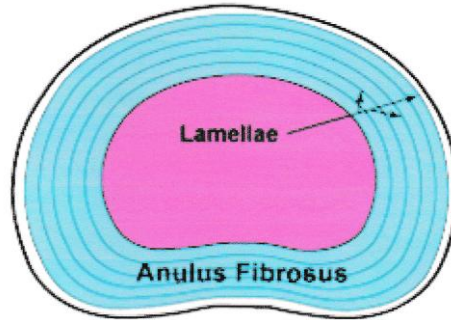


Figure-4: Showing disc physiology. (After D. Gillard 2007)

The anulus is the outer portion of the disc that surrounds the nucleus. It is made up of 15 to 25 collagen sheets which are called the lamellae'. The lamellae are 'glued' together with a proteoglycans. The collagen types I and II making up 55% of the dry weight, and proteoglycans making up 20% of the dry weight. 10% of the anulus also contain 'elastic fiber'. The very outer lamellae (very strong) are almost all Type I.

BIOMECHANICS OF THE SPINAL COLUMN

Human spinal posture is highly individual; through the overall impression is that of a person standing upright. Posture depends primarily on the genetically determined basic structure of the individual's spinal column. The spinal column performs a variety of mechanical functions the most important of which are the absorption, dampening and transmission of pressure and impact loads as well as the absorption and delimitation of movements. The smallest functional element of the spinal column is also known as a mobile segment. A mobile segment consists of 2 neighboring vertebrae, the intervertebra! disc between them, the facet joints and the ligamentous apparatus.

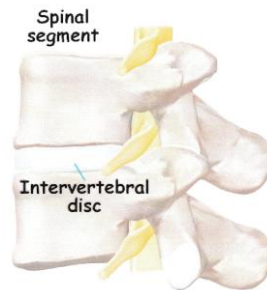


Figure-5: Showing the Smallest unit of the spinal column. (After www, eorthopod. com)

Tension and compression r Lateral shift to right or left r Sagittal shift to front or back. Flexion and extension, Torsion (rotation) to the right or left, Lateral inclination to the right or left.

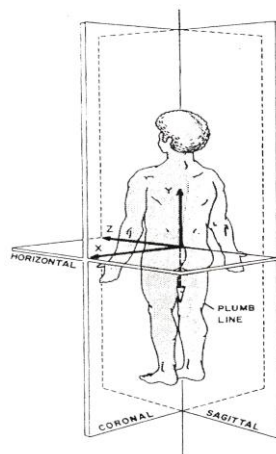


Figure-6: Three dimensional direction of movement. (After Ramani P.S 1996)

Cervical spine: The special structures of the cervical spine give the head its wide range of mobility. In biomechanical terms, the cervical spine is divided into three sections: The upper cervical spine (CO-C2) with

the atlantooccipital (CO-C1) and atlantoaxial (C1-C2) joints that are connected to the occipital bone of the skull. The central cervical spine C2-C5. The lower cervical spine C5-D1.

Thoracic spine: The thoracic spine is the part of the spinal column with the lowest degree of mobility in the frontal and sagittal planes, since the ribs of the thorax are solidly connected by joints to the thoracic vertebrae and the sternum.

Lumbar spine: The lumbar spine, taken as a whole, has a maximum mobility of 60°-70° in flexion and up to 30° in extension. Lateral inclination to the right and left is possible up to 30°. The rotation range of the individual mobile segments in the lumbar spine is limited to only 2°. Lumbosacral transition can be termed a weak point in spinal column statics, since the 5th lumbar vertebra shows a tendency to shift forward in response to changes in the lumbosacral angle (www.harms-spinesurgery.com 2007).

DDD AND DISC AGING

(After D. Gillard 2007)

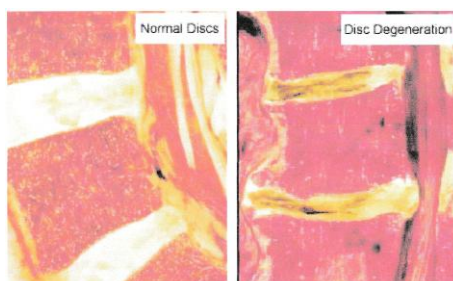


Figure-7: Showing the Normal disc. **Figure-8:** Showing the Degenerated disc.

DDD and Disc Aging: Unlike other tissues of the human body, the poorly vascularized intervertebral disc tends to undergo degeneration of its internal structure at a surprisingly early-age. Three separate stages

First stage: Dysfunction, Individuals 15-45yrs old, Circumferential and radial tears in the disc annulus and Localized synovitis of the facet joint

Second stage: Instability, 35-70yrs old, Internal disruption of the disc, progressive disc resorption

Degeneration of the facet joints with capsular laxity, subluxation and joint erosion

Third stage: Stabilization, Older than 60yrs. Progressive development of hypertrophic bone around the disc and facet joints leads to segmental stiffening to frank ankyloses. Each spinal segment degenerates at a different rate (After Campbell opera. ortho, 2164.)

THE MRI APPEARANCE

(After D. Gillard 2007)

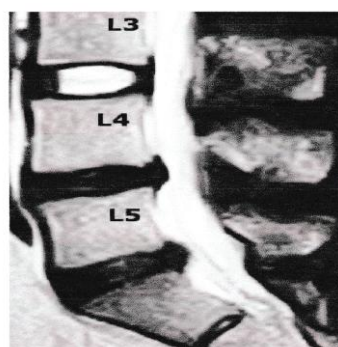


Figure-9: Showing the MRI appearance of degenerated disc.

Such MRI appearances are easy to spot and are characterized by a loss of signal intensity (loss of whiteness) of discal tissue, which makes the disc appear black instead of bright white content

This 'blackening' is called disc Desiccation

RESULTS OF DDD

Progressive collapse and consequent Internal Disc Disruption (IDD) and disc, narrowing of the intervertebral space causes subluxation and eventual arthrosis of the facet joints. The involved unstable segment may slip forwards or backwards. These mechanical alterations may cause discogenic or facet induced pain and possible compressive radiculopathy. There is now strong evidence that pain carrying nerve fibers can grow inward, deep into the middle annulus and even nucleus in some cases! ^[1].

IV. Methods

This is interventional prospective study. The study was conducted at Spinal Unit, Department of Orthopaedic Surgery General Hospital (Victoria) Narayanganj, Bangladesh. Study period was October, 2017 to September, 2019. Total Sample size was 20 cases. Judgment or purposive sampling which was guided as per selection criteria. The study groups were selected from the outpatient department of orthopaedic surgery General Hospital (Victoria) Narayanganj, Bangladesh. A questionnaire was prepared by the researcher considering the key variable like age, sex, presenting symptoms, clinical findings, associated medical conditions, investigations preoperative findings, outcome of surgery which was verified by the guide. The data were collected by the researcher himself. Aims, objectives, procedures, risks and benefits of the study were explained to the patients selected. The patients were encouraged for voluntary participation. They were also assured about the secrecy of information's and records

Statistical analysis: Findings of the study were compiled and calculated quantitative data was described accordingly and some qualitative data was coded and analyzed. Data were expressed as mean \pm SD and percentage. Data were analyzed by SPSS version!2.0 for statistical analysis. Chi-square test and paired t-test were performed as applicable. P value <0.05 as accepted as level of significance.

V. Results

The clinical trial was done on 20 patients whose age range from 40 to 60 years in spine unit of the department of orthopaedic Surgery, General Hospital (Victoria) Narayanganj, Bangladesh. There were 4 male, 16 females' patients. There were 3 patient of dessicated disc and 17 patients of degenerated spondylolisthesis. Among dessicated disc, 1 patients at L₃/L₄, L₄/L₅, 1 patient at L₄/L₅ and 1 patient at L₅/Si among spondylolisthesis 10 patient at L₄/L₅ and 7 patient at L₅/Si, 10 grade-II, 3 patient III and 4 patient grade-I. There were 14 patient impaired sensory functions (70%) and 14 patient impaired motor function (70%) and loss of ankle reflex 3 patients (15%). 20 patients were followed up, the follow up period were ranging froml .5 month to 12 month (mean-6.47, Std.Deviation~2.807). Local bone graft (spinous process, lamina) given in 20 patients. Postoperative complication developed in 1 patient out of 20 patients. Who developed nerve root compression by pedicle screw within the neural foramina between L₄/L₅ (Left). This patient showed postoperative left sided radiculopathy. It is about 5% of total patient. One patient developed superficial wound infection, which was subsequently recovered after daily surgical dressing. Another 1 patient developed per-operative dural tear that was managed properly. Later 2 patients had complete recover}/.

Table-I: Age and Sex distribution of the patients (n=20).

Age in years	no.(%)	Total	Male on (%)	Female on (%)	Total
40-59	14(70.0%)	14(70.0%)	0(0.0%)	14(70.0%)	14(70.0%)
50-59	6(30.0%)	6(30.0%)	2(20.0%)	2(10.0%)	6(30.0%)
		20(100.0%)			20(100.0%)

The result was shown in table-I & figure-10&11

The age ranges from 40 to 60 years & mean age was 50 years. Out of these, age group 40 to 49 comprised of 14 (70%) patients &50 to 59 comprised of 6(30%)patients, Out of 20 patients, 40 to 49 comprised of 14 (70%)female & 50 to 59 comprised of 4(20.0%)male and 2 (10.0%) patients female

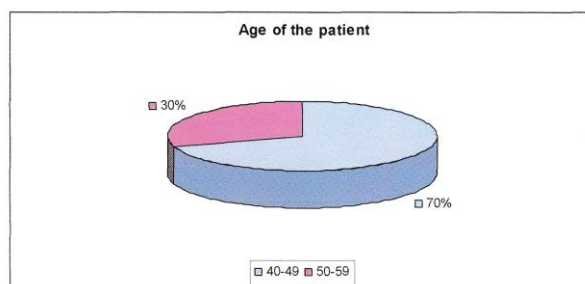


Figure-10: Pie-diagram showing age distribution of the patients.

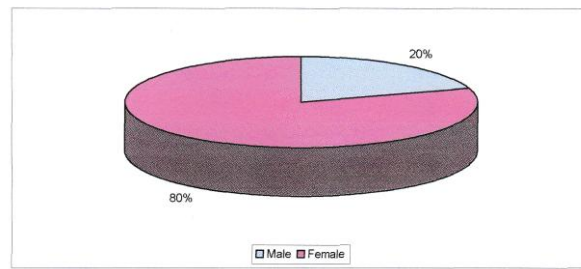


Figure-11: Pie-diagram showing sex distribution of the patients

Table-II: Occupation (n=20)

Occupation	No. of patients	Percentage
Manual worker	3	15.00
Sedentary worker	4	20.00
Housewife	13	65.00
Total	20	100.0

The result was shown in table-II & figure-12. Out of all patients (20) 13 (65%) patients were housewife, 4 (20%) patients were sedentary worker and 3 (15%) patients were manual worker. Occupation housewife is higher than other occupation.

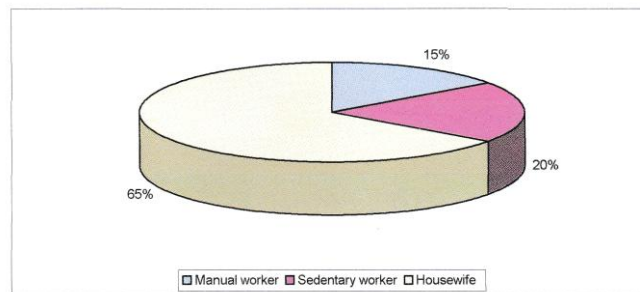


Figure-12: Pie-diagram showing occupation of the patients.

Table-III: Distribution of the patients by low back pain(n=20)

Low back pain	Pre operative	Post operative	P
Present	20(100.0%)	1(05.00%)	0.000
Absent	00(00.00%)	19(95.0%)	---

Data was expressed as mean±SD-0.95±0.22, Statistical analysis was done by paired t test. p-value <0.001 n=Number of cases. Among the 20 (100%) patients 19 (95%) patients reduced low back pain and 1 (5%) patient not reduced low back pain post-operatively.

Table-IV: Distribution of patients by radiculopathy.(n=20)

	pre operative	pre operative	P
Present	17(85.00%)	1(5.00%)	0.000
Absent	3(15.00%)	19(95.0%)	0.000
Total	20(100.00%)	20(100.00%)	

Data was expressed as mean±SD-0.80±0.41. Statistical analysis was done by paired t test, p-value <0.001 n=Number of cases, 17 (85%) patients had pre-operative radiculopathy. 3 (15%) patients had no pre-operative radiculopathy. Among 17 (100%) patients 1 (5.89%) patient was worsen radiculopathy post-operatively. But 16 (94.11%) patients post-operative radiculopathy was subsided.

Table- V: Types of degenerated disc disease(n=20)

DDD	No. of patients	Percentage
Dessicated disc	3	15.00
Olisthesis	17	85.00
Total	20	100.00

The result was shown in table-V. Among 20 (100%) patients of degenerative disc disease 3 (15%) patients were dicsiated disc and 17 (85%) patients were degenerative spondylolisthesis.

Table-VI: Level of dicsiated disc (black disc) (n=20)

Level	No. of patients	Percentage
L ₃ /L ₄	0	0.00
sL ₄ / L ₅	1	5.00
L ₃ / L ₄ & L ₄ / L ₅	1	5.00
LO / S ₁	1	5.00
Total	3	15.00

The result was shown in table-VI. Among 3 (15%) patients of dicsiated disc (black disc) both L₃/L₄, L₄/L₅, is 1 (5%) patient, L₄/L₅ level is 1 (5%) patient and L₅/Si is 1 (5%) patient.

Table-VII: Level of Olisthesis (n=20)

Level	No. of patients	Percentage
L ₄ over L ₅	10	50.00
L ₅ over Si	7	35.00
Total	17	85.00

It was shown in table-VII. L₄ over L₅ is more than L₅ over Si. L₄ over L₅ is 10 (50.00%) and L₄ over S₁ is 7 (35.00%). The incidence is more in L₄ over L₅, than L₅ over SI.

Table-VIII: Grading of spondylolisthesis. (n=20)

Grade	No. of patients	Percentage
I	4	20.00
II	10	50.00
III	3	15.00
Total	17	85.0

It was shown in table-VIII. Among the 17 patient grade I (up to 25% slip) in 4 patient (20.00%) Grade-II (25 to 50%) in 10 patient (50.00%) and grade-III (51 to 75%) in 3 patients (15.00) Grade-II listhesis is higher than other grade.

Table-IX: Sensory status. (n=20)

	Pre-operative	Post-operative
Normal	6(30.0%)	20(100.0%)
Decrease	14(70.0%)	00(0%)
Total	20(100.0%)	20(100.0%)

It is shown in table-IX. Among the 20 patients 14 patients (70%) had sensory impairment and 6 (30%) patients had no sensory impairment. After operation all patients were free from sensory deficit.

Table-X: Motor status. (n=20)

	Pre-operative	Post-operative
Normal	06(30.0%)	20(100.0%)
Decrease	14(70.0%)	00(0%)
Total	20(100.0%)	20(100.0%)

It was shown in table-X. Among 20 patients 14 (70%) patients had motor function impairment and 6 (30%) patients had no motor impairment. Post operatively all patients were recovered from motor impairment.

VI. Discussion

PLIF is increasingly advocated as the treatment of choice for disabling LBP due to DDD. From a biomechanical point of view, the graft is placed at the weight bearing center of the spine. Where 80% of the axial load occurs. The disc height and the sagittal balance can be restored just as well because optimal conditions are created for a higher fusion rate by placing the grafted cage under compression with an extensive blood supply from the adjacent vertebral end plates. Finally, the amount of bone required for the graft is significantly reduced. Via a posterior approach, the spinal canal can be easily explored; fixation can be achieved during the same operative session and the use of locally derived bone graft that reduced donor site morbidity. In this study we wanted to see the outcome of surgical treatment of DDD by using bone graft with cage. The outcome of this study was categorized as excellent, good, fair and poor according to inoue's grading. For

statistical analysis excellent and good results were regrouped as satisfactory and fair and poor results were regrouped as unsatisfactory.

In my study among 20 patients male patient 4 (20%), female patient 16 (80%). So, male: female- 1:4; female predominant. They did a multi-center clinical study of posterior lumbar interbody fusion with the expandable stand-alone cage for degenerative lumbar spinal disorders out of 57 patients; 37 (64.9%) female and 20 (35.1%) male patient's.^[15] So, female is predominant. In our series all patients were below 60 years. Among the 20 patient, the age ranges from 40 to 60 years. Mean age 50 years. Out of these, age group 40-49 comprise 14 (70%) and 6 (30%) patients within 50-59 years. Average age 46.15. Age group 40-49 were significantly high, as shown in Table-I. John W. Brantigan et al 2000- they did Posterior Lumbar Interbody Fusion with cage of 221 patients^[7]. Among them average age 44.3. Posterior lumbar interbody fusion combined with instrumented postero-lateral fusion: 5 years follow up in 60 patients- 83% give satisfactory result.^[18] Incidence, etiology classification and management of neuralgia after posterior lumbar interbody fusion surgery in 226 patients.^[19] The lumbar I/F cage for posterior lumbar interbody fusion with the variable screw placement system, 10 year results of Food and Drug Administration clinical trial gives 61% excellent, 27% good, 12% fair. Fusion success was reported 100%, patients satisfaction was reported 93.9%. [7].

This series is nearly similar to our series. In our series out of 20 patients 3 (15%) patients were manual worker, 4 (20%) patients were sedentary worker and 13 (65%) patients are housewife. Occupationally housewives were predominant, as shown in table-II All patients in our series of degenerated disc disease had low back pain. Among the 20 (100%) patients 19 (95%) patients reduced low back pain and 1 (5%) patient not reduced low back pain post-operatively as shown in table-III. Categorized the patients in two groups' preoperative and postoperative of all patients with low back pain and paired t-test was done between two groups. Test is very highly significant (PO.001), as shown in table-III. Among the 20 (100%) patients 17 (85%) patients had pre-operative radiculopathy. Among them 4 (20%) patients were right sided, 3 (15%) left sided and 10 (50%) patients were both side involvement. 3 (15%) patients had no pre-operative radiculopathy. 1 (5%) patient was worsen radiculopathy post-operatively. But 19 (95%) patients post-operative radiculopathy was subside, as shown in table-IV. Categorized patients in two groups' pre and post-operative radiculopathy. Following paired t test statistically significant difference was found.

Hence, post-operative radiculopathy was significantly associated with the outcome of treatment (p<.001), as shown in table-IV. In this series out of 20 cases 3 (15%) patients were dessicated disc (black disc) and 17 (85%) patients were degenerative spondylolisthesis. Among 3 (15%) patients of dessicated disc (black disc) both L₄/L₅ is 1 (5%) patient, L₄/L₅ level is 1 (5%) patient and L₅/S₁ is 1 (5%) patient. Among 17 patients of degenerative spondylolisthesis 10 (50%) patients were at L₄/L₅ and 7 (35%) were at L₅/S₁, as shown in table-IX. Monoj Krishna et al 2008- they did study 226 patients of Poster Lumbar Interbody Fusion among them 148 (65.5%) were dessicated disc and 27 (11.9%) were degenerative spondylolisthesis. Our series are not similar to that series. In 17 (85%) patients of degenerated spondylolisthesis 4 (20%) patients were grade-I, 10 (50%) patient's grade-II and 3 (15%) patients were grade-III. Grade-II listhesis is higher than other grade, as shown in table-VIII. In this series out of 20 patients, 14 (70%) patients showed sensory deficit and 14 (70%) patients showed motor deficit. This is possible because due to poverty and illiteracy patient came lately and less availability of diagnostic procedure and less number of expertise. More patients Presented with late neurological deficit. Post-operative follow up showed that the neurological deficit gradually became improve and finally all patients were free from neurological deficit, as shown in Table-IX&X.

Limitations of the study: The number cases in our study are small and duration in only 2 years and it is too early to say confidently that our results are static. So, the study should continue at least 5 years. There is no C-arm available during per operative penetration of pedicle screw through pedicle.

VII. Conclusion And Recommendation

Posterior Lumbar Interbody Fusion with cage with bilateral pedicle screw and rods provides adequate alignment, balance and mechanical stability and allows the minimum amount of autologous graft to fill the disc space. In this series, the combination of this procedure in ODD demonstrates clinical success in 95%. A stable fixation in all cases and a low complication rate 5%. The procedure is technically demanding and should only be performed by an experienced surgeon. We can only expect further improvement as spine specialists continue to adopt and develop emerging technologies and integrated them into their practices. We recommended the PLiF with cage and stabilization pedicle screw and rods for surgical treatment of degenerative disc disease. Development of multiple centers in our country in order to manage the detrimental consequence of DD. MRI should be the investigation of choice for early diagnosis. So, creation of multiple investigation center with MRI facilities in the periphery to combat the devastating consequence of DDD. Development of multiple spinal

centers in our country with C-arm facilities; it helps per operative penetration of pedicle screw through pedicle and reduces operative time.

References

- [1]. Yorum F, Sang-HL, Jose RS and Reuven G, 2003, 'Posterior lumbar interbody fusion for degenerative disc disease using a minimally invasive B-iwin expandable spinal spacer', *J Spinal Disord Tech*, vol, 16,pp.455-460.
- [2]. Evans JH, 1985, 'Biomechamcs of lumbar fusion", *Clin Ortho*, vol. 193, pp.38-46.
- [3]. Lin PM, 1985, 'Posterior lumbar interbody fusion technique: Complications and pitfalls', *Clin Orthop*, vol. 193, pp.90-102.
- [4]. Ramani P S,1996, "Posterior lumbar interbody fusion", Text book spinal surgery, 1st edition Department of Neuro -spinal surgery, University of Bombay, Mumbai,India,pp .5 89-90.
- [5]. Kamiah A Walker 2009, 'Surgery for degenerative disc disease, Retrieved may2 8,2009. Availablefrom: www.spineuniverse.com/condition /degenerative disc disease.
- [6]. Bagby GW, 1988, 'Arthrodesis by the distraction-compression method using a stainless steel implant', *Orthopedics*, vol. 11, pp. 931-4.
- [7]. Jon W.Brantigan, Arvo Neidre, John S. Toohey, 2004, 'The lumbar 1/F cage for posterior lumbar interbody fusion with the variable screw placement system: 10-year results of a food and drug administration clinical trial', *The spine journal*, vol. 4, pp.681-688.
- [8]. D.Gillard 2007.Disc anatomy available from www.chirogeek.com/'ooo_disc_anatomy.htm.
- [9]. Daniel E, Couture, and Charles L Branch Jr. 2004, "Posterior lumbar interbody fusion with bioabsorbable spacer and autograft in a series of 27 patients", *Neurosurg Focus*16(3): ArticaiS.
- [10]. James C.H.Goh et al, 2000, 'influence of PLIF cage size on lumbar spine stability',. *Spine*, vol. 25, pp.35-40.
- [11]. Ray CD, 1997, "Threaded titanium cages for lumbar interbody fusion \ *Spine*, vol. 22, pp.667- 80.
- [12]. Stefan Kroppenstedt, Martin Guide and Robert Schonmayr, 2008, 'Radiological comparison of instrumented posterior lumbar interbody fusion with one or two closed-box plasmapore coated titanium cages', *Spine*, vol.33, pp. 2083-2088.
- [13]. Drruchika 2009, "Specialized surgical options for degenerative disc disease available in india at affordable price' .May2009, Available from :www.spineuniverse.com/condition/degenerative disc disease
- [14]. Siviero Agazzi, Alain Reverdin,and Daniel. May, 1999- Posterior lumbar interbody fusion with cages; an independent review of 71 cases.
- [15]. Jin Wook Kim, M.D. et. al 2007.
- [16]. Hee Kit Wong, James C.H.; Goh, and Poh-Sun Goh, 2001- Paired Cylindrical interbody cage fit and facetectomy in posterior lumbar interbody fusion in an Asian population. Among the three lumbar segments (L₃/L₄,L₄/L₅ and L₅/S₁) studied L₅/S₁ had the highest proportion of segments that could accommodate paired cages and at the same time restore intervertebral height.
- [17]. Rapoff, Andrew j, Ghanayem, Alexander j, Zdeblick, Thomas A, 1997, 'Biomechanical Comparison of Posterior Lumbar Interbody Fusion Cages',*Spme*,voi.22,pp.2375-2379.
- [18]. Freeman BL. Licina P, Mehdian SH, 2000, "Posterior lumbar interbody fusion combined with instrumented postero-lateral fusion: 5-year result in 60 patients \ *Eur Spin j*; 9:42-6.
- [19]. Manoj Krishna, Raymond D. Pollock, Chandra Bhatia,2008, * Incidence, etiology, classification, and management of neuralgia after posterior lumbar interbody fusion surgery in 226 patients', *Spine*, vol.8, pp.374-379.

Md. Alamgir Hossain, et. al. "Evaluation of Treatment of Degenerative Disc Disease by Posterior Lumbar Interbody Fusion with Cage and Bone Graft." *IOSR Journal of Dental and Medical Sciences (IOSR-JDMS)*, 20(05), 2021, pp. 51-60.