

## Diagnostic Value of Ascitic Fluid Cytology in Malignancy

Dr. Yadav Hanmantrao Chavan<sup>1</sup>, Dr. Umme Ammarah Farooqui<sup>2</sup>

<sup>1</sup>Associate Professor, <sup>2</sup>Senior resident, Department of pathology,  
DR. Shankarrao Chavan Government Medical College, Nanded.

### Abstract

**Background-** Patients with malignant ascites clinically present similarly to those with non-malignant cause. Cytological examination of ascitic fluid is one of the first line investigations, if a malignant cause is suspected. Although many cases of ascites have an intra-abdominal malignancy, very few are diagnosed by ascitic fluid cytology.

**Objective-** The aim of this study is to evaluate the diagnostic efficacy of ascitic fluid cytological examination in determining malignancy.

**Method-** This was Retrospective observational study of patients admitted in Government Medical College, Nanded with ascites related malignancy. Patients with malignancy diagnosed radiologically or confirmed histopathologically were included in the study.

**Result-** Out of 30 samples sent for assessment, 19 were found to be positive for malignancy. The sensitivity of ascitic cytology was found to be 63.3% with 100% specificity. False negatives were found to be as high as 36.6%

**Conclusion-** When a malignancy is suspected, completely relying on cytology for diagnosis is not helpful in many cases. An integrated approach - clinical history, examination, radiology, SAAG and cytology is needed.

Date of Submission: 15-05-2021

Date of Acceptance: 31-05-2021

### I. Introduction

Malignant Ascites is defined as an accumulation of excess fluid in the peritoneal cavity secondary to a disseminated malignancy<sup>1</sup>.

Malignant ascites is a sign of peritoneal carcinomatosis, the presence of malignant cells in the peritoneal cavity. Tumours causing Carcinomatosis are more commonly secondary peritoneal surface malignancies which include : ovarian, colorectal, pancreatic, and uterine; extra abdominal tumours originating from lymphoma, lung and breast and a small number of unknown primary tumours. Malignant ascites occurs in 10% of all cases of ascites. The quality of fluid in patients with malignancy related ascites due to peritoneal carcinomatosis is distinctive, with positive cytology, high ascitic fluid protein concentrations and low serum-ascites albumin gradient<sup>3</sup>. Low gradient (< 1.1 g/dl) indicates causes of ascites not associated with increased portal pressure such as- tuberculosis, pancreatitis, peritoneal carcinomatoses etc. thus helping to differentiate malignant from non-malignant cause of ascites. The high protein content of malignant ascites indicates that there is an alteration in vascular permeability to allow for large molecules to accumulate in the intraperitoneal space. The biochemical properties of ascites fluid, including fibronectin, cholesterol, lactate dehydrogenase, sialic acid, telomerase activity and proteases, have been studied and while clinically helpful, they have not yet been found to be reliable in differentiating between malignant and benign ascites<sup>4</sup>

**PATHOPHYSIOLOGY-** The pathophysiology of malignant ascites is multifactorial. It is postulated that ascites formation is related to a combination of altered vascular permeability and obstructed lymphatic drainage<sup>5</sup>. There is an imbalance between fluid secretion and absorption by peritoneum. This is secondary to increased fluid production by tumour cells lining peritoneal cavity in cases of peritoneal carcinomatosis, alteration in vascular permeability, release of inflammatory cytokines and decreased lymphatic drainage due to tumour involvement and increased portal pressure due to tumour metastasis<sup>6</sup>

**PATIENTS AND METHODS-** We carried out retrospective analysis of malignant ascites in patients visiting Government medical college Nanded during a period of two years. The aim of the study was to determine efficacy of the ascitic fluid cytology in determining malignancy. Using the hospital data records, cytology specimens were identified and analysed. Each patient's electronic record was also reviewed for their clinical diagnosis, investigations, surgeries along with their care records via the hospital management information system. Those who were found to have an intra-abdominal malignancy were included in the study.

## II. Results

During two years period , 30 cases were identified , 16 male and 14 female. Of this 19 , were found to have malignant cells on cytology ( 6 females and 4 males) . The remaining 10 patients were reported as having no evidence of malignancy, While one sample ( male) was reported as inadequate. The 10 patients reported negative were false negatives as they had intra-abdominal malignancy, detected by other modalities like USG, MRI, and histopathological examination.

In the 11 female patients reported as positive, 8 had underlying ovarian malignancy, constituting upto 83.33% of positive cases, 2 patients had primary in gastrointestinal tract and one female patient had breast cancer as the primary lesion. While in 8 Male patients reported as malignancy on cytology, 6 of them had primary in the gastrointestinal tract, (75% of positive cases), one patient had secondary deposits in liver with unknown primary lesion with one patient having carcinoma.

In 11 patients (57.8 %) in our study , the presence of ascites was the first clinical sign of an underlying neoplastic process, which is in concurrence with other reports.<sup>8,9,10</sup> These patients were mainly the ovarian and the G.I cancer groups , while patients with breast cancer tended to develop ascites months or years after primary had been diagnosed and treated.

In our study ascitic fluid analysis for females was found useful in the assessment of possible ovarian cancer, as 83.33% of all the positive cytology results were ovarian in origin.

Overall Sensitivity of ascitic fluid cytology in diagnosing malignancy was 63.33%, with 78.5% in females compared to 50% in males. Overall false negative rate was 33.3% .

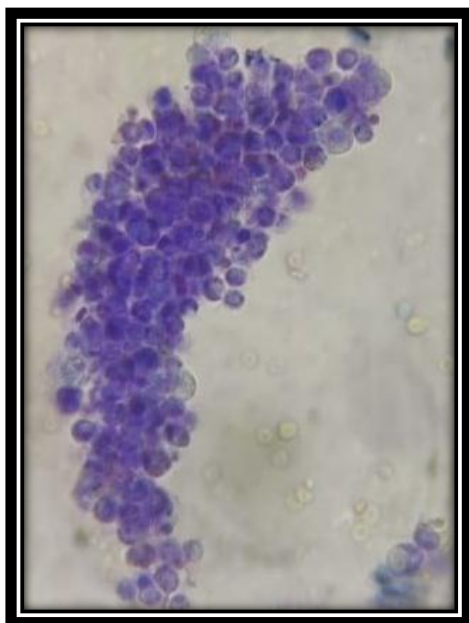
## III. Discussion

Two thirds of cases of ascites are due to malignancy are caused by peritoneal carcinomatosis, while the most common tumours causing peritoneal carcinomatosis are primary adenocarcinomas of the ovary, uterus, pancreas, stomach, colon, lung or breast. The remaining one third is due to hepatocellular carcinoma or diffuse hepatic metastases<sup>6</sup>.

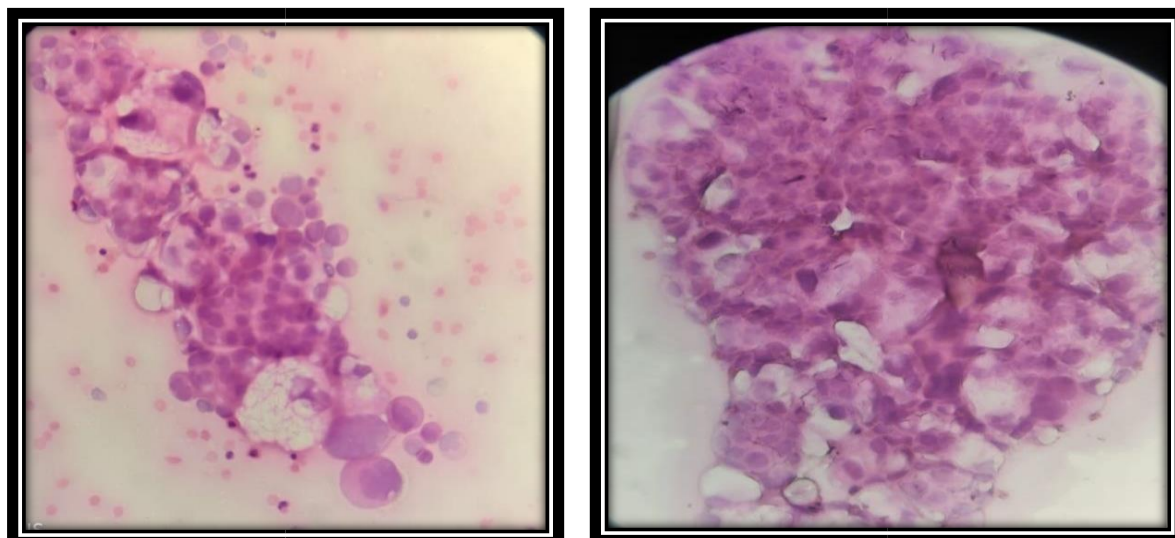
In our study we found 83% of all the positive cytology were ovarian in origin. Monte concluded that ovarian cancer is the most

likely diagnosis in woman with a non liver related ascites<sup>7</sup>.

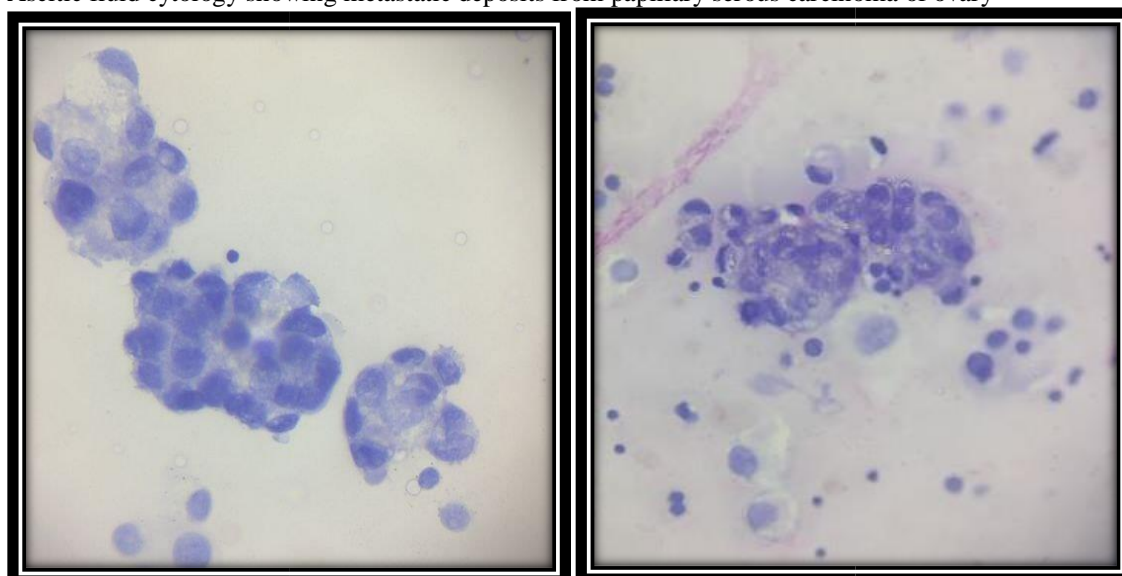
From the results we can conclude that ascitic fluid cytology analysis should be carried out as an additional investigation instead of primary test. Ultrasound examination should not be delayed for fluid cytology reports. We found that an integrated approach correlating clinical history, examination ,radiology, SAAG and cytology can be more helpful than ascitic fluid cytology alone.



The cluster of cells showing overlapping, hyperchromatic nuclei , with high nucleocytoplasmic ratio in peritoneal carcinomatoses on wet mount.



Ascitic fluid cytology showing metastatic deposits from papillary serous carcinoma of ovary



Photomicrographs showing 3 dimensional clusters with nuclear pleomorphism in adenocarcinoma on ascitic fluid cytology

### References

- [1]. Becker G, Galandi D, Blum he(2006) Malignant Ascites: Systematic Review and guideline for treatment. Eur J Can 42(5): 589-597
- [2]. Runyon BA. Care of the patients with ascites. N Engl J Med 1994; 330:337-342
- [3]. Runyon BA ,Hoefs JC, Morgan TR. Ascitic fluid analysis in malignancy- related ascites. Hepatology 1988 8: 1104-1109 4. Tangkijvanich P, Tresukosol D, Sampatanukul P,Sakdikul S, Voravud N, Macahi V, Mutirangura A. Telomerase assay for difrentiating between malignancy related and non malignant ascites. Clin Cancer Res 1999;5 2470- 2475
- [4]. Putnam TJ. The living peritoneum as a dialyzing membrane. Am J
- [5]. Physiol 1923,63: 548-565
- [6]. Le Blanc K and Arnold RA. Fast fact and concept #176. Evaluation of Malignant ascites . March 2007. End of life/palliative education resource centre <http://www.eperc.mcw.edu>.
- [7]. Monte SA, EhyaH,Lang WR. Positive effusion cytology as the initial presentation of malignancy. Acta cytol 1987;31:448-52
- [8]. Ayantunde AA, Parsons SL. Pattern and prognostic factors in patients with malignant ascites: a retrospective study. Ann Oncol. 2007;18:945-9
- [9]. Garrison RN, Kaelin LD, Galloway RH, Heuser L. Malignant ascites :clinical and experimental observations. Ann surg 1986;203:237-239
- [10]. Adam RA, Adam YG. Malignant ascites: past, present and future. J Am Coll Surg 2004; 198:999

Dr. Yadav Hanmantrao Chavan, et. al. "Diagnostic Value of Ascitic Fluid Cytology in Malignancy." *IOSR Journal of Dental and Medical Sciences (IOSR-JDMS)*, 20(05), 2021, pp. 25-27.