

Left Hemianopia and Superotemporal Branch Retinal Vein Occlusion

Battula Vishnuvardhan¹, Anees fatima², malleswari medikonda^{1,2,3}
^{1,2,3}(Sankara Eye Hospital,,Guntur, Andhra Pradesh, India)

Abstract: Purpose: Hypertension is the most prevalent risk factor for stroke and has been reported in 64% of patients with stroke. Hypertensive emergencies are defined as severe elevations in BP (>180/110 mmHg) associated with evidence of new or worsening target organ damage. Hereby we report a case of Left Homonymous Hemianopia due to Occipital lobe Infarction and superotemporal BRVO. Usually occipital lobe infarcts show hemianopias, but here the patient also developed Branch Retinal vein occlusion in right eye at the same time. This presentation can only lead us to one leading risk factor/cause that is,; Hypertension. So the purpose of our study is to remind my fellow Ophthalmologists and Physicians to consider and treat hypertensive emergencies on priority basis and regular checkups for known hypertensives.

Date of Submission: 16-04-2021

Date of Acceptance: 30-04-2021

I. Introduction

Stroke is the second most common cause of mortality worldwide and the third most common cause of disability(1). Hypertension is the most prevalent risk factor for stroke. Hypertensive emergencies are defined as severe elevations in BP (>180/110 mmHg) associated with evidence of new or worsening target organ damage and the most common emergency symptoms will depend on the organs affected but may include headache, visual disturbances, chest pain, dyspnea, dizziness and other Neurological deficits(2). Homonymous hemianopia (HH) involves vision loss on the same side of the visual field in both eyes. This type of visual field loss is indicative of a lesion involving the visual pathway posterior to the chiasm, most common cause of HH in adults is stroke. 52%–70% of hemianopias are caused by stroke(3,4). For lesions behind the LGN, visual field defects are generally more congruous if the lesion is located more posteriorly along the visual pathway and 84% of occipital lobe lesions produce congruous visual field defects(5). Macular representation, found at the posterior pole of the occipital lobe, is disproportionately large. It is estimated that 50%–60% of the visual cortex represents 10°–30° of central vision, because of the large macular representation, as well as the dual blood supply to the posterior occipital lobe, sparing of the central 2°–10° of the visual field is commonly found with occipital lobe lesions(6,7).

II. Case Report

A 44 years, Female, house wife came with chief complaints of Loss of vision in one half of visual field since 1 day and Headache on and off since a week, which was dull and boring and didn't reduce with any oral medication.

She didn't give any history of systemic illness except Hypertension (since 7 years) for which she was on oral anti-hypertensives. There was No history of any systemic and ocular Trauma.

Vision in OD was 6/12 unaided and improving to 6/6(p) with -0.75 with 85 degree cylinder but still complained some discomfort and 6/6 unaided in OS. Colour vision was WNL(21/21 on Ishihara chart) in both eyes, IOP(on NCT) was 16 and 20 mm of Hg in OD and OS respectively.

Anterior segment examination under Slit lamp(lids, conjunctiva, cornea, pupillary reaction and lens) were all WNL for both eyes, but on posterior segment(dilated fundoscopy) Hemorrhages, tortuous vessels and AV crossing changes in Superotemporal aspect in OD were noted(Figure 1) and it was normal in OS(figure 2).

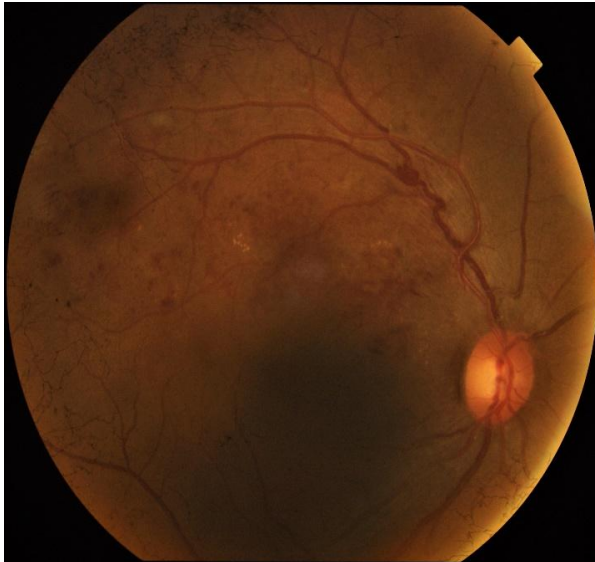

Fig.1: ST BRVO

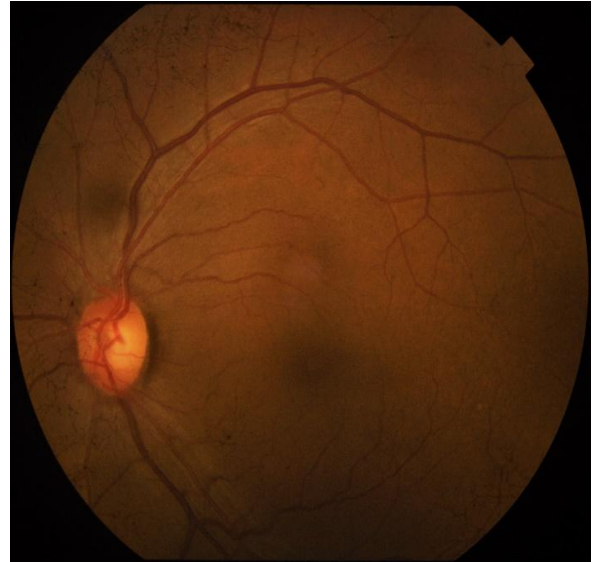


Fig.2 : WNL

She was also evaluated for visual fields with Humphrey SITA-Fast and Left Hemianopia was noted (Figure 3-OD and 4-OS). Her vitals were recorded and blood pressure was 210/110 mm of Hg and pulse 82/min, so she was immediately referred to a Neurophysician for Hypertensive emergency and advised for MRI brain.

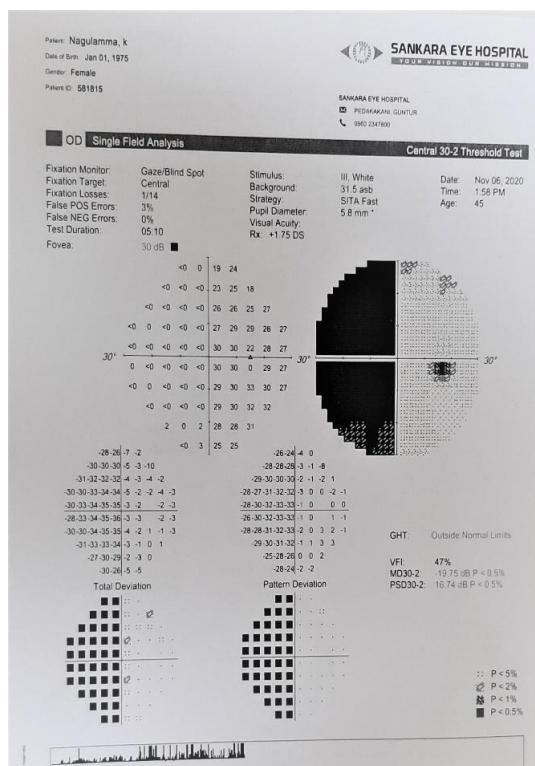


Fig.3

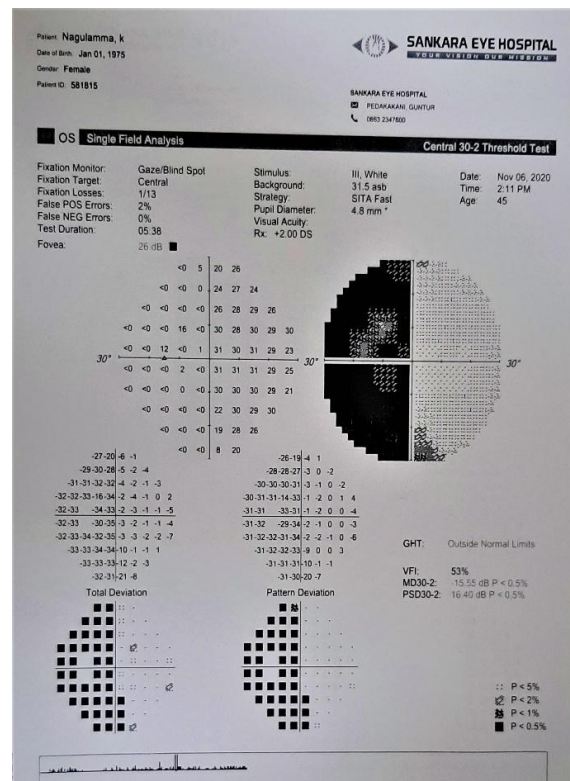


Fig.4

III. Result

On MRI brain she was reported with Occipital lobe Infarct (R>L) and was admitted in a Neurospeciality hospital for a week. There she was treated with I.V antibiotics and vit B12, T. Ecosprin (325 mg) and T. Clopiet A (75/150 mg) given stat and other oral antihypertensives were added. On admission she was diagnosed with Denovo DM with FBS and PPBS 195 and 242 mg/dl resp. and HBA1c levels 13.7, therefore oral Antihypoglycemic's and Inj. Insulin 15 units were started.

IV. Discussion

Among patients with acquired hemianopia secondary to stroke, the nature of the deficit can vary widely, depending on the location of the lesion and the part of the visual pathway that is disrupted, and recovery and functional improvement are adversely affected even when severity of stroke and motor deficits are controlled (8,9). Completed ischemic infarcts are not expected to worsen after initial injury, unless new injury occurs. Poststroke treatment thus includes identification of the stroke etiology, risk factor modification to prevent recurrences, and initiation of early and intensive rehabilitation to optimize functional outcomes. Such intensive rehabilitation has been shown to improve disability and independence after stroke, and even to reduce mortality(10-14). Few retrospective studies showed spontaneous improvement in 50% to 60% of patients within the first month after stroke, and almost none after 3 months(15). Patients with hemianopia tend to look toward their blind hemifield, even when confronted with visual scanning tasks. In addition, patients searching for targets in their blind hemifield perform a series of hypometric saccades that approach the target until it is found. After the target is found, the saccades become hypermetric with a subsequent corrective saccade back to the target(15). These natural compensatory strategies have been adapted into formal training protocols, which teach the patient how to consciously plan appropriate saccades and scanning strategies to more effectively bring the blind hemifield into the intact one in an organized and systematic fashion. These training strategies have been shown to improve the search fields of hemianopic patients by upto 10 degrees, reduce the time to find objects by up to 50%, and improve patients sense of impairment(16,17,18).

Optical aids work by either relocating the visual information received by the hemianopic field onto the normal visual field, or by expanding the normal visual field(19), Fresnel prisms (plastic press-on lenses that are fitted onto standard glasses) can be either monocular or binocular(fig.5). The commercially available prisms are typically 57 prism diopters and expand the field by about 30 degrees.

Another mode of treatment is Visual Restoration Therapy(VRT) ,this system targets the border zone between the intact visual field and the scotoma with suprathreshold light stimuli. The stimulus is postulated to recruit residual intact neurons in border zone areas between the intact visual field and the scotoma, stimulating any inherent plasticity in the visual system and thereby increasing the size of the visual field and reducing the size of the scotoma. When examined subjects with optic nerve lesions (but not visual cortex lesions) showed a reduction in the size of their scotoma; the border shift in cortical lesions was 0.43 degrees , and in optic nerve lesions 2.1 degrees(20).



Fig. 5: Obliquely oriented high-power Fresnel prism to expand the visual field(done to increase awareness of the left hemifield in a patient with a left homonymous hemianopia)

V. Conclusion

To sum Neither VRT nor other researched methods of visual system training and visual aids have led to standardized approaches to visual rehabilitation in patients with visual field defects, indicating that larger and more targeted studies are still needed to determine the best approach to the patient . Through our study we want to highlight that even Posterior segment OCT and complete funduscopy would be advisable for patients presenting with such symptoms and signs on the 1st visit itself. Hypertensives should be evaluated with utmost care as a precautionary measure and should be motivated to get regular checkups.

References

- [1]. Lozano R, Naghavi M, Foreman K et al. Global and regional mortality from 235 causes of death for 20 age groups in 1990 and 2010: a systematic analysis for the Global Burden of Disease Study 2010. *Lancet*. 2012;380:2095–128. doi: 10.1016/S0140-6736(12)61728-0
- [2]. Phal P, Molan M, Clare I. Hypertensive encephalopathy. *Australas Radiol*. 2002;46:319–24. doi: 10.1046/j.1440-1673.2002.01070.x.
- [3]. Zhang X, Kedar S, Lynn MJ, et al. Homonymous hemianopia in stroke. *J Neuroophthalmol*. 2006;26(3):180–183

- [4]. O'Neill EC, Connell PP, O'Connor JC, et al. Prism therapy and visual rehabilitation in homonymous visual field loss. *Optom Vis Sci*. 2011;**88**(2):263–268
- [5]. Kedar S, Zhang X, Lynn MJ, et al. Congruency in homonymous hemianopia. *Am J Ophthalmol*. 2007;**143**(5):772–780
- [6]. McFadzean R, Brosnahan D, Hadley D, et al. Representation of the visual field in the occipital striate cortex. *Br J Ophthalmol*. 1994;**78**(3):185–190
- [7]. Korogi Y, Takahashi M, Hirai T, et al. Representation of the visual field in the striate cortex: comparison of MR findings with visual field deficits in organic mercury poisoning (minamata disease) *AJNR Am J Neuroradiol*. 1997;**18**(6):1127–1130
- [8]. Patel AT, Duncan PW, Lai SM, et al. The relation between impairments and functional outcomes poststroke. *Arch Phys Med Rehabil* 2000;**81**:1357–63.
- [9]. Pambakian A, Currie J, Kennard C. Rehabilitation strategies for patients with homonymous visual field defects. *J Neuroophthalmol* 2005;**25**:136–42.
- [10]. Han L, Law-Gibson D, Reding M. Key neurological impairments influence function-related group outcomes after stroke. *Stroke* 2002;**33**:1920–4.
- [11]. Patel AT, Duncan PW, Lai SM, et al. The relation between impairments and functional outcomes poststroke. *Arch Phys Med Rehabil* 2000;**81**:1357–63.
- [12]. Strand T, Asplund K, Eriksson S, et al. Stroke unit care—who benefits? Comparisons with general medical care in relation to prognostic indicators on admission. *Stroke* 1986;**17**:377–81.
- [13]. Minematsu K. Acute ischemic stroke. *Rinsho Shinkeigaku* 2003;**43**:796–8 [in Japanese].
- [14]. Turner-Stokes L, Pick A, Nair A, et al. Multi-disciplinary rehabilitation for acquired brain injury in adults of working age. *Cochrane Database Syst Rev* 2015;**12**: CD004170.
- [15]. Das A, Huxlin KR. New approaches to visual rehabilitation for cortical blindness: outcomes and putative mechanisms. *Neuroscientist* 2010;**16**:374–87.
- [16]. Pambakian A, Currie J, Kennard C. Rehabilitation strategies for patients with homonymous visual field defects. *J Neuroophthalmol* 2005;**25**:136–42.
- [17]. Zihl J. Recovery of visual functions in patients with cerebral blindness. Effect of specific practice with saccadic localization. *Exp Brain Res* 1981;**44**:159–69.
- [18]. Kerkhoff G. Neurovisual rehabilitation: recent developments and future directions. *J Neurol Neurosurg Psychiatr* 2000;**68**:691–706.
- [19]. Pelak VS, Dubin M, Whitney E. Homonymous hemianopia: a critical analysis of optical devices, compensatory training, and novavision. *Curr Treat Options Neurol* 2007;**9**:41–7.
- [20]. Kasten E, Wu'st S, Behrens-Baumann W, et al. Computer-based training for the treatment of partial blindness. *Nat Med* 1998;**4**:1083–7.

Battula Vishnuvardhan, et. al. "Left Hemianopia and Superotemporal Branch Retinal Vein Occlusion." *IOSR Journal of Dental and Medical Sciences (IOSR-JDMS)*, 20(04), 2021, pp. 01-04.