

## The New Alternative to Conventional Dentures- All on 4 Dental Implant Treatment Concept: A Review Article

Dr. Shreya H. Mantri<sup>1</sup>, Dr. Sandeep S. Fere<sup>2</sup>, Dr. Sheeraz Badal<sup>3</sup>

<sup>1</sup>Intern, (Maharashtra Institute of Dental Sciences and Research Dental College, Latur / Muhs, India)

<sup>2</sup>Reader, (Department of Prosthodontics, Maharashtra Institute of Dental Sciences and Research Dental College, Latur / Muhs, India)

<sup>3</sup>Professor and Head of Department, (Department of Oral and Maxillofacial surgery, Maharashtra Institute of Dental Sciences and Research Dental College, Latur / Muhs, India)

**Abstract:** This review focuses on the concept that is used for the rehabilitation of edentulous arches i.e. All on 4 dental implant treatment, regarding its indications, surgical procedures, prosthetic protocols, advantages, disadvantages and its limitations. As implant supported prosthesis is impossible in many conditions without complex techniques such as nerve transposition, grafting, sinus lifting because of vicinity of vital anatomical structures, poor bone quality and quantity or atrophic jaws. So, implant technology developed the All on 4 treatment concepts as an alternative to conventional implant applications. This concept allows the rehabilitation of edentulous patients that is two implants are placed in the front of jaw and two are in the back at an intended angle (30°-45°). As this concept provides replacement of permanent implant retained prosthesis in same day, so it is called "Teeth in 1day" treatment concept. This is the immediate loading technique, which will maintain the structural integrity and supports the removable or fixed prosthesis of patients with superior esthetics and masticatory properties and reduces the discomfort and damage of hard and soft tissues.

**Key Words:** All on 4, dental implant, rehabilitation, prosthesis

Date of Submission: 14-03-2021

Date of Acceptance: 28-03-2021

### I. Introduction

Edentulism or missing teeth is a very common problem, which can be result of many factors such as poor oral hygiene, dental caries, and periodontal disease. There are also some individuals who face edentulism due to terminal non-restorable dentition. It has been shown to have negative social and psychological effects on individuals. It gives rise to gradual resorption of alveolar process, with change in the bone and muscle relations and in facial morphology<sup>[1]</sup>. It interferes with chewing ability, esthetics, speech ability which hampers the individual's performance and daily activities<sup>[2]</sup>. It affects most of the individuals globally approximately 2.3% of the population (according to 2010)<sup>[3]</sup>. The aim of modern dentistry is to return patient's normal oral health and function in predictable manner. There are various treatment options for rehabilitation of edentulous arches that are complete denture, overdenture, implant retained overdenture, implant supported removable or fixed denture<sup>[4]</sup>. The common reason for dissatisfaction in patients using dentures are pain, discomfort, poor denture stability, difficulties in mastication, difficulties in speech as well as poor retention capability<sup>[5]</sup>. Implant supported prosthesis may not be possible in many conditions because of vicinity of vital anatomical structures (such as maxillary sinus, mandibular nerve), poor bone quality and quantity or severely atrophic jaws. There are many techniques and procedures have been introduced to solve the complex problems associated with treatment of atrophic jaws and to avoid the surrounding vital anatomical structures such as the use of short implants, nerve transpositioning<sup>[6]</sup>, alveolar distraction osteogenesis, use of intraoral and extra oral autogenous bone grafts<sup>[7]</sup>, sinus lifting or ridge augmentation<sup>[8]</sup>, crestal bone expansion technique<sup>[9]</sup>, tilted implants<sup>[10]</sup>, zygomatic implants<sup>[11]</sup>, palatal implants, pterygoid implants<sup>[12]</sup>, etc. The high cost, time and morbidity associated with such approaches have limited their scope and application. As the solution for this, implant technology developed the All on 4 concepts, as an alternative to conventional treatment options of edentulous arches. This treatment concept refers to 'all' teeth being supported 'on four' dental implants. The term "All On" refers to that denture will firmly place on these implants. This concept allows immediate function and avoids regenerative procedures which increase treatment cost and discomfort of the patient as well as the complications associated to these procedures<sup>[13]</sup>.

### All on 4 Dental Treatment

It is modern approach, which allows the rehabilitation of totally edentulous patients with placement of only 4 implants in each jaw. This technique is innovated by Dr. Paulo Malo and Nobel Biocare Company

(2003). In this system, 2 implants are placed in the front of arch and 2 in the back at an intended angle (tilted as 30°-45°), to maximize implant length and avoids anatomical structures. This together forms the required foundation to support the prosthesis. This is graft less, cost effective, less invasive procedure which rehabilitate full arch and have immediate function and high success rates. In this technique, four implants are placed in the anterior region of jaw between the two mental foramina in mandible and between the anterior walls of maxillary sinus in the maxilla<sup>[14]</sup>. When this is used in the mandible, the tilted posterior implants make it possible to achieve good bone anchorage without interfering with mental foramina. In severely resorbed maxillae, tilted implants are also an alternative to sinus floor augmentation<sup>[15]</sup>. It provides replacement of permanent implant retained prosthesis in same day, so it is called “Teeth in 1day” treatment concept.

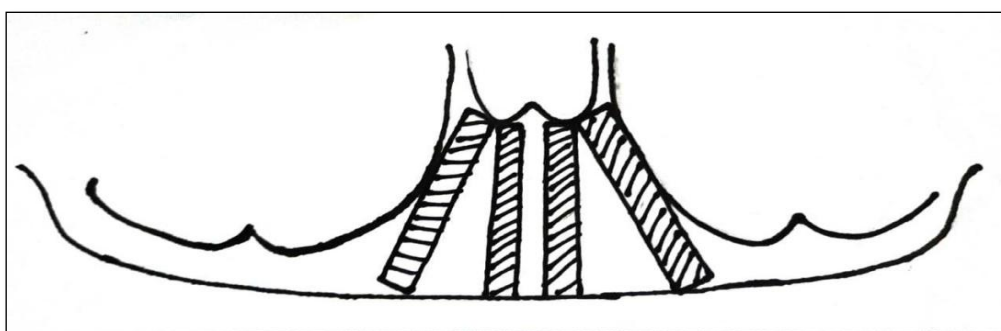


Fig. I Mesial-distal angulation of the implants, permitting longer implants posteriorly<sup>[16]</sup>.

### History of All on 4 Concept

All on 4 is not the invention, but rather a treatment technique that has evolved over time.

-The “All-on-4” technique has originally evolved from the work of Branemark and his colleagues in 1977, where they utilized 4 to 6 vertical implants placed within the anterior segment of the edentulous maxilla and mandible, which are cantilevered to adapt a full-arch fixed prosthesis. Although there is good success from their 10-year study (approximately 80% for the maxilla and 91% for the mandible), the cantilever remains too long and problematic, having to extend and provide adequate posterior dentition<sup>[17-18]</sup>.

- Earlier the All on 4 style concepts can be tracked back by Mattson and colleagues, in 1999 whereby they treated 15 patients (68 implants) with severely resorbed edentulous maxilla by inserting 4 to 6 implants in the maxilla to avoid sinus augmentation. They selected alveolar ridge heights 10 mm or minimum 4 mm in horizontal width and they successfully restored them with fixed prosthesis with 12 teeth supported by framework. They reported only one failed implant with 100% prosthesis stability in a 3-to-4.5-year period<sup>[19]</sup>.

-In 2000, Krekmanov and his colleagues were also able to show posterior tilted implant supported prosthesis. They were also able to demonstrate posterior tilted implant-supported prosthesis was possible, by increasing the anterior-posterior (A-P) spread, shortening of the cantilever, coupled with cross-arch stabilization, the implant/prosthetic outcome would be similar to traditional axial loaded cases. The angulation also provides the chances for placement of longer implants while moving the implant support posteriorly and enhancing load distribution<sup>[20]</sup>.

-This concept of immediate loading was developed, institutionalized and systematically analyzed in the 2003 by dentist Paulo Malo and colleagues in the form of retrospective study in mandible. The results presented were very encouraging, with short-term implant and prosthetic success rates. The data relating to 32 maxillae, for total of 128 implants placed, were later published and reported a cumulative implant survival of 97.6% after 1 year of functional loading<sup>[21]</sup>.

### Steps to identify right patient

A detailed evaluation is necessary in order to choose right treatment and to establish an expected treatment outcome. During the first consultation, possible implant contraindications should be ruled out during the course of the examination. To begin the evaluation following points should be consider<sup>[22-23]</sup>

1. Medical history, chief complaint and patient expectation: Any conditions that may affect the patient’s treatment procedure or outcome should be noted. The patient’s expectations should be recorded.
2. Dental History: History of teeth failure should be noted as well as habits are also recorded including clenching, bruxism, etc.
3. Radiographic Analysis: Radiographic evaluation should be done with the help of panoramic radiograph (OPG), full mouth periapical series (FMX / FMS), CBCT, or medical CT scan, etc. it is needed before the final decision<sup>[24]</sup>.

4. Intra-and Extra oral examination: Hard and Soft tissue evaluation should be done before starting the procedure. Also, occlusion, TMJ should be evaluated.

**Treatment Planning: how to get started**

Treatment planning has to start with patient evaluation. Once this is done, the quality and quantity of bone or available bone zones should evaluate.

- I. **Reviewing the presence or lack of hard and soft tissue** can help to determine the type of final prosthesis needed <sup>[25]</sup>.
- II. **Identification of transition line** can help to determine potential esthetic considerations and needs <sup>[26]</sup>.
  - When planning an implant-supported fixed prosthesis, we should consider smile line. We have ensured that during the patient’s maximum smile, the prosthesis tissue junction (PTJ) should not be visible. This is primarily because of the difficulty to match with precision of the color of the prosthetic gingiva with the natural gingival tissues <sup>[26-27]</sup>.
  - Transition line in green is apical to Smile line in red with esthetic outcome (fig. II)
  - Transition line in green is coronal to smile line in red with a unesthetic outcome (fig. III).

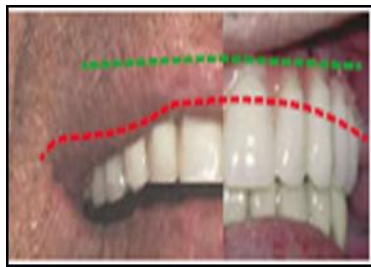

Fig. II

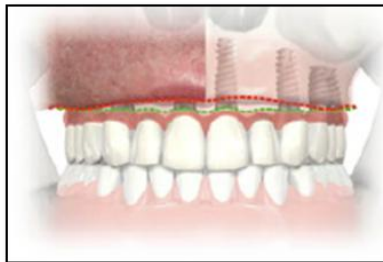


Fig. III

III. **Evaluation of Maxillary Zones:**

It helps to select particular surgical and restorative treatment protocol <sup>[27-28]</sup>.

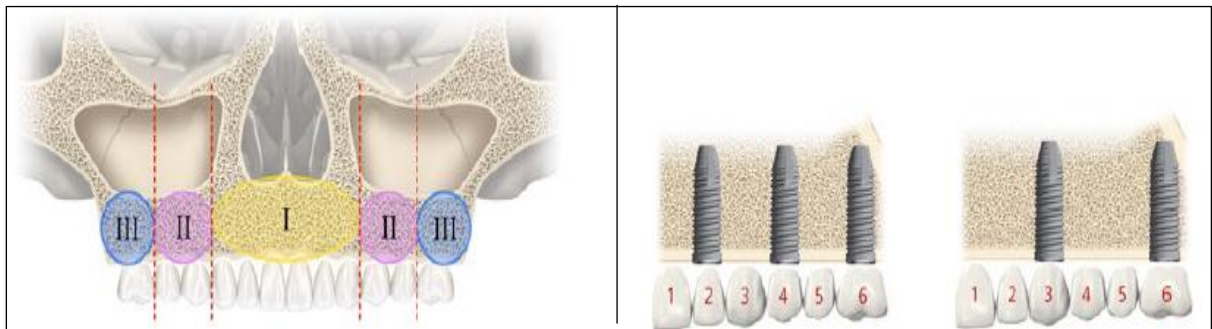


Fig. IV GROUP 1: Presence of bone in zone 1, 2, 3

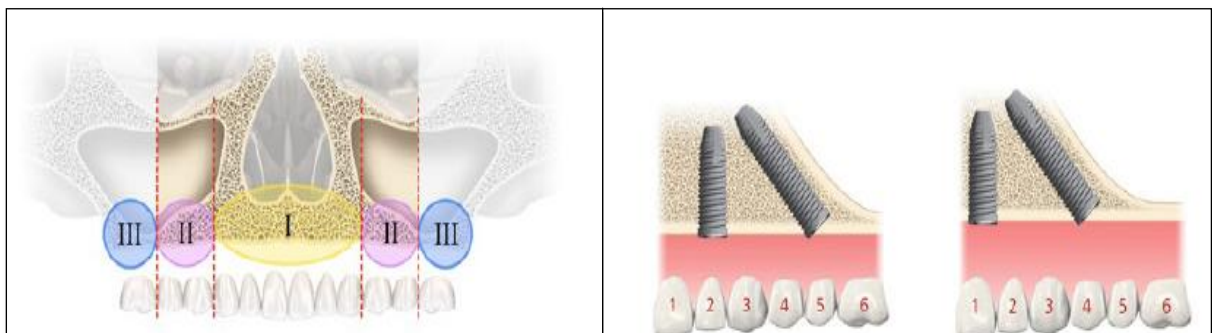


Fig. V GROUP 2: Presence of bone in zone 1 and 2

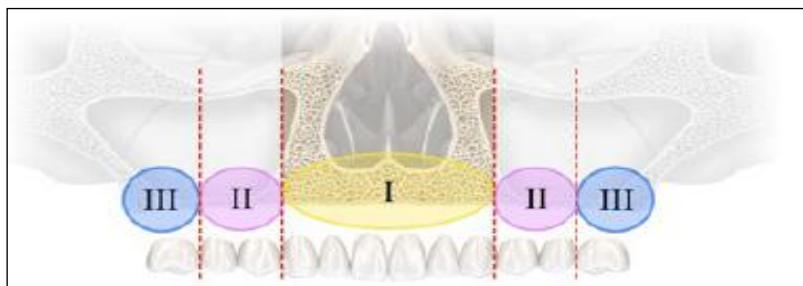


Fig. VI GROUP 3: presence of bone in zone 1 only

-Patients with bone only in zone 1 and 2 could be candidates for the All on 4 treatment concept.

- IV. **Considering the use of 3D software:** It is also recommended for evaluating the potential sites for implant placement using CAD / CAM technology<sup>[29-30]</sup>.

#### General considerations<sup>[31-34]</sup>

- Surgeon should be confident of the ability to achieve primary implant stability (35 to 45 Ncm insertion torque).
- Patient must have no severe parafunctions.
- In edentulous maxilla, Minimum bone width: 5mm  
Minimum bone height: 10mm (canine to canine).
- In edentulous mandible, Minimum bone width: 5mm  
Minimum bone height: 8mm (between the mental foramina).
- To reduce the cantilever, posterior implants can be tilted to a maximum of 45°.
- If the angulation is 30° or more, the tilted implant must be splinted.
- All on 4 treatments does not require wider opening of mouth than other implant procedure, due to angulation of tilted implants.
- If any remaining or ill-fitting teeth require extraction, then the extraction sockets should be cleaned and debrided completely after extraction, and implants should be placed between the extraction sockets into the interdental bone.
- For tilted posterior implants, plan the distal screw access holes to be located at the occlusal face of the 1st molar, 2nd premolar or 1st premolar.

#### Specific considerations – Implants<sup>[31-32]</sup>

- The posterior implants should be 4 or 4.3mm in diameter, if possible.
- Note: The 30 Multiunit Abutment: available for Regular Platform (RP)  
The 17 Multiunit Abutment: available for Narrow Platform (NP) and Regular Platform (RP).
- When placing posterior implants with an internal connection, make sure that one of the tri-channel lobes on the implant is pointing distal or slightly buccal. (fig. VII)

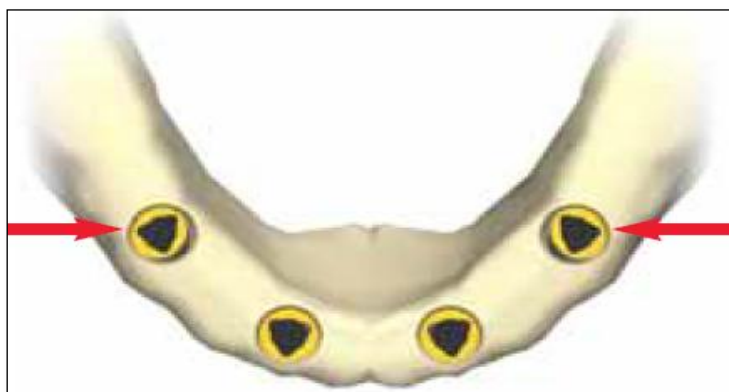

Fig. VII

#### Specific Considerations – Prosthetics<sup>[31-32]</sup>

- Patient's removable prosthesis can be used to fabricate the immediate all acrylic bridge, if it is in good condition.
- For proper esthetics and function, for final bridge should have 12 teeth.

**Surgical procedure of All on 4**

It can be performed in two ways that is with flap or without flap (flapless) [35].

-**With flap:** It is traditional method, uses standardized all on 4 guide for predictable and optimal positioning of implant.

-**Without flap (flapless):** It is modern technology, uses computer-based planning, customized template to correctly drill and position the implant.

**Items required for All on 4 surgical treatments**

**All on 4 guide:**

It guides the placement of implant as all on 4 protocols (fig. VIII).



**Fig. VIII** All On 4 Guide

**Products needed for restorative procedure**

It involves multiunit abutments, prosthetic screws, prosthetic kit, lab components, etc.

**Implants can be used for All on 4 concept** [36]

**Table I:** Types of implants used for All on 4

Parallel Implants	Tapered Implants
<ul style="list-style-type: none"> <li>• NobelSpeedy Groovy</li> <li>• NobelSpeedy Replace</li> <li>• Branemark System Mk III Groovy</li> <li>• NobelReplace Straight Groovy</li> <li>• Branemark System Mk III, TiUnite</li> <li>• Branemark System Mk IV TiUnite</li> <li>• Replace Select Straight</li> </ul>	<ul style="list-style-type: none"> <li>• NobelReplace Tapered Groovy</li> <li>• Replace Select Tapered</li> </ul>

**Checklist Prior to surgery** [37]

- Correct implants, guided components and instruments
- Operation specification
- Surgical template (fig. IX)
- Surgical index
- Prosthetic components and instruments



**Fig. IX** Surgical Template

-For Placing 30° Multi-unit Abutments Non-engaging, the jig construction includes (fig. X):

1. Impression coping open tray multi-unit
2. Guide pin
3. Abutment holder
4. Jig stabilizer
5. 30° multi-unit abutment non-engaging
6. Abutment screw

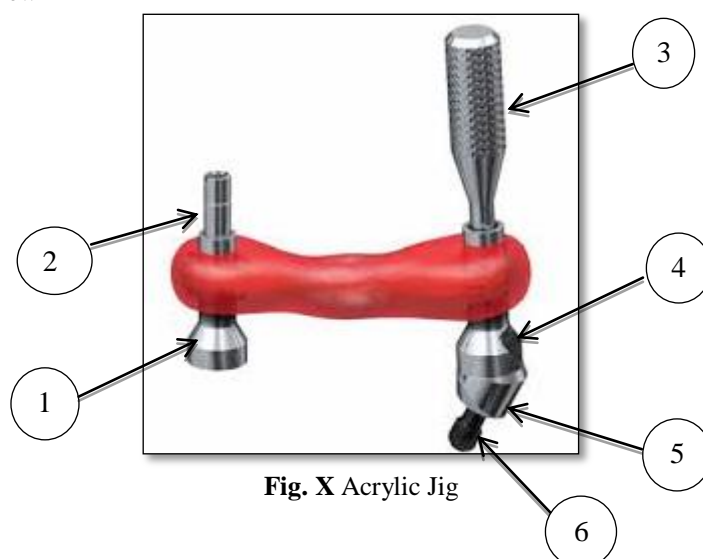


Fig. X Acrylic Jig

### Three phases of All on Four concept:

- Surgical phase
- A-P spread
- Prosthetic phase

### All on 4 standard

After the complete evaluation of medical history, dental history, intra- and extra- oral examination and radiographic analysis, patient's consent should be noted and then proceed towards the treatment. Then pre-operative photographs and impressions are taken and a proper aesthetic planning is performed according to an Edentulous Rehabilitation Planning Protocol. With the placement of removable prosthesis in the mouth, 2 marks are performed in the patients' chin and nose tip using a surgical marker. The distance between these 2 marks represents the reference point that allows maintaining or increasing the vertical dimension when the immediate bridge is placed. Surgical procedures for both jaws should be performed under local anesthesia with sedation. Antibiotics should be given 1 h before surgery and daily for 6 days thereafter. Prednisolone should be administered from the day of surgery until 4 days postoperatively in tapering manner. Analgesics should be given for 4 days and then just if needed.

### All on 4 treatment using Flap Approach (Traditional Approach) <sup>[38-50]</sup>

In this, implants and abutments are placed in one position at a time, in posterior region. The tilted implant placement is assisted by a special guide, (Edentulous guide / All On 4 Guide, Nobel Biocare) at an intended angle (30°-45°). The All on 4 guide is placed into a 2mm osteotomy made at the midline of the jaw and the titanium band is contoured to follow the arc of the opposing jaw. With this guide, the implants are placed in center of the opposing prosthesis. The insertion of the implants follows standard procedures (except that under-preparation is used to get a final torque of over 30 Ncm before the final seating of the implant). The preparation is typically done by full drill depth with a 2mm twist drill, followed by a widening of the entrance in the cortical bone with step drills, depending on bone density and implant diameter. The implant neck is aimed positioned at bone level, and bicortical anchorage is established whenever possible. The implants length varies from 10 mm to 18 mm. In case of immediate extraction, the socket of extracted teeth should be thoroughly cleaned and debrided to decrease the risk of infection and implants are placed in between interradiacal bone of extracted teeth. Depending on the degree of irregularity of the alveolar ridge, recontouring can be accomplished with a



rounger or any other device. After profuse irrigation, the edges of flaps can be trimmed to remove excess tissue and then sutured.

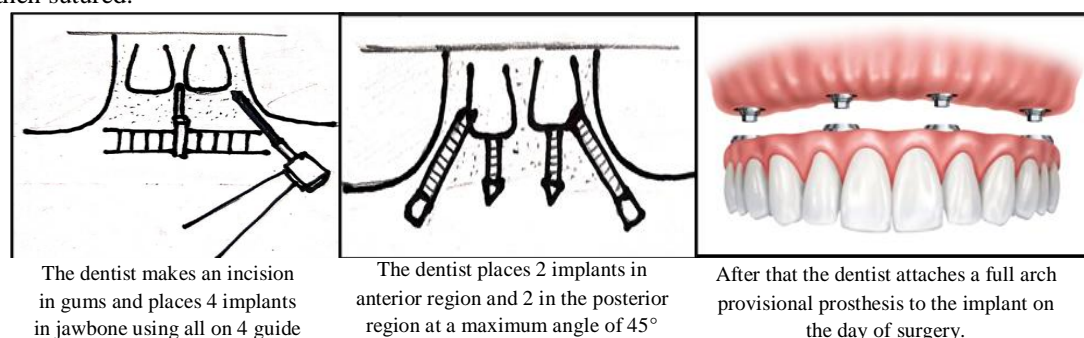


Fig. XI Placement of All on 4 dental implants using All on 4 Guide.

### Implant placement in the mandible <sup>[38-50]</sup>

In the mandible, a mucoperiosteal flap is raised along the top of the ridge in the area between two mental foramina without vertical-releasing incisions, to avoid damaging the mental nerve. In extremely atrophic mandibles, the mental foramina are superficial; in this a vertical-releasing incision is made at the midline allowing proper flap reflection and for easy mental nerve identification. Two distal implants are inserted just mesial to the mental foramina and the loop of the mental nerve. These fixtures are tilted distally about 30 degrees relative to the occlusal plane. These posterior implants typically emerge at the second premolar position. The additional two most anterior implants follow the jaw anatomy, which in severe resorption cases means a posterior tilting. The posterior implants should be of 4mm diameter, while the anterior ones can be 3.3mm in diameter. Straight and Angulated abutments (Multi-unit, Nobel Biocare AB) are used. The angle is either 17° or straight at the anterior implants and always 30°- 45° at the posterior implants. These abutment angulations are chosen in order to ensure that the prosthetic set screw access holes are in an occlusal or lingual location. To obtain a hygienic and mechanically resistant prosthesis the 4 abutments should be at the same height.

### Implant placement in the maxilla <sup>[38-50]</sup>

In the maxilla, a mucoperiosteal flap is raised along the top of the ridge with two relieving incisions performed on the buccal aspect in the molar area. A small window is done to the sinus using a round bur to identify the exact position of the anterior sinus wall. The tilted posterior implant allows shift of position on the implant head from a vertically placed implant in the canine or first premolar region to a tilted implant in the second pre-molar or first molar region, following the anterior/ mesial sinus wall with about inclination of 45°. For correcting the inclination to a maximum of 15°, 30° angulated abutments placed on the implant. The posterior implants are 4-4.3 mm in diameter. By replacing the edentulous guide, the anterior implants are oriented vertically by a guide pin. Care needs to be taken in the selection of the anterior positions not to come in conflict with the apex of the tilted posterior implants, which normally reach the canine area. The anterior implants can be 3.3 mm in diameter and typically placed in lateral or central incisor positions.

### Immediate prosthetic procedures <sup>[38-50]</sup>

On the day of surgery, the provisional complete arch all acrylic prosthesis is delivered. A pre-made open impression tray is used. After suturing, the open tray impression copings are screwed and connected with a metal bar and acrylic resin stabilizing the copings positions between each other. An accurate cast model is achieved thus accomplishing a prosthetic passive fit. Before placing complete filling with soft putty, small volumes of putty soft silicon are placed around the copings. Lighter impression materials are not used since they enter through the suture and can cause post-operative infections. After removing the copings, protection caps are placed to support the peri-implant mucosa during the manufacturing of the prosthesis. High-density baked all-acrylic prosthesis with titanium cylinders is manufactured at the laboratory, based on the impression and mostly delivered to the patient within 2-3 hours. The provisional prosthesis should not have more than one cantilever tooth and hence the number of immediate teeth varies from 10 to 12, depending on the degree of resorption (so the final prosthesis may have two cantilever teeth).

### Flapless Approach for All on treatment concept <sup>[38-50]</sup> (Modern Approach)

The position of the implants is the same as for the flap procedure but fixture delivery is guided with a surgical template (Nobel Guide, Nobel Biocare) based on a computer planning made in a 3D model of the

patient jaw, that is obtained from the axial cuts of a Ct-Scan. A pre-surgery prepared prosthesis is immediately delivered after surgery. Since no flap is reflected the postoperative period is more comfortable with less edema. This advantage can also be important in patients under anticoagulants therapies or with hemostatic disorders. However, the flapless approach has particular inclusion criteria, namely: good mouth opening capability, absence of teeth interfering with surgical template placement and no osteotomy or bone trimming needed.

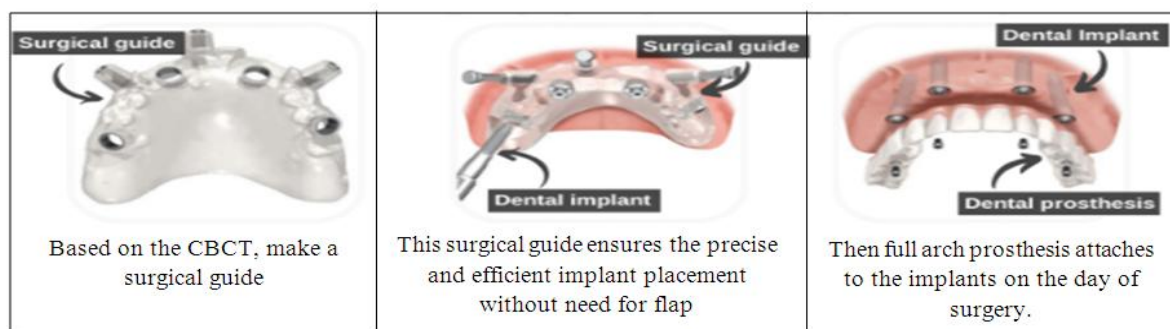


Fig. XII Placement of All on 4 dental implants using surgical guide.

### Final Prosthetic protocols <sup>[38-50]</sup>

The final prosthesis should be delivered after 4 to 6 months of surgery. If an adjustment of the angulated abutment is needed for better positioning of the screw access hole, the impression for the final prosthesis is taken at implant level. The abutment position is then decided at the laboratory and adjusted in the patient's mouth. For final impression, a combination of light and putty soft addition silicones is used. The prosthetic-mucosal interface should be compact, and it should be planed so that it somewhat pressures the soft tissues. In the area relating with the soft tissue, the prosthesis should have a convex configuration and, as the rest of the prosthetic structure, highly polished. The cantilevers are avoided and the occlusal contacts should be stronger within anterior teeth, in the immediate bridge. Canine and anterior guidance are preferred. The final prosthesis occlusion is adjusted according to the criteria of dentate individuals.

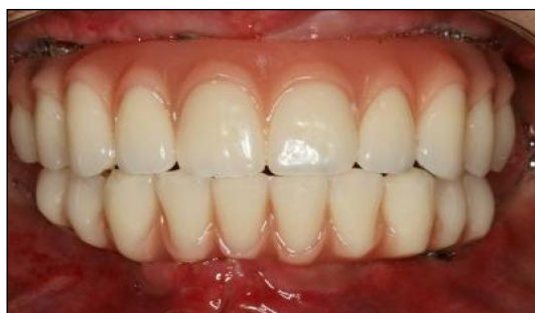

Fig. XIII Final prosthesis is adjusted on implants

### A-P Spread <sup>[51-52]</sup>

Rangert provides guidelines for controlling occlusal loads on implants and prosthetic reconstruction i.e., an A-P spread (distribution distance between the center of most anterior implant and distal position of most posterior implants) of 10 mm was proposed for a cantilever of 15- 20 mm ( $1.5 / 2 \times \text{A-P-spread}$ ) for mandibular ISFPs English proposed a rule of thumb for determining posterior cantilever in mandibular ISFPs should be 1.5 times A-P-spread. According to English, this allows a 10-12 mm posterior cantilever for the mandible, whereas due low bone density maxillary ISFP posterior cantilever should be reduced to 6-8mm.

### Occlusal Scheme <sup>[53-55]</sup>

Many implant failures can be charged to improper occlusal design which can focus on the stresses in the bone and lead to rapid bone resorption. The goal of any prosthetic procedure should include the foundation of a functional occlusion.

Basic requirements of occlusal scheme of implant-prosthetic framework are:

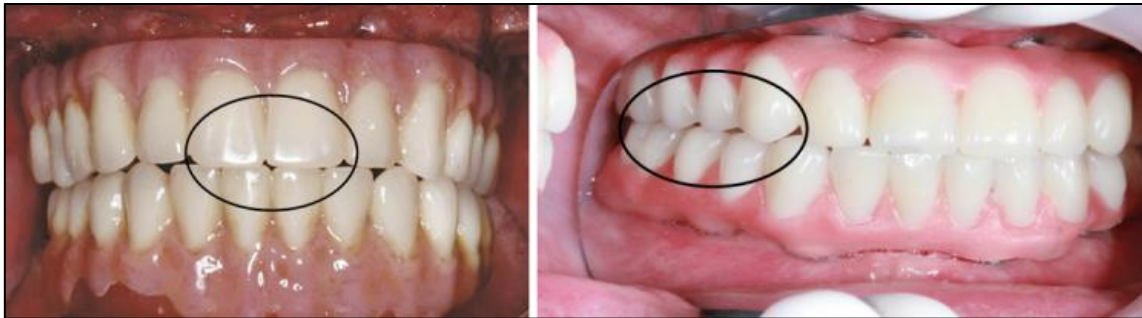1. Establishment of stable jaw relationships with maximum intercuspal contacts those are bilaterally identical.



2. Establishment of “freedom in centric”.
3. Elimination of any obstructions between the maximum intercuspal and retruded contact positions.

Occlusal scheme for immediate loading of implant and along with prosthesis:

- Avoid or minimize length of cantilever.
- Simultaneous bilateral contact points on all teeth, excluding teeth which are distal to implant emergence.
- In lateral movements, group function should be with flat linear pathways and with minimal vertical superimposition excluding teeth in cantilever.
- In protrusive movements, guidance divided on all anterior teeth.



**Fig. XIV** Simultaneous bilateral point contacts on canine and posterior teeth and grazing contacts on incisors.

**Limitation of All on 4 treatment concept** <sup>[56]</sup>

1. Good general health and acceptable oral hygiene.
2. Sufficient bone for 4 implants of at least 10mm in length.
3. Implants attain sufficient stability for immediate function.

**Advantages and Disadvantages of All on 4 treatment concept** <sup>[56-57]</sup>

**Table II:** Advantages and Disadvantages of all on 4

Advantages	Disadvantages
1. Angled posterior implants • Avoid anatomical structures. • Allow longer implants fixed in better quality bone • Reduces posterior cantilever 2. Avoids complex surgery 3. Less invasive procedure for patient 4. Simplified surgical and prosthetic procedure 5. Implants well-spaced, good biomechanics, easier to clean, immediate function and esthetics 6. High success rate 7. Reduced cost due to less number of implants and avoidance of grafting in majority of cases.	1. Length of cantilever in the prosthesis can't be extended beyond the limit. 2. Implant placement is completely prosthetically driven, as Free hand arbitrary surgical placement of implant is not always possible. 3. It is very technique sensitive procedure and it requires complex presurgical preparation such as CAD/CAM, surgical splint. 4. Not suitable where bone volume is limited. 5. Not ideal for patients with severe parafunction. 6. Not ideal for skeletal class II and III maxillomandibular relationships.

**Contraindications All on treatment concept** <sup>[58]</sup>

**Table III:** Contraindications of All on 4

<ul style="list-style-type: none"> <li>- Acute infectious disease</li> <li>- Chemotherapy</li> <li>- Systemic bisphosphonate medication (≥2yr) – induces risk of bisphosphonate- induced osteonecrosis (BON)</li> <li>- Renal osteodystrophy– increased risk for infection, reduced bone density</li> <li>- Severe psychosis</li> <li>- Depression</li> <li>- Pregnancy</li> <li>- Unfinished cranial growth with incomplete tooth eruption</li> </ul>	<ul style="list-style-type: none"> <li>- Pathologic findings at the oral soft- and/or hard tissues</li> <li>- Post head and neck radiation therapy– reduced bone remodeling, risk of osteoradionecrosis</li> <li>- Osteoporosis – reduced bone to implant contact</li> <li>- Uncontrolled diabetes– eventually wound healing problems</li> <li>- Status post chemotherapy, immuno- suppressants or steroid long- term medication, HIV infection</li> <li>- Alcohol and drug abuse, heavy smoking</li> <li>- History of aggressive periodontitis</li> </ul>
--	--

**Implant survival and prosthetic complications of immediate loading all-on-four** <sup>[59-60]</sup>

**Table IV:** Implant survival and prosthetic complications of immediate loading all-on-four

Author / Year	Location	Patients	Implants	Follow up in months	Survival rates %	Prosthetic complications
Capelli et al. (2007)	Both	65	342	36	97.6	NR
Francetti et al. (2008)	Mandible	68	248	60	100	Prosthesis fracture 7/68
Agliardi et al. (2010)	Both	173	692	60	98	Prosthesis fracture 24/173
Maló et al. (2011)	Both	245	980	120	93.8	Screw loosening 12/245 Prosthetic teeth wear 1/245
Cavalli et al. (2012)	Maxilla	34	136	12-73	100	Prosthetic teeth fracture temporary 20.6% definitive 17.7%
Francetti et al. (2012)	Both	47	196	60	100	No
Maló et al. (2012)	Maxilla	242	968	60	98	Fracture or loosening of mechanical and prosthetic components
Babbush et al. (2013)	Both	NR	227	36	98.7	NR
Di et al. (2013)	Both	69	344	12-56	96.2	Change fixed prosthesis for overdenture 3/69
Balshi et al. (2014)	Both	152	800	60	97.5	NR
Browaeys et al. (2015)	Both	20	80	36	100	No
Lopes et al. (2015)	Both	23	92	60	96.6	Prosthesis fracture 7/23 Screw loosening 2/23
Maló et al. (2015)	Both	110	440	60	95.5	-
Babbush et al. (2016)	Both	169	856	36	99.8	No
Sannino and Barlattani (2016)	Mandible	85	340	36	98.5	No
Tallarico et al. (2016)	Both	56	224	84	98.2	-
Niedermaier et al. (2017)	Both	NR	2081	84	97	NR

**All On Four Dental Implant treatment Failures**

**Biologic Complications** <sup>[61-63]</sup>

It includes soft tissue dehiscence, peri-implant bone loss, peri-implant mucositis, inflammation under the fixed prosthesis, hypertrophy/hyperplasia of soft tissue, etc.

**Technical Complications** <sup>[61-63]</sup>

It includes screw loosening, screw fracture, veneering material fracture, wear or total replacement of acrylic resin teeth, framework fracture, loss of screw access filling material, fracture of the opposing restoration, fracture of implant fixture, conversion of an implant-supported fixed complete dental prosthesis to complete denture or overdenture and patient dissatisfaction, etc.

**II. Conclusion**

The all on 4 seems to be alternative option for rehabilitating edentulous jaws compared with advanced surgical approaches without using removable prostheses. These are cost effective procedures, decreasing the treatment times, the morbidity of patients. The rehabilitation of completely edentulous resorbed jaws by placement of implants using all on 4 concept gives a new hope for appreciable success, using modern technology. So, it is easy to rid uncomfortable dentures, and by using this give a big smile to the rest of life. So, say goodbye to multiple visits and hello to same day dentistry.

**III. References**

- [1]. Sutton Dn, Lewis Br, Patel M, Et Al. Changes in facial form relative to progressive atrophy of the edentulous jaws. *Int J Oral Maxillofac Surg.* 2004; 33:676–82.
- [2]. Sk Shabana Begum, V Chandra Sekhara Reddy, R.V.S. Krishna Kumar, Km Sudhir, G Srinivasulu, Sk Noushad Ali. Tooth loss prevalence and risk indicators among adult people visiting community health centers in Nellore district, Andhra Pradesh: a cross sectional study. Doi: 10.4103/2319-593.195829
- [3]. Emami, E., De Souza, R. F., Kabawat, M., & Feine, J. S. The impact of edentulism on oral and general health. *International Journal of Dentistry*, 2013, 498305. Doi:10.1155/2013/498305

- [4]. Prithviraj D R, Gupta A. Full-mouth rehabilitation of completely edentulous patient using implant-supported fixed prosthesis. *J Indian Prosthodont Soc.* 2008; 8:44-7
- [5]. J. Sarangapany, common faults in complete dentures: a review; August 1993- *Quintessence International* 24(7):483-7
- [6]. Ali Hassani, Mohammad Hosein Kalantar Motamedi And Sarang Saadat. Inferior alveolar nerve transpositioning for implant placement, a textbook of advanced oral and maxillofacial surgery. (2013) Doi: 10.5772/52317.
- [7]. Elena Calciolari, Aliye Akcali, Nikolaos Donos, the role of osteopromotive membranes in guided bone regeneration, bone augmentation by anatomical region, (2020) 10.1002/9781119427926, (69-93).
- [8]. Shalu Chandna Bathla, Ramesh Ram Fry, Komal Majumdar. *J Indian Soc Periodontol.* 2018 Nov-Dec; 22(6): 468–473. Doi: 10.4103/Jisp.Jisp\_236\_18pmcid: Pmc6305100
- [9]. Jensen Ot, Cullum Dr, Baer D. Marginal bone stability using 3 different flap approaches for alveolar split expansion for dental implants—a 1-year clinical study. *J Oral Maxillofac Surg.* 2009; 67:1921–30.
- [10]. Testori T, Galli F, Fumagalli L, Et Al. Assessment of long-term survival of immediately loaded tilted implants supporting a maxillary full-arch fixed prosthesis. *Int J Oral Maxillofac Implants.* 2017; 32:904–11
- [11]. Branemark Pi, Grondahl K, Ohnrel Lo, Et Al. Zygoma fixture in the management of advanced atrophy of the maxilla: technique and longterm results. *Scand J Plast Reconstr Surg Hand Surg.* 2004; 38:70–85
- [12]. Candel E, Peñarrocha D, Peñarrocha M. Rehabilitation of the atrophic posterior maxilla with pterygoid implants: a review. *J Oral Implantol.* 2012; 38:461–6.
- [13]. Soto-Peñaloza D, Zaragoza-Alonso R, Peñarrocha-Diago M, Peñarrocha-Diago M. The all-on-four treatment concept: systematic review. *J Clin Exp Dent.* 2017;9: E474–88.
- [14]. Maló P, Rangert B, De Araújo, Nobre M. “All-on-four” immediate-function concept with brånemark system® implants for completely edentulous mandibles: a retrospective clinical study. *Clin Implant Dent Relat Res* 2003; 5(Suppl 1): 2-9
- [15]. Christopher Ck Ho, Grad.Dip.Clin.Dent, M.Clin. Dental implant rehabilitation in the edentulous jaw: the “ALL-ON-4” immediate function concept textbook 2012, page138-48
- [16]. Mattsson T, Konsell P, Gynther G, Et Al. Implant treatment without bone grafting in severely resorbed edentulous maxillae. *J Oral Maxillofac Surg* 1999; 57:282.
- [17]. Shakhawan M Ali, Zanyar M Amin, Rebwar A Hama, Hawbash O Muhamed, Rozhyna P Kamal And Payman Kh Mahmud. All on 4 treatment concept in dental implants: a review articles. March 2019; 10.32474
- [18]. Branemark Pi, Hannsson Bo, Adell R, Et Al. Osseointegrated implant in treatment of the edentulous jaw. Experience from A 10-Year Period. *Scand J Plast Reconstr Surg Suppl* 1977; 12:1–132
- [19]. Krekmanov L, Khan M, Rangert B, Et Al. Tilting of posterior mandibular and maxillary implants for improved prosthesis support. *Int J Oral Maxillofac Implants* 2000; 15:405–14.
- [20]. Mattsson T, Konsell P, Gynther G, Et Al. Implant treatment without bone grafting in severely resorbed edentulous maxillae. *J Oral Maxillofac Surg* 1999; 57:281–7.
- [21]. Tiziano Testori, Fabio Galli, Massimo Del Fabro. Immediate loading: a new era in oral implantology textbook, chpt.8
- [22]. How you can start with the all on 4 treatment concept nobel biocare booklet 2016: pg11
- [23]. Nu Zitzmann, Md Margolin, A Filippi, R Weiger, G Krastl. Patient assessment and diagnosis in implant treatment. May 2008: Doi:10.1111/J.1834-7819.2008.00036.X
- [24]. Sarika Gupta, Neelkant Patil, Jitender Solanki, Ravinder Singh, Sanjeev Laller. Oral implant imaging: a review. *Malays J Med Sci.* 2015 May-Jun; 22(3): 7–17. Pmcid: Pmc4681716
- [25]. Edward J, George Jm, Prakash Dg. Evaluation of peri-implant soft tissues and hard tissues in titanium implants in immediate and delayed cases: a comparative study. *J Dent Implant* 2017; 7:3-10
- [26]. Dr Binam Sapkota, Dr Shatakshi Srivastava, Dr Sushmit Koju, Dr Ritesh Srii. Evaluation of smile line in natural and forced smile position: an institution-based study. June 2017 *orthodontic Journal of Nepal* 7(1):27-32 Doi: 10.3126/Ojn.V7i1.18898
- [27]. How you can start with the all on 4 treatment concept nobel biocare booklet 2016: pg12
- [28]. How you can start with the all on 4 treatment concept nobel biocare 2016 booklet: pg16
- [29]. A. S. Bidra, “Technique for systematic bone reduction for fixed implant-supported prosthesis in the edentulous maxilla,” *Journal Of Prosthetic Dentistry*, Vol. 113, No. 6, Pp. 520–523, 2015.
- [30]. Thiago De Almeida, Prado Naves Carneiro. Digital technology in implant dentistry. Dec 2015
- [31]. Pankaj P. Singh, A.Norman Crainin. Atlas of oral implantology textbook 3rd edition; pg275
- [32]. Dr Paulo Malo. The all on 4 and all on 4 with nobelguide clinical solution booklet 2003; pg7
- [33]. Taruna M, Chittaranjan B, Sudheer N, Tella S, Abusaad M. Prosthodontic perspective to all-on-4® concept for dental implants. *J Clin Diagn Res.* 2014;8(10): Ze16-Ze19. Doi:10.7860/Jcdr/2014/9648.5020
- [34]. B. Anandh, B.Lokesh, Vijay Ebenezer, S.Jimson And J.Parthiban. All on four - the basics. *Biomedical & Pharmacology Journal* Sept 2015; Doi: 10.13005/Bpj/756
- [35]. Dr Paulo Malo. The all on 4 and all on 4 with nobelguide clinical solution booklet 2003 pg 4
- [36]. Pankaj P. Singh, A.Norman Crainin. Atlas of oral implantology textbook 3rd edition; pg275
- [37]. Dr Paulo Malo. The all on 4 and all on 4 with nobelguide clinical solution booklet 2003; pg16
- [38]. Paulo Malo, Isabel Lopes, Miguel De Araújo Nobre. Chapter 27: the all-on-4 concept march 2010
- [39]. Mukherjee S, Banerjee S, Chatterjee D, Deb S, Swamy Sn, Mukherjee A. All-on-four concept in dental implants. *Int J Oral Care Res* 2018;6(2): S77-79.
- [40]. M.Taruna, B.Chittaranjan, N.Sudheer, Suchita Tella, Md.Abusaad. Prosthodontic perspective to all-on-4® concept for dental implants. October 2014 *Journal Of Clinical And Diagnostic Research* 8(10):Ze16-Ze19 Doi: 10.7860/Jcdr/2014/9648.5020
- [41]. David Soto-Penaloza, Regino Zaragoza-Alonso, María Penarrocha-Diago, Miguel Penarrocha-Diago. *J Clin Exp Dent.* 2017 Mar; 9(3): E474–E488. Published Online 2017 Mar 1. Doi: 10.4317/Jced.53613 Pmcid: Pmc5347302
- [42]. Shakhawan M Ali, Zanyar M Amin, Rebwar A Hama, Hawbash O Muhamed, Rozhyna P Kamal And Payman Kh Mahmud. All-on-four treatment concept in dental implants: a review article. March 2019
- [43]. David Soto-Peñaloza, Regino Zaragoza-Alonso, María Peñarrocha-Diago, Miguel Peñarrocha-Diago. The all-on-four treatment concept: systematic review. March 2017 *Journal Of Clinical and Experimental Dentistry* 9(3) Doi: 10.4317/Jced.53613
- [44]. Charles A. Babbush, Ali Kanawati, John Brokloff. A new approach to the all-on-four treatment concept using narrow platform nonbelaective implants. *J Oral Implantol* (2013) 39 (3): 314–325 Doi:10.1563/Aaid-Joi-D-12-00223
- [45]. Balshi Tj, Wolfinger Gj, Schlauch Rw, Balshi Sf. A retrospective analysis of 800 branemark system implants following the all-on-four protocol. *J Prosthodont* 2014;23(2):83-8.
- [46]. Durkan R, Oyar P. All-on-four concept in implant dentistry: a literature review. (2017) *J Dent Oral Care Med* 3(2): 205. Doi: 10.15744/2454-3276.3.205. Doi: 10.15744/2454-3276.3.205

- [47]. Michael H. Chan, Curtis Holmes. Contemporary “all-on-4” concept textbook, pg 421
- [48]. Pankaj P. Singh, A.Norman Crainin. Atlas of oral implantology 3rd edition textbook, Pg275-281
- [49]. Miguel Peñarrocha-Diago, Ugo Covani, Luis Cuadrado. Atlas of immediate dental implant loading textbook, pg 213-236
- [50]. Paulo Maló, Bo Rangert, Mecheng Miguel Nobre. “All-on-four” immediate-function concept with brånemark system® implants for completely edentulous mandibles: a retrospective clinical study. Doi:10.1111/J.1708-8208.2003.Tb00010.X
- [51]. M.Taruna, B.Chittaranjan, N.Sudheer, Suchita Tella, Md.Abusaad. Prosthodontic perspective to all-on-4® concept for dental implants October 2014. Journal Of Clinical And Diagnostic Research 8(10): Ze16-Ze19 Doi: 10.7860/Jcdr/2014/9648.5020
- [52]. Purcell Ba, Mcglumphy Ea, Yilmaz B, Holloway Ja, Beck Fm. Anteroposterior spread and cantilever length in mandibular metal-resin implant-fixed complete dental prostheses: a 7- to 9-year analysis. Int J Prosthodont. 2015 Sep-Oct;28(5):512-8. Doi: 10.11
- [53]. Verma M, Nanda A, Sood A. Principles of occlusion in implant dentistry. J Int Clin Dent Res Organ 2015;7, Suppl S1:27-33607/Ijp.4172. Pmid: 26340012.
- [54]. Parekh Rb, Shetty O, Tabassum R. Occlusion in implant prosthodontics. J Dent Implant 2013; 3:153-6
- [55]. M.Taruna, B.Chittaranjan, N.Sudheer, Suchita Tella, Md.Abusaad. Prosthodontic perspective to all-on-4® concept for dental implants. October 2014 journal Of Clinical And Diagnostic Research 8(10):Ze16-Ze19 Doi: 10.7860/Jcdr/2014/9648.5020
- [56]. Shakhawan M Ali, Zanyar M Amin, Rebwar A Hama, Hawbash O Muhamed, Rozhyana P Kamal And Payman Kh Mahmud. All-on-four treatment concept in dental implants: a review articles March 2019
- [57]. Amit Punj, Sameh K. El-Ebrashi, And Jeffrey M. Burstein. Dental implant care using the all-on-four concept, March 2020
- [58]. Nu Zitzmann, Md Margolin, A Filippi, R Weiger, G Krastl. Patient assessment and diagnosis in implant treatment May 2008: Doi:10.1111/J.1834-7819.2008.00036.X
- [59]. Miguel Peñarrocha-Diago, Ugo Covani, Luis Cuadrado. Atlas of immediate dental implant loading textbook, pg 215
- [60]. Durkan R, Oyar P. All-on-four concept in implant dentistry: a literature review 2017. J Dent Oral Care Med 3(2): 205. Doi: 10.15744/2454-3276.3.205. Doi: 10.15744/2454-3276.3.205
- [61]. Carlos Parra and Stephen K. Harrel. Treatment planning strategies for dental implant procedures, August 2019
- [62]. Chee, W., Jivraj, S. Failures in implant dentistry. Br Dent J 202, 123–129 (2007). Doi:10.1038/Bdj.2007.74
- [63]. Dan Holtzclaw. All-on-4® implant treatment: common pitfalls and methods to overcome them. July 2016 the Compendium of Continuing Education In Dentistry 37(7):458-465

Dr. Shreya H. Mantri, et. al. "The New Alternative to Conventional Dentures- All On 4 Dental Implant Treatment Concept: A Review Article." *IOSR Journal of Dental and Medical Sciences (IOSR-JDMS)*, 20(03), 2021, pp. 26-37.