

## Functional Outcome of Stand Alone Cage In Cervical Disc Degeneration – A Prospective Follow –Up Study

Dr.H.S Chandrashekar<sup>1</sup>, Dr.Mohan N S<sup>2</sup>, Dr.Arjun Kumar<sup>3</sup>

<sup>1\*</sup>Director of Sanjay Gandhi institute of Orthopaedic and trauma, Bangalore.

<sup>2</sup> Associate Professor, Department of Orthopaedics, Sanjay Gandhi institute of orthopaedic and trauma, Bangalore.

<sup>3</sup> Junior resident, Department of Orthopaedics, Sanjay Gandhi institute of orthopaedic and trauma, Bangalore.  
Corresponding author-Dr.Ashwin S

Junior resident, Department of Orthopedics, Sanjay Gandhi Institute of Orthopedics and trauma, Bangalore.

---

### Abstract

**Introduction:** Age-related cervical degeneration is evident in over 50% of the middle-aged population and is the most common cause of neural dysfunction. Cervical spine anteriorly stabilised by use of anterior cervical plate, strut graft, standalone cage or combination to maintain curvature and facilitate arthrodesis. Standalone strut graft has high rate of complications such as graft subsidence, dislodgement, non-union and donor site morbidities. Anterior plating has inherent deficiencies like plate loosening, screw pull out, breakage, trachea-oesophageal irritation, has increased operation time. Intervertebral cages avoid some of these difficulties due to their self-fixing construct, ability to contain graft or graft substitute in it. The aim of this study is to compare the clinical and radiological outcome of stand-alone cage in single level anterior cervical discectomy and fusion used to treat cervical degenerative disc disease.

**Materials and Methods:** We performed a prospective study of 30 patients treated with stand-alone -cage in single level cervical disc disease. The clinical and radiological outcomes were evaluated which includes visual analogue scale, Japanese orthopaedic association score, neck disability index, neurological status, Cobb's angle, fusion and subsidence. Through Smith-Robinson approach ACDF was done. Patients were assessed up. There is a significant improvement of symptoms reflected by VAS score for pain and functional scores like JOA and NDI. Bony fusion was achieved in 29 patients with a rate of 96.7%.

**Results:** Cervical spine alignment was restored in all patients with kyphosis occurring in 23.3% of patients. Cage subsidence rate was 26.7% with majority occurring in C5-6 level. Anterior cervical discectomy and interbody fusion using stand alone cervical cages can be considered a safe and equally efficient alternative to iliac crest auto graft and anterior cervical plating by providing adequate stability. Stand-alone cage can restore physiologic disc height, provide immediate load bearing support to the anterior column and facilitate arthrodesis.

**Conclusion:** ACDF with stand-alone cages was associated with relatively good clinical and radiologic long-term results. Anterior cervical discectomy and interbody fusion using standalone cervical cages can be considered a safe and effective technique to cure cervical disc herniation with intractable pain or neural deficit in cases where conservative treatment failed. It reliably alleviates cervical degenerative radiculopathy by attaining adequate interbody fusion. It is a safe and equally efficient alternative to iliac crest autograft and anterior cervical plating by providing adequate stability.

**Keywords:** anterior cervical discectomy and fusion, Japanese orthopaedic association

---

### I. Introduction

Spondylosis refers to these age-related degenerative changes within the spinal column. Although the majority of cases are asymptomatic, changes such as disc herniation, osteophyte formation, and hypertrophied ligaments may compress the cervical nerve root to result in neck pain, radiculopathy, or myelopathy.<sup>1</sup> Several procedures have been described for the treatment of disc herniation and cervical spondylosis when conservative treatment fails, including anterior decompression, laminectomy, laminoplasty and instrumented anterior and posterior fusion by plates or screws. After anterior cervical discectomy, intervertebral fusion can be facilitated by using autograft (Iliac crest, fibula), allograft or bone graft substitutes.

Standalone strut graft has high rate of complications such as graft subsidence, dislodgement, non-union and donor site morbidities. Anterior plating has inherent deficiencies like plate loosening, screw pullout, breakage, trachea-oesophageal irritation has increased operation time.<sup>2, 3</sup> Intervertebral cages have been postulated to avoid some of these difficulties due to their self-fixing construct, ability to contain graft or graft substitute in it. Stand-alone interbody fusion cages represent an alternative for anterior cervical fusion in the treatment of cervical degenerative disc disease.

The reason for development of similar fusion device was the avoidance of complications arising from the use of autologous bone graft. Cage-assisted anterior cervical discectomy and fusion (ACDF) has proven to be a safe and effective procedure in available studies. Clinical outcomes have been encouraging in one- and two-level procedures [4-9] and reliability was shown even in three- and four-level surgeries [10]. Cervical intervertebral disc replacement by means of stand-alone cage can restore physiologic disc height, provide immediate load bearing support to the anterior column [11] and may facilitate arthrodesis.

## **II. Aims And Objectives Of The Study**

To find out short term clinical and radiological outcomes in patients with cervical disc disease.

## **III. Materials And Methods**

### **Sampling Area**

The study was carried out at Sanjay Gandhi Institute of Orthopedics and Trauma, Bangalore. The study ranged over a period of one year.

### **Sampling Size**

During the course of this study, thirty patients have been evaluated prospectively. Out of the total 30 patients, 16 were male and 14 were female. Their ages ranged from a minimum of 55 years to a maximum of 73 years. The average follow up is of about one year.

### **Inclusion Criteria**

All patients who have degenerative changes in cervical spine who underwent single level stand-alone cage fixation surgery.

### **Exclusion criteria**

Patients, otherwise meeting the inclusion criteria, were ineligible in case of any of the following criteria

1. Patients sustaining trauma.
2. had an earlier operation for cervical disease.
3. Another specific spinal disorder, e.g., ankylosing spondylitis, neoplasm or metabolic diseases.
4. Neurologic disease causing impaired function of the lower limbs, including diabetic neuropathy.
5. Psychiatric disorders.
6. Poor General Condition.

### **Sampling Method**

Most of the patients were those who were being managed on routine out-patient department (OPD) for a long term using conservative treatment modalities but without significant benefit. Presenting symptoms included (a) axial pain with neck stiffness radiating up to the subocciput region above or the shoulders below (b) radicular pain with numbness and tingling with or without associated weakness of the shoulder, chest, arms or hands, (c) Motor deficit with atrophy of muscles in upper limbs or lower limbs or both (d) Sensory deficits, (e) Myelopathy causing a wide based jerky gait with weakness and hyperreflexia. Patients with clinical and radiological evidence of cervical spondylosis were included in this study. After institutional ethics committee approval all patients coming to our outpatient department were assessed for inclusion and exclusion criteria.

### **Parameters to be studied :**

1. Pre and post-operative neurology.
2. Visual analogue scale.
3. Neck disability index.
4. Japanese orthopaedic association (JOA)
5. Cobbs angle (sagittal segmental alignment)
6. Bony fusion.

**Statistical Methods:** Descriptive and inferential statistical analysis has been carried out in the present study. Results on continuous measurements are presented on Mean  $\pm$ SD (Min-Max) and results on categorical measurements are presented in Number (%). Significance is assessed at 5 % level of significance. The following assumptions on data is made,

**Assumptions**

1. Dependent variables should be normally distributed,
2. Samples drawn from the population should be random, Cases of the samples should be independent Student t test (two tailed, independent) has been used to find the significance of study parameters on continuous scale between two groups (Inter group analysis) on metric parameters.

Student t test (two tailed, dependent) has been used to find the significance of study parameters on continuous scale with in each group. Chi-square/ Fisher Exact test has been used to find the significance of study parameters on categorical scale between two or more groups, Non-parametric setting for Qualitative data analysis. Paired Proportion test has been used to find the significance of proportion in paired data.

**Significant figures**

Suggestive significance (P value:  $0.05 < P < 0.10$ )

\* Moderately significant (P value:  $0.01 < P < 0.05$ )

\*\* Strongly significant (P value  $< 0.01$ )

**IV. Results**

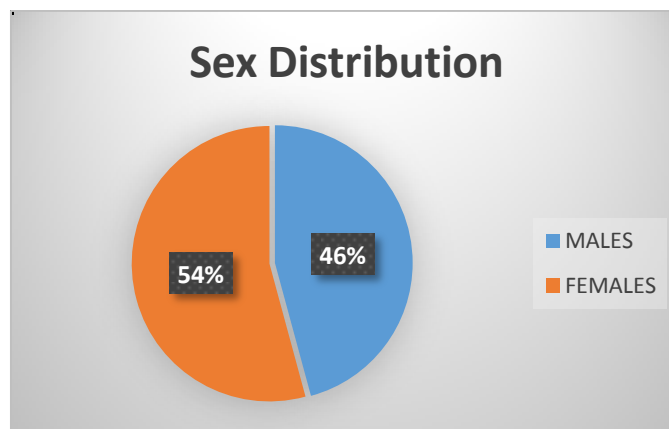
The result of the study is as follows:

**AGE**

Of all the patients, the youngest was a female aged 55 years, and the eldest was a male aged 73 years. Maximum patients were in the range of 61-70yrs.

Table 1: Age in years	No. of Patients	%
51-60	12	40.0
61-70	16	53.3
71-80	2	6.7
Total	30	100.0

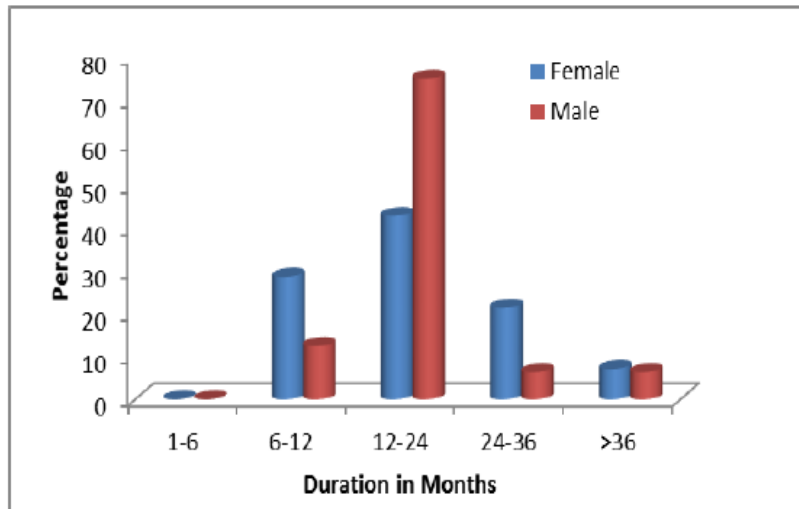
**SEX:** Of the 30 patients, 14 (i.e. 46.7%) were females. The rest 16 (i.e. 53.3%) were males.



**Duration of Symptoms**

Ranged from minimum of 7 months to maximum of 39 months. Maximum number of patients have symptoms duration of 12 to 24 months. Mean duration of symptoms is  $18.87 \pm 8.51$ .

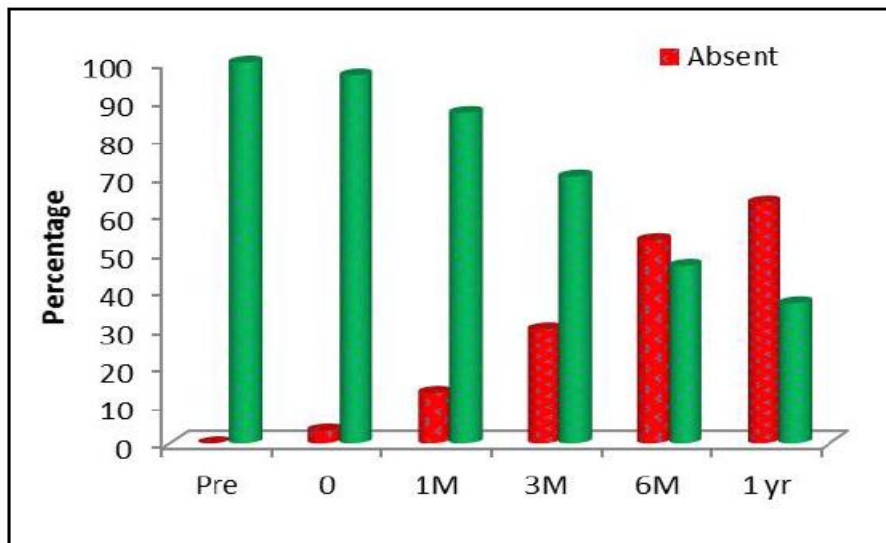
**Graph 2: Duration of symptoms in months**



**Presenting Symptoms and Neurological Status**

**Axial neck pain**

In current study and as shown in graph-3, thirty patients had axial neck pain pre-operatively. On follow up there was gradual decrease in neck pain. At the follow up at 6 months and 1 year there was 53.3% and 63.3% patients respectively improved in their neck pain.



**Graph 3: Axial neck pain distribution from pre operatively through 1 year follow up period.**

The patients' subjective condition was obtained with the Visual Analog Scale (VAS) for pain. A score of 0 mm indicate absence of pain & 100 mm as worst pain even experienced by the patient. In current study and as shown in table 2, mean pre-operative VAS score was 7.80±0.92. On follow up at 6 months and 1 year, the mean reduction in VAS score is 5.80±1.97 and 5.17±2.12 respectively.

Table 2: VAS Score	Min-Max	Mean ± SD	difference	t value	P value
Pre	6.00-9.00	7.80±0.92	-	-	-
0	5.00-10.00	8.63±1.35	-0.833	-3.022	0.005**
1M	3.00-9.00	7.47±1.25	0.333	1.581	0.125
3M	3.00-9.00	6.90±1.49	0.900	2.919	0.007**
6M	2.00-9.00	5.80±1.97	2.000	4.664	<0.001**
1 yr	2.00-9.00	5.17±2.12	2.633	5.711	<0.001**

**Neuro deficits**

In our study of 30 patients 27(90%) patients presented with Neuro deficits in the form of sensory, motor, or bowel and bladder disturbances. 3(10%) patients did not have any neurological deficits.

	Pre	0	1M	3M	6M	1 yr	% change
Absent	3(10%)	5(16.7%)	6(20%)	13(43.3%)	19(63.3%)	22(73.3%)	63.3%
Present	27(90%)	25(83.3%)	24(80%)	17(56.7%)	11(36.7%)	8(26.7%)	-63.3%
Total	30(100%)	30(100%)	30(100%)	30(100%)	30(100%)	30(100%)	-

Improvement of 63.3% in Neuro deficits is significant with  $P < 0.001^{**}$ , paired Proportion test.

In this current study and as shown in table-2, 90% patients who had Neuro deficits pre-operatively improved to 73.3% i.e, 22 out of 27 patients improved in neurology.26.7% of patients had persistence of neurology at the end of one year.

**Functional assessment of patient disability**

Japanese orthopaedic association (JOA) score : In this current study and as shown in table-4, the mean JOA score pre operatively is  $10.53 \pm 1.93$  and progressed gradually to a mean score of  $11.20 \pm 2.20$  post operatively at the end of one year.

	Min-Max	Mean $\pm$ SD	difference	t value	P value
Pre op	8.00-14.00	$10.53 \pm 1.93$	-	-	-
0	7.00-14.00	$10.13 \pm 2.01$	0.400	2.183	0.037*
1M	7.00-14.00	$10.47 \pm 1.94$	0.067	0.571	0.573
3M	8.00-14.00	$10.67 \pm 2.04$	-0.133	-1.000	0.326
6M	8.00-14.00	$11.00 \pm 2.23$	-0.467	-2.728	0.011*
1 yr	8.00-15.00	$11.20 \pm 2.20$	-0.667	-3.808	0.001**

Neck disability Index (NDI): In this study and as shown in table-5, the mean NDI score was  $27.10 \pm 5.22$  pre-operatively and gradually disability improved at the end of one year with mean decrease in NDI score  $22.77 \pm 7.65$ .

NDI	Min-Max	Mean $\pm$ SD	difference	t value	P value
Pre	17.00-37.00	$27.10 \pm 5.22$	-	-x	-
0	18.00-41.00	$28.83 \pm 5.60$	-1.733	-5.517	<0.001**
1M	15.00-39.00	$27.00 \pm 6.01$	0.100	0.300	0.766
3M	15.00-39.00	$25.80 \pm 6.31$	1.300	3.029	0.005**
6M	1x1.00-38.00	$24.10 \pm 7.23$	3.000	4.551	<0.001**
1 yr	11x.00-38.00	$22.77 \pm 7.65$	4.333	5.623	<0.001**

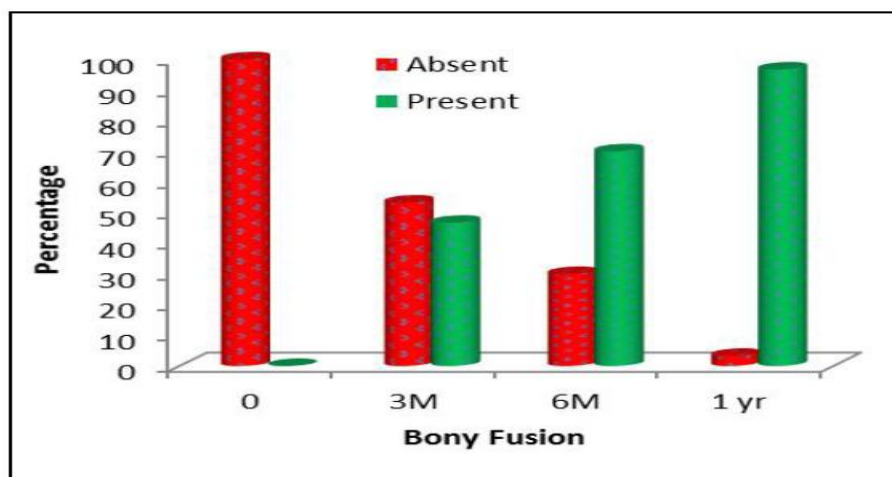
**Levels Fused**

All patients included in this study have a single level disease. Majority of patients in this study had pathology at C5-6 level (21 patients) 70%.30% patients (9 patients) had C6-7 level involvement.

**Radiological evaluation**

**Bony fusion.**

Fusion was achieved in 29 patients out of 30 patients i.e,96. 7%. One patient did not have radiological fusion at the end of one year. Improvement of 96.7% is significant, paired proportion test.



Graph 4: Bony fusion

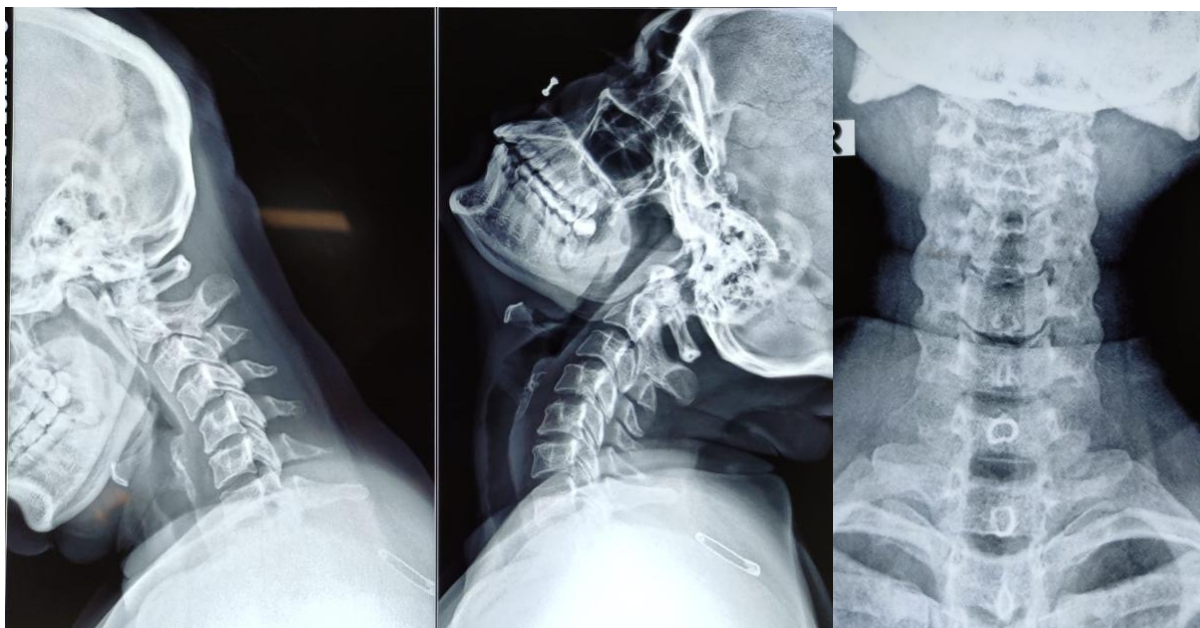
The mean segmental angle was found to be  $0.92 \pm 1.39$  in our study of 30 patients. Immediately after surgery angle increased to  $8.88 \pm 1.00$ . At the end of one year, mean segmental angle was  $4.93 \pm 1.30$ .

Cobbs Angle	Min-Max	Mean $\pm$ SD	difference	t value	P value
Pre	-1.50-3.70	$0.92 \pm 1.39$	-	-	-
0	7.50-10.50	$8.88 \pm 1.00$	-7.960	-50.295	<0.001**
1M	5.50-9.50	$7.58 \pm 1.16$	-6.660	-41.532	<0.001**
3M	4.00-9.00	$6.28 \pm 1.35$	-5.360	-31.094	<0.001**
6M	2.50-8.50	$5.52 \pm 1.39$	-4.593	-22.371	<0.001**
1 yr	2.00-8.00	$4.93 \pm 1.30$	-4.010	-18.846	<0.001**

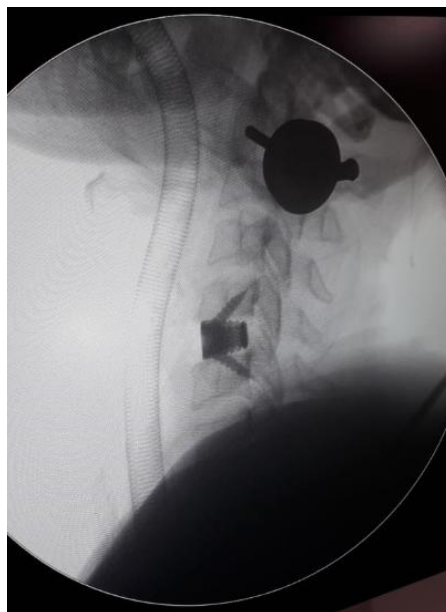
In our study and as shown in above table, out of 26 patients who had Neuro deficits pre operatively, 19 patients improved in the follow up period. 6 out of 7 patients who had kyphosis showed improvement in neuro deficit during follow up period. Only one patient who has kyphosis doesn't show Neuro deficit improvement. From the above table, there is no correlation between kyphosis and neurological outcome (p value-1.067).

Table 9: Kyphosis in relation to neurological outcome.

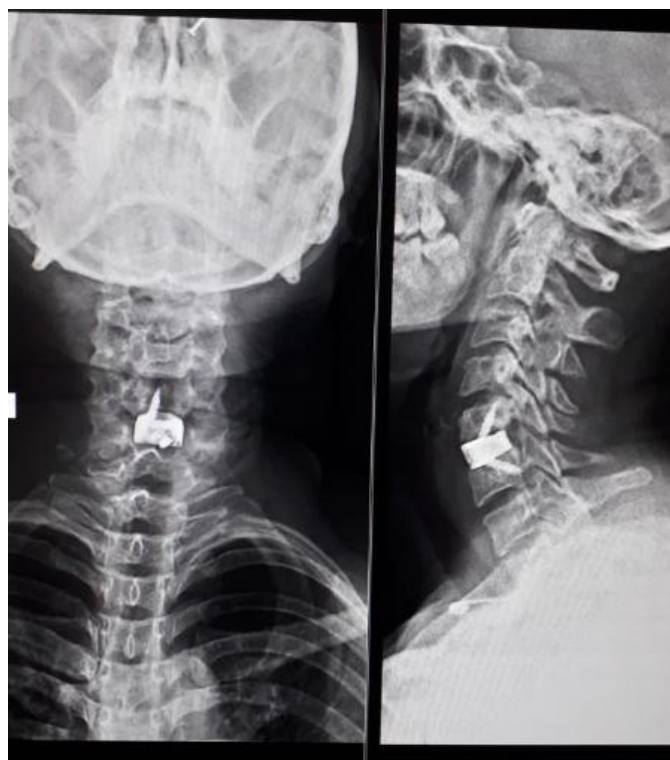kyphosis	Neuro deficits improved		Total
	Present	absent	
Present	6(31.6%)	1(12.5%)	7(25.9%)
Absent	13(68.4%)	7(87.5%)	20(74.1%)
Total	19	8	27



**Pre- Op X ray Showing C5 – C6**



**Intra – Operative C5-C6 Stand alone cervical cage placement**



C5-C6 Stand alone cervical cage one year follow-up showing c5-c6 fusion

## V. Discussion

Anterior cervical discectomy and fusion is established modality for treatment of degenerative conditions of cervical spine with radiculopathy.<sup>12-14</sup> Goal of fusion after anterior cervical discectomy is to provide stability to spinal column. Use of tricortical graft with plate or Biomechanical disc spacers like cage restores the height of the disc space by relieving buckling of posterior longitudinal ligament and ligamentum flavum. This in turn relieves cord compression and restores volume of the neural foramen thereby decompressing nerve root by the principle of ligamentotaxis. A fusion diminishes neural irritation by limiting motion and by allowing resorption of osteophytes partially.<sup>15</sup> Conventionally, tricortical auto graft is considered gold standard for fusion which provides osteogenic, osteoinduction and osteoconduction properties to graft along with mechanical strength owing to cortical struts in it. Such ideal fulfilments come with another set of concerns like graft collapse, graft extrusion and donor site complications. Graft has poor self-fixing characteristics and it can extrude, collapse or fail to heal resulting in symptomatic Pseudoarthrosis.<sup>14-16</sup> Prevention strategy for such complications requires addition or augmentation of fixation with anterior plate system. Minimal invasive harvesting of iliac crest graft aims to minimise various complications of graft harvesting, while giving benefits of autograft. Essentially, it saves surgical time by avoiding complex en-block harvesting of tricortical graft fills cage very well due to cancellous nature. Allograft eliminates donor site morbidity but having chances of disease transfer like HIV or hepatitis, though very rare.<sup>17</sup>

Newer surgical techniques attempt to eliminate donor site morbidity and graft related complications. Extrapolating from lumbar spine experience, a titanium cervical cage is proposed as an alternative method for cervical spine fixation and fusion simultaneously providing strength of cortical strut and osteogenic potential with minimal morbidities.<sup>17</sup>

Interbody fusion cages rely on the principle of annular tensioning (Ligamentotaxis) restoring disc height and volume and size of neuroforamen indirectly.<sup>18</sup> The main presenting symptom in our series was axial neck pain (100%). At the 1-year follow-up, the improvement of axial neck pain was 63.3%. The other presenting complaint of the patients are Neuro deficits in the form of sensory, motor, and/or bowel and bladder disturbances. 19 patients (63.3%) out of 27 who had Neuro deficits recovered at the end of 1 year follow up. 8 patients continued with the Neuro deficits. It is or more likely that these deficits represent overlap of dermatomes and myotomes from an adjacent or remote level supporting the notion of progression of cervical spine degenerative disease, acting as a major contributor to postoperative sensory and motor deficits.<sup>19</sup> In our series, there was a significant improvement in patient VAS scores at 1 year. Recently, Mehra *et al.*<sup>20</sup> found that approaching spinal levels above C4 and exposing more than 3 spinal levels were two factors significantly related to voice and swallowing problems. As all our operative levels were below C4 and we did not expose 3 levels in our patients, we did not have any incidence of persistent dysphagia or voice complaints. The JOA score



of all patients were improved after surgery ( $P < 0.05$ ). The average JOA score pre operatively was  $10.53 \pm 1.93$  and increased to  $11.20 \pm 2.20$  at final follow-up ( $P < 0.05$ ). The NDI score also significantly improved from a mean pre-operative score of  $27.10 \pm 5.22$  to  $22.77 \pm 7.65$  at the end of 1 year follow up. There was a significant improvement in patient functional status. Sagittal segmental alignment (SSA) i.e, cobb's angle is a good indicator of the efficacy of anterior cervical discectomy and interbody fusion.<sup>21</sup> Comparison between preoperative and postoperative SSA demonstrated the efficacy of our technique for correcting cervical sagittal alignment when degenerative changes produce cervical spine straightening or cervical kyphosis. In our study SSA angles of all patients has improved with a mean pre-operative value of  $0.92 \pm 1.39$  to  $4.93 \pm 1.30$  at the end of one year. SSA angles measured at last follow-up demonstrate a slight loss of correction in comparison with the 6 month postoperative angles, but these changes were not significant, suggesting that the correction obtained with surgery was maintained even after 1 year.

Cervical kyphosis was defined as progression of  $\geq 5^\circ$  at the postoperative 12-month follow-up compared to that measured at the immediate postoperative period.<sup>22</sup> Barsa and Suchome<sup>23</sup> have studied stand-alone cage group cervical angulation after 6-month postoperative follow-up. They reported that using Cobb angle resulted about  $8.7^\circ$  loss of segmental lordosis. Also Yang *et al.*<sup>24</sup> have studied average  $1.58^\circ$  cervical angulation change from immediate postoperative to last follow-up stand-alone cage group. And 29.8% of them changed over  $3^\circ$ . Our studies show that cervical kyphosis was occurred in 23.3%. Cervical kyphosis can occur disc space narrowing and adjacent segment degeneration.<sup>25,26</sup> In our study kyphosis did not show any adverse outcome in clinical improvement of the patients. The PEEK cage is radiolucent and allowing the surgeon to better evaluate fusion status on radiographs or CT scans. In our series, 29 patients (96.7%) achieved good solid fusion within 12 months (mean months) using a PEEK cage filled with cancellous allograft bone chips. These results confirm those of other studies.<sup>27, 28</sup> In addition to a high fusion rate, successful treatment depends on the maintenance of interspace height and segmental angle.<sup>29-31</sup> Solid arthrodesis was rated according to the following accepted criteria.<sup>32-35</sup> The operated segment was rated as a solid arthrodesis, if movement of less \*than  $2^\circ$  was measured, and by the absence of motion between the spinous processes on lateral flexion-extension radiographs. Cabraja *et al.*, did not find any statistical difference between two materials of cage with respect to cage subsidence, fusion rates and lordosis maintenance.<sup>36</sup> Thom *et al.*, found cage as safe modality for fusion as compared to tricortical autograft with better functional outcome in cage group with a concern for graft donor site morbidity.<sup>37</sup> An investigator blinded study with larger number of study subjects will establish true clinical superiority of one technique over other.

## VI. Conclusion

ACDF with stand-alone cages was associated with relatively good clinical and radiologic long-term results. Anterior cervical discectomy and interbody fusion using standalone cervical cages can be considered a safe and effective technique to cure cervical disc herniation with intractable pain or neural deficit in cases where conservative treatment failed. It reliably alleviates cervical degenerative radiculopathy by attaining adequate interbody fusion. It is a safe and equally efficient alternative to iliac crest autograft and anterior cervical plating by providing adequate stability.

## References

- [1]. Chau AM, Mobbs RJ. Bone graft substitutes in anterior cervical discectomy and fusion. *Eur Spine J.* 2009; 18(4):449-464.
- [2]. Burkhardt JK, Mannion AF, Marbacher S, Kleinstück FS, *et al.* The influence of cervical plate fixation with either autologous bone or cage insertion on radiographic and patient-rated outcomes after two-level anterior cervical discectomy and fusion. *European Spine Journal.* 2014; 1-7.
- [3]. Zhou J, Xia Q, Dong J, Li X, Zhou X, Fang T, *et al.* Comparison of stand-alone polyetheretherketone cages and iliac crest autografts for the treatment of cervical degenerative disc diseases. *Acta Neurochir.* 2010; 153:115-22.
- [4]. Hacker RJ. A randomised prospective study of an anterior cervical fusion device with a minimum of 2 years follow-up results. *J Neurosurg (Spine 2)* 2000; 93:222-226.
- [5]. Meier U, Grave A, Hajdukova A. Clinical experience with Cespace, the new intervertebral disc spacer by Aesculap for spondylosis of the cervical spine in comparison with similar products by Weber, Intromed and AcroMed. *Neurosurg Q.* 2003; 13:40-50. doi: 10.1097/00013414-200303000-00004.
- [6]. Payer M, May D, Reverdin A, Tessitore E. Implantation of an empty carbon fibre composite frame cage after single-level anterior cervical discectomy in the treatment of cervical disc herniation: preliminary results. *J Neurosurg (Spine 2)* 2003; 98:143-148.
- [7]. Profeta G, Falco R, Ianniciello G, Profeta L, Cigliano A, Raja AI. Preliminary experience with anterior cervical microdiscectomy and interbody titanium cage fusion (Novus CT-Ti) in patients with cervical disc disease. *Surg Neurol.* 2000; 53:417-426. doi: 10.1016/S0090-3019(00)00207-X.
- [8]. Thome C, Leheta O, Krauss JK, Zevgaridis D. A prospective randomized xcomparison of rectangular titanium cage fusion and iliac crest autograft fusion In patients undergoing anterior cervical discectomy. *J Neurosurg Spine.* 2006; 4:1-9.
- [9]. randomised comparison between the Cloward procedure and a carbon fiber cage in the cervical spine: a clinical and radiological study. *Spine.* 2002; 27:1694-1701. doi: 10.1097/00007632-200208150-00003.
- [10]. Hwang S, Lin C, Lieu A, Lee K, Kuo T, Hwang Y, *et al.* Three-level and four-level anterior cervical discectomies and titanium cage-augmented fusion with and without plate fixation. *J Neurosurg (Spine 1)* 2004; 2:160-167. doi: 10.3171/spi.2004.1.2.0160.
- [11]. Kadziora F, Pflugmacher R, Schafer J, Born C, Duda G, Haas NP, *et al.* Biomechanical comparison of cervical spine interbody fusion cages. *Spine.* 2001; 26:1850-1857. doi: 10.1097/00007632-200109010-00007. [PubMed] [Cross Ref]

- [12]. Chang Hyoun Kim, Chi Heon Kim, Chun Kee Chung. Tae-Ahn Jahng. Comparison of Operating Time between Stand-alone Cage and a Standard Method for a Single Level Cervical Disc Disease.
- [13]. 1x3- Published online 2012 Mar 31.doi:10.14245/kjs.2012.9.1.12.PMCID: PMC4432378.
- [14]. Pavel Barsa, Petr Suchomel. Factors affecting sagittal malalignment due to cage subsidence in standalone cage assisted anterior cervical fusion. Published online 2007 Jan 13. PMCID:PMC2200763.https://dx.doi.org/10.1007%2Fs00586-006-0284-8.
- [15]. 586-006-0284-8.
- [16]. Hacker RJ, Cauthen JC, Gilbert TJ, Griffith SL. A prospective randomized multicenter clinical evaluation of an anterior cervical fusion cage. *Spine (Phila Pa 1976)* 2000; 25(20):2646–2654. doi: 10.1097/00007632-200010150-00017. discussion 2655.
- [17]. Anakwenze OA, Auerbach JD, Milby AH, Lonner BS, Balderston RA. Sagittal cervical alignment after cervical disc arthroplasty and anterior cervical discectomy and fusion: results of a prospective, randomized, controlled trial. *Spine (Phila Pa 1976)* 2009; 34(19):2001-2007
- [18]. Faldini C, Leonetti D, Nanni M, Di Martino A, Denaro L, Denaro V, *et al.* Cervical disc herniation and cervical spondylosis surgically treated by Cloward procedure: a 10-year-minimum follow-up study. *J Orthop Traumatol.* 2010; 11(2):99-103. doi: 10.1007/s10195-010-0093-z.
- [19]. Faldini C, Pagkrati S, Leonetti D, Miscione MT, Giannini S. Sagittal segmental alignment as predictor of adjacent-level degeneration after a Cloward procedure. *Clin Orthop Relat Res.* 2011; 469(3):674-681.
- [20]. Celik SE, Kara A, Celik S. A comparison of changes over time in cervical foraminal height after tricortical iliac graft or polyetheretherketone cage placement following anterior discectomy. *J Neurosurg Spine* 2007; 6:10-16.
- [21]. David JA, Harry NK. Indications and trends in use in cervical spinal fusion. *Orthop Clin of North Am.* 1998; 29(4):731-44.
- [22]. Henry HB, Sanford EE, Donald BG, Paul KJ. Robinson anterior cervical discectomy and arthodesis for cervical radiculopathy, long term follow-up of one hundred and twenty two patients. *J Bone & Joint Surg (Am).* 1993; 75(4):1298-307.
- [23]. Burkhardt JK, Mannion AF, Marbacher S, Kleinstück FS. *et al.* The influence of cervical plate fixation with either autologous bone or cage insertion on radiographic and patient-rated outcomes after two-level anterior cervical discectomy and fusion. *European Spine Journal.* 2014; 1-7.
- [24]. Phillips FM, Lee JY, Geisler FH, Cappuccino A, Chaput CD, DeVine JG, *et al.* A prospective, randomized, controlled clinical investigation comparing PCM cervical disc arthroplasty with anterior cervical discectomy and fusion: 2-year results from the US FDA IDE clinical trial. *Spine.* 2013; 38:E907-18.
- [25]. Cannada LK, Scherping SC, Yoo JU, Jones PK, Emery SE. Pseudoarthrosis of cervical xspine: a comparison of radiological diagnostic measures. *Spine.* 2003; 28(1):46-51.
- [26]. Verhagen AP, Van Middelkoop M, Rubinstein SM, Ostelo R, *et al.* Effect of various kinds of cervical spinal surgery on clinical outcomes: A systematic review and meta-analysis. *PAIN.* 2013; 154:2388-96.
- [27]. Anderson DG, Albert TJ. Bone grafting, Implants, and plating options for anterior cervical fusion. *Orthopedic clinics of North America.* 2002; 33(1):317-28. [PubMed]
- [28]. Chau AM, Mobbs RJ. Bone graft substitutes in anterior cervical discectomy and fusion. *Eur Spine J.* 2009; 18(4):449-64.
- [29]. Ryu SI, Mitchell M, Kim DH. A prospective randomized study comparing a cervical carbon fiber cage to the Smith-Robinson technique with allograft and plating: up to 24 months follow-up. *Eur Spine J.* 2006; 15(2):157-
- [30]. Moreland DB, Asch HL, Clabeaux DE, *et al.* Anterior cervical discectomy and fusion with implantable titanium cage: initial impressions, patient outcomes and comparison to fusion with allograft. *Spine J.* 2004; 4(2):184-91.
- [31]. Assietti R, Beretta F, Arienta C. Two-level anterior cervical discectomy and cage-assisted fusion without plates. *Neurosurg Focus.* 2002; 12(1):23-30.
- [32]. Zevgaridis D, Thomas C, Krauss JK. Prospective control study of rectangular titanium cage fusion compared with iliac crest autograft fusion in anterior cervical discectomy. *Neurosurg Focus.* 2002; 12(1):42-47.
- [33]. Profeta G, De Falco R. Preliminary experience with anterior cervical microdiscectomy and interbody titanium cage fusion in patients with cervical disc diseases. *Surg Neurol.* 2000; 53:417-26.
- [34]. Moon HJ, Kim JH, Kwon TH, Chung HS, Park YK. The effects of anterior cervical discectomy and fusion with stand-alone cages at two contiguous levels on cervical alignment and outcomes. *Acta Neurochir.* 2011; 153:559-65.
- [35]. Lehmann CL, Buchowski JM, Stoker GE, Riew KD. Neurologic recovery after anterior cervical discectomy and fusion. *Global Spine J.* 2014; 4:41-46.
- [36]. Acharya S, Kumar S, Srivastava A, Tandon R. Early results of one-level cervical discectomy and fusion with stand-alone cervical cage and bone marrow soaked tricalcium phosphate. *Acta Orthop Belg.* 2011; 77:218-223.
- [37]. Oda I, Cunningham BW, Buckley RA, Goebel MJ, Haggerty CJ, Orbegoso CM, *et al.* Does spinal kyphotic deformity influence the biomechanical characteristics of the adjacent motion segments? An in vivo animal model. *Spine (Phila Pa 1976)* 1999; 24:2139-2146.
- [38]. Kulkarni AG, Hee HT, Wong HK. Solis cage (PEEK) for anterior cervical fusion: preliminary radiological results with emphasis on fusion and xsubsidence. *Spine J.* 2007; 7(2):205-209.