

A study of Clinical Profile of Cerebral Venous Sinus Thrombosis -an Experience in a Tertiary Care Centre in India

Dr. Byju N, MD DM (Neurology), Associate Professor in Neurology, GMC, Thrissur

Dr. Doron Susan Mathew, MD General Medicine, Lecturer in Medicine, GMC Thrissur

Dr. Biju P R, MS General Surgery, Associate Professor in Surgery, GMC Thrissur

Abstract: Cerebral Venous Sinus Thrombosis is an uncommon condition with diverse clinical features. It is a cause of stroke affecting young people preferably females and it is usually overlooked. Although the clinical features are very much confusing, it affects 5 people per million annually and accounts for 0.5% to 1% of all strokes. It is more common in young women frequently during the pregnancy and puerperium. There are many studies implicating oral contraceptives and various coagulation disorders as the cause of CVST. It may present as headache, seizures or focal neurological deficits. Sometimes papilloedema may be the only sign. Its etiology and pathology has not been well understood even now. Although the clinical features are very much confusing, Introduction of various imaging modalities have made the diagnosis easy. Diagnosis of this condition requires high index of suspicious and hence it is very important that we should learn about the clinical profile and risk factors.

Objectives: To study the clinical presentation, age of onset and gender distribution of patient with Cerebral Venous Sinus Thrombosis admitted in neurology department of a tertiary care hospital in India.

The patients are enrolled in the study based on definite inclusion and exclusion criteria. Sample size is 35 patients. The data collection tool is using a structured proforma. Methodology is data collection record based analysis. Secondary data of patients with CVST, particularly variables like age of onset, gender, clinical presentation are collected. Data is entered in MS excel & analyzed using appropriate software like Epi info. Qualitative data was analyzed using proportion. It was tabulated & discussed. Confidentiality of data will be maintained

Keywords: Cerebral Venous Sinus Thrombosis; Headache, Seizure, Papilloedema. NECT- NON enhanced CT scan, CECT contrast enhanced CT scan, MR Venogram; Superior Sagittal Sinus;

Date of Submission: 14-12-2021

Date of Acceptance: 28-12-2021

I. Introduction

Cerebral Venous Sinus Thrombosis (CVST) is an uncommon condition with diverse clinical features. It is a cause of stroke affecting young people preferably females and it is usually overlooked¹. Although the clinical features are very much confusing, introduction of various imaging modalities have made the diagnosis easy. Diagnosis of this condition requires high index of suspicious and hence it is very important that we should learn about the clinical profile and risk factors.

A Brief Review: Cerebral Venous Sinus Thrombosis is one of the commonest cause of young stroke in our country. The first case of CVST has been described as earliest in the 19th century by Ribes Et-al¹. But it still remains a diagnostic and therapeutic challenge to all clinicians. This is because of its varied clinical features, predisposing factors and brain imaging findings².

The cerebral venous system is made up of a network of superficial sinuses and deeper cortical veins that drain the superficial surfaces of both cerebral hemispheres, as well as the deeper brain structures returning blood back to the heart via the internal jugular veins. The cerebral sinuses, besides draining blood are essential for the transportation of cerebrospinal fluid (CSF) through the arachnoid villi. Occlusion of cerebral sinuses blocks transport of CSF which results in rise of intracranial pressure. Secondly, occlusion of a cortical vein, obstructs the drainage of blood from adjacent brain tissue. Depending upon the extent of the thrombus and availability of venous collaterals, it can cause an increase in venous and capillary pressure and breakdown of blood brain barrier³.

It affects 5 people per million annually and accounts for 0.5% to 1% of all strokes. It is more common in young women frequently during the pregnancy and puerperium. There are many studies implicating oral contraceptives and various coagulation disorders as the cause of CVST.⁴. Hereditary prothrombotic conditions

such as factor V Leiden mutation, deficiency of proteins C and S and AT III as well as prothrombin gene mutation also have been implicated. Alcoholism is another risk factor, which is often over looked. Although various risk factors have been described in association with CVST, the exact etiology and pathogenesis are yet to be understood.

Based on the time of onset, it has been divided into 3 subtypes

1. Acute-<48 hrs,
2. sub acute->48 hrs- <30 days.
3. chronic->1 month,

The most common form is sub acute form and the chronic form is less frequent⁵.

Headache is the most common presenting symptom of CVST and it is usually acute and severe. Seizures and focal neurological deficits such as hemi paresis can occur in the presence of brain parenchymal lesions. 40% of patients present with one or two seizures. Although it is possible to have any combination of signs and symptoms, most of the patients present with the following clinical syndromes; isolated intracranial hypertension (headache, decreased vision and papilledema), focal symptoms (deficits or seizures)¹.

Advances in imaging techniques have revolutionized the diagnosis of CVST. The usual imaging techniques used include computerized tomography (CT) plain and contrast, magnetic resonance imaging (MRI) and MR venography. MRI is the gold standard and allows visualizations of the thrombus within the vessel and absent flow in MR venogram. Early diagnosis allows early initiation of treatments and decreases the morbidity and mortality.

Objectives

- 1) To study the clinical presentation, age of onset and gender distribution of patient with Cerebral Venous Sinus Thrombosis admitted in neurology department of a tertiary care hospital in India.

II. Materials And Methods

Study design - Cross sectional study - Record based Study setting - GMC, Department of Neurology Thrissur Study participants

This is a retrospective study using the copies of discharge cards Cerebral Venous Sinus Thrombosis patients admitted in neurology ward from August 2018 (01/08/2018 to July 21 (31/07/2021).

Inclusion criteria

All the patients in the study are cases of Cerebral Venous Sinus Thrombosis diagnosed on clinical and radiological confirmation.

Exclusion criteria

1. Patients who were initially diagnosed Cerebral Venous Sinus Thrombosis, but whose MRI and MR Venograms were normal.
2. Patients below 12 years of age.

Study period - 2 months

Sample size - All cases during the period 01/08/2018 to 31/07/ 2021 will be included. So the Sample size is 35.

Data collection tool - structured proforma

Methodology - Data collection Record based Analysis. Secondary data of patients with Cerebral Venous Sinus Thrombosis were collected using a structured proforma. Data on clinical presentation, age of onset, gender, progression and clinical test performed and diagnostic test employed were collected.

Variables : Include Age, Gender, Clinical Presentation, Duration of symptoms. Radiological features etc...

Data Analysis

Data was entered in MS excel & analysed using appropriate software like Epi info. Qualitative data were analyzed using proportions, Was tabulated & discussed.

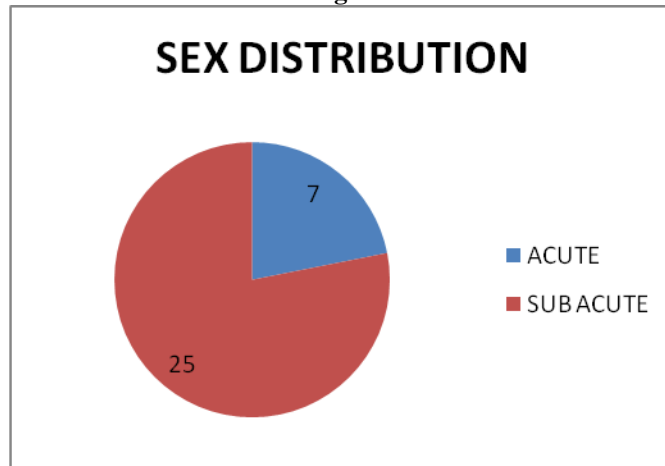
Ethical consideration

This is a record based study. It was started only after getting the approval from the research and ethical committee. Confidentiality of data will be maintained.

III. Results :

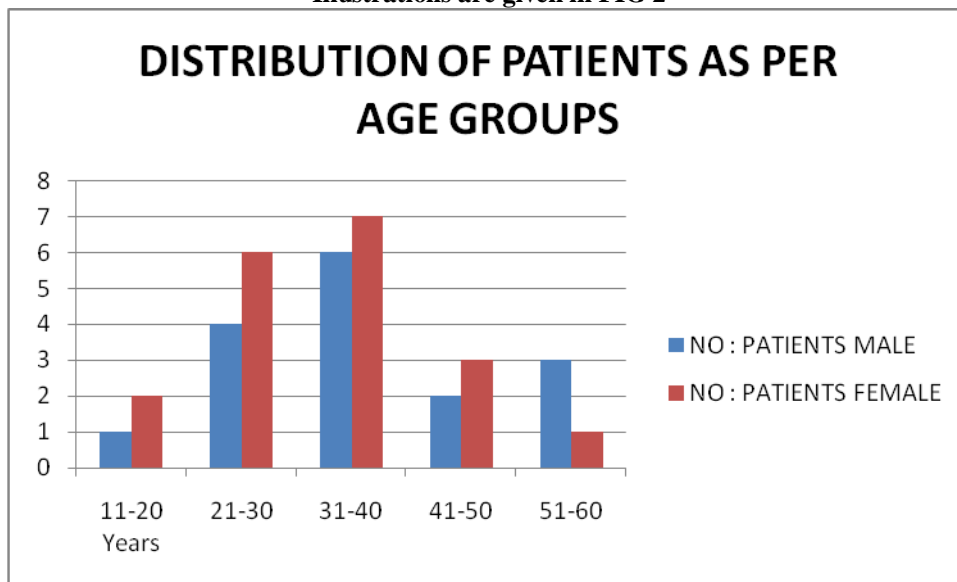
Sex : 35 patients were included in our study, out of which 19(54%) were females and 16 (46%) males.

Illustrations given in FIG 1



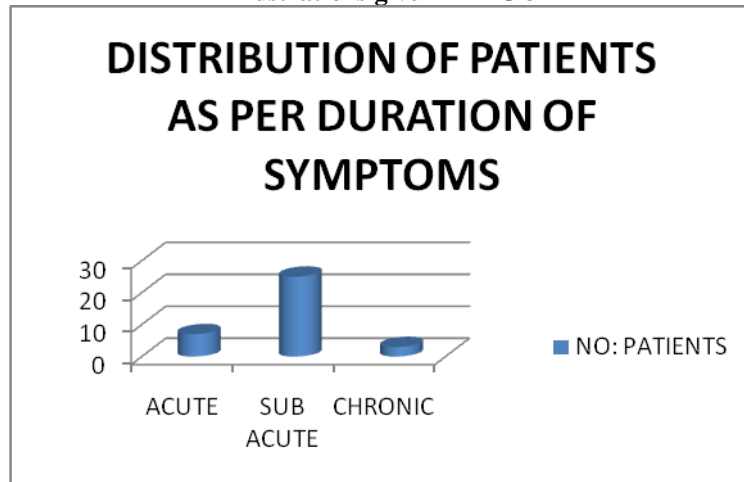
Age group Distribution : when the age groups was analyzed the age of patients ranged from 18 years to 54 years. The mean age the patients was 32 years.

Illustrations are given in FIG 2



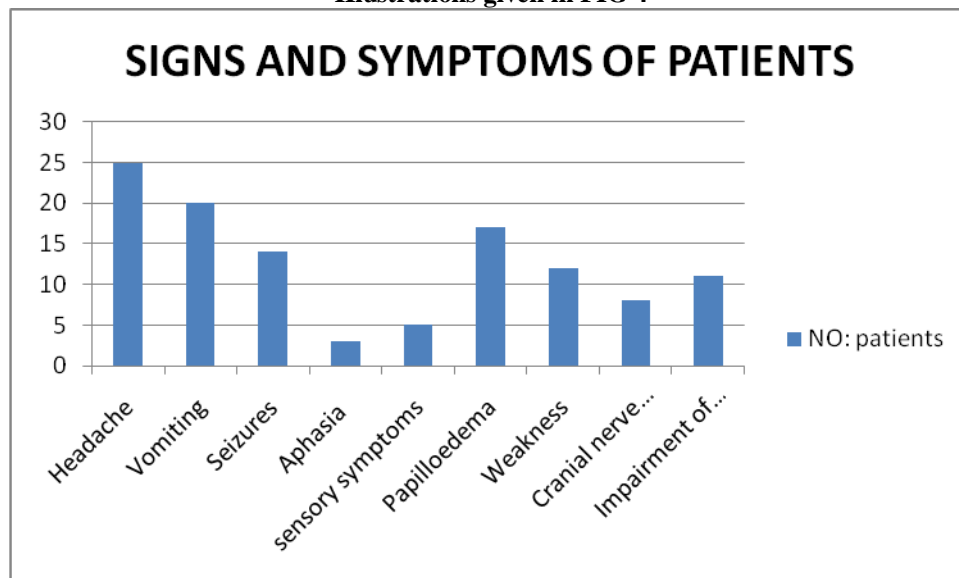
Mode of Onset: As per the duration, patients are classified into acute , sub acute and chronic. 7 patients (20%) presented within 24 hours (acute), 25 patients (71%) presented within a period of less than 30 days (sub acute), and 3 patients (9%) presented within a period more than one month (chronic).

Illustrations given in FIG 3



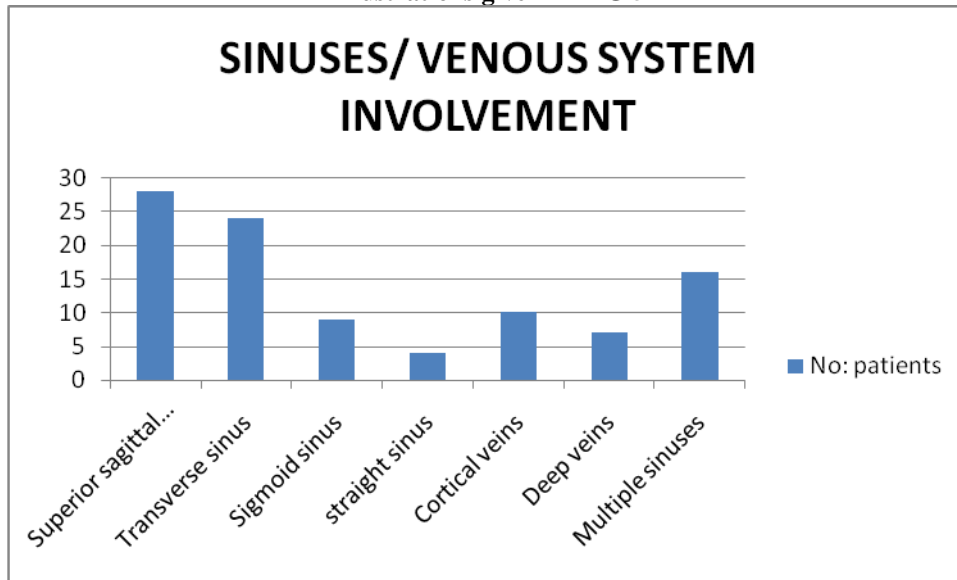
Symptoms and Signs: 25 patients (70.4%) had head ache, 20 patients (57.4%) had vomiting, 14 patients (40%) had seizures. Imparement of consciousness was present in 11 patients (30%) . 12 patients had (34.2%) had weakness out of which 7 had hemiplegia. 8 patients (22.8%) had cranial nerve involvment out of which 5 had 6th nerve involvement 2 had 9th and 10th nerve involvement and 1 had 12th nerve involvement. Papilloedema was present in 17 patients (48.5%), aphasia was present in 3 patients (8.5%) and sensory disturbances was present in 5 patients (14.25%).

Illustrations given in FIG 4



CT/MRI Findings: All patients were subjected to NECT CT and CECT scan head to search for the cause of neurological deficits. 5 patients (14.25 %) showed a cord sign in the non enhanced CT scan. In the contrast enhanced CT 12 patients (34.25%) showed an empty delta sign. Both the signs were indicative of CSVT. MRI of the brain was also done in all cases. MRI brain was normal in 5 patients (14.82%) of our study group .The location of the thrombus could be visualized with MR VENOGRAM. 25 patients (80%) in our study had superior sagittal sinus thrombosis,24 patients (68.5%) had transverse sinus thrombosis,9 patients (25.7%) had sigmoid sinus thrombosis,4 patients (11.4%) had straight sinus thrombosis. 10 patients (28.5%) had thrombosis of the cortical veins and 7 patients (20%) had thrombosis in the deep cortical venous system. 16 patients (45.5%) had multiple thrombi in different sinuses.

Illustrations given in FIG 5



Cause : Detailed history was taken to find out the predisposing factors and causes of CSVT, 25 Patients had addictions. Out of this 19 patients (76%) were alcoholics. 15 patients (60%) had smoking as risk factor. 3 patients (8.5%) were intra venous drug abusers. Anemia was seen in 24 patients (68.5%) out of which 7 (29.1%) had severe anemia. 7 Patients (20%) had infections as the pre disposing factor and 2 had malignancies. 14 patients were pregnant during the detection of CSVT and 11 of them had taken prolonged oral contraceptive drugs. 9 patients (25.7%) had pro thrombotic states in our study. Out of which 7 had APLA and 2 had combined deficiencies of Protein C and Protein S .

IV. Discussion:

Sex : There was a female preponderance in our study group with females constituting 19 out of 35 total patients. male to Female ratio is 1:1.17. Such female preponderance has been described by Narayan et al(1:1.5)⁶ and Khosya et al 1:1.3⁷

Age group Distribution : in our study the maximum number of patients was present in the age group 31-40 years with a slight female predominance. The mean age of the patients was 32 years. Mugundhan et al has reported the mean age of patients as 33.2 years⁸ and Narayan et al has reported the mean age as 31.3years⁶ respectively in their studies.

Mode of Onset: As per the duration , patients are classified into acute , sub acute and chronic. 7 patients (20%) presented within 24 hours (acute), 25 patients (71%) presented within a period of less than 30 days (sub acute) and 3 patients (9%) presented within a period more than one month. So in our study majority of the patients presented in the acute and sub acute stage. In the study by Khosya et al ⁷ 27% patients presented in the acute phase, 56% in the sub acute phase and 17% in the chronic phase. Similarly in the study by Ferro et al 37.2% patients were in the acute phase, 55.5% in the sub acute phase and 7.2 % in the chronic phase respectively⁹.

Symptoms and Signs: The symptoms and signs found in CVST could be explained by many mechanisms (a). Thrombosis of cerebral veins with local affects produced by venous obstructions. (b).The thrombosis of major sinuses causing rise in intra cranial pressure.

The most common symptom in our study group was headache, which was present in 70.4% of the patients followed by vomiting which was present in 57.4% of the patients. The inflammation of the involved sinus and the overstretching of the nerve fibers in the walls of the blocked sinus is believed to produce headache. Vomiting is due to the secondary effect of increased intra cranial pressure. Rajendran A et al has reported frequency of headache and vomiting as 69.7% and 75.6% in history⁴.

Various focal neurological deficits can occur in CVST depending on the area of brain involved in our study. Weakness was the presenting symptoms in our groups which was present in 12 patients (34.2%). Out of this 7 patients had hemi paresis (58.33%). Rajendran et al⁴ has described neurological deficits in 36.4% of its patients and hemi paresis in 66.6% of these patients with focal neurological deficits⁴. Cranial nerve deficits were found in 8 patients (22.8%). In our study an incidence of 21.2% of cranial nerve deficits has been described by Rajendran et al in his study⁴. Pappiledema was present in 17 patients (48.6%) . This is due to the

rise in intracranial pressure. It is more common in chronic cases and patients who had a delayed presentation of symptoms. In study by Rajendran et al⁴ and Krishnan et al Ref⁸ the incidence of Pappiledema are 45.5% and 38% respectively. Impairment of sensorium was seen in 11 patients(30%) in our study. A similar incidence has been reported by Krishnan et al⁸.

CT/MRI Findings: Non enhanced CT scan of the head may be the first performed investigations in a patient who presents with neurological symptoms. CVST may be seen as a hyper attenuation in the sinus which is occluded (cord sign). This increased attenuation is cost by decrease in the amount of serum and an increase in the amount of fibrinogen and proteins in the thrombus. This finding is seen only in 25 to 30% of the cases and only during the acute and sub acute phases. In our study cord sign was present in 5 patients (14.25%). Narayan et al⁶ has reported the incidence of this cord sign as very low (3%) in his study. Similarly, the empty delta sign can be perceived as a triangular area of contrast enhancement surrounding a hypo attenuating area in CECT. This is seen as a filling defect in the region of superior sagittal sinus. On the sagittal or coronal planes, the transverse sinus has a similar appearance. In our study empty delta sign was seen in 12 patients (34.2%). The incidence of the sign in the study by Narayan et al⁶ is (56%).

Non enhanced Magnetic resonance imaging of the head along with magnetic resonance venography is the most sensitive investigation tool in the diagnosis of CVST. There may be variations in signal intensity of the thrombus, depending upon its age. This phenomenon is due to the paramagnetic effects of the products of hemoglobin degradation. In the acute phase, thrombus appears as iso intense when compared with brain tissue in T₁ weighted images and hypo intense on T₂ weighted images due to the presents of the deoxy hemoglobin. In the sub acute face thrombus appears hyper intense on both T₁ and T₂ weighted images due to the formation of meth hemoglobin. In the chronic stage thrombus may be iso intense on T₁ weighted images and iso intense or hyper intense on T₂ weighted images. (MD Heterogeneous with variable intensity relative to surrounding brain tissue^{10,11}, Anatomical variants such as hypoplastic sinus can be distinguished from CVST by giving contrast to the MR venogram. Khosya et al⁷, In our study 80% had superior sagittal sinus thrombosis and 68.5% had transverse sinus thrombosis 45% patients had multiple sinus involvement. In the study by Rajendran et al⁴, 80% patients had involvement of the superior sagittal sinus and 68.5% had involvement of the transverse sinus. In the study by Halesha et al¹² the incidence of superior sagittal sinus thrombosis was 82% and transverse sinus thrombosis was 68%.

Cause and predisposing factors : On assessing the history in detail, it was found that 25 Patients(71.4%) in our study group had addictions. Out of this 19 patients(76%) were alcoholics. Addictions were observed in 81.8% of the patients in the study by Rajendran et al⁴ and the prevalence of alcoholics in this group of addictions was 72.7%. Although alcoholism has been recognized as cause of ischemic stroke, heavy binges of drinking is often associated with CVT. It may lead to a sympathetic surge leading on to changes in blood pressure, heart rate and increase the coagulability blood. Heavy binges of drinking will produce a state of dehydration, hyper viscosity and aggregation of platelets¹³. Seizures are also common in alcoholics. 15 patients (60%) had smoking as risk factor. 3 patients (8.5%) were intra venous drug abusers. Anemia was seen in 24 patients (68.5%) out of which 7 (29.1%) had severe anemia.

Pro-thrombotic states have been identified as common causes of CVST in many international studies, with an incidence of around 34%. Pai et al¹⁴ has described an incidence 12-18% Pro-thrombotic states. The prevalence of pro thrombotic states was 25.7% in our study. Rajendran et al⁴. Has reported an incidence of 27.3% of pro thrombotic states in his study. In our study 7 patients were APLA positive, 2 had homocystin deficiency and another 2 had protein C and protein S deficiency.

V. Conclusion :

Cerebral venous sinus thrombosis this one of the uncommon causes of young stroke. It is usually treatable and reversible, if detected in the early stages. Commonly it is more seen in young people with a slight female preponderance. The clinical symptoms are very diverse ranging from mild headache to various focal neurological signs including papilloedma. Headache is the most common symptom, in our group. Because of the atypical symptoms and signs, it is usually over looked and misdiagnosis by doctors. Majority of the cases usually present in the acute and sub acute phase, Anemia and alcoholism were common reversible pre disposing conditions. A careful search may be made for finding out other causes like pro thrombotic states. The diagnosis requires a high level of suspicion. Employment of newer imaging techniques has revolutionized the diagnosis of CVST and the management is made more efficient and prognosis much better.

References

- [1]. Coutinho JM. Cerebral venous thrombosis. *Journal of Thrombosis and Haemostasis*. 2015 Jun;13:S238-44.
- [2]. Singh A, Jain R, Chouksey D, Sodani A. CLINICAL AND RADIOLOGICAL PREDICTORS OF OUTCOME IN CEREBRAL VENOUS SINUS THROMBOSIS: AN OBSERVATIONAL STUDY. *Romanian Journal of Neurology*. 2020 Oct 1;19(4).
- [3]. Ungersböck K, Heimann A, Kempf O. Cerebral blood flow alterations in a rat model of cerebral sinus thrombosis. *Stroke*. 1993 Apr;24(4):563-9.
- [4]. Rajendran A, Bose JA, Ponnu SD, Jayasankar VR, Shameer P. Clinical and Etiological Profile of Cerebral Venous Sinus Thrombosis.
- [5]. Idiculla PS, Gurala D, Palanisamy M, Vijayakumar R, Dhandapani S, Nagarajan E. Cerebral venous thrombosis: A comprehensive review. *European Neurology*. 2020;83(4):369-79.
- [6]. Narayan D, Kaul S, Ravishankar K, Suryaprabha T, Bandaru VC, Mridula KR, et al. Risk factors, clinical profile, and long-term outcome of 428 patients of cerebral sinus venous thrombosis: Insights from Nizam's Institute Venous Stroke Registry, Hyderabad (India). *Neurol India* 2012;60:154-9.
- [7]. Khosya S. A Study of Clinical Profile, Risk Factors and Outcome of the Cerebral Venous Sinus Thrombosis (CVST): An Experience at a Tertiary Care Center, INDIA. *Austin J Neurol Disord Epilepsy*. 2018;5(2).
- [8]. Krishnan M, Nagarajan M. A Study of 50 Cases of Cerebral Venous Sinus Thrombosis. *IJRRJOURNAL*, Vol.6;issue :9, september 2019
- [9]. Ferro JM, Canhão P, Stam J, Boussier MG, Barinagarrementeria F. Prognosis of cerebral vein and dural sinus thrombosis: results of the International Study on Cerebral Vein and Dural Sinus Thrombosis (ISCVT). *Stroke*. 2004 Mar 1;35(3):664-70.
- [10]. Bianchi D, Maeder PH, Bogousslavsky J, Schnyder P, Meuli RA. Diagnosis of cerebral venous thrombosis with routine magnetic resonance: an update. *European neurology*. 1998;40(4):179-90.
- [11]. Macchi PJ, Grossman RI, Gomori JM, Goldberg HI, Zimmerman RA, Bilaniuk LT. High field MR imaging of cerebral venous thrombosis. *Journal of computer assisted tomography*. 1986 Jan 1;10(1):10-5.
- [12]. Halesha BR, Chennaveerappa PK, Vittak BG, Jayashree N. A study of the clinical features and the outcome of cerebral venous sinus thrombosis in a tertiary care centre in South India. *JOURNAL OF CLINICAL AND DIAGNOSTIC RESEARCH*. 2011 Jun 1;5(3):443-7.
- [13]. Malarcher AM, Giles WH, Croft JB, Wozniak MA, Wityk RJ, Stolley PD, Stern BJ, Sloan MA, Sherwin R, Price TR, Macko RF. Alcohol intake, type of beverage, and the risk of cerebral infarction in young women. *Stroke*. 2001 Jan;32(1):77-83.
- [14]. Pai N, Ghosh K, Shetty S. Hereditary thrombophilia in cerebral venous thrombosis: a study from India. *Blood Coagulation & Fibrinolysis*. 2013 Jul 1;24(5):540-3.

Dr. Byju N, et. al. "A study of Clinical Profile of Cerebral Venous Sinus Thrombosis - an Experience in a Tertiary Care Centre in India." *IOSR Journal of Dental and Medical Sciences (IOSR-JDMS)*, 20(12), 2021, pp. 25-31.