

Management of Impacted Maxillary Anterior Tooth with dilaceration by surgical repositioning

Dr. Lakshmi Kiran¹, Dr. Madhu Santhakumar², Dr. Kannan Vadakkepurayil³,
Dr. Anu Abraham⁴

¹ Post Graduate student, Department of Paediatric and Preventive Dentistry, Government Dental College, Kozhikode, Kerala, India

² Additional Professor, Department of Paediatric and Preventive Dentistry, Government Dental College, Kozhikode, Kerala, India

³ Professor and Head, Department of Paediatric and Preventive Dentistry, Government Dental College, Kozhikode, Kerala, India

⁴ Post Graduate student, Department of Paediatric and Preventive Dentistry, Government Dental College, Kozhikode, Kerala, India

Corresponding author-Dr Lakshmi Kiran, Post Graduate student, Department of Paediatric and Preventive Dentistry, Government Dental College, Kozhikode, Kerala, India. Email: lakshmi.pedogmail.com

Abstract

Trauma to deciduous anterior tooth can result in damage to the underlying permanent successor tooth leading to dilaceration and it ends in tooth being impacted. Management of dilacerated tooth can cause great difficulty to the clinician which usually ends in extraction of such tooth.

This article put forward two case reports describing the management of impacted permanent anterior teeth with dilaceration by surgical repositioning.

Key Words; impacted dilacerated anterior teeth, surgical repositioning

Date of Submission: 20-11-2021

Date of Acceptance: 04-12-2021

I. Introduction

Dilaceration refers to an angulation or a sharp curve in the root or crown of a formed tooth. Trauma results in change of the calcified portion of the tooth and the remaining tooth develops at an angle.³ The curve or bend in the tooth may occur anywhere along the tooth, depending upon the amount of tooth formed when the injury occurred.⁶

The most complicated situation is root dilaceration with the crown in an inverted direction; thus, the tooth always is impacted. Management of such tooth includes extraction, surgical /orthodontic treatment.¹

This article describes two case reports of management of impacted dilacerated anterior teeth by surgical repositioning along with bone graft placement.

II. Case description

Case 1

A 12 year old boy reported to the Department of Pedodontics and Preventive dentistry with the complaint of unerupted upper front teeth.

On examination root stump of right deciduous central incisor with missing permanent right maxillary central incisor was noted (Fig.1). Cone Beam Computerised Tomography (CBCT) was taken which revealed impacted maxillary right permanent central incisor with dilacerations of root (Fig2).

Treatment plan was formulated to reposition the tooth surgically with minimal trauma to avoid injury of periodontal ligament.

Local anaesthesia was administered and flap was elevated with vertical incisions to expose the impacted tooth. Bone covering the crown area was removed using carbide bur HP702 attached to micromotor handpiece and tooth carefully removed from socket with minimal trauma.

Tooth end was slightly reshaped for proper placement into the socket. Tooth was positioned into the socket within few minutes followed by bone graft (Osseograft-DMBM-xenograft) placement. Tooth was placed in a semi erupted position to safeguard marginal bone regeneration. Suture splint was given (Figs. 3-6). Antibiotics and analgesics were prescribed.

Management of Impacted Maxillary Anterior Tooth with dilaceration by surgical repositioning

Splint was removed after 2 weeks and cold test done .Tooth was found to be vital. Clinical and radiographic follow up after 1 year found no periapical pathology, inflammatory resorption /replacement resorption and intra oral periapical radiograph showed bone formation around the tooth (Figs. 7-8)

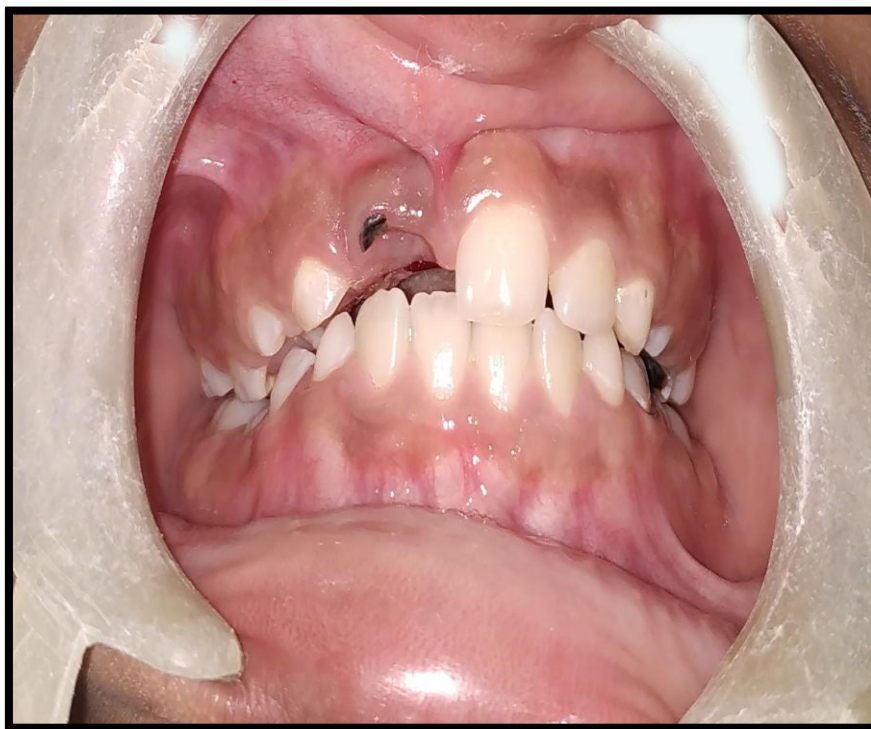

Fig 1

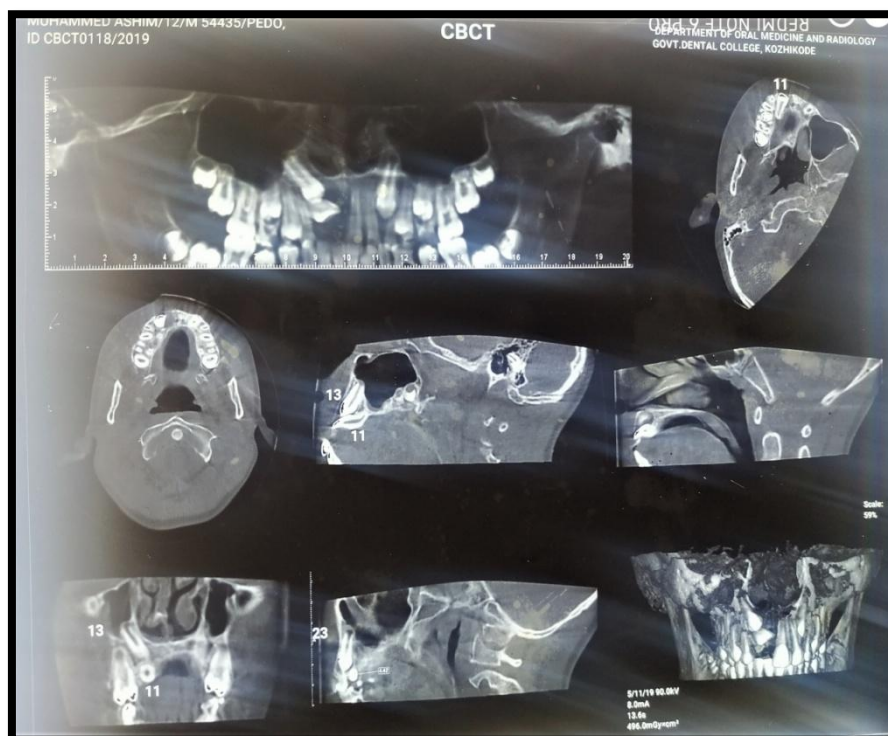


Fig 2

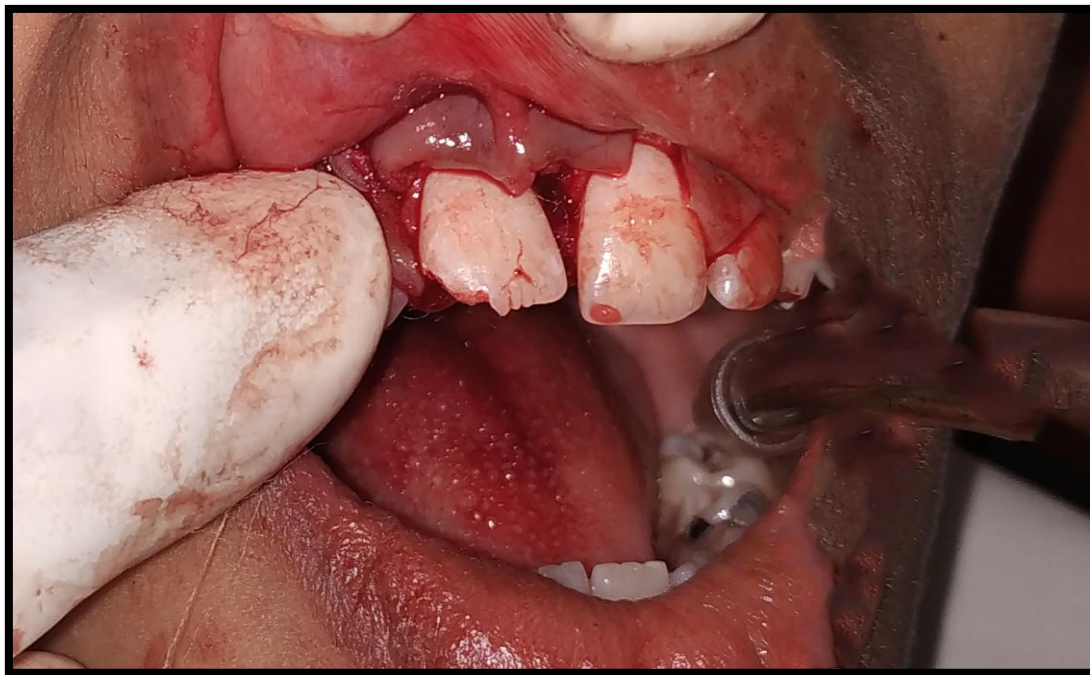


Fig 3

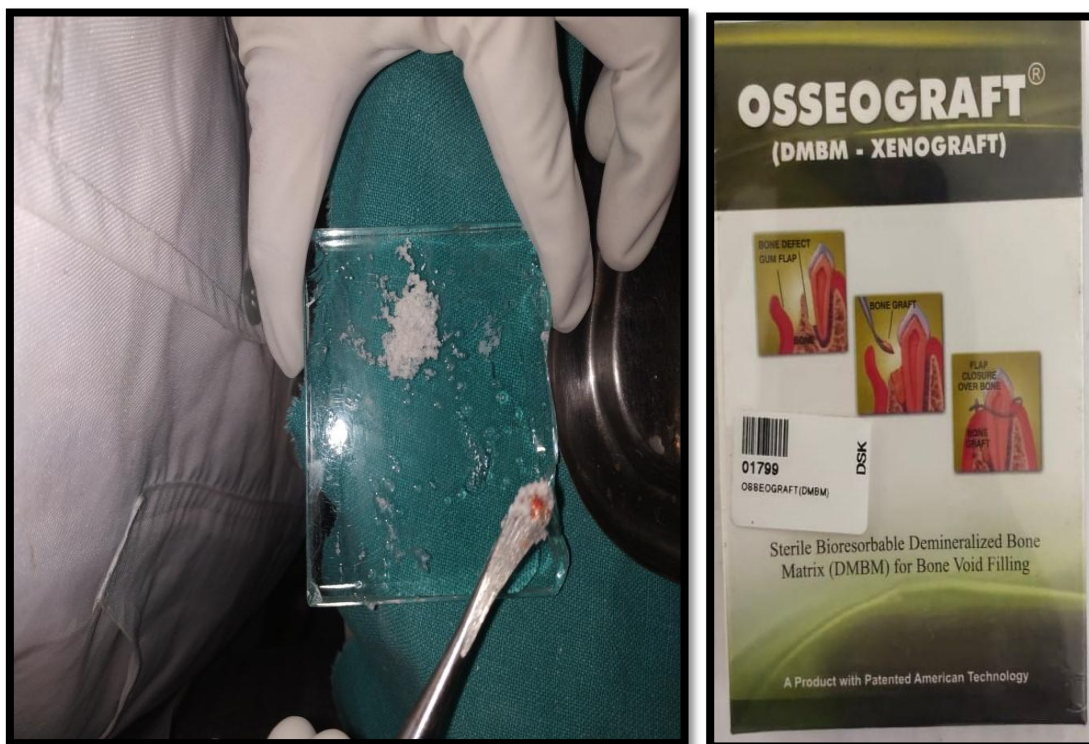

Fig 4

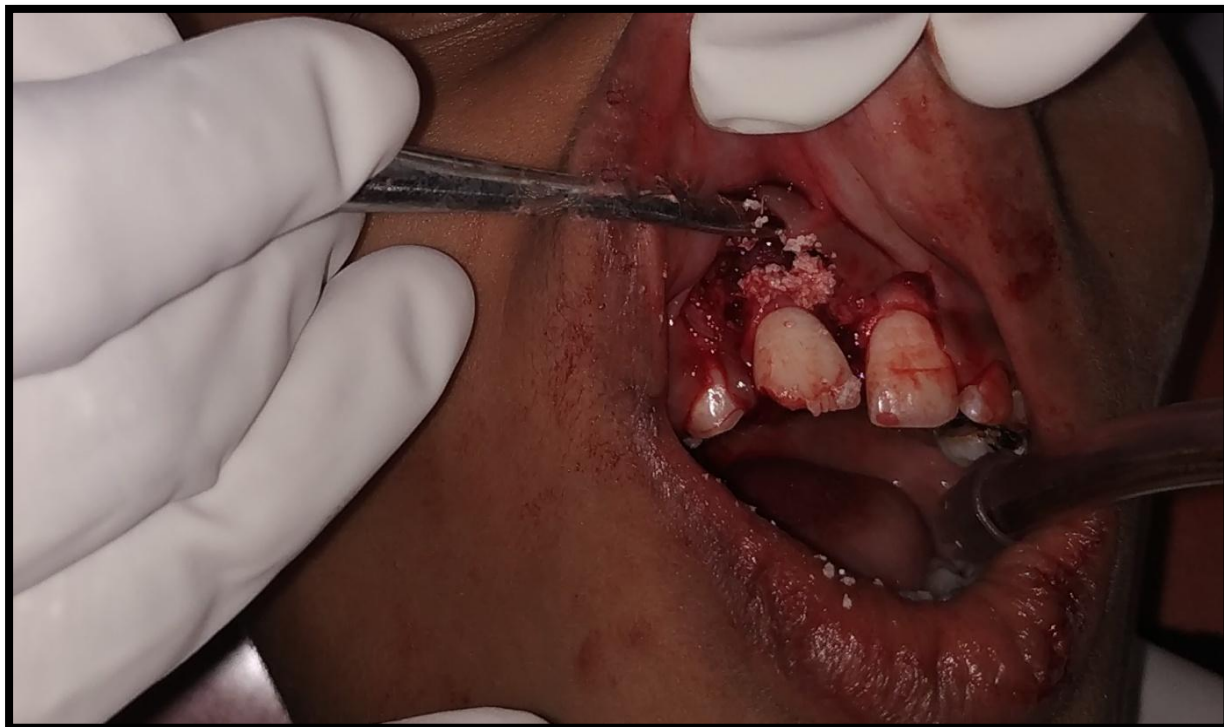


Fig 5

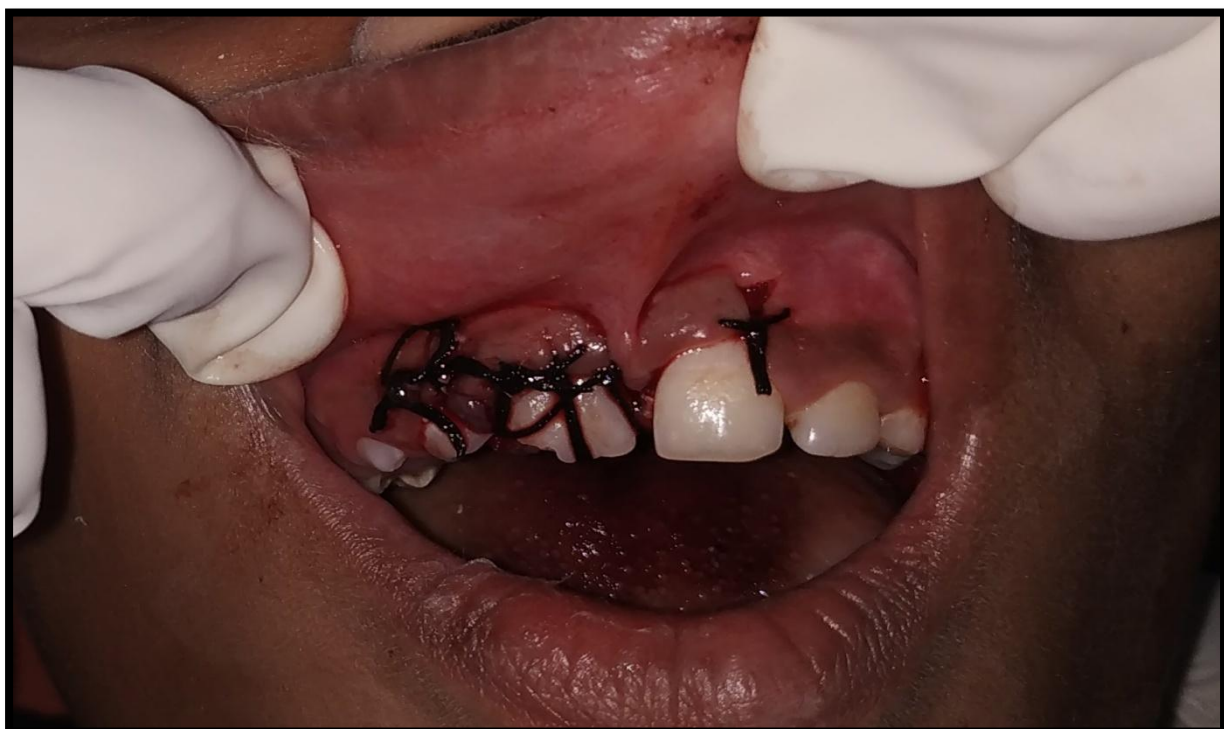

Fig 6

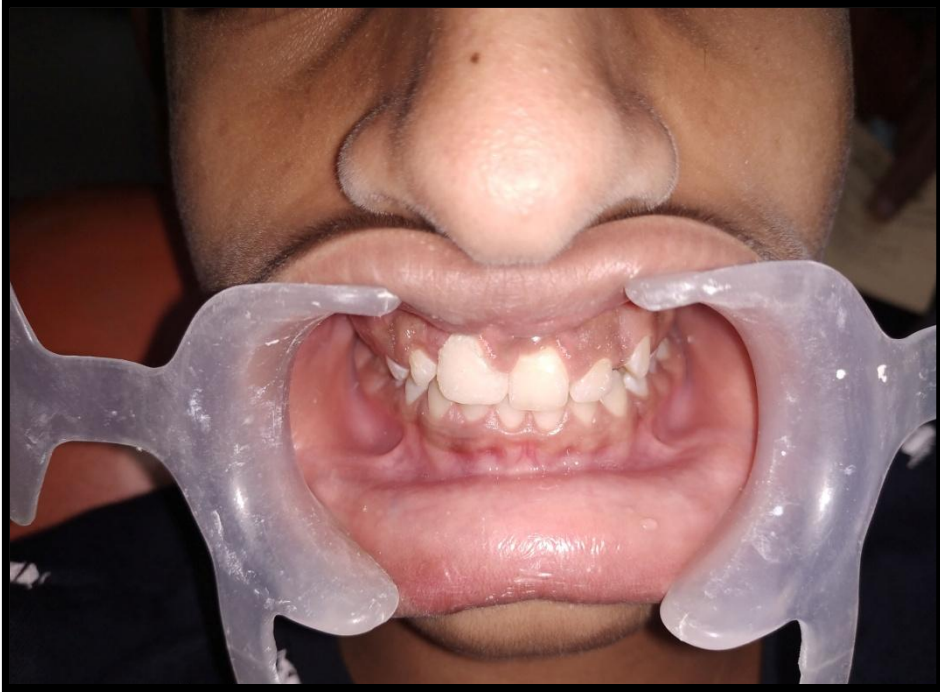

Fig 7

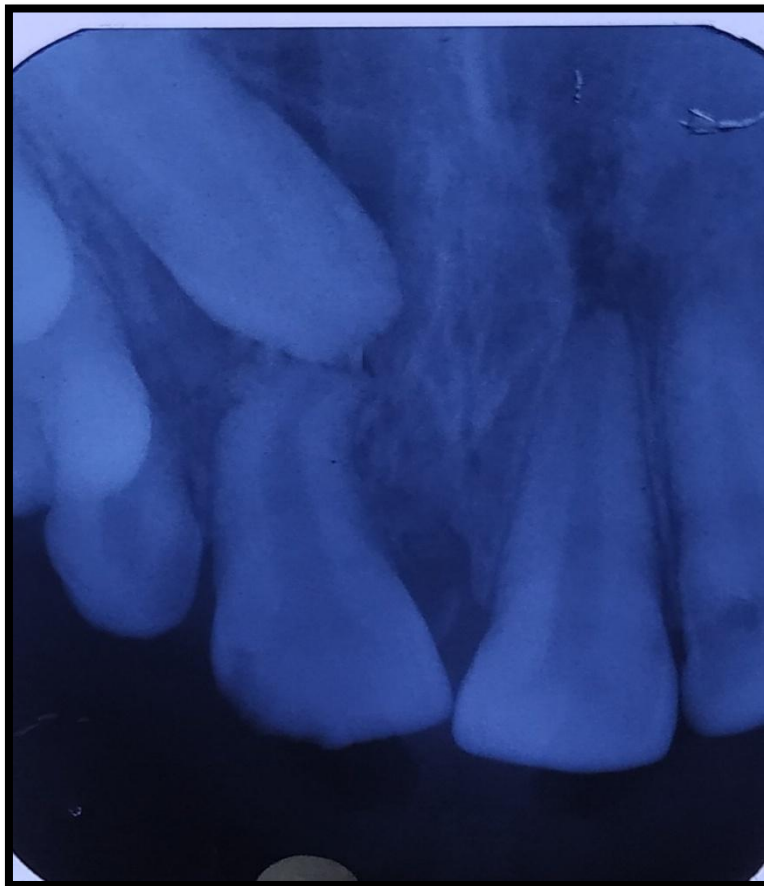


Fig 8

Case 2

A 10 year old girl reported to the Department of Pedodontics and Preventive dentistry complaining of missing upper front teeth. On examination permanent maxillary permanent right central incisor was missing (Fig.1). Intraoral periapical radiograph revealed presence of mesiodens along with dilacerated right maxillary central incisor (Fig.2).

Surgical removal of mesiodens followed by repositioning of right central incisor was planned. Local anaesthesia was administered and flap was raised labially and palatally. Mesiodens was extracted from anterior palatal area and labially impacted incisor was exposed after chipping the bone using rongeur. Tooth carefully transplanted onto the socket without causing much trauma to periodontal ligament. Bone graft was placed and flap sutured with tooth in semi-erupted position. Suture splint was given (Fig.3-5) .Antibiotics and analgesics were prescribed.

Splint was removed after 2 weeks and cold tests done and it was found that tooth is vital. Tooth responded normally to percussion and no mobility was found. Post operative intraoral periapical radiograph showed good healing of periapical region around the tooth (Fig. 6). Next follow up is being scheduled after 2 weeks.

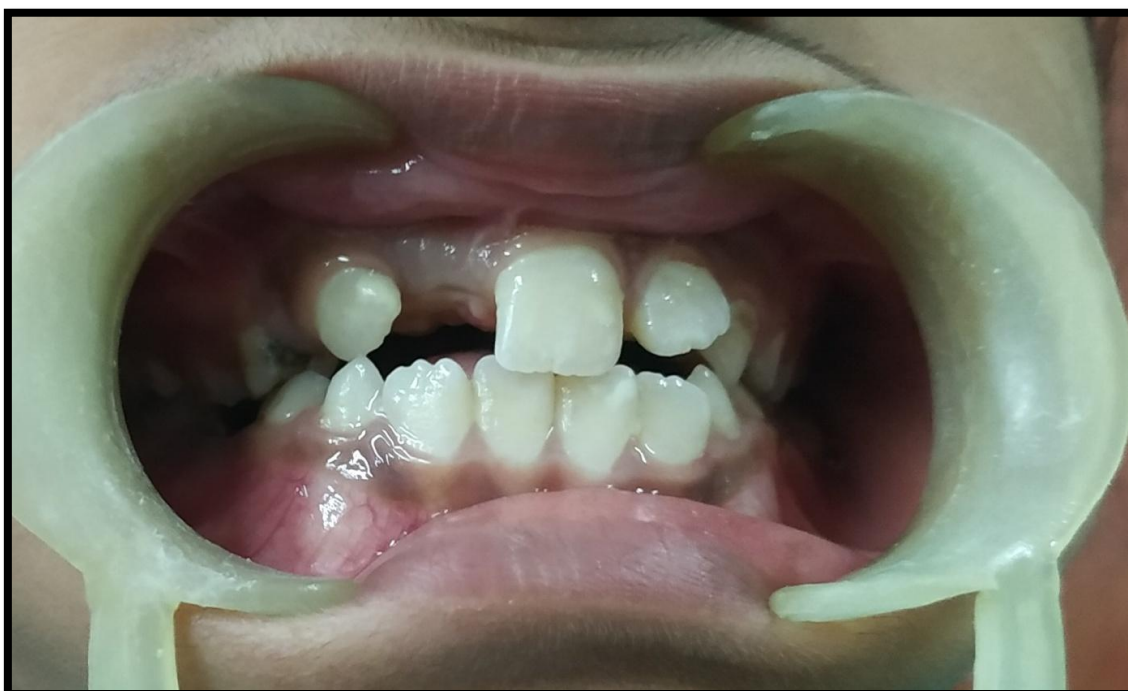

Fig 1

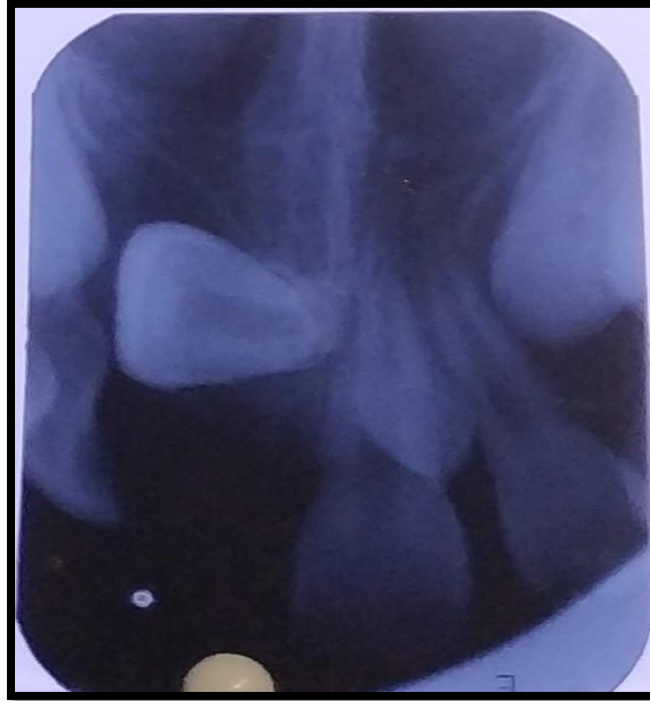

Fig 2

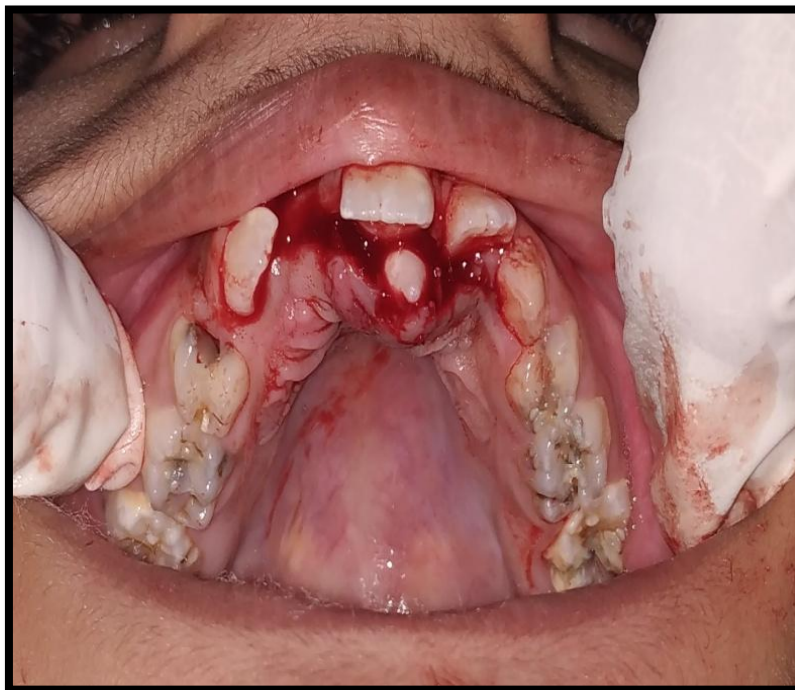


Fig 3

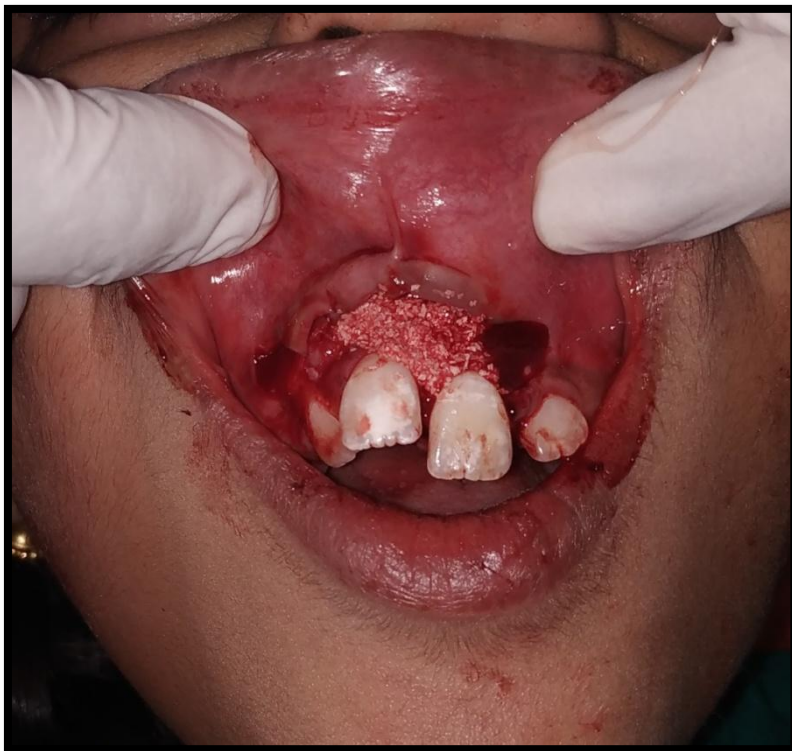

Fig 4

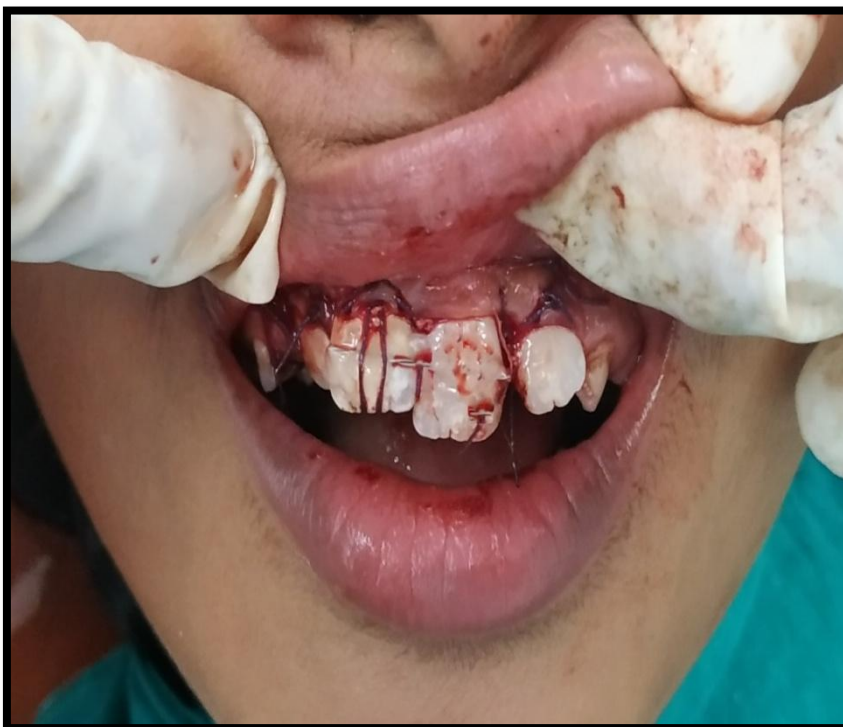

Fig 5

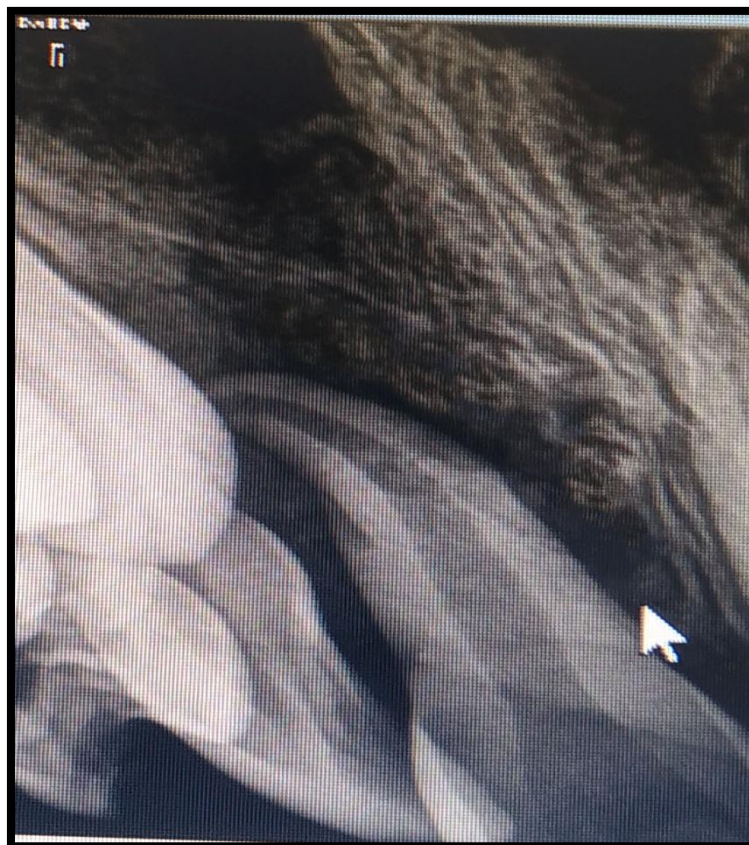


Fig 6

III. Discussion

Missing front tooth is always a psychological trauma to the child which being a Pediatric dentist is often encountered in our daily practice. Surgical removal or orthodontic treatments are the management options for a dilacerated maxillary permanent incisor. If the surgical option is chosen, the space can be closed orthodontically or replaced with prosthesis. Parents always found to choose the method which can save the tooth rather than removal.

Dilacerations is one among the sequale of trauma to deciduous dentition and which is often quite challenging to be managed. Dilacerations can be classified into mild ($20-40^{\circ}$), moderate ($41-60^{\circ}$) or severe ($\geq 61^{\circ}$) depending on the angle formed between the long axis of tooth and the deviated segment.⁴ In both cases it can be considered to be severe. Various treatment options include extraction, surgical exposure and orthodontic traction, autotransplantation with premolars or supernumerary teeth and surgical repositioning.

There are many advantages to surgical repositioning of an impacted dilacerated incisor. Only one surgical site and one procedure are needed. The surgical technique is relatively simple compared with that of transplanting a premolar into the incisor area.¹ A regular clinical setting, with local anaesthesia, is adequate for the procedure. The success rate of surgical repositioning of an impacted dilacerated incisor depends on the degree of dilaceration and on the position of the tooth and root formation.³

In both cases we have attempted to reposition teeth in the socket without much trauma and bone graft was placed for better healing and bone deposition. Teeth were maintained in a semi-erupt position for better healing for marginal gingiva.

After one year in first case tooth was found to be vital with normal periodontal healing. Reshaping and placement of bone graft may helped in healing. In second case good prognosis was found after 2 weeks and further follow up is required to ascertain success.

IV. Conclusion

The above two cases discussed in this article suggest that surgical repositioning can be a good treatment option for management of impacted dilacerated permanent tooth. Immediate improvement in aesthetics, better healing of gingiva and relatively simple procedure are the few advantages of this technique.

Bibliography

- [1]. Tsai TP. Surgical repositioning of an impacted dilacerated incisor in mixed dentition. *J Am Dent Assoc.* 2002 Jan;133(1):61–66
- [2]. Singh Harpreet, Kapoor Pranav, Sharma Poonam, Dudeja Pooja, Maurya Raj Kumar, Thakkar Surbhi. Interdisciplinary management of an impacted dilacerated maxillary central incisor. *Dental Press J. Orthod.* 2018 June ; 23(3): 37-46
- [3]. Vivek Kumar Adlakha, Preetika Chandna, Sumir Gandhi, Saroj Chopra, Namita Singh, Shamsheer Singh. Surgical Repositioning of a Dilacerated Impacted Incisor. *Int J Clin Pediatr Dent.* 2011 ; 4(1): 55–58
- [4]. Beatriz Feitosa da Silva, Luciana Ellen Dantas Costa, Ricardo Villar Beltrão, Tânia Lemos Rodrigues, Lombardi de Farias, Rejane Targino Soares Beltrã . Prevalence assessment of root dilaceration in permanent incisors. *Dental Press J Orthod.* 2012 Nov-Dec;17(6):97-102
- [5]. Anshula Deshpande, Sabrinath Prasad, Neeraj Deshpande .Management of impacted dilacerated maxillary central incisor: A clinical case report .*Contemp Clin Dent.* 2012 Apr; 3: S37–S40
- [6]. Shafer, WG.; Maynard, KH.; Bernet, ML. A textbook of oral pathology. 4th edition. Philadelphia: WB Saunders Co 1993. p. 40.
- [7]. Lin YT. Treatment of an impacted dilacerated maxillary central incisor. *Am J Orthod Dentofacial Orthop* 1999 Apr;115(4): 406-409.
- [8]. Andreasen JO, Petersen JK, Laskin DM. Textbook and color atlas Of tooth impactions. Copenhagen, Denmark: Munksgaard; 1997:113-24.

Dr Lakshmi Kiran, et. al. “Management of Impacted Maxillary Anterior Tooth with dilaceration by surgical repositioning.” *IOSR Journal of Dental and Medical Sciences (IOSR-JDMS)*, 20(12), 2021, pp. 31-40.