

One-Stage Ridge Splitting using piezoelectric surgery in the atrophic maxilla with simultaneous implant placement clinical and radiographic evaluation

Ahmed Mohamed Bilal¹, Mahmoud Taha El-Destawy², Akram Abbass Al-Awady³, Mohamed Mohamed bioumy⁴

Assistant Lecturer, Department of Oral Medicine, Periodontology, Diagnosis and Oral Radiology Faculty of Dentistry, Al-Azhar University, Cairo -Egypt¹

Associate professor, Department of Oral Medicine & Periodontology & Diagnosis and Oral Radiology, Faculty of Dental Medicine Al-Azhar University, Cairo -Egypt²

Professor, Department of Oral Medicine & Periodontology & Diagnosis and Oral Radiology, Faculty of Dental Medicine Al-Azhar University, Cairo-Egypt³

Professor, Department of Oral Medicine & Periodontology & Diagnosis and Oral Radiology, Faculty of Dental Medicine Al-Azhar University, Cairo -Egypt⁴

Abstract

Objectives: One- Stage crestal ridge splitting (CRS) was evaluated concerning implant stability measurements and marginal bone level.

Subjects and methods: 10 implants were inserted into ten patients with the atrophic alveolar ridge in the anterior maxillary arch. The crestal ridge splitting technique was performed with piezoelectric surgery followed by simultaneous implant placement. Records of Implant stability quotient (ISQ) were obtained immediately after implant insertion, 4, and after 6 months. Moreover, and marginal bone levels were evaluated via postoperative Cone-beam Computed Tomography (CBCT).

Results: Clinically, the crestal ridge splitting group showed increased postoperative Implant stability quotient scores at all observation intervals ($p \leq 0.001$). Moreover, postoperative Cone-beam Computed Tomography images of crestal ridge splitting participants revealed lower marginal bone loss ($p \leq 0.001$).

Conclusion: Following the implant placement into the narrow alveolar ridge, the crestal ridge splitting modality displayed enhanced implant stability measurements, and decreased marginal bone loss.

Keywords: piezoelectric surgery, segmental ridge Splitting, Implant Stability.

Date of Submission: 08-11-2021

Date of Acceptance: 24-11-2021

I. Introduction:

A sufficient amount of soft tissue and alveolar ridge must be present for successful dental implant treatment, and various methods have been used over the years to achieve these results. (1) When the width of alveolar ridges is not optimal, some authors advocate the use of onlay block or particulate grafts. (2) The difficulty with many of these techniques is that they necessitate secondary surgical sites with increased morbidity and discomfort, necessitating patient sedation in many cases. All of these factors contribute to an increase in the length and cost of treatment delivery. (3)

Edentulous ridges can be split and expanded to widen the width of the narrow ridge so that a standard-sized implant can be placed. Osseous ridge expansion with a piezoelectric-driven saw, followed by bone cut expansion with motor-driven expansion screws, can make room for immediate implant placement. To perform precise, minimally traumatic bone surgery, the dental profession was introduced to piezoelectric bone surgery. (4) Traditional approaches for treating narrow alveolar ridges require careful effort and care. Earlier techniques for ridge expansion were performed with chisels, air-driven rotary handpieces, or oscillating saws. (5) Ridge expansion can be difficult when the cortex is dense, as in the mandible. Rotating and oscillating instruments are effective but may damage nerves and arteries. Piezoelectric saws will not significantly damage these structures. Ultrasonically driven saws can cut hard tissues but preserve gingiva, blood vessels, nerves, and sinus membranes from injury. (4) Piezosurgery is suitable for edentulous ridge expansion, bone block section, sinus elevation, nerve lateralization, resective bone surgery, and bone biopsy. The purpose of this article is to demonstrate that piezoelectric surgery and motor-driven screws for edentulous ridge expansion and immediate implant placement may be effective and minimally invasive. (6)

SUBJECTS AND METHODS:

Randomized Clinical trial: Ten patients were assigned to *One- Stage crestal ridge splitting* with simultaneous implant placement

Patient selection:

All the patients who took part in the study had no systemic conditions, good oral hygiene, and were missing one tooth in the anterior maxillary arch with sufficient alveolar ridge height (8 mm) but insufficient alveolar ridge width (3-5 mm) that interfered with traditional straight forward implant placement.

Smoker patients were excluded from the study or if they had uncontrolled general conditions that could affect the surgical outcome.

All patients have explained the nature of the surgical procedure conducted within the study, and informed consent was obtained from every participant.

Treatment protocol:

The preoperative phase included case history, clinical evaluation, preoperative photographs, and the CBCT scan to determine the alveolar ridge morphology. Adequate periodontal management and oral hygiene motivation were given to all patients two weeks before the operation.

A single surgical procedure was performed on each patient, including alveolar ridge expansion/splitting with immediate implant placement.

Under local anesthesia administration, all surgeries were performed (Articaine hydrochloride 4% with 1/100000 epinephrine, septanest, Septodont). All patients were given premedication one hour before the operation with amoxicillin 875mg. /clavulanic acid 125 mg. (Augmentin 1gm tablets/ GlaxoSmithKline) orally.

Surgical procedures: Full-thickness mucoperiosteal flap released labially and palatally at the edentulous area using one crestal incision and two vertical labial incisions.

Crestal ridge splitting: Segmental ridge-split procedure (SRSP) performed as follows: horizontal crestal split using piezoelectric device tips (CS Series) crestal split series sequentially starting from (CS1-6). (CS -1 diameter is 0.55 mm) tip thickness until (CS-6 diameter is 3.75 mm) followed by two vertical bone releases to avoid fracture of the labial cortical plate of bone. After performing the crestal ridge split, small wedge, or spiral drills are used to expand the implant bed, finger pressure on the two plates of bone during drilling procedures tends to provide stabilization to the facial plate of the bone figure (1).

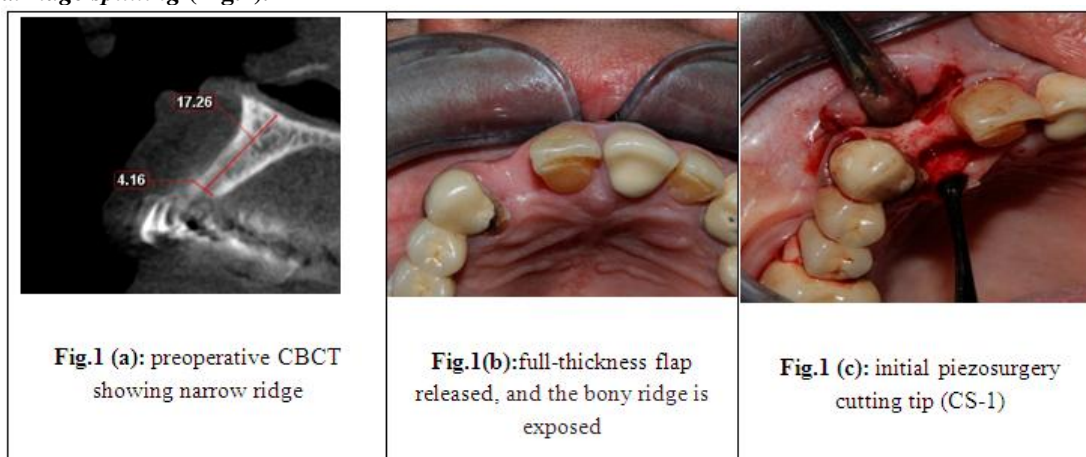
Implant installation:

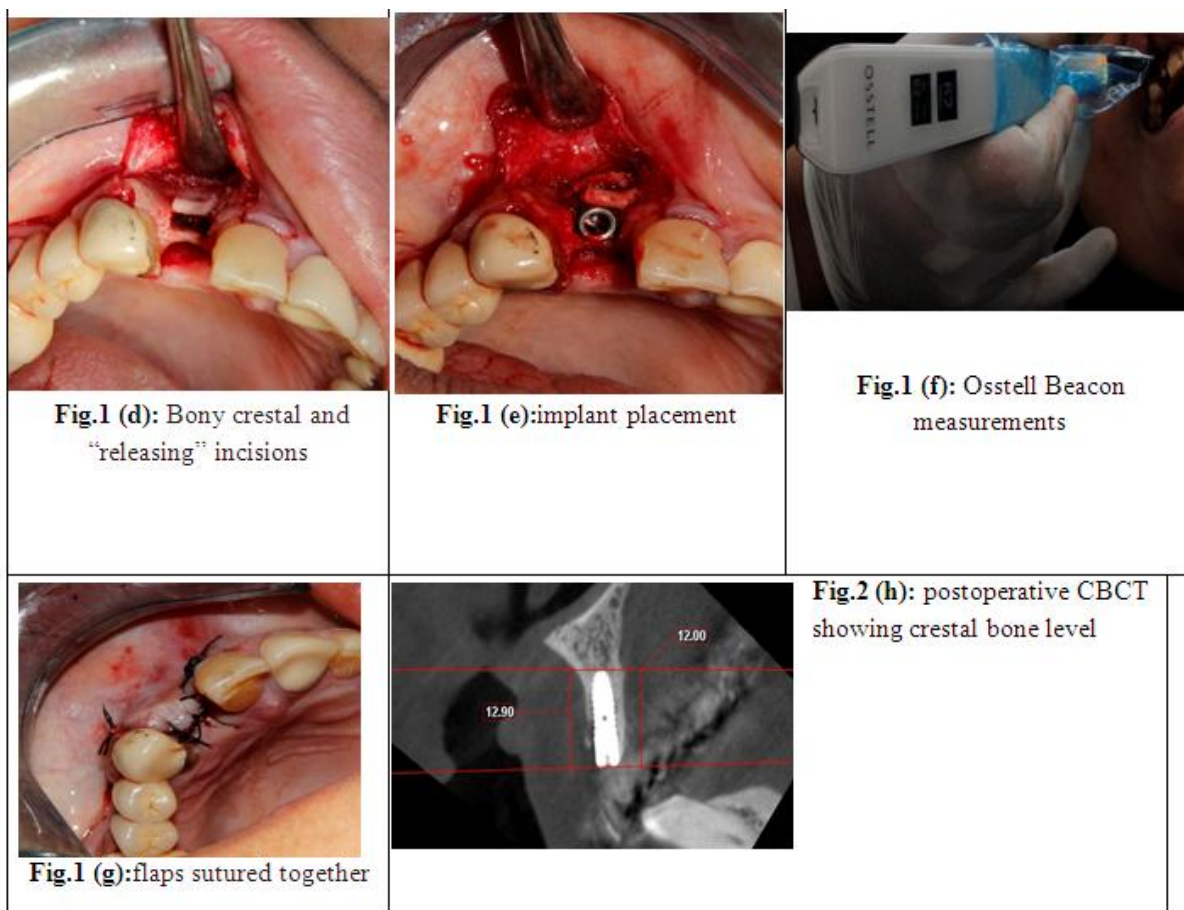
All the implants utilized in this study were the same size (3.5mm x 12mm) Nucleoss (T6) bone level implant the flaps were closed by simple interrupted sutures using 3/0 suture silk material. The sutures were removed two weeks later following surgery. patients were instructed to administer acetaminophen 1g every 8 hours.

Followed by a postoperative CBCT scan taken to check adequate implant placement and postoperative measurements.

Clinical and radiographic assessment: Osstell Beacon® (integration diagnostics AB, Gutenberg, Sweden) was used to evaluate implant stability immediately after surgery, four months later, and six months later. For each implant, the ISQ was measured labially, palatally, distally, and mesially, and the mean value was calculated. The radiographic measurements are as follows, from the implant shoulder to the crest of the alveolar bone.

crestal ridge splitting (Fig.1):





II. Results:

one year following the implant installation, the implants' survival rate was 100%.

Comparison between the different periods according to ISQ values:

Table (A) showed a comparison between the periods according to ISQ. At baseline, 4, and 6 months, there was a statistically significant difference in mean ISQ.

ISQ	Ridge splitting	p
Baseline	63.20 ± 2.10	<0.001*
4 months	68.80 ± 1.99	<0.001*
6 months	70.10 ± 2.13	<0.001*

*: Statistically significant at $p \leq 0.05$.

Table (B): Comparison between the different periods according to change in labial marginal bone level (mm)

change in labial marginal bone level (mm)	Ridge splitting	p
6 months	-0.88 ± 0.17	0.002*
One year	-1.28 ± 0.19	0.002*

p *: Statistically significant at $p \leq 0.05$

Table (B) showed a comparison between the periods according to change in labial marginal bone level (mm) after six months of follow-ups and one year, there was a statistically meaningful difference in mean labial marginal bone level (mm).

III. Discussion:

many studies have reported higher success rates and many advantages for implant placement utilizing the segmental ridge splitting technique for alveolar ridge splitting/ expansion. (7) (8)

In the alveolar ridges that are approximately 4 mm thick, this technique allows the placement of implants in the host bone within the intercortical space. The implants are protected by the solid cortical layers, thus allowing better host bone contact with the implant surface area. The intercortical space is made up of cancellous bone, which is well vascularized and highly osteogenic.

An implant bed preparation in ridges of the same thickness using the conventional twist drills for 3.5-mm-diameter implants would be expected to induce bone dehiscence requiring additional bone augmentation. The piezoelectric osteotomy used in this study offered alternative instrumentation for ridge augmentation. The study showed that the piezoelectric surgery unit and its inserts permitted thinner, more precise cuts, and less vibration and tissue damage than surgical saws or burs as noted in previous studies that employed the same surgical units. (9) (10)

In the present study, the implant stability was evaluated using Osstell® device. Regarding the primary implant, stability showed a statistically significant difference in (ISQ) values in the study periods. the mean ISQ value at baseline was 63.20 ± 2.10 at four months was 68.80 ± 1.99 , ISQ value at six months was 70.10 ± 2.13 these results follow the findings of **Vinh Giap et.al (2016)** who concluded that implant stability is coincide with our results. (11)

Crestal bone level surrounding dental implants has been considered one of the implant successes. The commonly used criteria for implant success should present with less than 1.5mm of crestal bone loss during the 1st year. Besides, less than 0.2 every year and a maximum of two mm over five years as reported by **Albrektsson & Isidor (1994)**(12).

Ridge splitting group the mean crestal bone level value at six months was 0.88 ± 0.17 . The mean crestal bone level value of the Ridge splitting group one year after the prosthetic installation was 1.28 ± 0.19 . The following success criteria are defined by **Albrektsson & Isidor (1994)**.

Besides, these findings were compatible with results obtained by **Renzo Bassetti et.al (2002)** (13). Who placed twenty-two implants by crestal Ridge splitting procedure and during the follow-up of six months after placement, the mean value of crestal bone loss was -1.68 ± 0.90 mm.

IV. Conclusion:

The Crestal ridge splitting technique showed the ability to manage narrow alveolar ridge, and implant stability, around implants without a bone fracture or fenestration. This study showed the amount of implant stability obtained with Versah bur was superior to piezosurgery.

References:

- [1]. Brånemark PI, Hansson BO, Adell R, Breine U, Lindström J, Hallén O, et al. Osseointegrated implants in the treatment of the edentulous jaw. Experience from a 10-year period. *Scand J Plast Reconstr Surg Suppl.* 1977;16:1–132.
- [2]. Marx RE, Carlson ER, Eichstaedt RM, Schimmele SR, Strauss JE, Georgeff KR. Platelet-rich plasma: Growth factor enhancement for bone grafts. *Oral Surg Oral Med Oral Pathol Oral Radiol Endod.* 1998 Jun;85(6):638–46.
- [3]. Zijdeveld SA, ten Bruggenkate CM, van Den Bergh JPA, Schulten EAJM. Fractures of the iliac crest after split-thickness bone grafting for preprosthetic surgery: report of 3 cases and review of the literature. *J oral Maxillofac Surg Off J Am Assoc Oral Maxillofac Surg.* 2004 Jul;62(7):781–6.
- [4]. Vercellotti T. Piezoelectric surgery in implantology: a case report--a new piezoelectric ridge expansion technique. *Int J Periodontics Restorative Dent.* 2000 Aug;20(4):358–65.
- [5]. Coatoam GW, Mariotti A. The Segmental Ridge-Split Procedure. *J Periodontol.* 2003 May;74(5):757–70.
- [6]. Vercellotti T, Nevins ML, Kim DM, Nevins M, Wada K, Schenk RK, et al. Osseous response following resective therapy with piezosurgery. *Int J Periodontics Restorative Dent.* 2005 Dec;25(6):543–9.
- [7]. Sethi A, Kaus T. Maxillary ridge expansion with simultaneous implant placement: 5-year results of an ongoing clinical study. *Int J Oral Maxillofac Implants.* 2000;15(4):491–9.
- [8]. Chiapasco M, Ferrini F, Casentini P, Accardi S, Zaniboni M. Dental implants placed in expanded narrow edentulous ridges with the Extension Crest device. A 1-3-year multicenter follow-up study. *Clin Oral Implants Res.* 2006 Jun;17(3):265–72.
- [9]. Sohn D-S, Ahn M-R, Lee W-H, Yeo D-S, Lim S-Y. Piezoelectric osteotomy for intraoral harvesting of bone blocks. *Int J Periodontics Restorative Dent.* 2007 Apr;27(2):127–31.
- [10]. Stübinger S, Landes C, Seitz O, Zeilhofer H-F, Sader R. [Ultrasonic bone cutting in oral surgery: a review of 60 cases]. *Ultraschall Med.* 2008 Feb;29(1):66–71.
- [11]. Nguyen VG, von Krockow N, Weigl P, Depprich R. Lateral Alveolar Ridge Expansion in the Anterior Maxilla Using Piezoelectric Surgery for Immediate Implant Placement. *Int J Oral Maxillofac Implants.* 2016;31(3):687–99.
- [12]. Albrektsson, T. and Isidor, F. (1994) Consensus Report of Session IV. In Lang, N.P. and Karring, T., Eds., *Proceedings of the First European Workshop on Periodontology*, Quintessence Publishing, London, 365-369. - References - Scientific Research Publishin.
- [13]. Bassetti R, Bassetti M, Mericske-Stern R, Enkling N. Piezoelectric Alveolar Ridge-Splitting Technique with Simultaneous Implant Placement: A Cohort Study with 2-Year Radiographic Results. *Int J Oral Maxillofac Implants.* 2013;28(6):1570–80.