

Colonic Conduit for Corrosive Esophageal Stricture

Dr.P.Thirumoorthy MS Postgraduate

Prof.Dr.K.Kesavalingam M.S

Department of general surgery, GMKMCH, Salem, Tamil Nadu

Abstract:

Introduction: Alkaline caustics and acids are the most common chemicals implicated in caustic burns. Stricture formation with inability to swallow food after the injury is inevitable in some cases. As for the complications and ineffectiveness of the dilation in more severe strictures, colonic transposition serves as a better replacement for the esophagus.

Aim: This study aims to study the adequacy of colonic transposition done for cases of corrosive esophageal strictures and to discuss the complications and their management and the outcome of therapeutic measures employed.

Materials and Methods: A total of eight adults with corrosive esophageal strictures were studied at Government Mohan kumaramangalam medical college and hospital for 2 years from October 2019 to November 2021.

Results: Of the eight patients, who were studied, five were male and three were female. Intentional mode of corrosive intake was higher (n = 5) and acidic corrosive was more commonly ingested (n = 6). Upper esophageal stricture was seen in five patients. Colonic transposition + feeding jejunostomy (FJ) was done in eight patients, of which two patients underwent transhiatal esophagectomy+colonic transposition+FJ. Complications were seen in 50% of the patients with 38% having anastomotic leak and 12% having anastomotic stricture which were managed conservatively. All the eight patients had improved outcome of life. **Conclusion:** Colonic transposition is a good and effective conduit for the management of corrosive esophageal strictures.

Date of Submission: 05-11-2021

Date of Acceptance: 20-11-2021

I. Introduction;

Digestive injury and complications resulting from caustic ingestion is the most challenging clinical situations encountered in gastroenterology. The commonest chemicals implicated in gastrointestinal caustic injury are alkaline and acid agents. The caustic ingestion is voluntarily and in suicidal intent in most situations in adult. In fact, successful management of these patients requires multidisciplinary therapeutic approach including psychiatric support. Early diagnosis and adequate treatment are the keys of success particularly in severe injury which can lead to death resulted from complications. Ct scan abdomino-thoracic has an important value to diagnose and precise the trans-mural character of the esophageal lesion thus reducing excessive esophageal excision and digestive complications. Stricture formation is inevitable in some cases and the first treatment of this stricture is the dilations. Every effort should be made to retain the native esophagus and reconstructive surgery is required for ineffectiveness, complications or lack of the dilations. The objective of surgery is to establish both digestive continuity and swallowing function. Establish the gut continuity needs the use of an abdominal digestive organ. The time of surgery for caustic stricture is still under controversy. However suggest that the most beneficial time for surgery is not less than 3 months for the esophagus and 6 months for the pharynx. Despite the reduction in operative mortality, the morbidity rate is still high. The accuracy of the surgical technique and the experiences of surgeon are the most important factors that may impact outcome in esophageal reconstructive surgery.

In this study, we aimed to study the adequacy of colonic transposition done for cases of corrosive esophageal strictures, to discuss complications and their management and the outcome of therapeutic measures employed.

II. Materials And Method:

A retrospective study was conducted at Government mohan kumaramangalam Medical College and Hospital, salem, for a duration of 2 years from October 2019 to November 2021. A total of eight patients were included in the study that had developed esophageal strictures secondary to corrosive intake. The age of the

patients ranged from 18 to 72 years with a median of 37 years. The following parameters were evaluated for each patient:

- Time of presentation after corrosive ingestion
- Investigations - upper gastrointestinal (UGI) endoscopy and barium swallow
- Interventions performed - operative management (Colonic transposition)
- Complications and their management
- Length of hospital stay
- Readmission
- Outcome.

Of the eight patients, 37.5% were female and 62.5% were male with a ratio of female:male as 3:5. The time of presentation of the patients after corrosive ingestion was 2 months–2 years with a median of 6 months. Of the eight patients, five patients had intentionally ingested the corrosive substance while three patients had ingested it accidentally. Six of the patients gave a history of intake of the acidic corrosives while two patients had taken alkaline corrosives .

All the eight patients had developed esophageal strictures, and the esophageal segment involved was upper 1/3rd of the esophagus in five patients, middle 1/3rd of the esophagus in one patient, and lower 1/3rd of the esophagus in two patients.

The patients were investigated with UGI endoscopy and barium swallow . All the patients underwent UGI endoscopy and dilatation with a Savary-Gilliard dilator No. 7 preoperatively. 3 patients (21.9%) were stented preoperatively.

All the eight patients underwent definitive surgeries at a later date. Six patients underwent colonic transposition + feeding jejunostomy (FJ) and two patients underwent transhiatal esophagectomy + colonic transposition + FJ. Three patients underwent a two-stage procedure and five patients underwent a definitive procedure at the first stage itself. All the eight patients were started orally on post-operative day (POD3).

Preoperative evaluation

Preoperative colonoscopy is recommended to explore colon in patient for whom a colonic interposition was planned. Mesenteric angiography is recommended for patient older than 60 years and for patient with prior intestinal resection or peripheral vascular disease. Angiography is very helpful in outlining the vascular arcade of the intestinal segment to be interposed in patient who had previous colonic resection. Patients candidate for esophageal surgery are at high risk to develop malnutrition. Therefore the preoperative evaluation of the nutritional status of these patients is primordial. Poor nutritional status is associated with high rate of postoperative complications. The nutritional improvement of patient prior to surgery is highly recommended and peri-operative introduction of nutritional supports have a direct impact on postoperative results. Both parenteral and enteral nutrition can be used however the enteral nutrition is the preferred one to treat malnutrition and to improve patient nutritional status. The mechanical bowel preparation is so performed 48 hours before time of surgery.

Choice of replacement

The Decision of which organ to use for esophageal reconstruction is based on multiple factors: esophagus disease, length of reconstruction, digestive organ available and surgeon experience and preference. Stomach, colon and jejunum are used to restore digestive continuity after esophagectomy or to bypass malignant and benign esophageal stricture.

Jejunal interposition is seldom used because of the difficulty for operation since blood vessels of jejunum are too thin and easier to be affected after anastomosis. Furthermore, the jejunum is fragile to the erosion of acid in a long run, so the jejunum should not be the first choice. Therefore the best indication for free jejunal graft is the reconstruction of the cervical esophageal portion .Some authors considered that gastric interposition was the procedure of choice to establish digestive continuity for patient with both benign and malignant esophageal disease. The gastric reconstruction is widely employed because of its simplicity and it requires less time to achieve the procedure as compared to colon reconstruction. However, stomach has the disadvantages of long term gastro esophageal reflux which can lead to complications such esophageal ulceration and anastomotic stenosis. In case of diffused injuries with pharyngo-esophageal stenosis, the stomach is not sufficiently long to reach the basis of the tongue in order to perform a pharyngoplasty. In other hand, the stomach is often injured during massive caustic ingestion and its use as an esophageal substitute is often impossible.

The colon is the first digestive organ used to replace diseased esophagus and many authors have suggested that the colon is the best conduit to construct the esophagus and to restore swallowing function because mainly of an increased incidence of aspiration and reflux with gastric conduit .The colon reconstruction lies on the anatomic and physiologic features of colon , including its relatively straight mesentery, increased length that can be mobilized on its vascular pedicle, its low incidence of disease, its resistance to chronic gastric

reflux and the long-term good functional results of colon reconstruction. However the completion of colon reconstruction requires more time to achieve the procedure as compared to gastric reconstruction. Both right and left colon can be used however the left colon is more preferable and this preference lies on the near-invariability of the left colonic artery in contrast with the vascular pattern of the right colon and its smaller lumen which matches perfectly with the esophageal lumen. Isoperistaltic left colonic graft based on the left colic artery is first choice. When performed by experienced surgeons, substernal left isoperistaltic colon reconstruction is the surgical procedure of choice to reconstruct the scarred esophagus with low mortality, acceptable morbidity and good functional results.

Route of reconstruction:

During esophageal reconstruction, there are three placement sites of graft namely the posterior mediastinum, the substernal tunnel and the subcutaneous space. The subcutaneous route is the longest and has strong angulation at its cervical and abdominal extremity, so this route is at high risk of graft necrosis. As reported, the high incidence of graft necrosis associated with the subcutaneous route suggests that only when other routes are not available or suitable; the subcutaneous route should be used. The posterior mediastinum and the substernal route are the two most commonly route used in esophageal reconstruction. The posterior mediastinum is the shortest and most direct route, thereby relaxing tension to the cervical anastomosis site and reducing thus the kinking and twisting risk of graft vascular pedicle. The use of the posterior mediastinum needs the ablation of the native esophagus. In some situations, the access to the posterior mediastinum is difficult or technically not possible. This route also has a high rate of mortality if graft necrosis or anastomotic leakage occurs, and it is naturally not indicated for palliative cases because the posterior mediastinum is a tumor bed.

The disadvantages of the posterior mediastinal route have prompted some surgeons to advocate the substernal approach. The substernal route has been an alternative for delayed esophageal reconstruction or when access to the posterior mediastinum is difficult or technically not possible. It is easy to achieve the substernal route without need to thoracic approach. Substernal route is an ideal indication for esophageal palliative surgery. This route is widely employed in caustic stricture because the scarred esophagus is often left in place and its ablation is associated with high risk of operative complications. The substernal route has a biggest disadvantage of potential risk of compression of the graft at the thoracic inlet leading mechanical graft ischemia. To ensure there is no risk of compression, enlarging the thoracic inlet by inlet by removing the left half of manubrium and internal third of clavicle is highly suggested when the substernal approach is considered. This procedure allows to easy access to the left internal thoracic vessels which can be useful for supercharge of graft by performing microvessel anastomosis.

The posterior mediastinal and retrosternal routes are associated with similar rates of immediate postoperative complications. Compared to posterior mediastinum, the substernal route is associated with a slightly higher rate of cervical anastomotic leak related partially to the compression of the graft at the level of thoracic inlet. However, the opening of the thoracic inlet may reduce the incidence of cervical leak and its enlargement is suggested by many surgeons performing esophageal substernal reconstruction. Regarding to functional results, both posterior mediastinal and retrosternal routes are associated with similar long-term outcomes. The posterior mediastinum is preferred for immediate reconstruction after esophagectomy and the substernal route for delayed reconstruction. However the selection of the pull-up route should be based on the nature of disease, benign or malignant and the functional aspect. Regardless of the route used for reconstruction, it is important to take care of checking constantly the position of the graft vessels to ensure there is no mechanical compression that may impair the vascular supply of the graft, and to select a graft with sufficient length avoiding thus tension at the anastomotic site.

In our institution, we use the substernal approach for esophageal malignant conditions considering the possibility of mediastinal recurrence and for caustic stricture when the diseased esophagus is left in place. However, when using the substernal approach, we feel it is essential to enlarge the thoracic inlet by removing the left half of the manubrium and the sternal head of the left clavicle to ensure there is no compression on the interposed grafted. Although and when necessary the excision should be extended to the medial end of the first and second rib in order to perform a vascular supercharge of the graft.

Colonic Interposition for Replacement of Esophagus

An upper midline laparotomy incision and a left cervical oblique incision were made along the inner border of the sternocleidomastoid muscle. The cervical esophagus was explored and transected above the level of the diseased esophagus. A sufficient length of the isoperistaltic loop of the transverse colon for graft was mobilized from colonic mesentery after ligation of the left and middle colic arteries. Resection of parts of the sternum should be considered for colonic interposition to allow a spacious room for the graft colon, if the sternum exerts pressure on the graft colon.

The grafted colon was mobilized through a substernal tunnel and esophagocolic anastomosis was done in an end-to-end fashion with hand-sewn, single layer anastomosis. Cologastric anastomosis was performed over the midportion of the anterior wall of the stomach and the anastomosis between the distal portion of graft and a Roux-en-Y loop of jejunum was performed. The resected ends of the colon were closed by a colocolic anastomosis. An FJ was performed. A corrugated drain was placed at the level of esophagocolic anastomosis in the neck. The abdomen was closed after placement of abdominal drains in the subhepatic space and the pelvis.

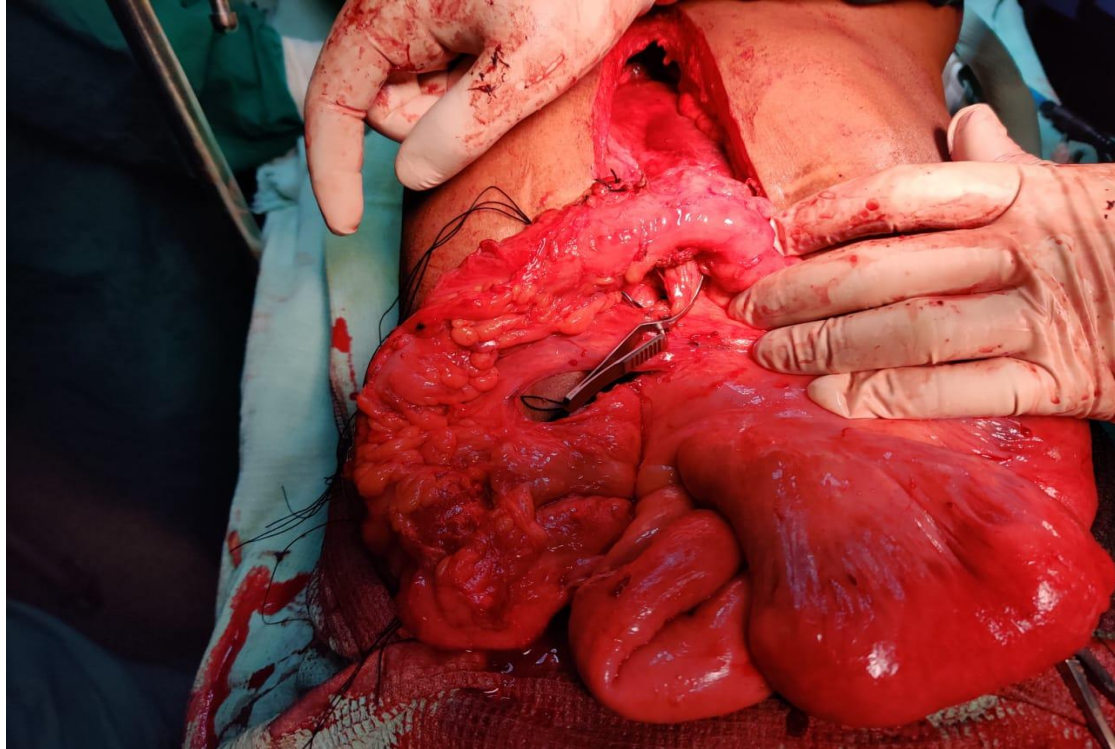


Figure: 1 Colon conduit based on left colic artery

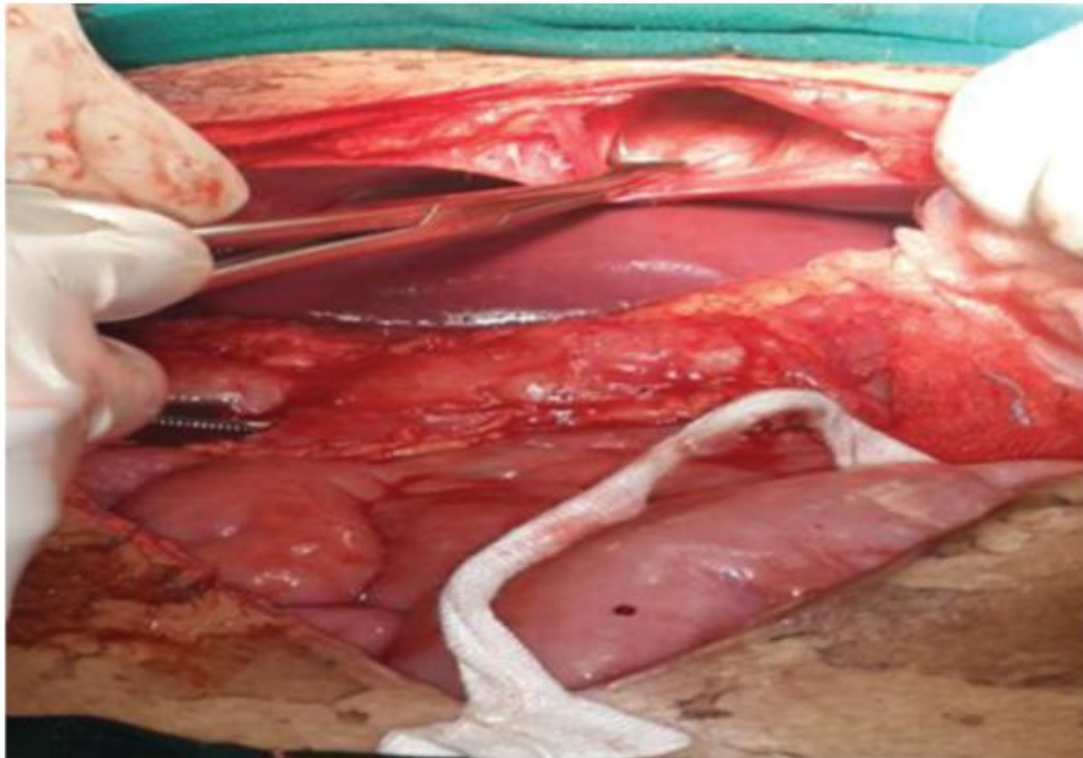


Figure:2 Substernal tunnel creation

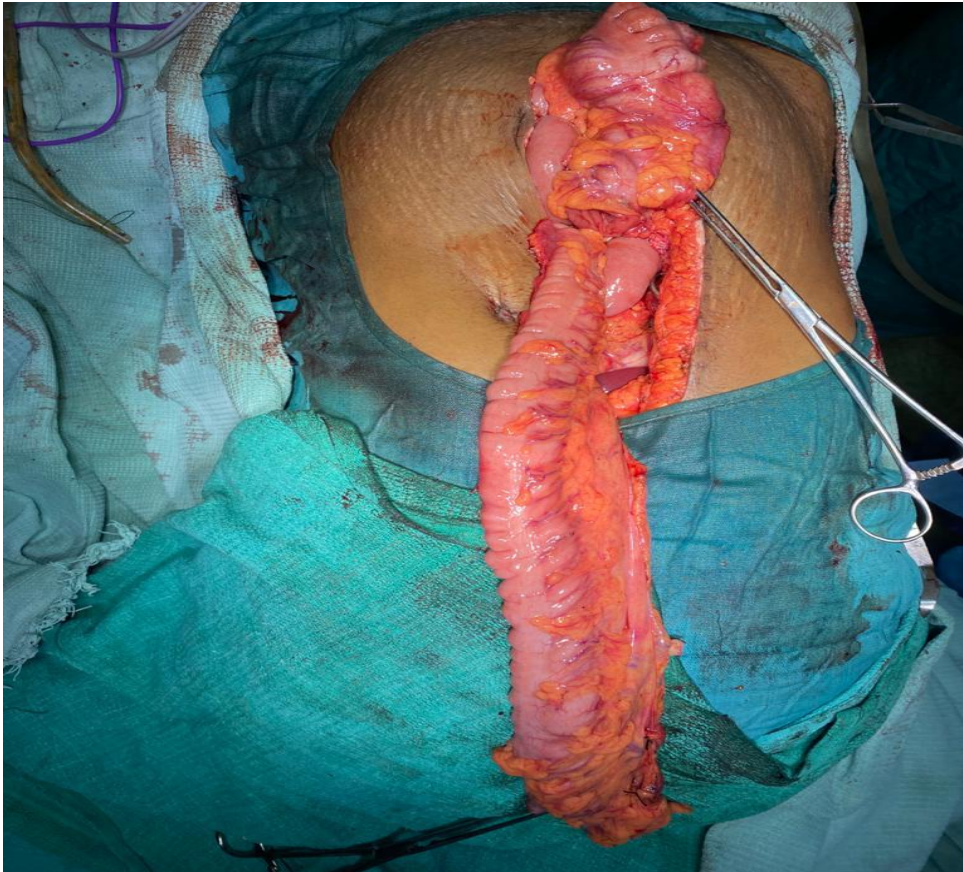


Figure:3 Length of colon conduit

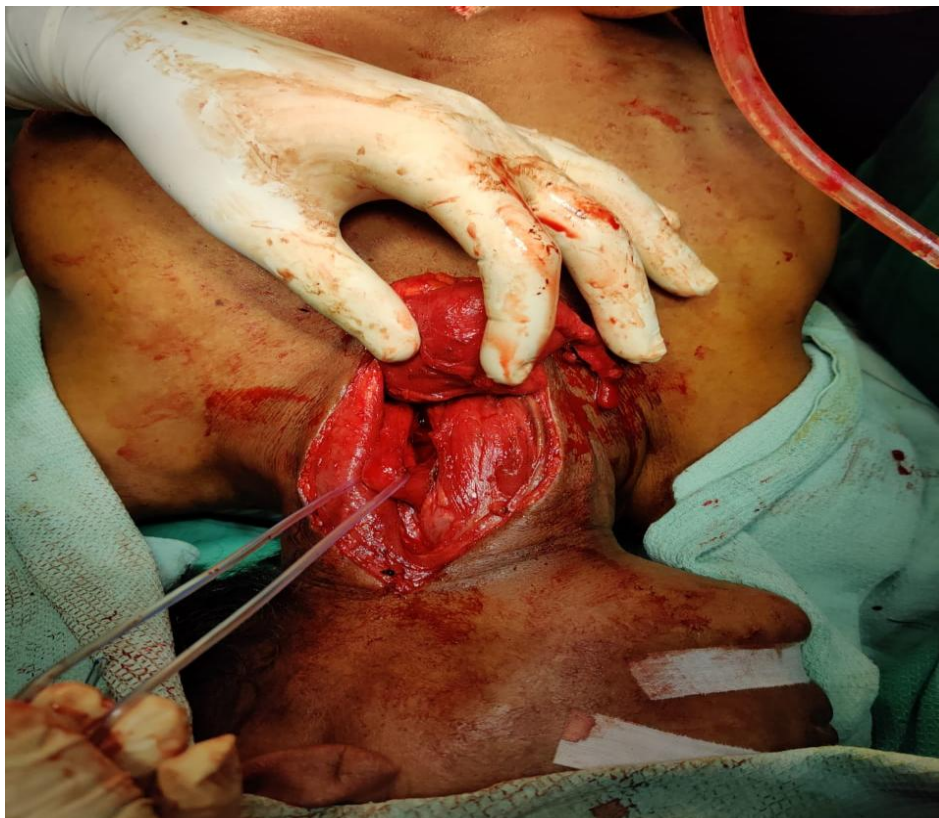

Figure:4 cervical oesophagus mobilization

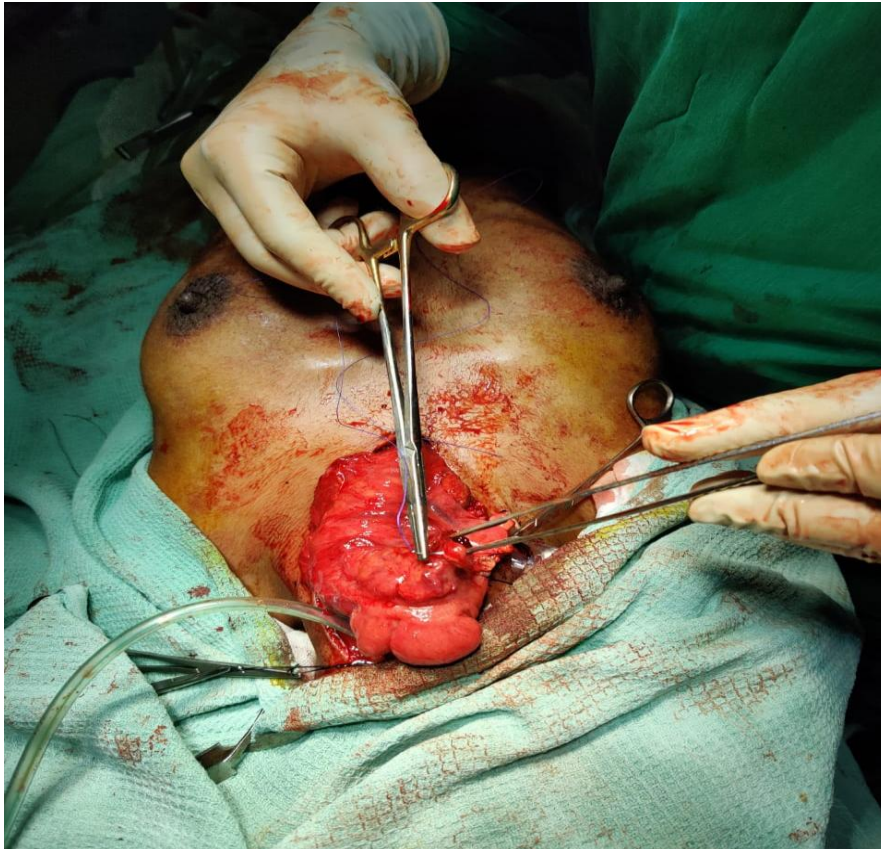

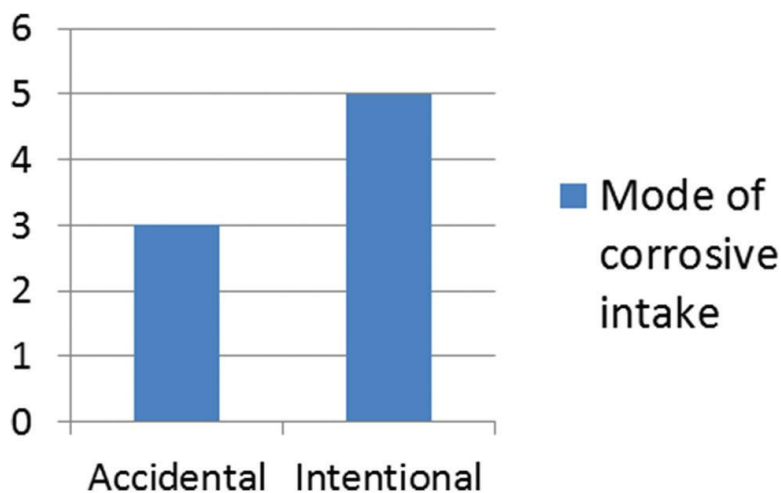
Figure:5 Cervical oesophago-colic anastomosis

III. Results:

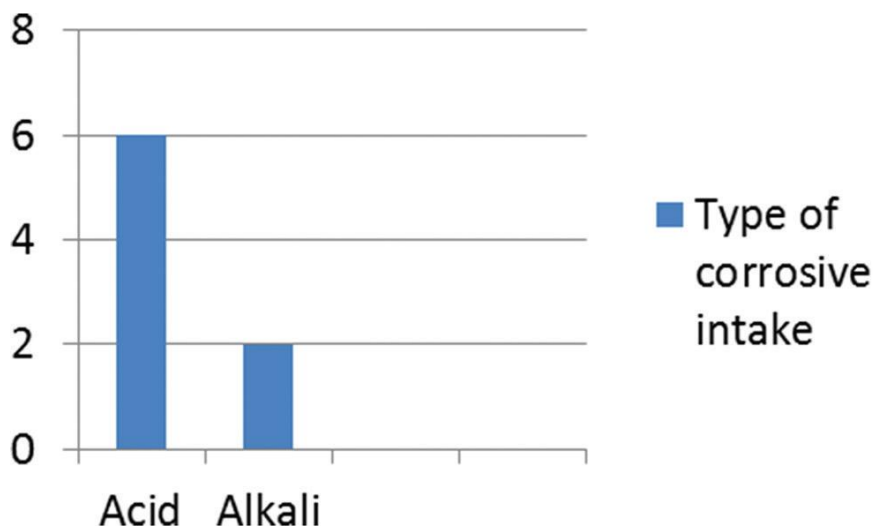
After the initial and post-operative management of the eight patients, 4 patients (50%) had no complications and had an uneventful post-operative period. 4 patients (50%) developed complications, of which 3 patients had an anastomotic leak on POD3, POD4, and POD5, and one patient developed an esophageal stricture at the anastomotic site.

The three patients with the anastomotic leak were managed conservatively with NPO status, parenteral nutrition, and IV antibiotics for 5 days. The anastomotic leak resolved and the patient was started orally. One patient who developed an anastomotic stricture with complaints of dysphagia underwent esophagogastroduodenoscopy + controlled radial expansion balloon dilatation . The patient was started orally 2-day post-procedure with resolution of dysphagia.

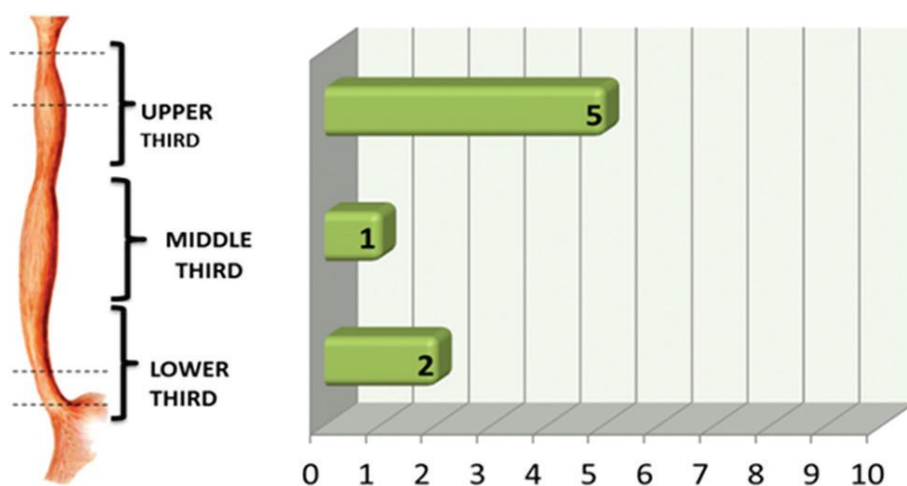
The length of the hospital stay was 10–30 days with an average of 20 days.



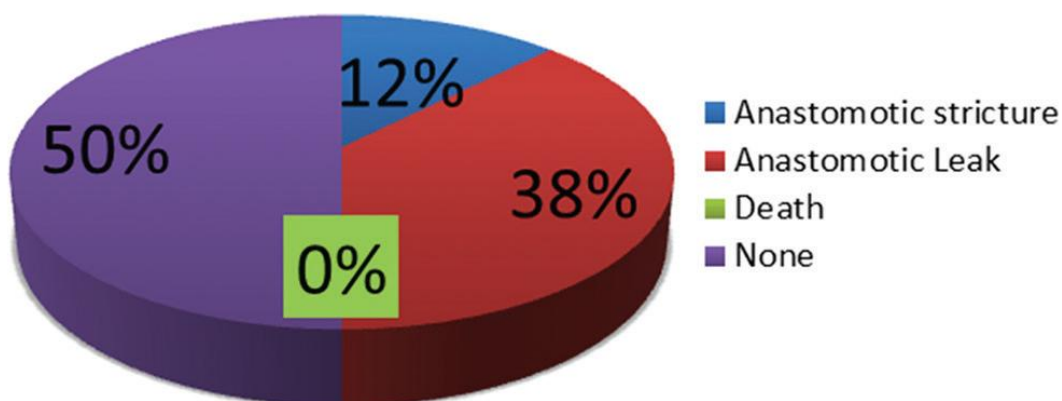
Graph:1 Mode of corrosive intake



Graph:2 type of corrosive intake



Graph:3 Oesophageal segment involment



Graph:4 Complications after post colonic transposition

Mortality and Morbidity

The mortality for esophageal reconstructive surgery was increasingly improved over time and the decrease of mortality rate was related to operative technique improvement and anaesthetic progress. The main cause of death was graft necrosis, followed by sepsis and adult respiratory distress syndrome . Regarding to pulmonary complications, the incidence has been recently decreased by improvements in preoperative

management. The most severe complication is the graft necrosis which is associated with high rate of death in absence of early diagnosis and adequate management. This disastrous complication is more frequent after colon interposition and the incidence of necrosis in gastric and colonic reconstructions was 1% and 2.4 respectively. Compared to gastric interposition, colon reconstruction is surgical procedure with slightly high risk of graft necrosis. The difficulty is how to complete further digestive re-reconstruction which requires a panel of complex surgical procedures. The precautions are the rule to prevent graft necrosis, so meticulous dissection, selection of an optimal graft and avoiding twist by checking the position of the graft vessels are highly recommended. In other hand, cervical leakage is the most common complication encountered in esophageal reconstruction surgery and is comparable in both gastric and colon reconstruction. The leakage heals spontaneously and surgery is exceptionally needed. Many improving nutritional conditions may reduce the risk to develop anastomotic leakage. Anastomotic stricture was less observed than leakage and high percentage of stricture resulted of healed leakage. The anastomotic stricture should be treated conservatively and the first treatment is endoscopic balloon dilatation. Therefore the surgery is indicated after lack of dilatation. The main late complication of colonic interposition is the redundancy of the interposed colon graft . Redundancy leads to retention of food and liquid in the graft, causing dysphagia, regurgitation and nocturnal aspiration and surgery is frequently needed to treat redundancy.

Follow up:

Barium swallow study was routinely carried out to evaluate patency of conduit and condition of anastomosis 10 days after reconstruction of esophagus. After discharge from the hospital, patients were monitored in outpatient clinic. The ability to swallow, body weight, and activity were recorded. The length of follow-up ranged from 1 month to 7 years. Data for the follow-up study was obtained through clinic visits and questionnaires. Complications developed post operatively or during follow-up were considered operative morbidity and death within one month after operation was defined as operative mortality

IV. Discussion:

Adequate nutrition and careful post-operative care are important for the healing process of anastomosis. Gastrostomy or jejunostomy must be performed for the nutrition of patients. The main criteria for a successful anastomosis are a well-vascularized conduit and a tension-free anastomosis. Hence, an adequate length of substitutes must be prepared.

Although the stomach is considered as an ideal replacement for the esophagus, more and more surgeons are advocating the use of colon as a transposition graft. The left colon has been considered by many surgeons to be a preferable conduit. With good blood supply and improved somatic growth, colon is long enough for esophageal replacement, and it causes fewer late complications of esophagitis and stricture because of the resistance to acid. However, the left colon interposition used in an antiperistaltic fashion, may cause inflammation of the anastomosis, and affect the healing process. The colon could offer potential advantages over other organs and is believed to be an ideal organ for the replacement.

In our study, we dealt with eight cases of esophageal corrosive injury and all of them underwent transhiatal esophagectomy and colonoscopic transposition as a curative procedure. 50% of patients had no complications and the rest 50% with complications were managed conservatively and by interventional procedures. The rate of mortality and relaparotomy was nil. Hence, the colonic conduit for esophageal replacement is a preferable and safe option.

V. Conclusion:

The most severe caustic injuries are caused by Strong acid or alkali ingestion especially in suicide attempts. The early endoscopic evaluation of patients provides accurate diagnosis and permit to define an appropriate therapeutic strategy to prevent complications (early operation). The dilations constitute the first treatment of esophageal stricture. Esophageal reconstructive surgery is indicated when stricture is so severe and after failure of dilations. The goal of this surgery is to restore digestive continuity and good swallowing function with acceptable mortality and morbidity. Both gastric and colon reconstruction procedures can be used to establish digestive continuity after esophagectomy or to bypass diseased esophagus .The selection of the surgical procedure essentially depends on the anatomic conditions of patient and the surgeon preference.

Reference:

- [1]. Ertekin C, Alimoglu O, Akyildiz H (2004) The results of caustic ingestions. *Hepato gastroenterology* 51(59): 1397-1400.
- [2]. Zhou JH, Jiang YG, Wang RW (2005) Management of corrosive esophageal burns in 149 cases. *J Thorac Cardiovasc Surg* 130(2): 449- 455.
- [3]. Boukerrouche A (2016) A 15-year Personal Experience of Esophageal Reconstruction by Left Colic Artery-dependent Colic Graft for Caustic Stricture: Surgical Technique and Postoperative Results. *Journal of GHR* 5(1): 1931-1937.
- [4]. Boukerrouche A (2015) Complications Associated with Enteral Nutrition Using Tube Jejunostomy after Esophageal Reconstruction. *J Gastrointest Dig Syst* 5: 252.

- [5]. Kight CE (2008) Nutrition considerations in esophagectomy patients. *Nutr Clin Pract* 23(5): 521-528.
- [6]. Schilling MK, Mettler D, Redaelli C (1997) Circulatory and anatomic differences among experimental gastric tubes as esophageal replacement. *World J Surg* 21(9): 992-997.
- [7]. Collard JM, Tinton N, Malaise J (1995) Esophageal replacement: gastric tube or whole stomach? *Ann Thorac Surg* 60(2): 261-266.
- [8]. Urschel JD, Blewett CJ, Bennett WF, Miller JD, Young JE (2001) Handsewn or stapled esophagogastric anastomoses after esophagectomy for cancer: meta-analysis of randomized controlled trials. *Dis Esophagus* 14(3-4): 212-217.
- [9]. Thomas P, Fuentes P, Giudicelli R, Reboud E. Colon interposition for esophageal replacement: Current indications and long-term function. *Ann Thorac Surg* 1997;64:757-64.
- [10]. Chen HC, Chana JS, Chang CH, Feng GM, Ho-Asjoe M, Tang YB, *et al.* A new method of subcutaneous placement of free jejunal flaps to reconstruct a diversionary conduit for swallowing in complicated pharyngoesophageal injury. *Plast Reconstr Surg* 2003;112:1528-33.
- [11]. Chen HC, Kuo YR, Hwang TL, Chen HH, Chang CH, Tang YB, *et al.* Microvascular prefabricated free skin flaps for esophageal reconstruction in difficult patients. *Ann Thorac Surg* 1999;67:911-6.
- [12]. Kim YT, Sung SW, Kim JH. Is it necessary to resect the diseased esophagus in performing reconstruction for corrosive esophageal stricture? *Eur J Cardiothorac Surg* 2001;20:1-6.
- [13]. Glasgow JC, Cannon JP, Elkins RC. Colon interposition for benign esophageal disease. *Am J Surg.* 1979;137:175-9.
- [14]. Keenan DJM, Hamilton JRL, Gibbons J, Stevenson HM. Surgery for benign esophageal stricture. *J Thorac Cardiovasc Surg.* 1984;88:182-8.
- [15]. Curet-Scott MJ, Ferguson MK, Little AG, Skinner DB. Colon interposition for benign esophageal disease. *Surgery.* 1987;102:568-74.
- [16]. Mansour KA, Hansen HA, Hersh T, Miller JI Jr, Hatcher CR Jr. Colon interposition for advanced non-malignant esophageal stricture: experience with 40 patients. *Ann Thorac Surg.* 1981;32:584-91.
- [17]. Knezevic JD, Radovanović NS, Simić AP, Kotarac MM, Skrobić OM, Konstantinović VD, *et al.* Colon interposition in the treatment of esophageal caustic strictures: 40 years of experience. *Dis Esophagus.* 2007;20:530-4.

Dr.P.Thirumoorthy MS, *et. al.* "Colonic Conduit for Corrosive Esophageal Stricture." *IOSR Journal of Dental and Medical Sciences (IOSR-JDMS)*, 20(11), 2021, pp. 06-14.