

Management of Placenta Percreta, a conservative approach for low resource centres.

Yash Bahuguna¹, Dharmendra Raut³, Bhupendra Patil², Prachi Koranne²

1 Junior Resident, Department of Obstetrics and Gynaecology, Government Medical College, Akola

2 Assistant Professor, Department of Obstetrics and Gynaecology, Government Medical College, Akola

3 Associate Professor, Department of Obstetrics and Gynaecology, Government Medical College, Akola

Correspondence: Dr. Yash Bahuguna

Junior Resident, Department of Obstetrics and Gynaecology

Govt. Medical College, Akola

Introduction/Abstract

PAS is a group of disorders, previously known as Morbidly Adherent Placenta, which involves pathological invasion of the placental trophoblasts into the uterine wall^[1]. This includes Placenta Accreta, Placenta Increta, and Placenta Percreta, depending on the depth of the invasion of the trophoblasts^[2]. With a pooled incidence of about 1 in 533 deliveries^[3], it is one of the commonest and most morbid conditions in modern obstetrics.

Here we present two similar cases encountered in our setup, summarizing our experience, and outlining our management by preserving the uterus while excising the part of the uterine wall most adherent to the placenta, an approach which can prevent emergent peripartum hysterectomies in young women, which is suitable for low resource settings.

Keywords

Case Report, Placenta Accreta Spectrum, Obstetrics

Date of Submission: 04-10-2021

Date of Acceptance: 18-10-2021

I. Case 1

A 24-year-old woman, Gravida 2 Para 1, with 38 weeks of gestation was referred to our institute due to a Previous Caesarean Section (CS) with Placenta Previa. Her previous caesarean section was done 2 years prior.

On admission, the patient did not complain of any pain in abdomen or bleeding per vaginam. The patient was vitally stable. The fundal height was corresponding to the period of gestation, with the foetus in longitudinal Cephalic presentation. There were no uterine contractions, and the foetal heart rate on examination was 146 beats per minute. A per speculum examination revealed a tightly closed cervical os with no presence of bleeding.

Baseline blood investigation were within normal limits.

Prenatal ultrasound was suggestive of anterior asymmetric complete placenta previa with no features suggestive of PAS, and healthy foetal biometry.

The patient was taken up for elective CS on the following day. After opening the abdomen and separating the bladder from the lower uterine segment, thick vasculature and ballooning of the lower uterine segment was seen, with placental deposits seen in the Uterovesical fold and invading the posterior bladder serosa, suggestive of Placenta Percreta. The incision was taken above the margin of the placental invasion to avoid haemorrhage, and a baby of 2800g was delivered out, cord clamped and cut, and the placenta was kept in situ for the next steps.

Stepwise devascularisation was done by ligation of the uterine vessels on both sides, followed by the internal iliac arteries, to minimise the blood loss during surgery. Dissection and removal of the myometrium adherent to the placenta was done, and a two-layer repair of the remaining myometrium and lower uterine segment was done. As parts of the bladder serosa and uterovesical fold were involved on the left side, ligation of the Left Superior Vesical Artery as a feeding artery was done, and haemostasis was achieved. The patient needed a total of 3 bags (1050ml) of whole blood, 4 bags (600ml) of Fresh Frozen Plasma, and 1g of Tranexamic acid IV, during the procedure.

The postoperative course of the patient was uneventful, she was shifted to the ward. The patient was given Injection Methotrexate 1mg/kg after beta-hCG measurement. She was kept for 10 days postoperatively, for close observation, after which suture removal was done. Patient did not require any blood products postoperatively, and the postoperative laboratory reports were all within normal limits.

Case 2

Our second case involves a 28-year-old Gravida 3 Para 1, with 30 weeks of gestation, came to our centre referred as a case of Placenta Previa with IUGR, and came with complaints of Decreased fetal movements. There were no complaints of pain in abdomen or bleeding per vaginum. History revealed a previous CS done 5 years ago, and a check curettage done 2 years ago.

A physical examination revealed that the patient was vitally stable and abdominal examination revealed a uterus size corresponding to the age of gestation, the baby was in Longitudinal lie and with a Podalic lower pole, Fetal Heart sounds were not appreciable, and a per speculum examination revealed a tightly closed os.

laboratory reports were normal and both Prenatal Ultrasounds were suggestive of Placenta Previa without evidence of Placenta Accreta.

The patient was shifted for emergency LSCS, and after opening the abdomen in layers, the bladder was found to be densely adherent to the lower uterine segment. Careful dissection and downward displacement of the bladder revealed dense vasculature and evidence of Placenta Percreta in the lower uterine segment, with some invasion of the bladder wall and Uterovesical fold. Incision was taken above the line of insertion of the placenta, and an IUD baby of 1750g was delivered by breech extraction, the placenta was kept in situ to reduce bleeding during the subsequent steps.

Stepwise devascularization was done by ligating first the Uterine Arteries and followed by the Internal Iliac Arteries. Both the Superior Vesical Arteries were ligated, to reduce bleeding from the bladder surface, and sutures were taken on the bladder wall to achieve hemostasis. Dissection and removal of the myometrium adherent to the placenta was done, and a two-layer repair of the remaining myometrium and lower uterine segment was done. The course of the ureters was confirmed and absence of placental invasion as well as injuries was noted. Hemostasis was achieved and the abdomen was closed in layers. The patient needed a total of 3 bags (1050ml) of whole blood and 8 bags (1200ml) of fresh frozen plasma.

The postoperative course of the patient was uneventful, she was shifted to the wards. Methotrexate was given to this patient at a dose of 1mg/kg after beta-hCG measurement. Patient did not require any blood products postoperatively, and suture removal was done on the 10th day. Patient was discharged as all laboratory reports were normal.

II. Discussion

Previous Caesarean Section and Placenta Previa are major risk factor for PAS^[4]. As the rates of Caesarean Sections have increased in the past few decades, the rate PAS have risen^[5] and are a constant threat to maternal life and lead to severe morbidities including peripartum hysterectomy.

Peripartum hysterectomy is still a mainstay for management of PAS, but as the number of cases have increased in women of younger age groups; conservative management is being explored to preserve the uterus. With advancements in Interventional radiology, balloon catheterisations of the Iliac Arteries and Abdominal aorta^[6] are useful in centres having such facilities and in patients who have been diagnosed with PAS in earlier ultrasound scans.

When faced with PAS in the setting of an ultrasound negative for PAS, but is evident on surgery, conservative management is possible, albeit difficult. In our approach, like that of Shabana et al.^[7]

1. The delivery was done by taking a Transverse incision above the line of invasion of the placenta
2. The uterus was exteriorised and compressed anteriorly.
3. Bilateral Internal Iliac and Uterine arteries were ligated.
4. Manual removal of placenta with the adherent uterine wall was done.
5. In our case closure of the rest of the uterine wall was done with mattress sutures, after sufficient separation of the bladder towards the pubic symphysis.

This approach is ideal for patients in whom the bladder involvement is minimal and should be avoided if the patient has such invasion, or if invasion of the placenta is in the posterior wall. It is associated with lower blood loss, conservation of the uterus, and better patient outcomes, with lower rates of morbidity and mortality which are commonly associated with Peripartum Hysterectomy.

LEARNING POINTS/TAKE HOME MESSAGES

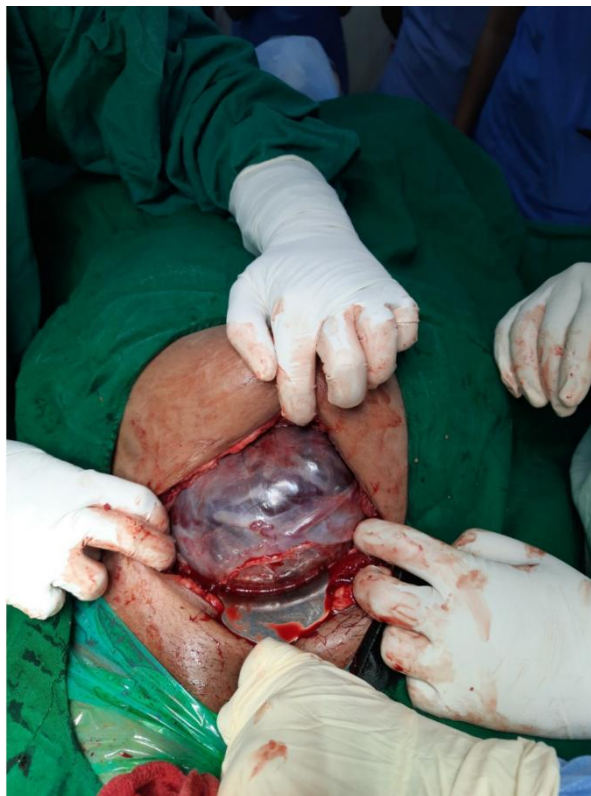1. Conservative Management with resection of placenta with invaded myometrium may help in preventing massive blood loss and preserves subsequent fertility in young patients.
2. In centres with low resources, stepwise devascularisation and resection is a suitable alternative to Abdominal Aorta and Internal Iliac balloon tamponade.

References

- [1]. Placenta accreta spectrum. Obstetric Care Consensus No. 7. American College of Obstetricians and Gynecologists. *ObstetGynecol* 2018;132: e259–75.
- [2]. Luke RK, Sharpe JW, Greene RR. Placenta accreta: The adherent or invasive placenta. *Am J Obstet Gynecol.* 1966; 95:660–668.
- [3]. Wu S, Kocherginsky M, Hibbard JU. Abnormal placentation: twenty-year analysis. *Am J Obstet Gynecol.* 2005 May;192(5):1458-61.
- [4]. Hung TH, Shau WY, Hseih CC, Chiu TH, Hsu JJ, Hseih CC. Risk factors for placenta accreta. *ObstetGynecol* 1999; 93:545-50.
- [5]. Wu S, Kocherginsky M, Hibbard JU. Abnormal placentation: twenty-year analysis. *Am J Obstet Gynecol.* 2005 May;192(5):1458-61.
- [6]. Cali G, Forlani F, Giambanco L, Amico ML, Vallone M, Puccio G, et al. Prophylactic use of intravascular balloon catheters in women with placenta accreta, increta and percreta . *Eur J ObstetGynecolReprodBiol* 2014; 179: 36 – 41.
- [7]. Shabana, A., Fawzy, M. &Refaie, W. Conservative management of placenta percreta: a stepwise approach. *Arch GynecolObstet* 291, 993–998 (2015). <https://doi.org/10.1007/s00404-014-3496-x>

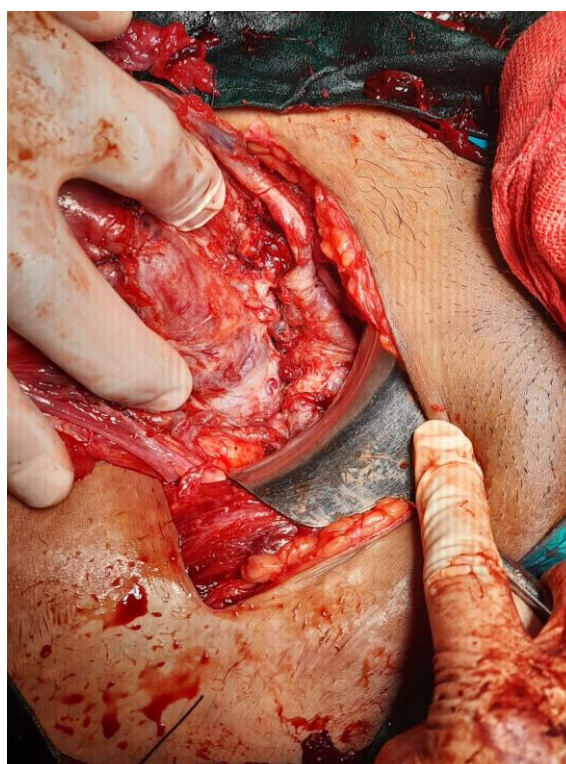
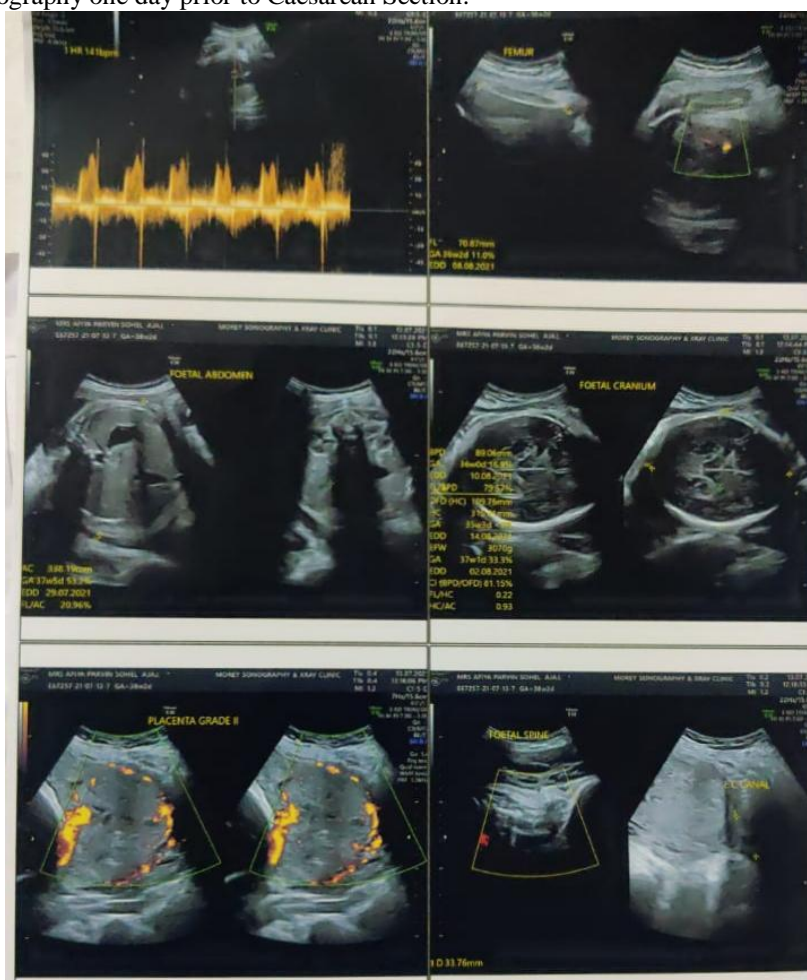FIGURE/VIDEO CAPTIONS

1.



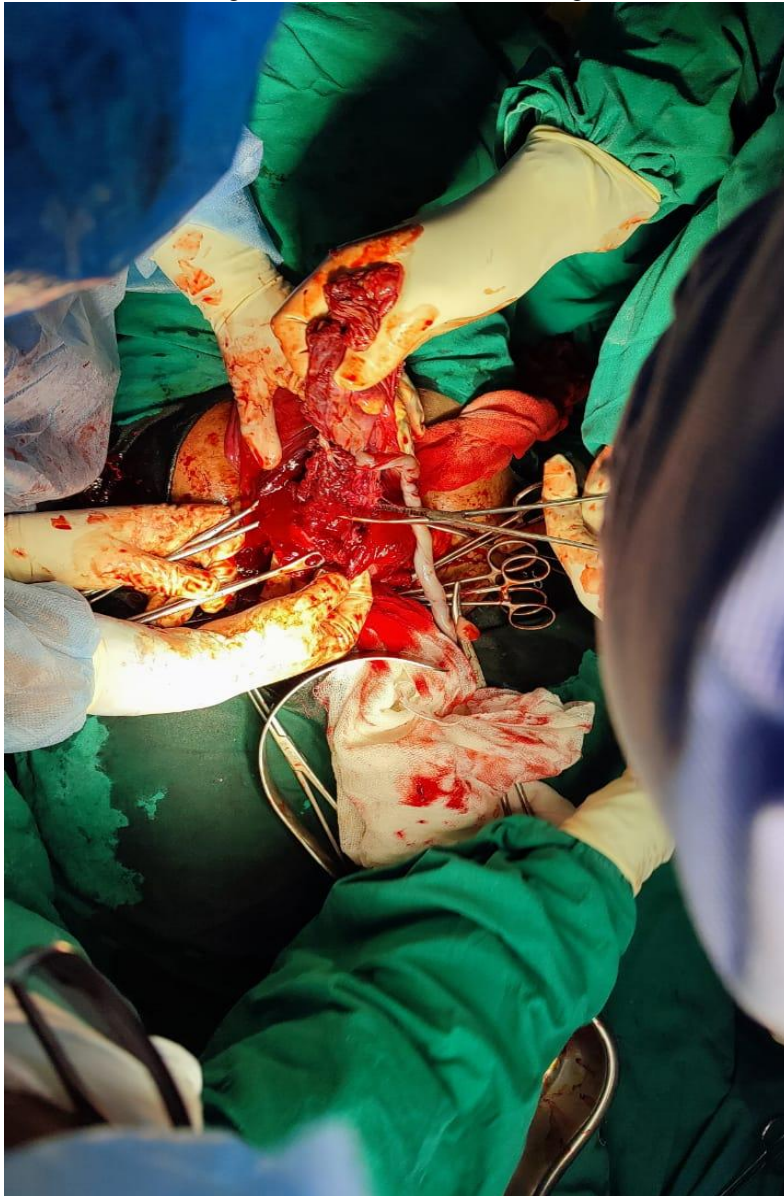
Case 1: Intraoperative findings of thick vasculature and ballooning of the lower segment of uterus, indicating Placenta Percreta

3. Ultrasonography one day prior to Caesarean Section.



Implantation of placenta on uterovesical fold

4. Case 2: Adherent Placenta being removed with lower uterine segment



Dr. YashBahuguna, et. al. "Management of Placenta Percreta, a conservative approach for low resource centres." *IOSR Journal of Dental and Medical Sciences (IOSR-JDMS)*, 20(10), 2021, pp. 23-27.