

Anaesthesia Management in Myasthenia Gravis with Thymoma

Dr .Kusuma M¹, Dr Javed Wani², Dr Archana Har C³ , Dr R L Gogna⁴

¹Dr Kusuma M Junior Resident, Dept of Anaesthesia

²Dr Javed Wani Junior Resident, Dept of Anaesthesia

³Dr Archana Har C Professor, Dept of Anaesthesia

⁴Dr R L Gogna Professor & Head of Dept of Anaesthesia

Abstract /Introduction

Myasthenia gravis (MG) is an autoimmune syndrome caused by the failure of neuromuscular transmission, which results from the binding of autoantibodies to proteins involved in signaling at the neuromuscular junction (NMJ). These proteins include the nicotinic AChR or less frequently a muscle-specific tyrosine kinase (MuSK) involved in AChR clustering¹.

The disease incidence is 3–30 cases per million per year and rising as a result of increased awareness. Medical treatment of MG includes improving neuromuscular transmission by anticholinesterases, suppressing the immune system with corticosteroids and immunosuppressants, and decreasing circulating antibodies with plasmapheresis and, in selected cases, thymectomy.²

The myasthenic patient can be a challenge to anesthesiologists, and the post-surgical risk of respiratory failure has always been a matter of concern. During postoperative period pain, analgesics and residual effects of anesthetics can adversely affect pulmonary function which is already limited by the MG itself. This makes it important for the anesthesiologist to be aware of possible signs of the disease and to be properly updated on the optimal perioperative anesthetic management of the myasthenic patient.³

Patients with generalized MG and patients with ocular symptoms poorly controlled by anticholinesterases often benefit from thymectomy.⁴

Keywords: General anaesthesia, Myasthenia gravis, thymectomy, thoracic epidural.

Date of Submission: 01-10-2021

Date of Acceptance: 15-10-2021

I. Case Report

A 70-year-old female (50 kg) diagnosed as a case of myasthenia gravis Grade I since 2 year was scheduled for thymoma excision procedure. She started developing symptoms of ptosis two year before. On further evaluation, it was diagnosed as myasthenia. She was started on Tablet Neostigmine 15mg BD to which she responded. Her blood and other investigations were within normal range. Her pulmonary function tests (PFT) showed severe impairment of lung function with poor bronchodilator effect. She was at risk of post-operative respiratory complications.

Patient had history of extensive burns at the age of 15years. Extensive burn scar on chest, upper limb

MO : 3 fingers MPC : 4

Short neck +

2D ECHO : Trivial TR, MR, LVEF = 60 %, Grade I DD

Xray neck AP/Lateral-NAD

- USG Neck (8/1/21) s/o malignant lesion to r/o thyroid malignancy, parathyroid malignancy ,metastasis
- CT scan neck + chest(8/1/21) s/o tumour extending retrosternally and compressing the left brachiocephalic vein and posteriorly, mass effect on vessels, carotid artery and jugular vein

GENERAL EXAMINATION

BP 120/70 mmhg Rt arm supine position^[LSEP]Pulse 88 b/min, regular rhythm

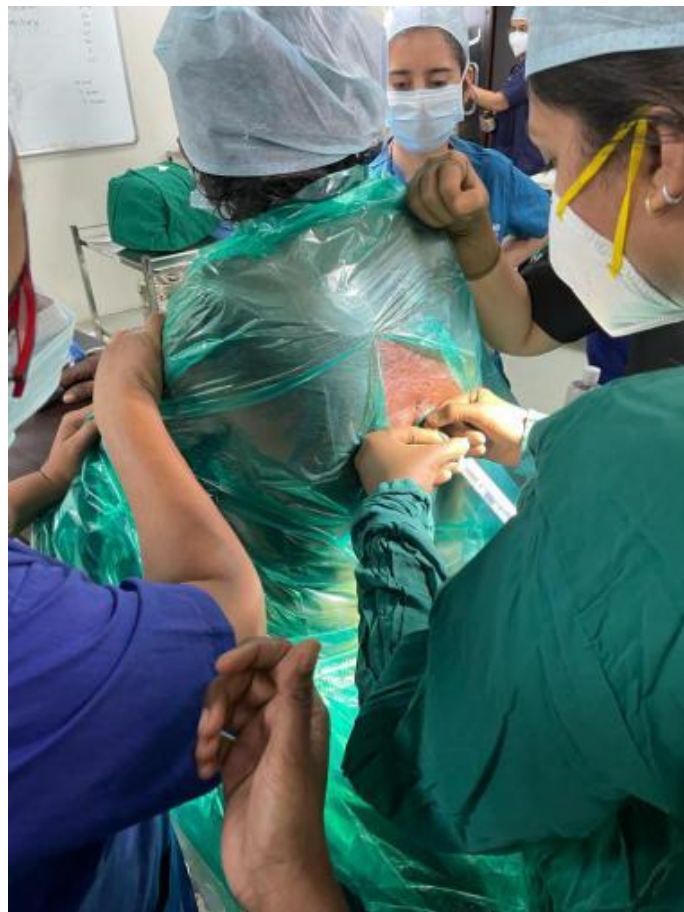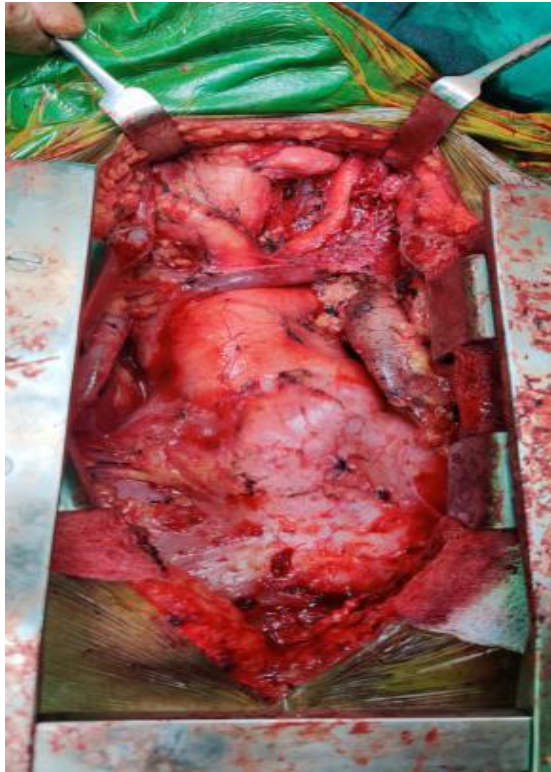O/E : Vitally stable

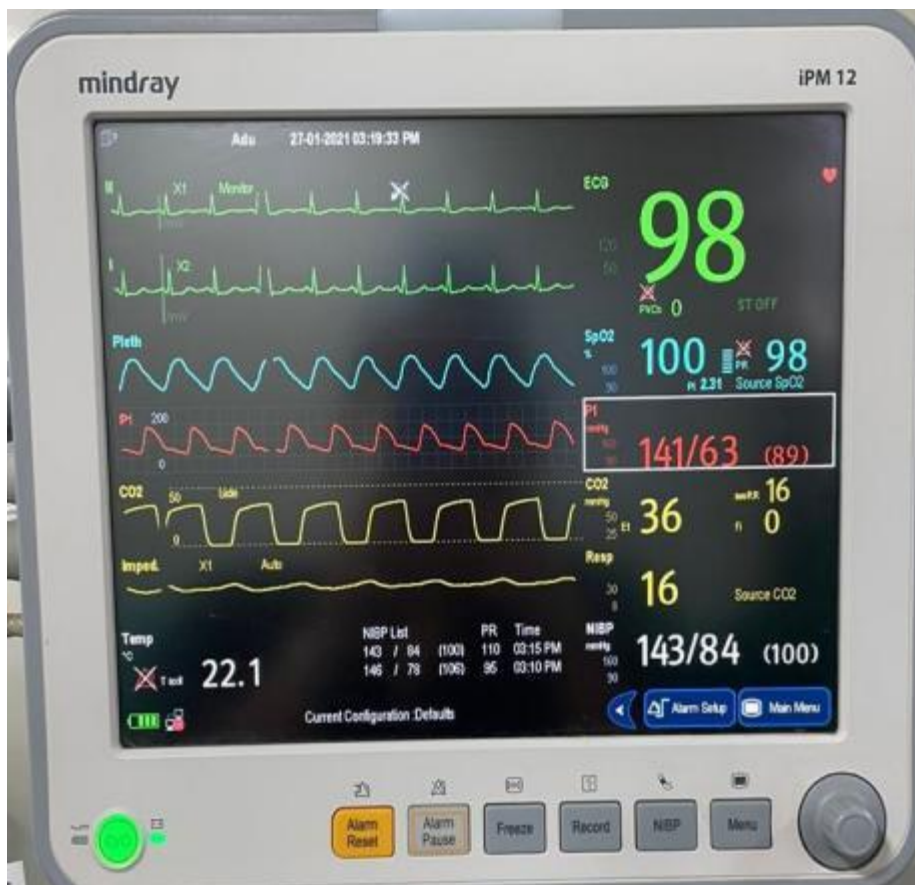
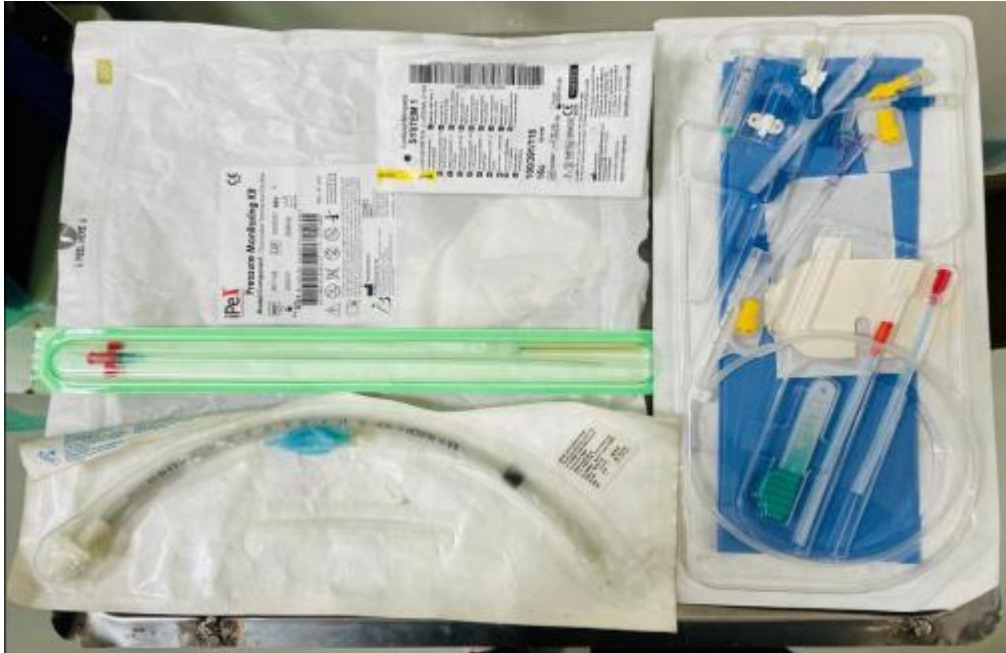AIRWAY EXAMINATION

Mallampatti scoring of 4

Restricted neck mobility

Mouth opening- 3 fingers
No loose teeth





SYSTEMIC EXAMINATION

RESP: bilateral Air entry equal, No added sounds.

CVS : S1 S2 normally heard, no murmur heard.

CNS : conscious, oriented

P/A : soft, non tender.

PRE-ANAESTHETIC CHECK UP DONE WITH ALL ROUTINE INVESTIGATIONS

- Complete blood count,

- LFT,
- RFT, TFT
- Serum electrolytes,
- Random blood sugar,
- ECG and 2D echo were within normal range

X-RAY-CHEST NAD

X RAY NECK AP/LATERAL-NAD

USG Guided Neck Biopsy- Histomorphological features are consistent with thymic neoplasm, suggestive of thymoma- Type A (WHO Classification 2015)

PREOPERATIVE ADVICE

Patients was kept nil by mouth for 6 hours.

Informed consent with due risk taken, nebulisation with Duolin and Budecort 6 hourly, Injection hydrocortisone 100 mg preoperatively.

In pre operation room patient's airway was prepared for the difficult intubation situation with nebulization with lox 4% 2ml followed by Inj glycopyrolate 0.2mg IV, gargle with viscous gargle lox 2%.

Patient was wheeled in the operation room, standard ASA monitors were attached and baseline vitals were recorded.

INTRAOPERATIVE CARE-

Patient was taken in, arterial line was secured for beat to beat BP monitoring, USG guided central line secured for measuring CVP, patient was taken in sitting position and thoracic epidural secured at T7 Level, general anaesthesia was considered with difficult intubation cart including supra glottic devise, bougie, fiberoptic bronchoscope, video laryngoscope were kept ready.

Patient was preoxygenated with 100% oxygen for 3min, administered Inj. Midazolam 1mg and 50mcg titrated fentanyl given IV

Patient was induced and intubated using inhalational agent sevoflurane, McCoy's blade MAC 3 with cuffed ET tube no 7.5 and fixed at 21cm incisor level. Position of ET tube was confirmed by auscultation and capnography.

Inj propofol 50mg given for deeper plain of anaesthesia

Anaesthesia was maintained with air, oxygen and titrated doses of sevoflurane analgesia maintained with epidural infusion with ropivacaine 0.2% @ 3-5ml/hr

The surgery was performed in supine position and lasted for 6 hours.

Intraoperative Adequate fluid requirement was maintained using crystalloids at 2ml/kg.

1 pint PCV was transfused intra op.

Perioperative urine output of 0.5-1.0 ml/kg/hr was maintained.

Considering the difficult airway patient was shifted to SICU and electively extubated in SICU on same day after 4 hours, patient was shifted to ward on POD3 and was discharged on POD 15.

II. Discussion

The safe use of general anesthesia requires attention to monitoring the patient and understanding the variable responses that the myasthenic patients may have to many drugs including steroids and immuno suppressants.

A through pre anaesthetic check up and drug history is mandatory.

The use of muscle relaxants in patients with MG has been a controversial topic.

If needed NMDR are to be used with neuromuscular monitoring in a reduced dose.

Patients with MG are usually sensitive to the effects of non-depolarizing muscle relaxants, and volatile anesthetic agents accelerate their effect. Furthermore, the potential interaction of anticholinesterases (administered as therapeutic agents for MG) with both the depolarizing and non-depolarizing muscle relaxants is also a problem.⁹

It is difficult to determine the optimal amount of muscle relaxants required in a patient with MG⁵. Hence, there is an increasing trend of using non-muscle relaxant techniques in such patients who undergo surgery.⁶

All patients with MG should be closely monitored postoperatively in the postanesthesia care unit or the surgical intensive care unit, where respiratory support can be immediately reinstated. Weakness after surgery represents as special problem in MG patients. The differential diagnosis includes myasthenic crisis, residual effects of anesthetic drugs, nonanesthetic drugs interfering with neuromuscular transmission and cholinergic crisis.⁵

In our case, intraoperative condition was maintained using combination of low MAC sevoflurane anesthesia and an infusion of ropivacaine with thoracic epidural anesthesia. Muscle relaxants were not used and haemodynamic responses to intubation were controlled effectively.

Post operative pain management was given with thoracic epidural anaesthesia

Institution of early physiotherapy and incentive spirometry for fast recovery and avoid post op pulmonary complications.

III. Conclusion

Myasthenia gravis is a disease with many implications for the safe administration of anesthesia. The potential for respiratory compromise in these patients requires the anesthesiologist to be familiar with the underlying disease state, as well as the interaction of anesthetic and nonanesthetic drugs with MG. Thymectomy is a surgical procedure commonly undergone by patients with MG.

References

- [1]. Conti-Fine BM, Milani M, Kaminski HJ (2006) Myasthenia gravis: past, present, and future. *J Clin Invest* 116: 2843-2854
- [2]. McGrogan A, Sneddon S, de Vries CS (2010) The incidence of myasthenia gravis: a systematic literature review. *Neuroepidemiology* 34: 171-183.
- [3]. Blichfeldt-Lauridsen L, Hansen BD (2012) Anesthesia and myasthenia gravis. *Acta Anaesthesiol Scand* 56: 17-22.
- [4]. Wilkins KB, Bulkley GB (1999) Thymectomy in the integrated management of myasthenia gravis. *Adv Surg* 32: 105-133.
- [5]. Tripathi M, Srivastava K, Misra SK, Puri GD (2001) Peri-operative management of patients for video assisted thoracoscopic thymectomy in myasthenia gravis. *J Postgrad Med* 47: 258-261.
- [6]. Mori T, Yoshioka M, Watanabe K, Iwatani K, Kobayashi H, et al. (2003) Changes in respiratory condition after thymectomy for patients with myasthenia gravis. *Ann Thorac Cardiovasc Surg* 9: 93-97.
- [7]. Della Rocca G, Coccia C, Diana L, Pompei L, Costa MG, et al. (2003) Propofol or sevoflurane anesthesia without muscle relaxants allow the early extubation of myasthenic patients. *Can J Anaesth* 50: 547-552.
- [8]. Anesthetic management of patient with myasthenia gravis and uncontrolled hyperthyroidism for thymectomy. January 2010 *Annals of Cardiac Anaesthesia* 13(1):49-52 DOI:10.4103/0971-9784.58835
- [9]. Başkan et al. *Int J Anesthetic Anesthesiol* 2015, 2:022 DOI: 10.23937/2377-4630/2/1/1022 Volume 2 | Issue 1
- [10]. MYASTHENIA GRAVIS: A CHALLENGE. *Indian Journal of Anaesthesia* | Vol. 59 | Issue 3 | Mar 2015 DOI: 10.4103/0019-5049.153047
- [11]. Minal H, Rakesh B. Myasthenia Gravis and Anesthesia Challenges. *Res Inno in Anesth* 2019;4(2):36–39.
- [12]. *J. Clin. Invest.* 116:2843–2854 (2006). doi:10.1172/JCI29894.
- [13]. Vanjari V, Maybauer MO. Anaesthetic management of myasthenia gravis in coronary artery bypass grafting. *Ann Card Anaesth* 2020;23:209-11.

Dr .Kusuma M, et. al. “Anaesthesia Management in Myasthenia Gravis With Thymoma.” *IOSR Journal of Dental and Medical Sciences (IOSR-JDMS)*, 20(10), 2021, pp. 44-48.