

Papilla Reconstruction Around Teeth And Implants- A Review

Dr. Shilpa Mathew¹, Dr. Roshni Ramesh², Dr. Santhosh Kumar S³

¹PG student, ²Professor, ³Professor and Head of the Department

Department of Periodontology and Implant dentistry

Government Dental College, Trivandrum.

Abstract

An open interproximal space between teeth known as Black Triangle is an esthetically displeasing condition. It can also cause food impaction, phonetic problems as well as periodontitis. Current dentistry focusses on both functional and esthetic demands of patients. Therefore treatment of black triangle has increasing demand on esthetic dentistry. It is more challenging and difficult, as it is associated with patient's smile and esthetics. Various treatment approaches for papilla reconstruction around teeth and implants are present, that involves both surgical and non-surgical approaches. This review help us to have an outlook on various treatment modalities for papilla reconstruction.

Keywords- Black triangle, Interdental papilla, Interimplant papilla, Non-surgical, Papilla reconstruction, Surgical

Date of Submission: 29-09-2021

Date of Acceptance: 12-10-2021

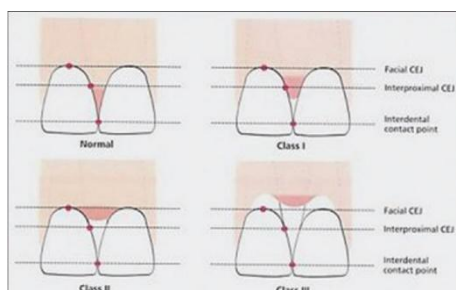
I. Introduction

Interdental papilla is a portion of gingiva that occupies the gingival embrasure, the space beneath the contact area of two adjacent teeth.¹ Patient's smile is greatly influenced by interdental papilla and its absence leads to a deformity called Gingival Black Triangle (GBT), which impairs esthetics, phonetics and causes food accumulation.^{2,3} The etiology of black triangle is multifactorial. Reconstruction of lost interdental papilla around teeth and implants have been inconsistent among clinicians.⁴ Various surgical and non surgical techniques are available for management of gingival black triangle. This review discusses various classifications of papilla loss, factors affecting papilla loss and currently available non-surgical and surgical treatment modalities for papilla reconstruction around teeth and implants based on thorough literature search from 1974 to 2020.

II. Classification Of Interdental Papilla Loss

Nordland and Tarnow, 1998⁵

Based on three anatomical landmarks: contact point, facial apical extent of cemento enamel junction (CEJ) and the interproximal coronal extent of the CEJ.



Nordland and Tarnow classification of interdental papilla

- **Normal**: Interdental papilla fills entire embrasure space.
- **Class I**: Tip of interdental papilla is located between contact point and the most coronal extent of the interproximal CEJ (space present but interproximal CEJ is not visible)
- **Class II**: Tip of interdental papilla is located at or apical to interproximal CEJ but coronal to apical extent of facial CEJ (interproximal CEJ visible)

- **Class III:** Tip of interdental papilla is located at or apical to the facial CEJ.

Papilla Index Score (PIS) -Jemt, 1997⁷

For papillary loss around implants, measured from a reference line that passes through the highest gingival curvature of the implant restoration on the facial side and the adjacent permanent tooth.

- Score 0 : Absence of papilla and no curvature of the soft tissue contour adjacent to single implant restoration
- Score 1: Papillary height is less than half and a convex curvature of soft tissue contour adjacent to single implant crown; adjacent tooth is observed.
- Score 2: Half or more than half of height of papilla is present; does not fill entire papillary height.
- Score 3: Papilla fills entire proximal space
- Score 4: Hyperplastic papilla and covers too much of single implant restoration and/or adjacent tooth.

Nemcovsky 2001^{3,8}

A modification of papilla index score (PIS) of **Jemt**.

- PIS 0: Papilla is absent and there is no curvature of soft tissue contour.
- PIS 1: Papillary height is less than half compared to that of proximal teeth; a convex curvature of soft tissue contour is observed.
- PIS 2: At least half of the papilla height is present when compared proximal teeth, and is not in complete harmony with interdental papillae of proximal teeth.
- PIS 3: Papilla fills the entire interproximal embrasure to the level same as that of proximal teeth and is in complete harmony with adjacent papillae.

Cardaropoli et al , 2004⁹

Papilla Presence Index (PPI)- Based on the positional relationship among papilla, cementoenamel junction (CEJ) and adjacent teeth.

- PPI 1: Papilla is completely present and coronally extends to contact point to fill interproximal embrasure.
 - PPI 1r: PPI 1 complicated by buccal gingival recession.
- PPI 2: Papilla lies apical to contact point, not at the same level of adjacent papillae, embrasure is not completely filled, but interproximal CEJ is not visible.
 - PPI 2r: PPI 2 complicated by the presence of buccal gingival recession.
- PPI 3: Papilla is moved more apically and interproximal CEJ is visible (Interproximal soft tissue recession is present)
- PPI 4: Papilla lies apical to CEJ both buccally and interproximally. (Interproximal and buccal soft tissue recession is present).

III. Factors Determining Papilla Loss

Causes for papilla loss are multifactorial.^{2,3,6}

- Interdental space
- Distance between inter-proximal contact position and bone crest
- Gingival biotype
- Age
- Periodontal diseases
- Diverging roots
- Tooth morphology

INTERDENTAL SPACE

Filling of papilla decreased as the distance between roots increased. Closer roots increases the likelihood of full papillae.^{10,11}

DISTANCE BETWEEN INTER-PROXIMAL CONTACT POSITION AND BONE CREST

When the distance of contact point to bone crest was 5 mm or less, the papilla was present almost 100% of time. When this distance was 6 mm, the papilla was present 56% of time, and when the distance was 7 mm or more, the papilla was present 27% or less.^{11,12} For single tooth implant, when the measurement from contact point to bone crest was 5 mm or less, papilla was present almost 100% of the time. When the distance was ≥ 6 mm, the papilla was present 50% of the time or less.¹³

GINGIVAL BIOTYPE

Thin biotype and high scallop are more prone for the development of interproximal papilla loss.¹⁴

AGE

Ageing can cause thinning of oral epithelium and reduced keratinization, resulting in reduced papillae height.³ Papillary tissue height decreases by 0.012mm/year.¹¹

PERIODONTAL DISEASES

Periodontitis cause loss of alveolar bone.¹⁵ Since the foundation of gingival support is underlying osseous crest, loss of alveolar bone will cause loss of interdental papilla.¹²

DIVERGING ROOTS

Diverging roots are highly associated with open gingival embrasures, which occurs naturally or by improper bracket placement during orthodontic treatment.¹⁶

TOOTH MORPHOLOGY

Triangular teeth predisposes to 'black triangles' when compared to square teeth.¹⁷

IV. Methods Of Interdental Papilla Reconstruction

There are both non surgical and surgical methods for papilla reconstruction.

NON-SURGICAL APPROACHES

CORRECTION OF TRAUMATIC ORAL HYGIENE PRACTICES

Toothbrush abrasion due to abusive brushing, improper flossing harm the gingival tissues. Usage of flat trim toothbrush bristle, end-rounded filaments and rubber bristles are recommended to reduce gingival abrasion. Regrowth of interdental papilla was observed after correction of brushing technique, supportive periodontal therapy and after stoppage of using interdental tooth brush.^{6,18,19}

TOOTH CONTOURING

The contour of a restoration can affect the interdental papillary space. Restorations can be designed to have broad contact areas positioned correctly in relation to the bone crest to eliminate a GBT.^{3,20}

PINK RESTORATIVE MATERIALS

Pink colored composite resin can be used on restorations to replace missing soft tissue.³

VEREERS

Removable acrylic or silicone can be used as a gingival veneer to hide black triangles especially in patients with high smile line. These are known by different names such as flange prosthesis, gingival veneer prosthesis, removable gingival veneer, acrylic gingival veneer, acrylic periodontal veneer, removable gingival extension and gingival mask.^{3,21}

ORTHODONTIC TOOTH MOVEMENT

Orthodontic therapy has been used to create a papilla in diastema. The movement of two teeth closer together creates a papilla due to the physical, coronal displacement of the interdental gingiva by "squeezing" the gingiva together.²²

CURETTAGE

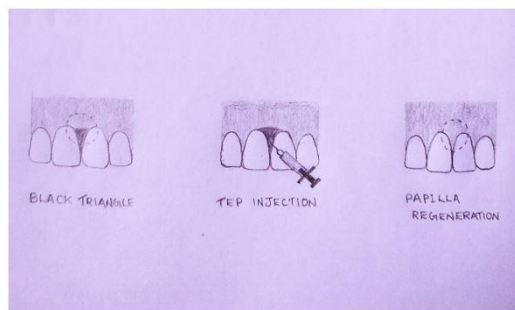
Regeneration of interdental papillae was noted after curettage in Acute Necrotizing Gingivitis patients which was performed every 10 days, a total of 4 times.¹⁹

TISSUE VOLUMIZATION

Hyaluronic Acid(HA) was used to reduce or eliminate GBTs adjacent to dental implants and teeth in the aesthetic zone. After administration of local anaesthetic, HA is injected apical to coronal tip of involved papillae. Repeated administration for 3-5 times every 3-5 weeks may be required.²³⁻²⁵ 5% of HA is effective for interdental deficiency treatment with minimal rebound at the end of 6 months.²⁶ Non-animal stabilized HA is widely used for clinical applications because of less allergic reactions. Disadvantages include varying degrees of resorption and hence require additional injections for soft-tissue augmentation.²⁷

INJECTABLE STEM CELL THERAPY (TISSUE ENGINEERED PAPILLA- TEP)

Injectable TEP was prepared as follows; Bone marrow mesenchymal stem cells(BMMSCs), Platelet Rich Plasma(PRP) and HA are mixed into two syringes. In one syringe,BMMSCs were mixed with PRP and HA and thrombin/calcium chloride mixture is prepared in another. These two syringes were connected by a T connector and were pushed and pulled alternatively to acquire a gel like consistency. After cleaning of injection area, the region was anesthetized and TEP was injected into papilla without incision.²⁷



HEMOLASER THERAPY (ZANIN ET AL, 2018)²⁸

It is a nonsurgical technique where the patient's blood drops are used in a given area together with laser Photobiomodulation therapy (PBMT). This technique (HLT) involves the use of 660nm diode laser associated with gingival bleeding to fill black spaces. Gingival bleeding is made by stimulating the gingival sulcus with clinical probe. This procedure helps to release mesenchymal stem cells (MSCs) along with the blood to favor neovascularization and reconstruction of the interdental papilla.

SURGICAL APPROACHES

PEDICLE GRAFT PROCEDURE (BEAGLE ,1992)²⁹

This is a combination of Papilla preservation by Evian et al and Abram's roll techniques.⁸ A partial thickness incision was made along the line angles of adjacent teeth on the palatal aspect. Sulcular incisions were made in the interdental region to separate the papillary unit. Then partial thickness flap was elevated to the labial aspect,folded and sutured.^{6,29,30}

SEMILUNAR CORONALLY REPOSITIONED PAPILLA WITH SUB EPITHELIAL CONNECTIVE TISSUE GRAFT (HAN AND TAKEI, 1996)²²

A semilunar incision is placed in interdental region. Intrasulcular incisions are made around the mesial and distal half of the two adjacent teeth to free the connective and to allow the coronal displacement of the gingival-papillary unit. Subepithelial connective tissue graft is removed from the palate and placed into the pouch-like space after the gingival-papillary unit is pushed incisally. This procedure may be repeated after 2-3 months. This appears to be one of the most predictable procedures due to the movement of a large segment of gingival-papillary unit with intact blood supply.²²

ENVELOPE FLAP WITH CONNECTIVE TISSUE GRAFT (AZZI ET AL ,1998)³¹

It is a surgical technique, that elevates papilla from its base and has attachment to the palatal flap. A wedge shaped connective tissue graft was placed under buccal and palatal flaps and was sutured.

PAPILLA RECONSTRUCTION USING AUTOGENOUS OSSEOUS AND CONNECTIVE TISSUE GRAFTS (AZZI ET AL ,2001)³²

An intrasulcular incision is made around the neck of teeth, on the buccal and palatal aspects adjacent to papilla. From mucogingival junction, a horizontal incision was made, which extends into the alveolar mucosa and apically up to the labial vestibular fold to elevate a split-thickness flap. Another horizontal incision directed to the bone at the apical portion of the split-thickness flap is performed to release a mucoperiosteal flap. Papillae are gently undermined and entire gingiva papillary unit is displaced coronally and sutured. Holes are drilled into the cortical bone for better osteogenic environment. Osseous graft is removed from the maxillary tuberosity and positioned on the recipient site. Crushed cancellous bone is packed around the grafted bone in the shape of the interdental bone. A large connective tissue graft harvested from the palate is placed on top of the bone graft to cover the entire augmented area and sutures are given.

Advantages include maximum blood supply to the graft site and root coverage along with papilla fill.

ADVANCED PAPILLARY FLAP COMBINED WITH A GINGIVAL GRAFT (NEMCOVSKY, 2001)⁸

Used in large interdental space. A coronally curved incision was made in the palate, aligned with the interdental space, at or 2mm apical to bone crest and ending coronally at least 2 mm from the gingival margin. Intrasulcular incisions were then made around the mesial and distal half of adjacent teeth. Release of all interdental soft tissue from the root surfaces to enable the flap to coronally advance. A Palatal tissue wedge containing epithelium and connective tissue was harvested, positioned properly by sutures. This procedure is easy to perform but, long term predictability is not established.

MICROSURGICAL TECHNIQUE FOR AUGMENTATION OF THE INTERDENTAL PAPILLA (NORDLAND AND HARINDER, 2008)³³

Surgical dissecting microscope and micro scalpel blade are used. Sulcular incision is made to the crest of the bone, that extends circumferentially around adjacent teeth. Releasing incisions are not used. A split-thickness flap is prepared. Extend the sulcular incision facially up to and past the mucogingival junction, which helps the mobility of undermined flap. Connective tissue graft is harvested and placed into position with a suture that begins at the palatal gingiva; goes under the papilla, lassoing the graft; and then is run back through to the palatal gingiva to be tied off. Advantages are less trauma and maintenance of vascularity.

SUB EPITHELIAL CONNECTIVE TISSUE GRAFT (CARRANZA ET AL, 2011)³⁴

Interproximal spaces measuring 3mm or more are selected. Intrasulcular incisions are made. Two vertical releasing incisions, diverging apically, are made on mesiobuccal and distobuccal line angles. Put horizontal incision on papillary base palatally, atleast 5 mm apical to gingival margin. Reflect full thickness flap and connective tissue graft harvested from palate is introduced into the papillary area through one of the vertical incisions and place sutures. This technique showed a significant gain of papillary volume, notable esthetic improvement , no visible scars or color mismatch.

SEMILUNAR FLAP WITH PLATELET RICH FIBRIN(PRF) , LALITHA ET AL, 2012³⁵

Through a semilunar incision made in the region of interdental papillae, a split thickness flap was raised to create a pouch and PRF was pushed coronally to fill the papillae. Reconstructed papilla was stable for 3-6 months post operatively.

ADVANCED PAPILLARY FLAP WITH INTERPOSED SUBEPITHELIAL CONNECTIVE TISSUE GRAFT (JHAMB ET AL, 2014)³⁶

A 3-5mm semilunar incision was given 2 mm coronal to the mucogingival junction, over the papillary region. Intercrevicular incision given buccally and palatally. Gingiva-papillary unit was freed from the underlying bone, by passing through semilunar incision. Sub epithelial connective tissue graft harvested was placed under the flaps to fill dead space and suture it. Advantage is that semilunar incision allows the coronal displacement without creating tension and prevents the gingiva from rebounding back to its original position.

MODIFIED BEAGLE'S TECHNIQUE (CHAULKAR ET AL, 2017)³⁰

Incisions were given at adjacent line angles of the interdental papilla, such that length is more than length of the black triangle space to be reconstructed and were connected by a horizontal incision. A partial thickness pedicle flap was raised. Pedicle graft obtained was advanced coronally to obliterate black triangle. Flap is then sutured coronally.

INTERPROXIMAL TUNNELLING WITH A CUSTOMIZED CONNECTIVE TISSUE GRAFT THROUGH MICROSURGICAL APPROACH (FEUILLET ET AL , 2018)³⁷

4X magnification loupe was used. Straight and curved microsurgical instruments were used to create a mucoperiosteal tunnel on the buccal side. Full thickness tunnel was extended laterally around half of the teeth and apically beyond mucogingival line. Palatally, two vertical parallel releasing incisions and split thickness dissection was performed. A tunnelling instrument, Deppeler was used to connect buccal and palatal recipient sites, under interdental papilla. Connective tissue graft harvested was properly positioned and maintained by three stabilizing sutures. A vertical double cross mattress suture suspended at the contact point to coronally displace the papilla. This technique is less invasive and preserves the blood supply of the papilla.

V. Reconstruction Of Inter Implant Papilla

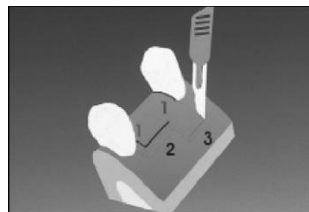
There are many methods for interproximal papilla reconstruction. Some of the methods are discussed in this review.

SOFT TISSUE AUGMENTATION (ARNOUX ET AL, 1997)³⁸

This technique involve placement of sub epithelial connective tissue before, at or after stage 1 prior to stage 2 of implant placement. During Stage 2, tissue punch is used to preserve previously augmented soft tissue.

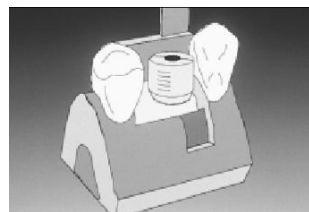
PALATAL SLIDING STRIP FLAP (ADRIAENSSENS ET AL, 2000)³⁹

During stage 2 surgery, a full-thickness sulcular incision is made in a labiopalatal direction perpendicular to the ridge crest, both on the mesial and distal aspects of the implant. A full thickness horizontal incision is made from distal to mesial on the palatal side approximately two-thirds of the distance between the two teeth. Two incisions, parallel to each other, are made in a labiopalatal direction to create a partial-thickness flap extending in the palate to form a strip mesially.



Placemet of incisions

Flaps are elevated to uncover implant and cover screw. After placement of healing abutment, a semilunar incision is made distally to provide another strip. Distal pedicle will be rotated 90 degrees in the palatal direction around the healing abutment and mesial pedicle from the palate will fill the interproximal space, which will allow the reconstruction of two papillae.



Insertion of healing abutment

Advantages are: (1) minimal trauma; (2) flap nutrition (3) augmentation of soft tissue (4) tissue like formation of papilla (5) avoidance of a donor site with a second surgical area or multiple surgeries (6) Uneventful wound healing by secondary intention.

SPLIT FLAP TECHNIQUE (NEMCOVSKY ET AL , 2000)⁴⁰

During implant exposure, U-shaped incision, open towards the buccal aspect of the implant site with slightly divergent arms was made, with adjacent papilla remaining adhered to the proximal teeth and were connected palatally. De-epithelialized outer edges of the incision and full thickness flap was raised. After insertion of healing abutment, flap was split in its center into mesial and distal halves. Each part of the buccal flap was positioned over de-epithelialized papillae and secured with vertical mattress sutures.

DEMINERALIZED FREEZE DRIED BONE ALLOGRAFT BLOCK FIXED BY TITANIUM SCREW (CHARDE ET AL, 2012)⁴¹

This technique was used for interimplant papilla reconstruction in esthetic zone of maxilla during one stage early loading multiple implant procedure. A horizontal palatal incision was made 2mm away from crest of the ridge without splitting adjacent papillae. Vertical releasing incision on labial surface extending to vestibule was made. After raising flap, implants were placed. Interimplant bone was drilled by 1mm diameter bur. The prepared block allograft (freeze, dried, demineralized, irradiated bone allograft block) was predrilled to accommodate (1.5mm × 8mm) titanium screw. After stabilization of allograft block between the two implants, the buccal flap was positioned around the implants and sutured to the palatal flap. On a 6 month follow up, papillary height found to be increased.

TUNNELLING WITH SUB EPITHELIAL CONNECTIVE TISSUE GRAFT (FROUM ET AL, 2016) ⁴²

Implant supported provisional restoration was removed and embrasure space was opened at the site of papilla augmentation. Full thickness oblique incisions were made buccally starting apical to mucogingival junction to the deficient papilla and palatally from distal to mesial direction. A translingual curette (EBINA) was inserted into buccal incision, to elevate the flap and create a subperiosteal tunnel towards crest of the ridge coronally to interproximal area.



Translingual curette

Similar elevation was performed palatally, thus creating a tunnel between buccal and lingual incisions. Subepithelial connective tissue graft was harvested from palate and positioned over interproximal area and sutures are placed properly.

VI. Discussion

Over the years, a number of authors have advocated various methods to treat black triangle.(Figure6) Mahantesha Sharanappa et al in 2016⁴³ presented a case report of two cases using PRF and pedicle graft combination and observed an increase in papillary height even after 6 months and results were found to be stable.

Chhavia and Sandeep in 2017⁴⁴ presented a case series demonstrating a combination of modified beagle's technique and composite restoration to reconstruct the papilla and complete reconstruction of the lost papilla was achieved in both cases 6 months postoperatively.

A case series⁴⁵ describes a surgical technique to reconstruct interproximal papillae around early loaded single implant using sub epithelial connective tissue graft in maxillary anterior region. Results showed that papilla reconstruction procedure using SCTG at the time of implant placement resulted in statistically significant increase in papillary height .

A case report describing papillary reconstruction using Beagle's technique with 3.5x magnification showed an optimized result.⁴⁶

Studies comparing various techniques have also been published.

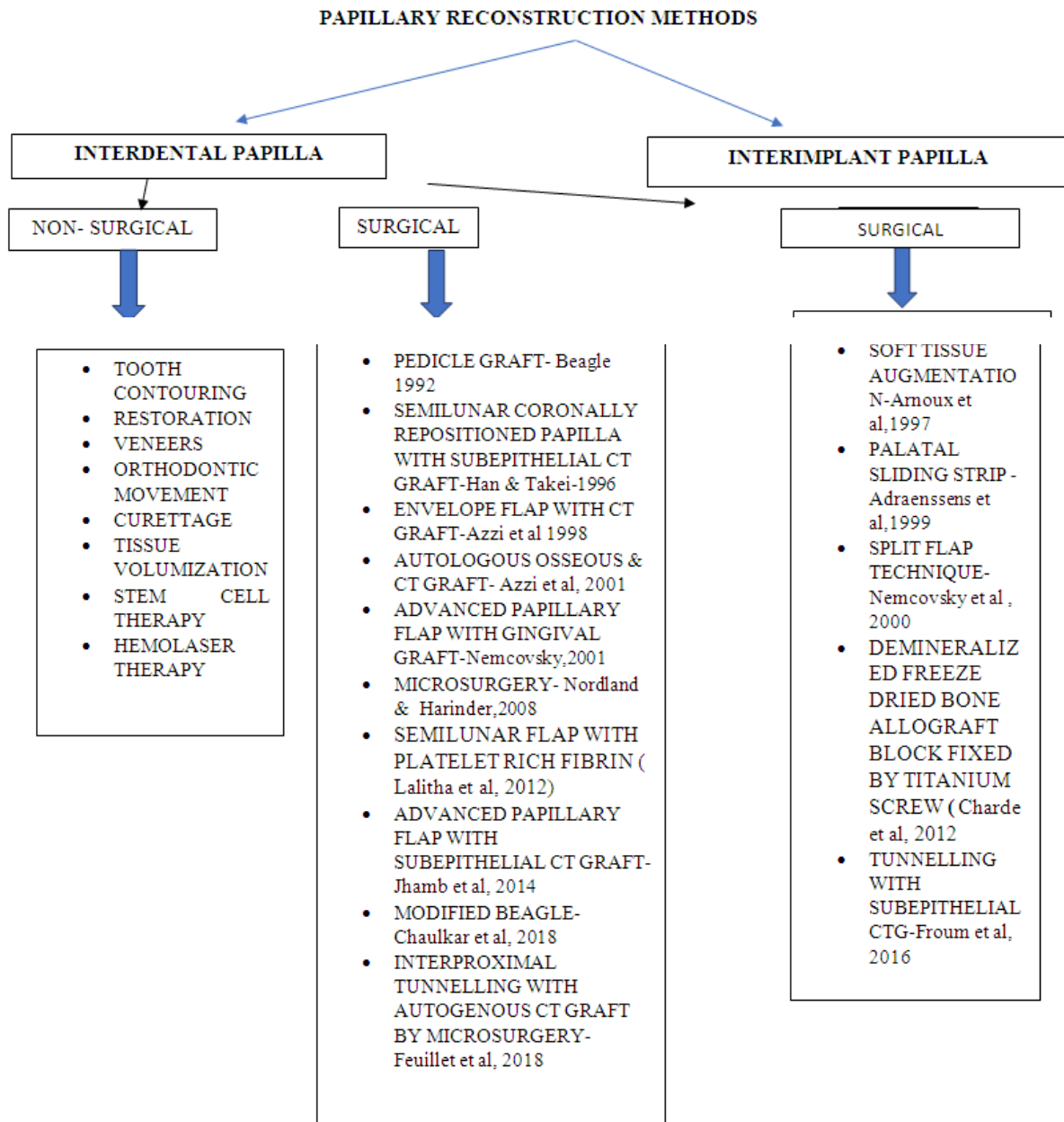
Hennig et al ⁴⁷ conducted a Systematic review on treatment alternatives for the absence of interdental papilla between the years 2010 and 2015. They analysed percentage of interdental space filling and the reduction of the distance between the contact point and the tip of the papilla in millimeters. They concluded that there is no gold standard technique for the interdental papilla augmentation.

A case report was published by Shenoy et al in 2020⁴⁸, where 3 techniques of papilla reconstruction i.e, Roll technique, Composite build up followed by Roll technique and Pouch and tunnel with connective tissue graft using microsurgical instruments were discussed. Papilla refill was obtained and maintained for 2 years for Roll technique. For Pouch and Tunnel with Connective Tissue Graft, after approximately 2 years, a relapse of about 0.5mm was seen. For second technique, patient missed follow up after 2 months.

VII. Conclusion

It has been proven that by maintaining the height of bone in the interproximal area, an aesthetic reconstruction of the papilla can be achieved. Periodontal plastic procedures can be used to restore the lost papilla. In aesthetically compromised cases, restorative intervention can mask the loss of tissues. Newer regenerative techniques like stem cell therapy are in the way of progress and are non invasive.

Even though there are many approaches showing good clinical results and have shown to restore the lost interdental papilla, the predictability of various procedures has not been completely documented, and no data on the long term stability are available in the literature till date.



References

- [1]. Newman and caranza's clinical periodontology 13th edition.
- [2]. H T, H Y, T H. Maxillary anterior esthetics. Preservation of the interdental papilla. Dental clinics of North America [Internet]. 1989 Apr [cited 2021 Apr 30];33(2). Available from: <https://pubmed.ncbi.nlm.nih.gov/2656318/>
- [3]. Ziahosseini P, Hussain F, Millar BJ. Management of gingival black triangles. Br Dent J. 2014 Nov;217(10):559–63.
- [4]. Al-Zarea K, Sghaireen M, Alomari W, Bheran H, Taher I. Black Triangles Causes and Management: A Review of Literature. BJASt. 2015 Jan 10;6(1):1–7.
- [5]. Nordland WP, Tarnow DP. A Classification System for Loss of Papillary Height. Journal of Periodontology. 1998 Oct;69(10):1124–6.
- [6]. Jamwal DD, Kanade DK, Tanwar DVS, Waghmare DP, Landge DN. Treatment of Interdental Papilla: A Review. 2019;(2):12.
- [7]. Jemt T. Regeneration of gingival papillae after single-implant treatment. Int J Periodontics Restorative Dent. 1997 Aug;17(4):326–33.
- [8]. Nemcovsky CE. Interproximal papilla augmentation procedure: A novel surgical approach and clinical evaluation of 10 consecutive procedures. Int J Periodontics Restorative Dent. 2001;
- [9]. Cardaropoli D, Re S, Corrente G. The Papilla Presence Index (PPI): A New System to Assess Interproximal Papillary Levels. Int J Periodontics Restorative Dent. 2004 Nov;24(5):488–92.
- [10]. Cho H-S, Jang H-S, Kim D-K, Park J-C, Kim H-J, Choi S-H, et al. The Effects of Interproximal Distance Between Roots on the Existence of Interdental Papillae According to the Distance From the Contact Point to the Alveolar Crest. Journal of Periodontology. 2006 Oct;77(10):1651–7.

- [11]. Chow YC, Eber RM, Tsao Y-P, Shotwell JL, Wang H-L. Factors associated with the appearance of gingival papillae: Appearance of gingival papillae. *Journal of Clinical Periodontology*. 2010 Jul 1;no-no.
- [12]. Tarnow DP, Wagner AW, Fletcher P. The Effect of the Distance From the Contact Point to the Crest of Bone on the Presence or Absence of the Interproximal Dental Papilla. *Journal of Periodontology*. 1992 Dec;63(12):995–6.
- [13]. Choquet V, Hermans M, Adriaenssens P, Daelemans P, Tarnow DP, Malevez C. Clinical and Radiographic Evaluation of the Papilla Level Adjacent to Single-Tooth Dental Implants. A Retrospective Study in the Maxillary Anterior Region. *Journal of Periodontology*. 2001 Oct;72(10):1364–71.
- [14]. Kois JC. Predictable single tooth peri-implant esthetics: five diagnostic keys. *Compend Contin Educ Dent*. 2001 Mar;22(3):199–206; quiz 208.
- [15]. Lindhe J, editor. *Textbook of clinical periodontology*. 2. ed, 5. print. Copenhagen: Munksgaard; 1995. 648 p.
- [16]. Sharma AA, Park JH. Esthetic Considerations in Interdental Papilla: Remediation and Regeneration. *Journal of Esthetic and Restorative Dentistry*. 2010 Feb;22(1):18–28.
- [17]. Ahmad I. Anterior dental aesthetics: Gingival perspective. *Br Dent J*. 2005 Aug;199(4):195–202.
- [18]. Litonjua LA, Andrea S, Bush PJ, Cohen RE. Toothbrushing and gingival recession. *International Dental Journal*. 2003 Apr;53(2):67–72.
- [19]. Yanagishita Y, Yoshino K, Taniguchi Y, Yoda Y, Matsukubo T. Nonsurgical Recovery of Interdental Papillae under Supportive Periodontal Therapy. :7.
- [20]. Bichocho N. Papilla Regeneration By Noninvasive prosthodontic treatment: segmental proximal restorations. :4.
- [21]. Alani A, Maglad A, Nohl F. The prosthetic management of gingival aesthetics. *Br Dent J*. 2011 Jan;210(2):63–9.
- [22]. Han TJ, Takei HH. Progress in gingival papilla reconstruction. *Periodontol 2000*. 1996 Jun;11(1):65–8.
- [23]. Mansouri SS, Ghasemi M, Salmani Z, Shams N. Clinical Application of Hyaluronic Acid Gel for Reconstruction of Interdental Papilla at the Esthetic zone. 2013;25(3):7.
- [24]. Becker W, Gabitov I, Stepanov M, Kois J, Smidt A, Becker BE. Minimally Invasive Treatment for Papillae Deficiencies in the Esthetic Zone: A Pilot Study. *Clinical Implant Dentistry and Related Research*. 2010 Mar;12(1):1–8.
- [25]. Lee W-P, Seo Y-S, Kim H-J, Yu S-J, Kim B-O. The association between radiographic embrasure morphology and interdental papilla reconstruction using injectable hyaluronic acid gel. *J Periodontal Implant Sci*. 2016;46(4):277.
- [26]. Singh S, Vandana KL. Use of different concentrations of hyaluronic acid in interdental papillary deficiency treatment: A clinical study. *J Indian Soc Periodontol*. 2019;23(1):35–41.
- [27]. Yamada Y, Nakamura S, Ueda M, Ito K. Papilla regeneration by injectable stem cell therapy with regenerative medicine: long-term clinical prognosis: Injectable papilla regeneration with stem cell therapy. *J Tissue Eng Regen Med*. 2015 Mar;9(3):305–9.
- [28]. Zanin F, Moreira MS, Pedroni ACF, Windlin M, Brugnera AP, Brugnera Júnior A, et al. Hemolasertherapy: A Novel Procedure for Gingival Papilla Regeneration—Case Report. *Photomedicine and Laser Surgery*. 2018 Apr;36(4):221–6.
- [29]. Beagle JR. Surgical reconstruction of the interdental papilla: case report. *Int J Periodontics Restorative Dent*. 1992;12(2):145–51.
- [30]. Chaulkar P, Mali R, Mali A, Lele P, Patil P. A comparative evaluation of papillary reconstruction by modified Beagle’s technique with the Beagle’s surgical technique: A clinical and radiographic study. *J Indian Soc Periodontol*. 2017;21(3):218.
- [31]. Azzi R, Etienne D, Carranza F. Surgical reconstruction of the interdental papilla. *Int J Periodontics Restorative Dent*. 1998 Oct;18(5):466–73.
- [32]. Root coverage and papilla reconstruction using autogenous osseous and connective tissue grafts. *Int J Periodontics Restorative Dent*.
- [33]. Nordland WP, Sandhu HS, Perio C. Microsurgical technique for augmentation of the interdental papilla: three case reports. *Int J Periodontics Restorative Dent*. 2008 Dec;28(6):543–9.
- [34]. Carranza N, Odont D, Zogbi C. Reconstruction of the Interdental Papilla with an Underlying Subepithelial Connective Tissue Graft: Technical Considerations and Case Reports. *Restorative Dentistry*. 2011;31(5):6.
- [35]. A novel surgical procedure for papilla reconstruction using platelet rich fibrin.
- [36]. Jhamb K. Clinical Evaluation of Papilla Reconstruction Using Subepithelial Connective Tissue Graft. *JCDR [Internet]*. 2014 [cited 2021 Apr 30]; Available from: http://jcdr.net/article_fulltext.asp?issn=0973-709x&year=2014&volume=8&issue=9&page=ZC77&issn=0973-709x&id=4881
- [37]. Feuillet D, Keller J-F, Agossa K. Interproximal Tunneling with a Customized Connective Tissue Graft: A Microsurgical Technique for Interdental Papilla Reconstruction. *Int J Periodontics Restorative Dent*. 2018 Nov;38(6):833–9.
- [38]. Arnoux J-P, Weisgold AS, Lu J. Single-Tooth Anterior Implant: A Word of Caution, Part II. *J Esthet Restor Dent*. 1997 Nov;9(6):285–94.
- [39]. Adriaenssens P, Hermans M, Ingber A, Prestipino V, Daelemans P, Malevez C. Palatal Sliding Strip Flap: Soft Tissue Management to Restore Maxillary Anterior Esthetics at Stage 2 Surgery: A Clinical Report. 2000;7.
- [40]. Nemcovsky CE, Moses O, Artzi Z. Interproximal Papillae Reconstruction in Maxillary Implants. *Journal of Periodontology*. 2000 Feb;71(2):308–14.
- [41]. Charde P, Bhongade ML, Deshpande A, Jadhav A, Thakare K, Jaiswal P. Interimplant Papilla Reconstruction by Using Demineralized Freeze Dried Bone Allograft Block Fixed by Titanium Screw: A Case Report. *Case Reports in Dentistry*. 2012;2012:1–3.
- [42]. Froum S, Lagoudis M, Rojas GM, Suzuki T, Cho S-C. New Surgical Protocol to Create Interimplant Papilla: The Preliminary Results of a Case Series. *Restorative Dentistry*. 2016;36(2):9.
- [43]. Sharanappa M, Konuganti K, Kumar A, Lnu R. Papilla Reconstruction: Reclaiming the Lost! *Journal of Health Sciences & Research*. 2016 Jun;7(1):19–22.
- [44]. Interdisciplinary approach to reconstruct papilla in esthetic zone : A Case Series 2021.
- [45]. Gupta S, Deo V, Williams C. Interproximal Papillae Reconstruction around Implant Using Subepithelial Connective Tissue Graft in Maxillary Anterior Region: A Case Series. *JOMR [Internet]*. 2012 Apr 10 [cited 2021 Jul 18];3(2). Available from: <http://www.ejomr.org/JOMR/archives/2012/2/e1/v3n2e1ht.htm>
- [46]. Microsurgical technique for papilla reconstruction: A case report 2018.
- [47]. Hennig MAM, Mustafa JM, Muszkopf ML. Absence of interdental papilla – Systematic review of available therapeutic modalities. 2016;22:14.
- [48]. Santhosh Shenoy B,1 Anahita Punj , Amitha Ramesh , Avaneendra Talwar; Salvaging the lost pink triangle : A case series of Papilla Reconstruction 2020.