

Spheno-Orbital Meningiomas: Surgical Results and Review of the Literature

A Retrospective Descriptive Study of 37 Operated Cases over the Past 10 Years

K,Bouaita¹,T, selmane², A, Mati.

Department neurosurgery chercHELL, Algeria
universityblida, Algeria

Abstract:

Aim: This retrospective study aims to evaluate our results according to figures in the literature and to conclude about the best choice of surgical approach as well as long term results in the management of SOM. Spheno-orbital meningiomas are a rare location of grade I meningioma that arise from the sphenoid wing and cause hyperostosis with a large dural infiltration. This tumour can invade important neurovascular structures such as the optic nerve, occulo motor nerves, peri orbit and the cavernous sinus (CS). Surgery of SOM addresses the balance between gross total tumour removal and the long-term progression free survival with low recurrence rate. Patients and methods: In this study we are reviewing a serie of 37 patients operated from SOM in the period between 2011 and 2021 in two reference centres in Algeria. This retrospective study aims to evaluate our results according to figures in the literature and to conclude about the best choice of surgical approach as well as long term results in the management of SOM. Results: SOM account for 7% of all the intra cranial meningiomas operated in our centre, 33 patients operated from SOM were females and 4 males. Their age ranges from 19 to 68 years old. Proptosis was the most common clinical feature that was found in 89% of cases followed by eye motility dysfunction in 15 cases. There were two surgical approaches adopted for our cases: the supra orbital pterional approach was adopted in 81% with the unroofing of the optic canal in 48% and the lateral orbitotomy was used for 07 cases (19%) with micro surgical orbital roof and sphenoid wing removal. Conclusion: The large surgical removal of SOM remains the key factor for long recurrence free outcome with good progression free survival. On the other hand, excessive tumour resection can risk eye motility dysfunction and extra complication rate due to the infiltration of the orbital apex and the cavernous sinus (CS).

Keywords: Spheno-orbital meningiomas, Orbitosphenoid meningiomas, meningioma “en plaque”, Optic nerve

Abbreviations: Optic nerve: ON, spheno-orbital meningiomas: SOM, Cavernous Sinus: CS, progression free survival: PFS

Date of Submission: 25-09-2021

Date of Acceptance: 08-10-2021

I. Introduction

Spheno orbital meningioma or orbito sphenoid meningioma is a specific pathological entity that was first described by Cushing and Eisenhardt in 1938 as “meningiomas en plaque”[1,2,3,4,6]

The spheno-orbital meningiomas arise from the arachnoid cap cells of the arachnoid granulations and follow neural structures involving secondarily the orbit. In the opposite the latter is different of the rarer primary meningiomas of the orbit which arise from the optic nerve sheath and causes hyperostosis[1,8,12,15,16].

The recent description of the SOM as meningiomas arising from any part of the sphenoid wing associating with “en plaque” feature or hyperostosis with further extension to the orbit and the CS. The ON is found particularly compressed when the hyperostosis reaches the orbital apex. SOM can invade the anterior and middle cerebral fossae, para nasal sinuses and even the infra temporal region[4,5,12].

The understanding of the proper anatomical and pathological features has evolved in the past decades leading to a better overall outcome with low recurrences rate. The supra orbital approach was adopted in most cases of SOM that needs the opening of supra orbital fissure and/or the clinoid process with the optic canal. surgical procedure of SOM with extension to the orbit requires better understanding of the local anatomy of the orbit[15,20,25].

Modern imaging techniques and the use of recent surgical techniques helped surgeons to achieve high resection rate with better functional preservation when compared with earlier series[1,25].

Recurrences remain the main complication of this site of meningiomas as it showed historically 35-50% of recurrences rate[10,13,19,21]

Recent technological advances such as the stereotactic radiation technique allowed a longer symptom free interval for patients presenting with recurrences but still present some difficulties when applied due to the proximity of the tumour to the ON[1,5].

II. Patients And Methods

We are presenting a retrospective analytic study of 37 cases of SOM operated on in the period between 2011 and 2021 in two specialized neurosurgical centres (Ali Ait Idir specialized hospital in Algiers and the Neurosurgical specialized hospital in Cherchell – Tipaza). Our cases were referred to our department mainly by ophthalmologists after a documented SOM was shown on imaging (MRI and CT scan) with an objective ophthalmological examination.

CT scan was performed for all our patients in the early post-operative period to assess the bony removal of the hyperostosis with an accurate analysis of the optic canal and the superior orbital fissure. MRI control was performed after 6 months of surgery firstly, then periodically every year to evaluate any recurrences or tumor growth along with ophthalmological follow up. The actual follow up ranges from 1 to 9 years. The extent of tumour resection was obtained after post-operative MRI examination

III. Clinical Findings

SOM accounted for 7 % of all intra cranial meningiomas operated in the same period. Patients were 33 females and 4 males with patient age ranges from 19 to 68 years (sex ratio is 1 male/8 females).

Variable degree of Proptosis was the main clinical feature of our Serie represented by 89.1% followed by Unilateral optic neuropathy that was found in 60%, while diplopia and eye motility dysfunction involved 7 cases (19%). Other minor neurological symptoms like headaches and seizures were reported about 14 patients.

Neuroradiological findings were assessed by MRI and CT scan that were performed in all our patients.

CT scan is particularly important to define the hyperostosis of the sphenoid bone and the surrounding bony structures, while MRI imaging evaluate the extent of SOM and its relationship to the neurovascular structures. Pathological study show that all our cases were grade I meningiomas

IV. Results

Two surgical approaches were used in our Serie. The supra orbital pterional approach was adopted in the majority of cases for SOM with lateral, supero lateral and orbital apex extension of the tumour. The supra orbital pterional approach was used in 81% with optic canal unroofing in 48.6% of the operated cases by this approach. On the other hand, the lateral orbitotomy was performed in 07 cases (19%) with the removal of the orbital roof and the sphenoid wing under microsurgical procedure

The reconstruction of the fronto temporal bone was performed using acrylic material after the supra orbital pterional approach.

Table 1: clinical features

Proptosis	89.1% (33 cases)
Eye motility dysfunction	40.5% (15 cases)
Optic disc abnormalities	43% (16 cases)
Ptosis	8.1% (3 cases)
Cranial nerve dysfunction	10.8% (4 cases)

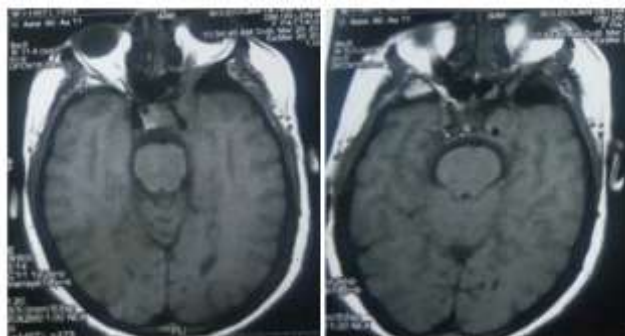


Figure 1: preoperative MRI showing the intra orbital SOM, invasion of CS with hyperostosis of the lesser left sphenoid wing

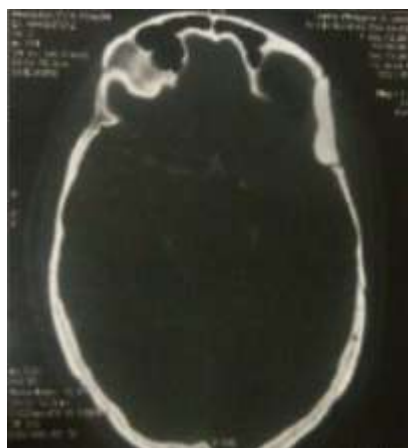

Figure 2: Post operative CT scan showing the extent of the bony removal with acrylic material reconstruction of the fronto-pterional vault

Proptosis reduction was obtained under different degrees early after surgery with the rate of 60% depending on the previous proptosis state. Good cosmetic results were achieved for the majority of our cases. Reconstruction of the frontal vault was performed in 12 patients operated from diffuse SOM.

The extent of tumour resection was evaluated after post-operative CT scan and MRI. Therefore, complete tumour resection was achieved in 70% of our cases which are related to Simpson grade I and II. The latter are put in the same category due to the difficulty to define the limit of dural resection. Simpson grade III and IV were obtained in 6 patients (16.2%) and 5 patients (13.5%) respectively. After reviewing our cases, Simpson grade I&II tumour removal were more prone to be achieved in lateral and supero lateral location of SOM in the opposite of the diffuse SOM for which the tumor removal was incomplete in 6 cases (16.2%). Also, the infiltration of the CS and the superior orbital fissure limit the extent of tumour removal to avoid further neurological deficit without any long-term outcome.

V. Complications

Visual worsening was observed in 4 patients operated from type III and IV, while 8 patients presented a transient proptosis who were recovered after 3 months. Diplopia was seen in 3 patients due to the infiltration of the superior orbital fissure.

The delay for recurrences appearance varies according to the extent of tumour removal. The overall recurrences rate in our series was 35% with early recurrences found 3 years after surgery which refers to Simpson III & IV of tumour removal quality. The recurrence rate seems to be related to the initial tumour location in the diffuse forms as well as the orbital apex types. Hence, the lateral and the supra lateral forms are more prone to complete tumour resection and consequently to lower or no recurrences rate. From all the 13 patients who showed recurrences 08 were reoperated with large tumour removal and reconstruction of the frontal vault using acrylic material to reduce cosmetic prejudice. The tumour progression after the second surgery was controlled in 5 patients with 3 other patients were referred to radiation therapy.

VI. Discussion

Despite the modern advances in neurosurgical techniques, SOM's are still considered as a challenging lesion due to the requirements that need to be addressed when operating such lesion like the total removal of the tumour from intra cranial space and the orbit, the infiltrated dura, the removal of the hyperostosis while preventing further neurological deficits [1,4,15,16,25]. In practice, those requirements can only be achieved in some cases. Furthermore, controversies about the need of the removal of the CS infiltration with large bone flap and resection of the zygomatic bones are still under debate [1,13,14,15].

It is admitted that SOM's are characterized by large dural infiltration which is unclear to be defined. Therefore, Simpson grade I & II is inadequate to be applied to evaluate the extent of resection or to predict the rate of recurrences such as the other locations of intra cranial meningiomas. Accordingly, the resection rate tends to be overestimated in SOM's [1,3].

Many surgical approaches were described in the literature for SOM's like lateral orbitotomy, supra-orbital-pterional, fronto-temporal-orbito-zygomatic, fronto-orbito-malar and pterional. The approach is chosen according to the tumour location and its extension as well as the personal surgeon's experience to achieve a complete total resection of the tumour and to avoid surgery related complications [8,10,11]

In our series, we used two approaches, the supra-orbital pterional approach in 81% and the lateral orbitotomy in 19%. The different approaches described in the literature were advocated by some authors to answer the surgical

challenges in the purpose to achieve a large total removal of the tumour with the lowest recurrence rate. The intra orbital part of the tumour was found in 15 cases and it influences the choice of the surgical approach with or without craniotomy. The supra orbital pterional approach was chosen in our series as it can reach the intra cranial, intra orbital and allows the optic canal opening. This approach is limited by the infiltration of the CS and diffuse inferiortypes of SOM's.

The supraorbital pterional approach can be applied for type II, III, and IV. Larger and diffuse SOM in type IV can also be approached via the fronto-temporal-orbitozygomatic approach to remove the inferomedial tumour component according to some authors[1,5].

The fronto-temporal-orbitozygomatic approach is reserved for large meningiomas with significant invasion of the infra temporal fossae[10,18,24].

The fronto-orbito malar approach was not used in our series as it needs large skin incision and bone flap while the same result attempted can be achieved with a smaller incision allowing good visualisation by drilling the hyperostosis[1].

The periorbita is removed when it is infiltrated more aggressively than the extra ocular muscles to avoid recurrences and to preserve ocular motility post operatively[1].

The Radical and excessive surgical removal of the infiltrated CS, the orbital apex and the superior orbital fissure can carry a higher risk of neurological deficits and functional eye disturbances[1,15,16,25]. Additionally, it was shown that the extensive tumour removal does not affect the rate of recurrences while risking or causing a poor post-operative outcome[5]. Leroy and al reported a poor PFS associated with the infiltration of CS and the OC while showing that the unroofing of the OC helped significantly the PFS[2,5].

The reconstruction of the frontal vault by acrylic material is not advocated for every operated patient due to the overall good results in most cases and to the fact that meningiomas are unlikely to develop in that the operated site. On the other hand, some authors advocate the use of acrylic material reconstruction for large SOM which are prone to regrowth by helping a safe reoperation and preventing fibrosis in the operated site[1,15,23].

Many features of SOM's like the large dural and bone invasion, infiltration of the periorbita, invasion of the superior orbital fissure and the optic canal as well as the CS tend all to participate in the regrowth and recurrence of SOM. On the other hand, it is unnecessary to achieve large tumour removal that risks further neurological deficits with eye motility dysfunction. The rate of recurrences varies significantly in the literature between 8 to 60% and even 82% in some series. Surgeons appreciation varies between series to define evidence of regrowth or recurrence of an operated SOM as well as an underestimation of bone and dura infiltration. The recurrence rate is found to be particularly related to the extent and size of the intra orbital portion of SOM which was less addressed in the previous series[9,14,21].

Total resection rate was achieved classically in small and mid-sized SOM lateral and supero-lateral to the orbit in the opposite of SOM's Located in the apex which are associated with a higher recurrence rate. Recurrences of SOM's increases progressively over the years. The rate of recurrences is better reflected by the longer period of time after surgery[1,13,15,16,19,24].

Studies vary about the effectiveness of radiotherapy after SOM surgery. However, in a Jürgen Grauvogel study, a significant PFS was shown after 5 years in the group of patients who received radiotherapy after Subtotal resection[5]. The small number of cases and the retrospective character of the study does not conclude objectively about the place of radiotherapy after SOM Surgery. Other studies who recommended radiotherapy after meningiomas surgery did not include large number of cases. Also, Boari and co recommended radiotherapy for cases showing invasion of the superior orbital fissure and the cavernous sinus to achieve low surgical morbidity[5,9].

Studies aiming to evaluate the benefit of radiotherapy were found limited by the small number of cases and the retrospective study making the interpretation of results variable concerning the evaluation of the tumour removal rate[1,5].

VII. Conclusion

Large tumour resection with function preservation are important factors for PFS and long-term recurrence free. However, the tumour infiltration of the orbital apex, superior orbital fissure and the cavernous sinus appear to represent an independent factor associated with poor PFS and high recurrence rate. Post-operative radiotherapy can be considered for subtotal tumour resection to delay long-term complications.

References

- [1]. G. Mariniello, F. Maiuri, D. Strianese, Spheno-orbital Meningiomas: Surgical Approaches and Outcome According to the Intraorbital Tumor Extent *Zentralblatt für Neurochirurgie* · August 2008, DOI: 10.1055/s-2008-1077077 ·
- [2]. Oya S, Sade B, Lee JH. Sphenoorbital Meningioma: Surgical Technique and Outcome. *J Neurosurg* (2011) 114:1241–9. doi:0.3171/2010.10.JNS101128
- [3]. Ringel F, Cedzich C, Schramm J. Microsurgical Technique and Results of a Series of 63 Spheno-Orbital Meningiomas. *Neurosurgery* (2007) 60:214–21; discussion 221. doi: 10.1227/01.NEU.0000255415.47937.1A

- [4]. Terrier L-M, Bernard F, Fournier H-D, Morandi X, Velut S, Hénaux P-L, et al. Spheno-Orbital Meningiomas Surgery: Multicenter Management Study for Complex Extensive Tumors. *World Neurosurg* (2018) 112: e145–56. doi: 10.1016/j.wneu.2017.12.182
- [5]. Boari N, Gagliardi F, Spina A, Bailo M, Franzin A, Mortini P. Management of Spheno-Orbital En Plaque Meningiomas: Clinical Outcome in a Consecutive Series of 40 Patients. *Br J Neurosurg*(2013) 27:84–90. doi: 10.3109/02688697.2012.709557
- [6]. Rogers L, Barani I, Chamberlain M, Kaley TJ, McDermott M, Raizer J, et al. Meningiomas: Knowledge Base, Treatment Outcomes, and Uncertainties. A RANO Review. *J Neurosurg* (2015) 122:4–23. doi: 10.3171/2014.7.JNS131644
- [7]. Combs SE, Farzin M, Boehmer J, Oehlke O, Molls M, Debus J, et al. Clinical Outcome After High-Precision Radiotherapy for Skull Base Meningiomas: Pooled Data from Three Large German Centers for Radiation Oncology. *RadiotherOncol* (2018) 127:274–9. doi: 10.1016/j.radonc.2018.03.006
- [8]. Freeman JL, Davern MS, Oushy S, Sillau S, Ormond DR, Youssef AS, et al. Spheno-Orbital Meningiomas: A 16-Year Surgical Experience. *WorldNeurosurg* (2017) 99:369–80. doi: 10.1016/j.wneu.2016.12.063
- [9]. Honig S, Trantakis C, Frerich B, Sterker I, Schober R, Meixensberger J. Spheno-Orbital Meningiomas: Outcome After Microsurgical Treatment: A Clinical Review of 30 Cases. *Neurol Res* (2010) 32:314–25. doi: 10.1179/016164109X12464612122614
- [10]. Sandalcioglu IE, Gasser T, Mohr C, Stolke D, Wiedemayer H. Spheno-Orbital Meningiomas: Interdisciplinary Surgical Approach, Resectability and Long-Term Results. *J CraniomaxillofacSurg* (2005) 33 :260–6. doi: 10.1016/j.jcms.2005.01.013
- [11]. Nagahama A, Goto T, Nagm A, Tanoue Y, Watanabe Y, Arima H, et al. Spheno-Orbital Meningioma: Surgical Outcomes and Management of Recurrence. *World Neurosurg* (2019) 126: e679–87. doi: 10.1016/j.wneu.2019.02.123
- [12]. Cannon PS, Rutherford SA, Richardson PL, King A, Leatherbarrow B. The Surgical Management and Outcomes for Spheno-Orbital Meningiomas: A 7-Year Review of Multi-Disciplinary Practice. *Orbit* (2009) 28:371–6. doi:10.3109/01676830903104645
- [13]. Samadian M, Sharifi G, Mousavinejad SA, Amin AA, Ebrahimzadeh K, Tavassol HH, et al. Surgical Outcomes of Sphenoorbital En PlaqueMeningioma: A 10-Year Experience in 57 Consecutive Cases. *World Neurosurg* (2020) 144: e576–81. doi: 10.1016/j.wneu.2020.09.002
- [14]. AdegbiteAB, Kahn MI, Paine KWE, Tan LK. The recurrence of intracranial meningiomas after surgical treatment. *J Neurosurg*1983;58: 51 – 56
- [15]. DolencV. Microsurgical removal of large sphenoidal bone meningiomas. *ActaNeurochir* (Wien) 1979;28: 391 – 396
- [16]. MacDermottMW, DurityFA, RootmanJ, WoodhurstWB. Combined frontotemporal-orbitozygomatic approach for tumors of the sphenoid wing and orbit. *Neurosurgery* 1990;26: 107 – 116
- [17]. Newman SA, Jane J A. Meningiomas of the optic nerve, orbit and anterior visual pathways. In: Al Mefty O (ed). *Meningiomas*. Raven Press, New York 1991, chapt. 38 : 461 – 494
- [18]. PompiliA, DeromePJ, VisotaA, GuiotG. Hyperostosing meningiomas of the sphenoid ridge – clinical features, surgical therapy, and long-term observations: review of 49 cases. *SurgNeurol*1982;17: 411 – 416
- [19]. Simpson D. The recurrence of intracranial meningiomas after surgical treatment. *J NeurolNeurosurgPsychiatr*1957;20: 22 – 39
- [20]. BrotchiJ, LevivierM, RaftopoulosC, NotermanJ. Invading meningiomas of sphenoid wing. What must we know before surgery? *ActaNeurochirSuppl* (Wien) 1991 ; 53 : 98 – 100
- [21]. PhilipponJ. The recurrence of meningiomas. *Neurochirurgie*1986; 32 (Suppl 1): 575
- [22]. Belinsky I, Murchison AP, Evans JJ, Andrews DW, Farrell CJ, Casey JP, et al. Spheno-Orbital Meningiomas: An Analysis Based on World Health Organization Classification and Ki-67 Proliferative Index. *OphthalPlastReconstrSurg* (2018) 34:143–50. doi: 10.1097/IOP.0000000000000904
- [23]. Leake D, Gunnlaugsson C, Urban J, Marentette L. Reconstruction After Resection of Sphenoid Wing Meningiomas. *Arch Facial PlastSurg* (2005) 7:99–103. doi: 10.1001/archfaci.7.2.99
- [24]. Saeed P, van Furth WR, Tanck M, Kooremans F, Freling N, Streekstra GI, et al. Natural History of Spheno-Orbital Meningiomas. *ActaNeurochir* (Wien) (2011) 153 :395–402. doi: 10.1007/s00701-010-0878-0
- [25]. Bikmaz K, Mrak R, Al-Mefty O. Management of Bone-Invasive, Hyperostotic Sphenoid Wing Meningiomas. *J Neurosurg* (2007) 107:905–12. doi: 10.3171/JNS-07/11/0905

K, Bouaita, et al. “Spheno-Orbital Meningiomas: Surgical Results and Review of the Literature A Retrospective Descriptive Study of 37 Operated Cases over the Past 10 Years.” *IOSR Journal of Dental and Medical Sciences (IOSR-JDMS)*, 20(10), 2021, pp. 47-51.