

## Fixed twin block treatment for a non-compliant growing patient- A case report

Glodwin Antony<sup>1</sup>, Mithun K Naik<sup>2</sup>, Sachin Shaji<sup>3</sup>, Shetty Suhani Sudhakar<sup>4</sup>,  
Nishanth Shetty<sup>5</sup>

<sup>1</sup>(Consultant orthodontist, Ernakulam, Kerala, India)

<sup>2</sup>(A.J. Institute of Dental Sciences, Mangalore, Karnataka, India)

<sup>3</sup>(Consultant orthodontist, Ernakulam, Kerala, India)

<sup>4</sup>(Srinivas Institute of Dental Sciences, Mangalore, Karnataka, India)

<sup>5</sup>(Consultant orthodontist, Bangalore, Karnataka, India)

---

### Abstract:

Patients with class II malocclusion generally seek orthodontic treatment for esthetic concern. Functional appliance have been treatment of choice for growing patient with skeletal class II malocclusion. Twin block is one such removable appliance which is simple, efficient, removable appliance which is to be worn 24 hours. One of the major disadvantage of removable appliance is patient compliance. Here's a case report demonstrating a female patient treated with fixed twin block which eliminates the need of patient compliance and ensures full time wear of the appliance. 12 year old girl with mandibular retrognathism was treated with fixed twin block. This appliance when given during growing phase produce the good skeletal effect and pleasing soft tissue profile

**Key Word:** Fixed twin block appliance, Functional appliance, Growth modulation, Skeletal class II malocclusion..

---

Date of Submission: 25-09-2021

Date of Acceptance: 08-10-2021

---

### I. Introduction

Class II malocclusion is one of the most commonly seen malocclusion in orthodontic practice. Approximately one third of the patients with class II malocclusion seek orthodontic treatment<sup>1,2</sup> Class II can be either due to maxillary protrusion, mandibular retrusion or both, along with dental and soft tissue profile abnormalities.<sup>3</sup> Mandibular retrognathism is one of the most characteristic feature of skeletal class II malocclusion.<sup>4</sup>

Functional appliance have been treatment of choice for growing patient with skeletal class II malocclusion. Functional appliance can either be fixed or removable. Twin block is one such removable appliance which was described in 1977 by Dr. William Clark. It is a simple, efficient appliance which is to be worn 24 hours.<sup>5</sup> Main objective of twin block is to induce mandibular lengthening by stimulating condylar growth.<sup>6</sup> One of the major disadvantage of removable appliance is patient compliance.

Here's a case report demonstrating a case treated with fixed twin block which eliminates the need of patient compliance and ensures full time wear of the appliance.

### II. Case report

Female patient aged 12 years came to the department of orthodontics and dentofacial orthopaedics with the chief complaint of forwardly placed upper front teeth. Patient has no relevant dental and medical history. Patient's brother had similar malocclusion. On behavior examination, the patient was found to be uncooperative. On extraoral examination, patient had an oval facial form, convex profile, posterior divergence, incompetent lip and acute nasolabial angle. Patient had a protruded upper lip and retruded lower lip. On intraoral examination all permanent teeth except third molars were present with good oral hygiene. She had generalized fluorosis. She had Angle's class II molar relationship bilaterally, class II canine relationship bilaterally, increased overjet of 12mm and overbite of 80% as shown in figure 1.

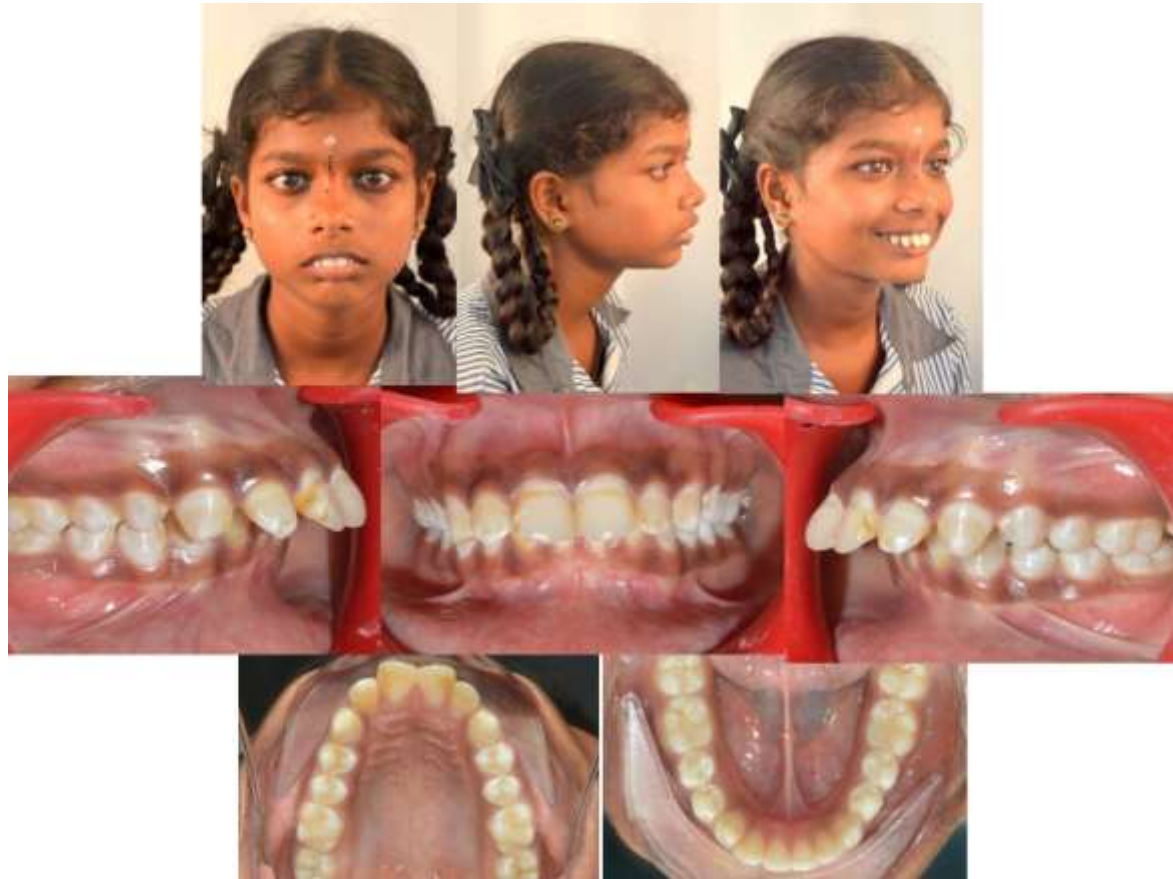

Figure 1- Pre treatment photograph

Cephalometrically, patient had an ANB of  $5^\circ$ , reduced mandibular length by 8mm. Patient had an average growth pattern, upper and lower anterior proclination and acute nasolabial angle. Orthopantomograph revealed that there was no underlying pathology or impacted teeth. The visual treatment objective (VTO) of the patient was positive and suggested that the patient can be treated with growth modulation. On hand-wrist radiograph, patient was found to be in skeletal maturity index-4 which is favorable for functional appliance therapy.

Diagnosis was skeletal class II base due to retrognathic mandible and average growth pattern with Angles's class II malocclusion with bimaxillary protrusion, deepbite and acute nasolabial angle.

#### **Treatment objective**

1. Correction of reduced mandibular length.
2. Correction of proclined upper and lower anteriors.
3. Correction of overjet.
4. Correction of overbite.
5. Correction of curve of spee.
6. Correction of protruded upper & retruded lower lip.
7. Attaining pleasing soft tissue profile.

#### **Treatment alternative**

Conventional twin block treatment was planned for the treatment but as patient was not co-operative, removable twin block treatment option was discarded

#### **Treatment plan**

As the patient had skeletal and dental Class II relationship and hand-wrist radiograph indicated that he had considerable amount of growth remaining, growth modification was planned using functional appliance followed by fixed orthodontic appliance for final detailing of occlusion. Fixed twin block was decided upon. Construction bite was taken with advancement of 10mm which was 70% of protrusive pathway as per the recommendation of Roccabado<sup>5</sup> and 5mm inter-premolar vertical opening. Fixed twin block was fabricated with heat cure acrylic as shown in figure 2. Two inclined plane were place on one arch each. Angulation of  $70^\circ$  was

placed between upper and lower block. Upper block was connected with a transpalatal bar made of 0.9mm stainless steel wire. Lower block was also connected by wire which ran on the lingual alveolar bone on the lower arch.

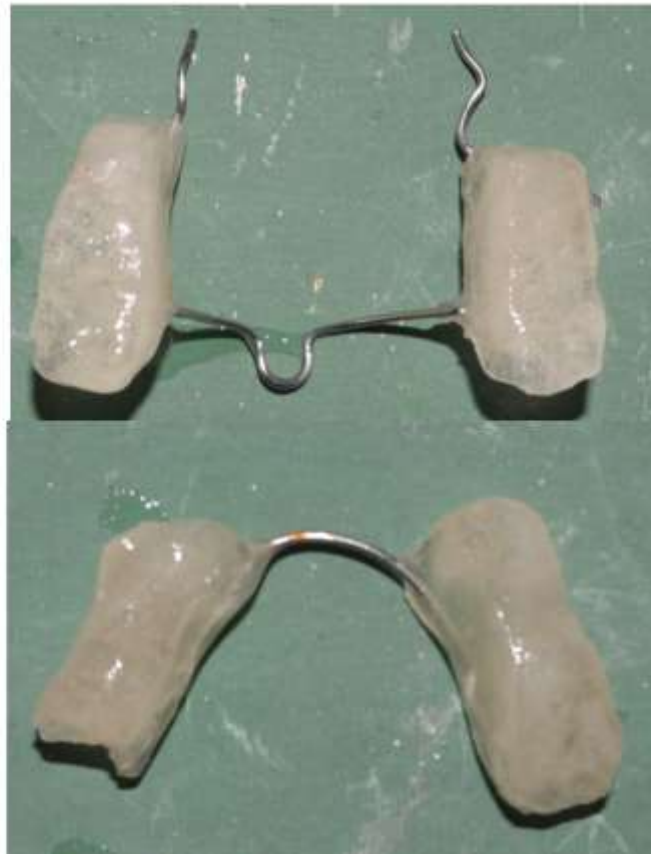


Figure 2- Fabrication of fixed twin block

Figure 3 shows the appliance after placing in patient's mouth. Fabricated appliance is fixed to the upper and lower arch with Type 1 GIC.

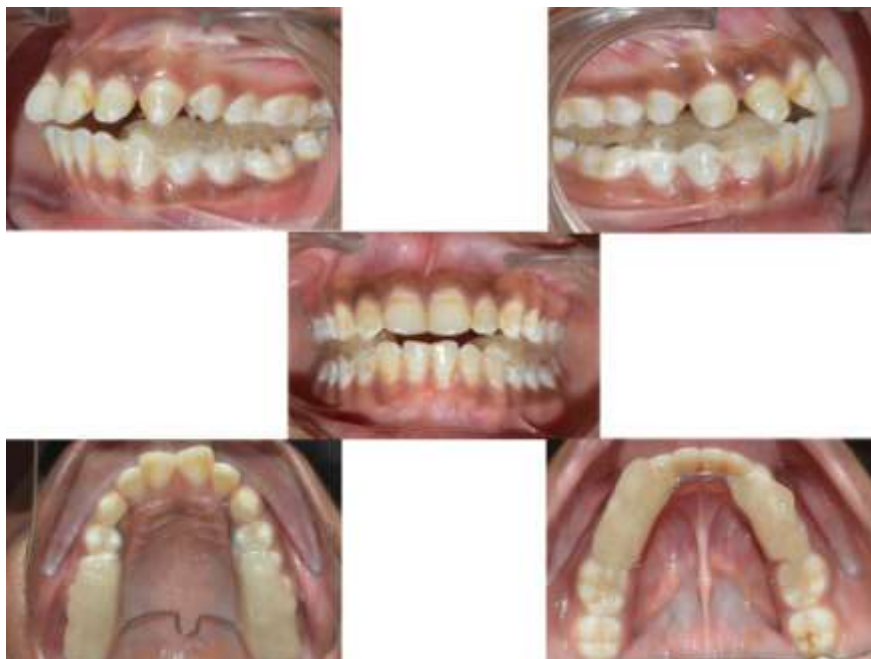

Figure 3- photograph after appliance placement.

Trimming is recommended in deepbite case but this could not be carried out as the appliance was fixed. The patient was advised to do lip exercise to achieve lip competency. Patient was recalled every four weeks to check the changes and any sign of breakage. Posterior open bite which appears was later treated with fixed orthodontic treatment.

### **Treatment results**

After 8 months period of wear, the significant improvement was noted in profile and lip competency. Significant correction in molar and the canine relation was obtained along with significant reduction in overjet and overbite. Post-functional intra-oral and extra-oral photographs is shown in figure 4. ANB value also changed to  $5^{\circ}$  to  $2^{\circ}$  which denotes a skeletal class 1 base and mandibular length increased from 103mm to 110mm. Fixed anterior plate was placed in the upper arch for retention which was to be followed by fixed orthodontic therapy.

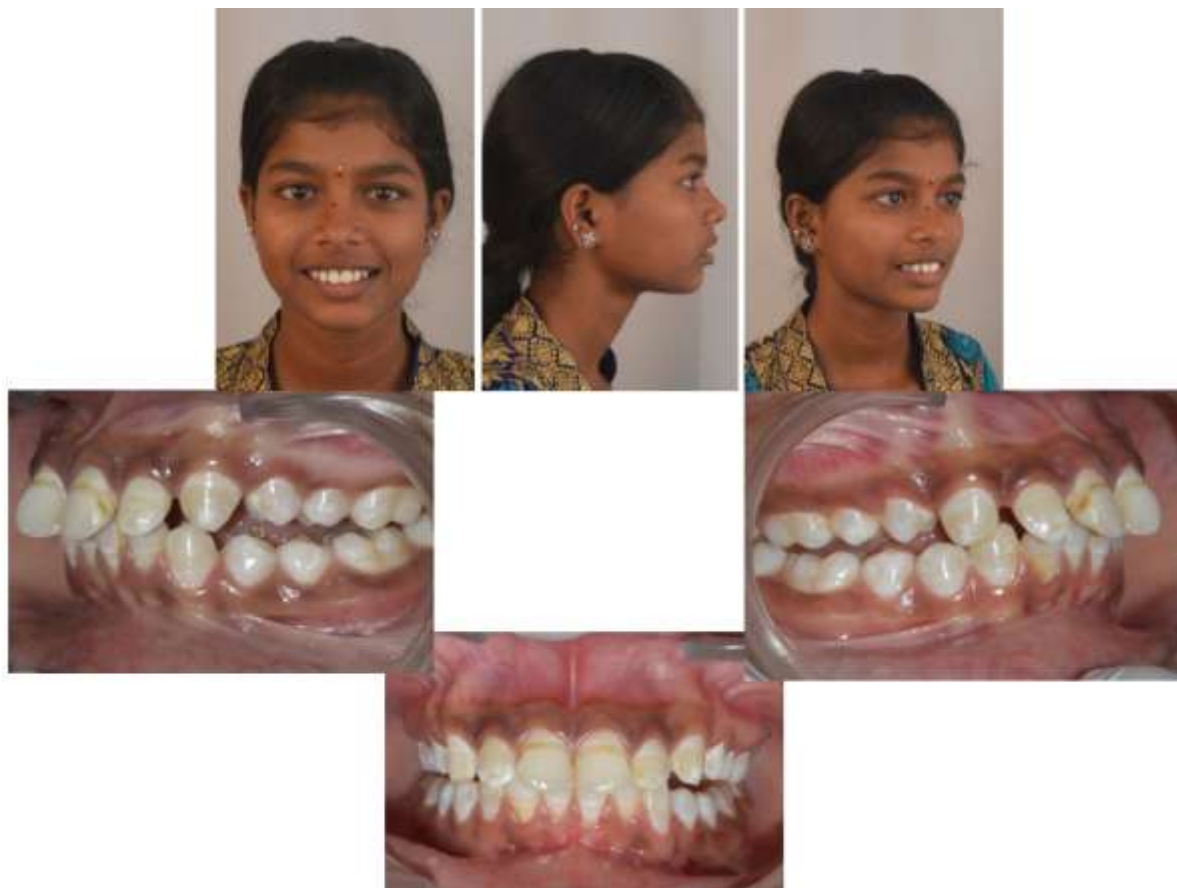

Figure 4- post treatment photographs

### **III. Discussion**

Skeletal class II malocclusion is one of the most common malocclusion seen. Patient with skeletal class II with growth potential, can be treated with appliance which modify or redirect growth. Functional appliances are the appliance of choice for treating class II with retrognathic mandible.<sup>7</sup> Twin block is preferred over other functional appliance as attributes to greater mandibular growth and lesser altered speech.<sup>8</sup> Thus, the treatment of choice for this patient was twin block.

Twin block was given in 1977 by Dr. Clark which was a simple, efficient, removable appliance to redirect mandibular growth, with the recommended 24 hours wear. Patient acceptance with twin block is good.<sup>5</sup> but our patient was highly unco-operative thus compliance was a concern. Thus, we decided on fixed twin block as it overcomes the compliance problem and ensures 24 hours wear.

Significant changes were seen within 2 to 3 months of use of twin blocks. The changes can be attributed to the altered muscle balance due to continuous wear of the appliance. The total treatment time in our case was 9 months of active treatment. We were able to achieve 7mm increase in mandibular length.

We have modified the original design of twin block by giving only the occlusal bite blocks, which rested on a stainless steel wire framework. The wire framework was made using a 0.9 mm stainless steel wire which was placed in both upper and lower arches. The bite planes were made on the wire framework with heat cure clear acrylic. The bite blocks were inclined by 70° to each other.<sup>9</sup>

Correction of the skeletal malocclusion was maintained with an inclined bite plane during the retention period which was followed by fixed orthodontic treatment for posterior openbite correction

#### **IV. Conclusion**

The fixed twin block appliance significantly increases mandibular length as compared with the normative growth. They correct the underlying skeletal malocclusion and reduce the treatment duration of fixed orthodontic appliance.

The fixed design of the twin block described in this article can be used in uncooperative patients for better treatment results.

#### **References**

- [1]. Proffit WR, Fields HW Jr, Moray LJ. Prevalence of malocclusion and orthodontic treatment need in the United States: estimates from the NHANES III survey. *Int J Adult OrthodonOrthognath Surg.* 1998; 13:97–106.
- [2]. Celikoglu M, Akpınar S, Yavuz I. The pattern of malocclusion in a sample of orthodontic patients from Turkey. *Med Oral Patol Oral Cir Bucal.* 2010; 15:e791–e796.
- [3]. Arici S, Akan H, Yakubov K, Arici N. Effects of fixed functional appliance treatment on the temporomandibular joint. *Am J OrthodDentofacialOrthop.* 2008; 133:809–814.
- [4]. McNamara JA Jr. Components of Class II malocclusion in children 8–10 years of age. *Angle Orthod.* 1981; 51:177–202.
- [5]. Clark WJ. The twin block traction technique. *Eur J Orthod* 1982; 4:129-38.
- [6]. J. R. Mills, “The effect of functional appliances on the skeletal pattern,” *British Journal of Orthodontics*, vol. 18, no. 4, pp. 267–275, 1991.
- [7]. Sidlauskas A. The effects of the Twin-block appliance treatment on the skeletal and dentoalveolar changes in Class II Division 1 malocclusion. *Medicina (Kaunas)* 2005 Feb;41(5):392-400.
- [8]. Carmichael GJ, Banks PA, Chadwick SM. A modification to enable controlled progressive advancement of the Twin Block appliance. *Br J Orthod* 1999 Mar;26(1):9-13
- [9]. Baccetti T, Franchi L, Toth LR, McNamara JA Jr. Treatment timing for Twin-block therapy. *Am J OrthodDentofacialOrthop* 2000 Aug;118(2):159-170.

Glodwin Antony, et. al. “Fixed twin block treatment for a non-compliant growing patient- A case report.” *IOSR Journal of Dental and Medical Sciences (IOSR-JDMS)*, 20(10), 2021, pp. 31-35.