

“Role of MRI in Evaluation of Bone Tumour and Tumour Like Lesions”

Dr. Asutosh Dave

(Professor & Head Department of Radio-diagnosis, GCS Medical College, Hospital and Research Centre, Ahmedabad).

- ¹ Dr. Harsh V Thakrar (3rd year Resident in GCS medical college, Ahmedabad).
- ² Dr Ajay Upadhyay (Professor Department of Radio-diagnosis, GCS Medical College, Hospital and Research Centre, Ahmedabad).
- ³ Dr. Anand Patel (3rd year Resident in GCS medical college, Ahmedabad).
- ⁴ Dr. Ashutosh Agarwal (3rd year Resident in GCS medical college, Ahmedabad).
- ⁵ Dr. Radhika Patel (3rd year Resident in GCS medical college, Ahmedabad).

Abstract

Bone tumours and tumour-like lesions are frequently encountered by radiologists. Although radiographs are the primary screening technique, magnetic resonance imaging (MRI) can help narrow the differential or make a specific diagnosis when

a lesion is indeterminate or shows signs of aggressiveness.

MRI can extend the diagnostic evaluation by demonstrating several tissue components.

MRI is superior to the other imaging modalities in detecting bone marrow lesions and tumoral tissue (faint lytic/sclerotic bone lesions can be difficult to visualise using only radiographs).

Contrast-enhanced MRI can reveal the most vascularised parts of the tumour and MRI guidance makes it possible to avoid biopsying necrotic areas.

MRI is very helpful in local staging and surgical planning by assessing the degree of intramedullary extension and invasion of the adjacent physal plates, joints, muscle compartments and neurovascular bundles. It can be used in assessing response to neoadjuvant therapy and further restaging. The posttherapeutic follow-up should also be done using MRI.

Teaching Points

- When a lesion is indeterminate or shows signs of aggressiveness, MRI is indicated.
- When MRI does not lead to a diagnosis, biopsy is indicated.
- MRI is superior to the other imaging modalities in detecting bone marrow lesions.

Keywords Magnetic resonance imaging . Bone neoplasms .

Diagnosis . Neoplasm staging . Follow-up.

Date of Submission: 15-10-2021

Date of Acceptance: 30-10-2021

Aims & Objectives :-

Explain the types of bone tumors and to evaluate the role of MRI (Diagnostic factors and criteria) in differentiating certain bone tumors with tumor like lesions having thin line of diagnostic demarcation.

To explain why MRI is the optimal imaging method for sensitive detection of tumoral tissue, local staging, preoperative evaluation, assessing the response to neoadjuvant therapy, restaging and follow-up.

To discuss potential pitfalls and limitations.

Material and Methods :-

Study was conducted in GCS medical college, Ahmedabad and includes 30 patients (17 female and 13 male patients) over a period of 6 months from July 2020 to December 2020. MRI was done using 1.5 Tesla GE Signa Explorer machine including standard scan protocol.

Inclusion criteria :-

- Any patient referred to the radio diagnosis department for evaluation of bone tumor or tumor like lesion.

Exclusion criteria :-

- Patients whose data is incomplete.
- Patient who have allergic reaction to contrast medium.
- Implanted electric and electronic devices are a relative contraindication to the magnetic resonance imaging, and in particular , heart pacemakers (especially older types) , insulin pumps , implanted hearing aids , neurostimulators , intracranial metal clips , metallic bodies in the eye.

I. Introduction

In the 21st century with the extensive research and development in the field of medicine today we have newer diagnostic modalities in form of advanced MRI scanners , CT machines , PET scanners alongwith that there is availability of newer chemotherapy agents , radiotherapy and salvageable surgical options thus it is important to hit the bulls eye and provide with the most specific diagnosis possible (1).

Conventional Radiographs are still considered as the primary screening technique and is an inseparable part of diagnostic evaluation of any patient presenting with signs and symptoms pertaining to skeletal system , however plain radiograph carries low spatial resolution as well as it has limited role in evaluation of marrow and adjacent soft tissue structure , so when a lesion is indeterminate or shows signs of aggressiveness, CT and magnetic resonance imaging (MRI) is indicated for further evaluation , preferably MRI. It can extend the diagnostic evaluation by delineating components such as cartilage, vascular tissue, fat, liquid and haemosiderin. Even if a specific diagnosis cannot be made, MRI can help by narrowing the differential diagnosis(16 , 22 , 23).

Contrast-enhanced MRI can reveal the most vascularised parts of the lesion and thus guides in taking biopsy thus helps to avoid biopsing necrotic areas. Restaging after neoadjuvant therapy and the post- therapeutic follow-up should also be done using MRI.

MRI PROTOCOL AND ITS IMPORTANT FEATURES IN MSK IMAGING -

- T1-weighted imaging (T1WI)

T1WI is very important in the evaluation of bone marrow. Most bone tumors will be evident as lesions with low signal against a background of surrounding fatty marrow.

- Fat suppression, T2WI and STIR

The use of fat suppression (PDFS) in MRI can confirm or exclude the presence of fat in a lesion (this is particularly useful for diagnosing haemangioma and lipoma).

Water shows higher signal than fat on T2WI, but suppressing the fat signal can allow an even better evaluation of the extent of oedema.

Short tau inversion recovery (STIR) sequences effectively and homogeneously suppress all fat signal but sometimes it can lead to overestimation of the tumoral extension and compromise its characterization.

- Gadolinium-based contrast study

Most bone tumours and tumour-like lesions have a significant amount of cartilaginous tissue (hyperintense on T2WI). CEMRI (Contrast enhanced MRI) can be used in the differentiation between solid hyperintense and fluid-containing lesions. Solid, non- necrotic areas will show diffuse enhancement while physiological fluid containing tissue will not.

Gadolinium-based contrast medium also allows an accurate determination of the degree of vascularisation.

- Diffusion-weighted imaging (DWI)

DWI shows restriction to the diffusion of water molecules in malignant tumours. A favourable therapeutic response is associated with a decrease in the signal intensity in high b values.

- Apparent diffusion coefficient

Apparent diffusion coefficient (ADC) ratios may also be used for assessing the response to neoadjuvant therapy.

➤ MR spectroscopy imaging

Spectroscopy can help differentiate malignant from benign tumors by revealing the presence or absence of water-soluble choline metabolites. Further investigation is needed but MR spectroscopy seems to show great potential in differentiating benign from malignant lesions.

We at GCS hospital ahmedabad follow the following protocol for MSK imaging –

➤ T1-WI in the axial, coronal, and sagittal planes.

➤ T2- in the axial, coronal, and sagittal planes.

➤ T2W STIR (Short tau inversion recovery sequence) AND proton density fat suppression (PDFS) in the axial, coronal and/or sagittal planes.

➤ DW MRI acquired in the axial plane. Images were obtained using b values of 0, 400, and 800 s/mm². The ADCs are expressed numerically and were calculated by manually placing a region of interest (ROI) over the solid portion of the tumor and exclude cystic areas.

➤ Post contrast sequences (in the axial, sagittal, and coronal planes) using intravenous gadolinium (Gd - DTPA) approximately 0.1 – 0.2 mmol/kg body weight, at least one fat-saturated sequence was obtained.

II. Result

The study included 30 patients.

The age groups of patients in the study area is as follows: -

➤ 0-20 years (n = 15)

➤ 21-40 years (n = 09)

➤ 40 years (n = 06)

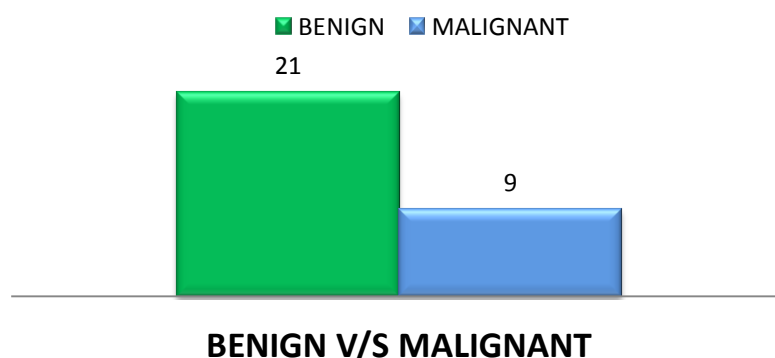
The bone tumour and tumour like lesion were studied using conventional radiographs and MRI.

Out of total population studied 17 (56.6%) were female and 13 (43.4%) were male.

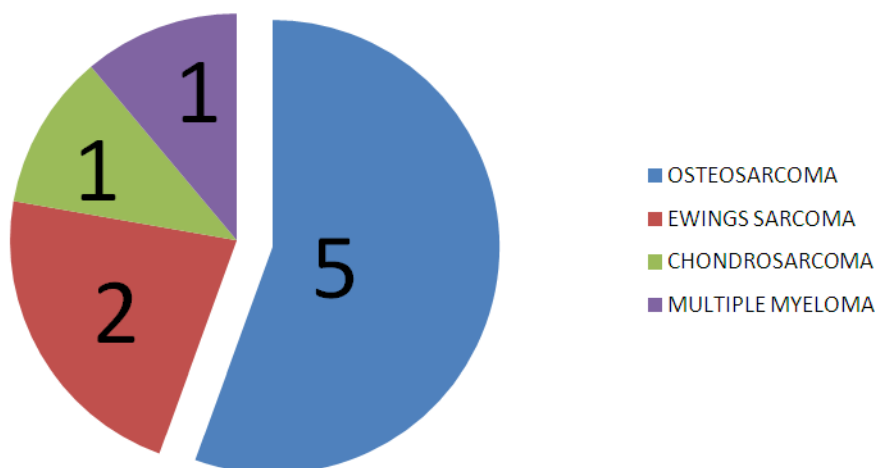
In our study the most common bones involved were long bones to be specific femur followed by tibia. Few of the lesion like osteochondroma (Bony exostosis), enchondromas , hemangioma and multiple myeloma showed multiple lesions.

Benign lesions constituted 70 % of cases (n = 21), whereas malignant lesions constituted 30 % of cases (n = 09).

Overall, the commonest tumour was found to be osteosarcoma and osteochondroma (16 % cases; n = 05 cases each).

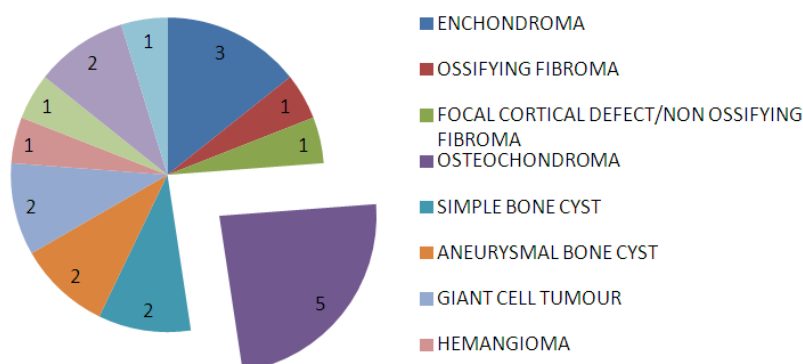


MOST COMMON AMONG MALIGNANT LESION



Out of malignant tumour most common malignant tumour was osteosarcoma (55 % cases; n = 05).

MOST COMMON AMONG BENIGN LESION



Out of benign tumour most common benign tumour was osteochondroma (23 %; n= 05) followed by enchondroma (14 %; n=3).

Most of the benign lesions had well defined margins with narrow zone of transition, whereas nearly all the malignant lesions had ill-defined margins with wide zone of transition except lesion of multiple myeloma in skull which showed well defined margin with narrow zone of transition.

TABLE 1.

Diagnosis	AGE WISE DISTRIBUTION OF CASES			Total
	<=20 years	21-40 years	>40 years	
Enchondroma	0	2	1	3
Ossifying fibroma	0	1	0	1
Focal cortical defect / Non ossifying fibroma	0	1	0	1
Osteochondroma	3	2	0	5
Simple bone cyst	1	0	1	2
Aneurysmal bone cyst	2	0	0	2
Giant cell tumour	0	2	0	2
Ewings sarcoma	2	0	0	2
Osteosarcoma	4	0	1	5
Chondrosarcoma	0	0	1	1

Hemangioma	0	0	1	1
Ameloblastoma	0	0	1	1
Chondromyxoid fibroma	1	0	0	1
Osteoid osteoma	0	2	0	2
Multiple myeloma	0	0	1	1
Total	13	10	07	30

TABLE 2.

BONES INVOLVED		
Name of bone	Diagnosis	Percentage
Femur	09	30
Tibia	04	13
Radius	01	03
Ulna	01	03
Metacarpal	01	03
Metatarsal	0	-
Phalanges	03	10
Mandible	02	06
Skull	02	06
Vertebra	01	03
Clavicle	01	03
Multiple bones	05	16

TABLE 3.

Type of lesion	Zone of transition		Total
	Narrow	Wide	
Benign	21	0	21
Malignant	03	06	09
Total	24	06	30

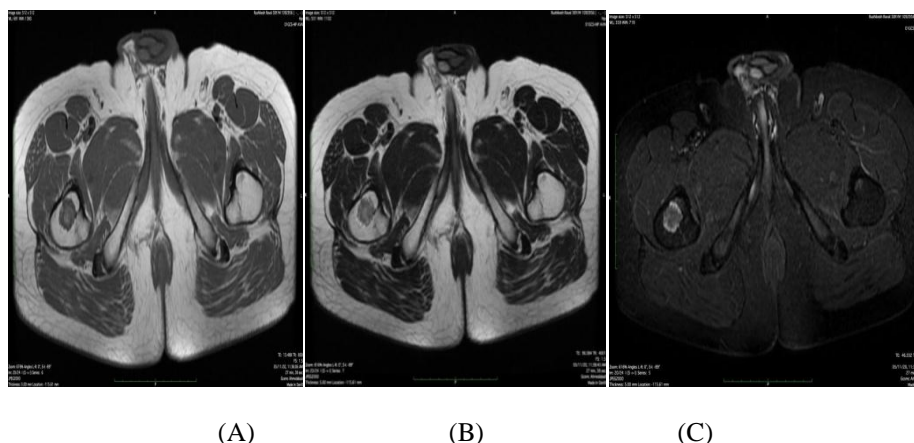
TABLE 4.

Type of lesion	Periosteal reaction		Total
	Present	Absent	
Benign	0	21	21
Malignant	07	02	09
Total	07	23	30

III. Discussion

**Cases -
CASE 1**

A 38 years old male patient presented with the complaint of chronic pain in right hip joint and was advised MRI. Fig 1.



Presence of well defined altered signal intensity lesion noted involving medullary cavity of proximal diaphysis of right femur, which appears hypointense on T1WI images Fig 1. (A) and hyperintense in T2WI and STIR images Fig 1. (B & C) respectively.
There is no e/o any endosteal scalloping noted.
There is no e/o underlying cortical breach or thinning is noted.

Radiological diagnosis is in favor of benign etiology – Enchondroma.

Enchondromas are one of the common benign tumor of bone and are characterized by formation of abundant mature hyaline cartilage. They are most commonly seen during second and third decade of life, and are most frequently found in the tubular bones of the hands and feet, but can arise in any bone (22).

Enchondromas are central, well-defined, expansile masses with or without endosteal scalloping, chondroid calcifications may be seen. MR imaging usually shows a lobulated T1 hypointense and T2 hyperintense lesion.

CASE 2

A 16 years old male patient presented with the complaint of swelling and pain in distal forearm, X-ray was s/o expansile lytic lesion involving distal radius, further MR evaluation was advised.

The name “aneurysmal bone cyst” is a misnomer. ABC are not true cysts, nor are they true aneurysms.

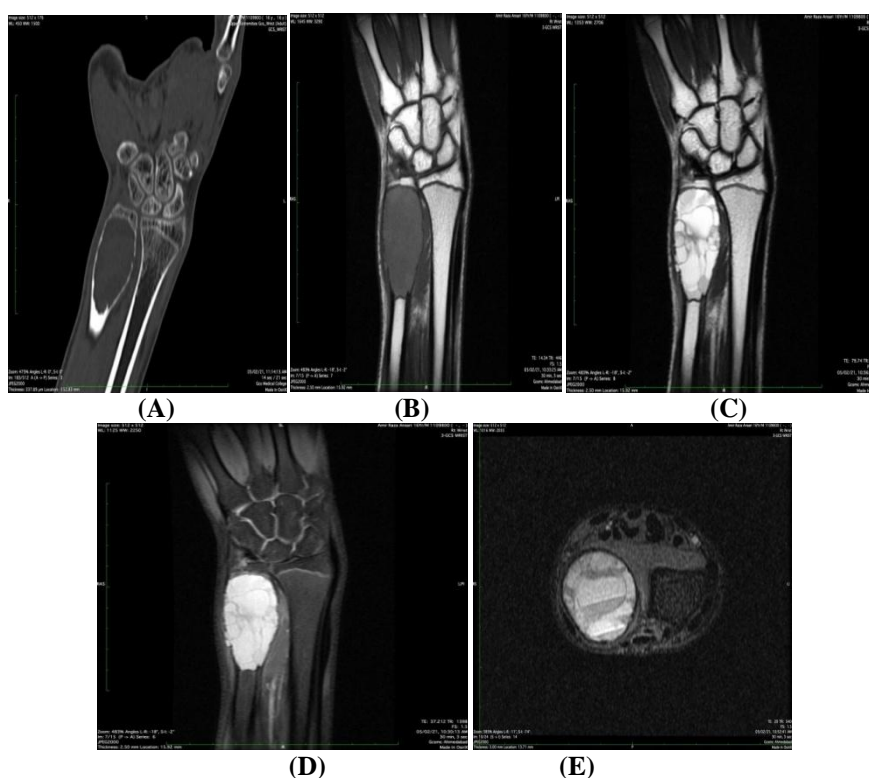
ABC consists of large vascular spaces, filled with blood and hemosiderin, and lined with giant cells.

Plain radiographs show a radiolucent, expansile mass without matrix production, but often with septations.

ABC are low signal on T1-weighted images and high signal on T2-weighted images with low signal fibrous tissue lining the spaces (16, 22).

Fluid Fluid level (FFL) were first described in ABC, and result from separation of blood and serum in the cavernous spaces.

Fig 2.



On CT there is presence of well defined, lobulated, expansile lytic lesion noted involving metaphysis of distal shaft of right ulna.(Fig 2. A)

It appears hyperintense on T2W and STIR images (Fig 2. C & D) and hypointense in T1W images (Fig 2. B).

The lesion does not cross the epiphyseal growth plate, epiphysis appears to be intact.

It shows multiple internal septations and internal fluid-fluid levels within (Fig 2. E).

The lesion shows narrow zone of transition with the adjacent normal bone.

No evidence of any soft tissue component or periosteal reaction is seen.

CASE 3.

A 40 years old male patient presented with the complaint of soft tissue mass and pain in proximal phalanx of middle finger of right hand , was diagnosed GCT on MRI and advised biopsy correlation.

Giant cell tumors of bone, also known as **osteoclastomas**, are common benign bone tumors.(16, 12).GCT are very rare in children.

There are four characteristic radiographic features when a giant cell tumor is located in a long bone :

- Occurs only with a closed growth plate
- Abuts articular surface
- Well-defined with non-sclerotic margin
- Eccentric : if large this may be difficult to assess

At MR imaging, GCT frequently demonstrates peripheral low signal on T1-weighted images and hyperintensity on T2-weighted images with few T2-hypointensity which may result from the tumor cellularity, or from recurrent hemorrhage within the lesion. It is a useful feature in characterizing this tumor.

The solid portions of GCT enhance diffusely after gadolinium administration, whereas cystic components demonstrate a delicate septal and peripheral enhancement pattern thus helping differentiate from aneurysmal bone cysts.

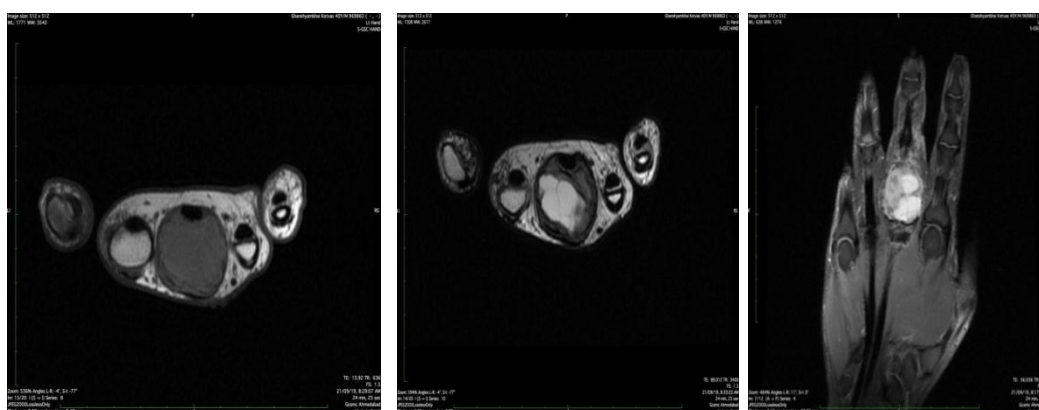


Fig 3. (A) (B) (C)

Well-defined expansile lobulated altered signal intensity lesion involving proximal phalanx of middle finger near metacarpophalangeal joint.

It appears hypointense on T1W images (Fig 3. A) and hyperintense on T2 W and PDFS images (Fig 3. C & D) and does not shows fat suppression on PDFS image.

The lesion causes thinning of adjacent cortex without cortical breach. The lesion shows narrow zone of transition.

The lesion is extending upto metacarpophalangeal joint without any intraarticular extension. Flexor tendon of middle finger is separately seen from lesion.

No extension of the into soft tissue, muscle noted.

CASE 4.

A 15 years old male patient presented with the complaint of soft tissue mass and local pain in forearm , was diagnosed ewings sarcoma on MRI.

Ewing sarcomas are the second most common malignant primary bone tumors of childhood after osteosarcoma, typically arising from the medullary cavity with the invasion of the Haversian system(19). As far as a location within long bones femur is the most common and the tumor is almost always metadiaphyseal or diaphyseal(16 , 17).

Common radiological findings include :- permeative lesion , lamellated periosteal reaction , sclerosis.They occasionally demonstrate other appearances, including Codman triangles, spiculated (sunburst) or thick periosteal reaction and even bone expansion or cystic components.

In addition to assessment of the primary tumor site, imaging should be performed to evaluate for metastatic disease, which most commonly occurs in the lungs, followed by bone and bone marrow.

One of the close differentials of ewings sarcoma is osteosarcoma , differentiating features are as described below :

- more often has amorphous calcified matrix
- classically perimetaphyseal, Ewing sarcoma also occurs in other locations
- more prevalent around the knee and in the proximal humerus, in other locations Ewing sarcoma is the more frequent of the two.

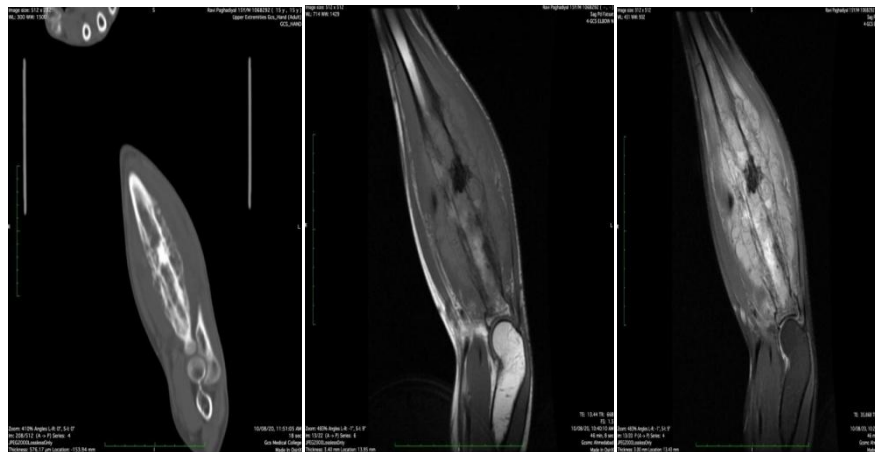
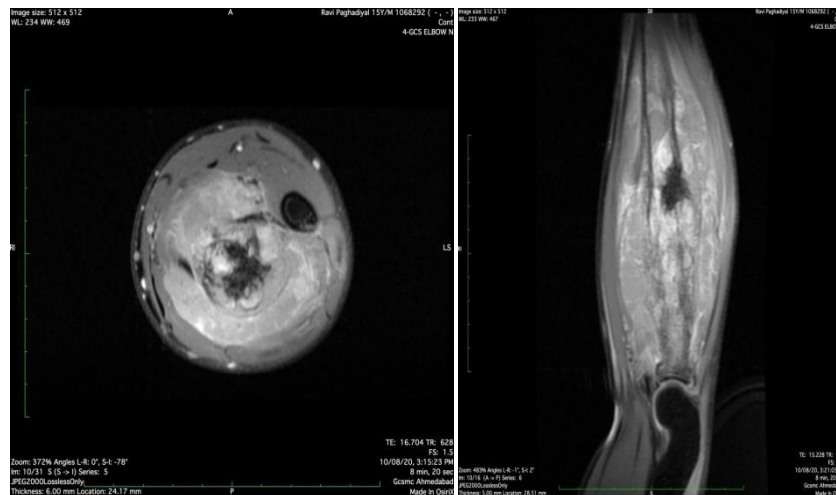


Fig 4. (A) (B) (C)



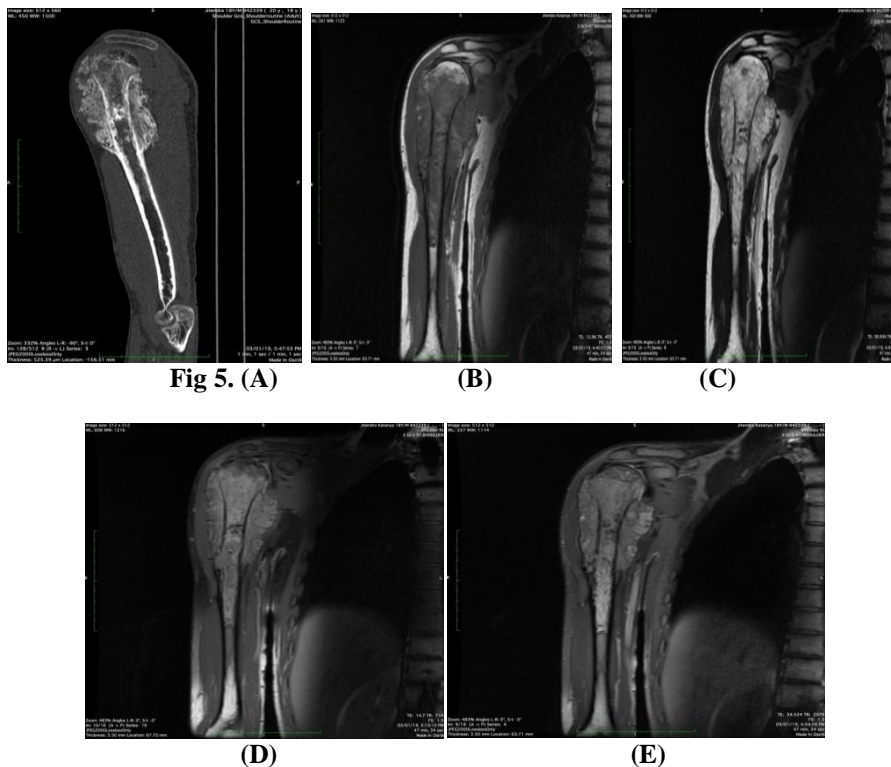
(D) (E)

MR imaging shows the mass to be heterogeneous and T1 isointense to mildly hypointense and T2 hyperintense; with a variable enhancement pattern.

CASE 5.

Osteosarcoms can be classified into primary and secondary forms, as well as histologic types, of which **conventional osteosarcoma** is the most common (3).

Primary osteosarcoma typically occurs in young patients (10-20 years) with 75% taking place before the age of 20 because the growth centers of the bone are more active during puberty/adolescence.



A 18 year old male patient presented with large mass involving right shoulder and upper arm with bone pain.

Presence of long segment permeative destructive bone lesion with poorly defined borders noted at proximal end of right humerus extending from anatomical neck of humerus and involving metaphysis and extending upto diaphysis of right humeral bone. Aggressive sun burst type of periosteal reaction noted.

Soft tissue component of the bone lesion noted surrounding the proximal end of the right humerus extends circumferentially into surrounding muscles. Tumour shows heterogeneous signal-area with wide zone of transition. Cortical breach noted at lateral aspect of upper 1/3rd of humerus. On post contrast study the lesion shows heterogenous enhancement. (Fig 5. E.)

Osteosarcomas are malignant bone-forming tumors. They are the second most common primary bone tumor after multiple myeloma.

Secondary osteosarcoma occurs in the elderly, usually secondary to malignant degeneration of Paget disease, extensive (7, 10, 20).

The tumor is characterized by production of bone. On plain radiographs, it may be a lytic, blastic, or mixed aggressive bony lesion, typically of large size, with indistinct margins, cortical destruction, aggressive periosteal reaction (Codman triangle or sunburst), and a soft tissue mass. Pathologic fracture is uncommon, except in the rare telangiectatic osteosarcoma.

Osteosarcoma is usually hypointense on T1-weighted images, and hyperintense on STIR imaging.

The neoplastic bone is dark on all imaging sequences.

The longitudinal extent of the soft tissue mass usually matches that of the intramedullary tumor.

Marrow and soft tissue edema, sometimes massive, may be seen.

General differentials include the following: metastatic lesion to bone, Ewing sarcoma, aneurysmal bone cyst.

Characterization of the lesion

The diagnosis of a bone tumor can frequently be suggested on the basis of age, location and classical radiographic findings.

Lytic bone lesions can only be detected on a standard radiogram when the tumor has caused 30–50% of trabecular bone destruction. Therefore, MRI may be useful in any case of neoplastic infiltration without bony destruction

Although MRI may have a limited additional role in the characterization of bone tumors, contrast resolution can be manipulated by varying the signal parameters. Therefore, a wide variety of images can be obtained, and allow characterization of some tissue components based on their signal characteristics. The careful use and interpretation of these studies can lead to a reasonable differential diagnosis prior to biopsy (6).

Signal intensity of the lesion

Analysis of the SI of a lesion allows to recognize specific tissue components.

High SI on T1w images that persists on fat suppressed sequences, indicates the presence of meta-hemoglobin and can be found in telangiectatic OS, aneurysmal bone cyst (ABC), giant cell tumor (GCT), fibrous dysplasia or rarely, in chondroblastoma or osteoblastoma.

Similarly, the presence of fat tissue in a bone lesion (e.g., intraosseous lipoma, periosteal and parosteal lipoma, and hemangioma) displays high SI on T1w images, which will be suppressed on fat saturation sequences.

Low SI on T2w sequences can be caused by hemosiderin deposition, fibrous tissue, calcification or mineralized osteoid matrix. It may be encountered in GCT, fibrous dysplasia, parosteal or osteoblastic OS and cartilaginous tumors.

In these lesions the SI depends on the ratio between cellularity and collagenous matrix.

Unfortunately, most skeletal tumors demonstrate nonspecific SI behavior on MRI; heterogeneous SI with significant overlap on T1w and T2w sequences is frequently encountered in both benign and malignant lesions (3,22,23)

Margins & morphology of the lesion

Cortical penetration, periosteal reaction and soft tissue involvement are signs of biologically aggressive lesions and are usually encountered in malignant tumors.

Identification of fluid-fluid levels in cystic cavities within a well-defined lesion is a characteristic of ABC, although it can also be found in GCT, fibrous dysplasia, plasmacytoma, telangiectatic OS, chondroblastoma and some bone metastases.

Benign and low-grade cartilaginous tumors are characterized by their lobulated morphology representing cartilage nodules separated by septa.

The presence of an associated soft tissue component is one of the most important imaging malignancy predictors in bone tumours(6). It can point to a malignant degeneration of enchondroma, osteochondroma, previous irradiated areas and Paget's disease. This is usually a prominent feature in Ewing's sarcoma and osteosarcoma.

Evaluation of bone marrow edema

MRI is the best technique in depicting bone marrow edema (5) which can be associated with both benign and malignant lesions. Extensive bone marrow edema related to small-sized lesions is often predictive of benign tumors and is typically associated with osteoid osteoma, osteoblastoma, chondroblastoma, Langerhan's cell histiocytosis and less

frequently with ABC or GCT. (12)

Conversely, minimal BME surrounding a large lesion is more likely to be associated with malignant lesions and is often found in Ewing's sarcoma, chondrosarcoma, Osteosarcoma and in bone metastases. (22)

Dynamic contrast-enhanced study

The dynamic contrast-enhanced (DCE) study can give additional diagnostic information.

Some lesions exhibit specific enhancement patterns useful for their characterization. The marked enhancement of the nidus in the arterial phase makes the diagnosis of osteoid osteoma very specific even when it is located in atypical sites. (11, 23)

An early enhancement and rapid washout, has been proved to characterize GCT.(12)

A DCE study can help to distinguish benign from malignant cartilaginous tumors. Benign chondromas do not enhance or enhance slowly, while chondrosarcomas display early enhancement.

IV. Conclusion

MRI is a unique imaging technique that allows direct visualization of bone marrow with high spatial resolution and is considered the best tool for local staging of bone tumors. Owing to its high natural contrast resolution, it can depict specific tissue components useful for tumor characterization

To summarize, MRI has high specificity when a bone lesion presents with particular features, specific morphology or a well-defined enhancement pattern.

A good knowledge of the characteristic MRI features of benign and malignant osseous conditions and their role in staging, therapeutic planning and follow-up in the setting of malignancy is essential for optimal patient care.

References

- [1]. Miller TT: Bone tumors and tumor-like conditions: analysis with conventional radiography. *Radiology* 246(3), 662-674 (2008).
- [2]. Baur-Melnyk A, Buhmann S, Becker C *et al.*: Whole-body MRI versus whole-body MDCT for staging of multiple myeloma. *AJR Am. J Roentgenol.* 190, 1097–1104 (2008).
- [3]. Saifuddin A: The accuracy of imaging in the local staging of appendicular osteosarcoma. *Skeletal Radiol.* 31, 19201 (2002).
- [4]. Bäuerle T, Hillengass J, Fechtner K *et al.*: Multiple myeloma and monoclonal gammopathy of undetermined significance: importance of whole body versus spinal MR imaging. *Radiology* 252, 477–485 (2009).
- [5]. James SLJ, Panicek DM, Davies AM: Bone marrow oedema associated with benign and malignant bone tumors. *Eur. J. Radiol.* 67, 11–21 (2008).
- [6]. Ehara S: MR imaging in staging bone tumors. *Cancer Imaging* 6, 158–162 (2006).
- [7]. Alyas F, James SL, Davies AM, Saifuddin A: The role of MR imaging in the diagnostic characterization of appendicular bone tumors and tumor-like conditions. *Eur. Radiol.* 17, 2675–2686 (2007).
- [8]. Gelderblom H, Hogendoorn PC, Dijkstra SD *et al.*: The clinical approach towards chondrosarcoma. *Oncologist* 13(3), 320–329 (2008)
- [9]. Littrell LA, Wenger DE CT, and MR imaging features of dedifferentiated chondrosarcomas: a retrospective review of 174 *de novo* cases. *Radiographics* 24, 1397–1409 (2004).
- [10]. Bertoni F, Bacchini P, Staals EL, Davidovitz P: Dedifferentiated parosteal osteosarcoma: the experience of the Rizzoli Institute. *Azura M, Vanel D, Alberghini M, Picci P, Staals E, Mercuri M: Parosteal osteosarcoma dedifferentiating into telangiectatic osteosarcoma: importance of lytic changes and fluid cavities at imaging. Skeletal Radiol.* 38(7), 685–690 (2009).
- [11]. Zampa V, Bargellini I, Ortori S, Faggioni L, Cioni R, Bartolozzi C: Osteoid osteoma in atypical locations: the added value of dynamic gadolinium-enhanced MR imaging. *Eur. J. Radiol.* 71(3), 527–535 (2009).
- [12]. Libicher M, Bernd L, Schenk JP, Mädler U, Grenacher L, Kauffmann GW: Characteristic perfusion pattern of osseous giant cell tumor in dynamic contrast-enhanced MRI. *Radiologie* 41(7), 577–582 (2001).
- [13]. Geirnaerd MJ, Hogendoorn PC, Bloem JL, Taminiau AH, van der Woude HJ: Cartilaginous tumors: fast contrast-enhanced MR imaging. *Radiology* 214(2), 539–546 (2000).
- [14]. Lavini C, Pikaart BP, de Longe MC, Schaap GR, Maas M: Region of interest and pixel-by-pixel analysis of dynamic contrast enhanced magnetic resonance imaging parameters and time–intensity curve shapes: a comparison in chondroid tumors. *Magn. Reson. Imaging* 27, 62–
- [16]. Wang CK, Li CW, Hsieh TJ, Chien SH, Liu GC, Tsai KB: Characterization of bone and soft-tissue tumors with *in vivo* spectroscopy: initial results. *Radiology* 232, 599–605 (2004). future science group H MR
- [17]. Lewis VO: What’s new in musculoskeletal oncology. *J. Bone Joint Surg. Am.* 91, 1546–1556 (2009).
- [18]. McCarville MB: New frontiers in pediatric oncologic imaging. *Cancer Imaging* 8, 87–92 (2008).
- [19]. Ueda T, Naka N, Araki N *et al.*: Validation of radiographic response evaluation criteria of preoperative chemotherapy for bone and soft tissue sarcomas: Japanese Orthopaedic Association Committee on Musculoskeletal Tumors Cooperative Study. *J. Orthop. Sci.* 13, 304–312 (2008).
- [20]. Dyke JP, Panicek DM, Meyers PA *et al.*: Osteogenic and Ewing sarcoma: estimation of necrotic fraction with dynamic contrast-enhanced MR imaging. *Radiology* 228, 271–278 (2003).
- [21]. Reddick WE, Wang S, Xiong X *et al.*: Dynamic magnetic resonance imaging of regional contrast access as an additional prognostic factor in pediatric osteosarcoma. *Cancer* 91(12), 2230–2237 (2001).
- [22]. American College of Radiology (2013) ACR Appropriateness Criteria. Primary Bone Tumors. American College of Radiology. Available via <http://www.acr.org/~media/ACR/Documents/AppCriteria/Diagnostic/PrimaryBoneTumors.pdf>. Accessed 9 Apr 2014
- [23]. Davies AM, Sundaram M, James SLJ (2009) *Imaging of Bone Tumors and Tumor-Like Lesions* Springer, Berlin Heidelberg 23. MRI of bone tumors: advances in diagnosis and treatment assessment.

Dr. Asutosh Dave, et. al. “Role of MRI in Evaluation of Bone Tumour and Tumour Like Lesions” *IOSR Journal of Dental and Medical Sciences (IOSR-JDMS)*, 20(10), 2021, pp. 01-11.