

An Unusual Presentation of Scrub Typhus: Acute Mastoiditis

Sandipa Roy Chowdhury¹, Prisha Nankana², Medo M. Kuotsu³, Deepak Dhakal⁴, Japheth Thono⁵, Sarath Chandran K R⁶, Lalrinchhani⁷

^{1,2,3,4,5,6,7}PGTs Department of Medicine, Regional Institute of Medical Sciences, Imphal, Manipur, India

Abstract: Scrub typhus, a zoonosis caused by bacterium *Orientia tsutsugamushi*. Commonly manifest as acute febrile illness, however atypical presentation with resultant delay in diagnosis and treatment may occur. Multi-organ failure with high mortality in such cases is major concern while dealing with this common disease. Here we are reporting an interesting case of scrub typhus presenting as acute mastoiditis.

Keywords: Scrub typhus, acute mastoiditis, zoonosis, eschar, *Orientia tsutsugamushi*.

Date of Submission: 27-12-2020

Date of Acceptance: 08-01-2021

I. Introduction:

Scrub typhus, a zoonosis caused by bacterium *Orientia tsutsugamushi*. Organism is acquired through bites of trombiculid mites.^[1,2] Commonly manifest as acute febrile illness with favorable outcomes, indeed manifestations are variable with multi-organ system involvement and high mortality. Scrub typhus is endemic most of the north-east states of India where atypical presentation are not unusual. Here we describe scrub typhus presenting as acute mastoiditis which very rare with handful of cases reported in literature.

II. Case Report:

Forty five years old female from agriculture background presented to outpatient department (OPD) of our institute with symptoms of high grade fever associated with chills and rigors of one week duration. She also noticed swelling along with dark scab on left side of her neck which was followed by symptoms of bilateral earache for last 5 days. On examination she was febrile with pulse rate of 112 per minute and blood pressure of 110/76 millimeter of mercury (mmHg). Single 2 x 3 centimeters (cm), tender, firm, mobile, level two left cervical lymph node along with eschar of size 2 x 1 cm at left supraclavicular were evident.(Image:1) On ear examination bilateral mastoid tenderness was present. Rest of physical and systemic examinations was unremarkable. Patient admitted in general ward for further evaluation. On laboratory evaluation mild anemia and transaminitis along with Scrub typhus IgM antibody (by ELISA method) were present, rest of laboratory findings were normal. (Table:1) In view of her ear symptoms patient further evaluated with X ray mastoid area and high resolution computed tomography (HRCT) scan of temporal bone which showed opacity and fluid in bilateral mastoid air cells well suggestive of acute mastoiditis.(Image:2) In view of findings of characteristic eschar, positive scrub typhus antibody and high rate of occurrence of scrub typhus in our area patient started on oral doxycycline 100 mg twice daily. Patient showed dramatic response to treatment within two days of initiation of therapy and became afebrile with disappearance of ear symptoms. Patient discharged after seven days of hospital stay with advice of completion of 14 days of doxycycline treatment. Patient was symptomatic till three months of follow-up visits.

III. Discussion:

Scrub typhus also known as tsutsugamushi disease is an acute febrile illness caused by *Orientia tsutsugamushi* which is derived from combination of two Japanese word tsutsuga means “dangerous” and means mushi “bug”.^[1,2] “Tsutsugamushi triangle” which extend from Japan, Taiwan, China, South Korea, Nepal, Northern Pakistan, Papua New Guinea, and the Australian states of Queensland and Northern New South Wales are endemic regions of scrub typhus.^[3] In India cases of scrub typhus commonly reported from states of North-East region, Haryana, Jammu, and Kashmir, Himachal Pradesh, Uttaranchal, West Bengal, Maharashtra, Kerala and Tamilnadu.^[4] Incidence of disease is high during wet seasons in months of June to November. Causative organism is an obligate intracellular Gram negative bacterium. Organism gains entry into human body through bites of trombiculid mites (chiggers). Incubation period ranges from 6-20 days. Underlying pathogenic process is invasion of vascular endothelial cells resulting in disseminated vasculitic and perivascular inflammatory infiltrate with consequent vascular leakage. Pathogenic process may involve multiple organ systems with multi-organ failure and rapid downhill clinical course which is associated with high fatality if diagnosis and treatment delayed.^[5] Clinical diagnosis can be mad in presence of compatible presentation of acute febrile illness and

characteristic eschar. Typical skin lesion begins as primary papule, where chigger has fed, later on enlarges in size and undergoes central necrosis and crusting to form characteristic flat black eschar. (Image: 1) Regional lymph nodes are often enlarged and tender, generalized lymphadenopathy may occur. However frequency of eschar in scrub typhus ranges from 11-44% and not universal finding always. Diagnosis may get delayed when presentation is atypical and characteristic eschar is present.

Scrub typhus is presenting as acute mastoiditis is very unusual with only few cases reported in literature. Lal et reported case of acute mastoiditis treated with empirical amoxicillin-clavulanic acid and metronidazole without much clinical improvement but later on tested positive for scrub typhus with dramatic response to doxycycline underscoring the importance of early diagnosis and prompt institution of treatment with effective antibiotic against causative organism.^[6] Similarly Mahajan et al reported two cases of acute reversible hearing loss caused by scrub typhus diagnosis which were confirmed by nested PCR.^[7] Our case presented primarily with acute febrile illness and cervical lymphadenopathy, later on involving mastoid air cells manifested clinically and radiologically as acute mastoiditis. Diagnosis was further supported by presence of characteristic eschar, positive scrub typhus antibody and rapid improvement with doxycycline antibiotic in our case. Usually Response to doxycycline antibiotic is prompt and complete with rapid improvement in clinical status. The underlying mechanism is assumed to be vasculitic damage by *Orientia tsutsugamushi*.^[8]

IV. Conclusion:

Unusual presentation of scrub typhus do encountered in clinical practice underscoring the requirement of high index of suspicion for early diagnosis and treatment for better outcome.

References:

- [1]. Walker DH, Dumler JS, Marrie T. Rickettsial Diseases. (Part 8,Section 10, Chapter 174) In: Longo DL, Fauci AS Kasper DL,Hauser SL, Jameson JL, Loscalzo J, editors. Harrison’s Principle of Internal Medicine. 18th ed. USA: The McGraw- Hill Companies; 2012. p.1064- 5.
- [2]. Rapsang AG, Bhattacharyya P. Scrub typhus. Indian J Anaesth 2013;57:127-34.
- [3]. Chang WH. Current status of tsutsugamushi disease in Korea. J Korean Med Sci 1995;10:227- 38.
- [4]. Mahajan SK, Kashyap R, Kanga A, Sharma V, Prasher BS, Pal LS. Relevance of Weil- Felix test in diagnosis of scrub typhus in India. J Assoc Physicians India 2006;54:619- 21.
- [5]. Devine J. A review of scrub typhus management in 2000-2001 and implications for soldiers. Journal of Rural and Remote Environmental Health. 2003;2(1):14- 20.
- [6]. Lal B, Minhas RS, Sharma DR, Kumar S. Scrub Typhus Presenting as Acute Mastoiditis. Online J Health Allied Scs. 2013;12(4):14.
- [7]. Mahajan SK, Bakshi D. Acute reversible hearing loss in scrub typhus. J Assoc Physic. India. 2007;55:512- 513.
- [8]. Sexton DJ. Acute hearing loss in rickettsial diseases. Clin Infect Dis. 2006;42:1506

Table 1: Laboratory testing results of presenting case

Investigations	Date:12.12.2019
Hemoglobin	11
Total Leucocytes Count	8000
Platelet Counts	200000
SGOT	60
SGPT	65
BUN	15
Creatinine	1.1
Scrub Typhus anti-Ig M	Positive

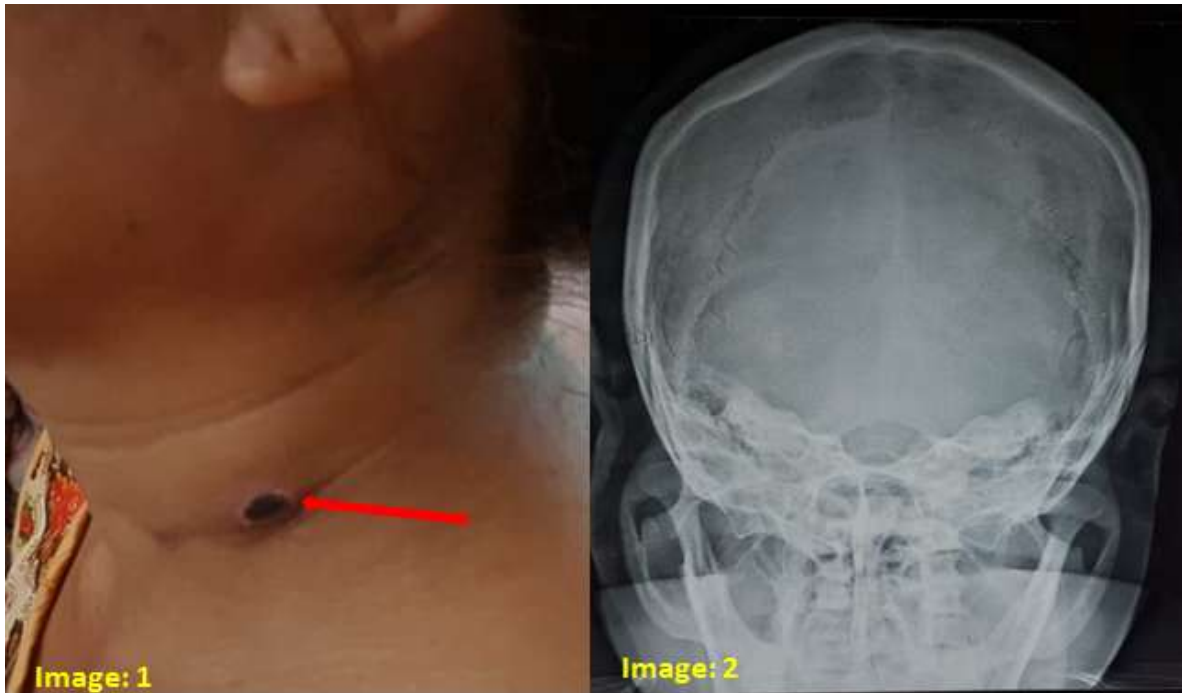


Image 1: characteristic flat black eschar in nape of the neck. **Image 2:** HRCT scan of the temporal bone showing opacity and fluid in bilateral mastoid air cells.

Sandipa Roy chowdhury, et. al. "An Unusual Presentation of Scrub Typhus: Acute Mastoiditis." *IOSR Journal of Dental and Medical Sciences (IOSR-JDMS)*, 20(01), 2021, pp. 23-25.