

## **Bipolar hip prosthesis with modular revision rod on loss of proximal substance of the femur (about a case)**

Lahsika Mohammed<sup>1</sup>; Benchekroun Seddik<sup>1</sup>; Mnina Ayoub<sup>1</sup>; El Idrissi Mohammed<sup>1</sup>; El Ibrahimi Abdelhalim<sup>1</sup>; El Mrini Abdelmajid<sup>1</sup>

<sup>1</sup> Department of Traumatology and Orthopedics Hassan II UHC, Fez, Morocco

Main Author: Dr. Lahsika Mohammed

Resident, Department of Traumatology Orthopedic B4,  
University Hospital Hassan II Fez, Morocco

---

### **Abstract:**

Cervical screw scanning is a complication that concerns all means of osteosynthesis of the upper end of the femur, it is generally linked to several factors: poor bone quality, insufficient reduction or bad position of the cervical screw.

We report a case of an intermediate hip replacement prosthesis. It is a case of myeloma of the upper extremity of the femur, the treatment of which was palliative and consisted of an excision with stabilization by a cervico-medullary nailing system. The development was marked by the occurrence of a scan of the cervical screw, hence the decision to undergo surgical revision with removal of the nail and prosthetic replacement with an intermediate hip prosthesis with a REVITAN® modular revision rod (Zimmer Biomet®).

Major losses of bone substance from the proximal end of the femur represent difficult situations without an ideal therapeutic solution. One of the lifesaving solutions is femoral revision prostheses.

The REVITAN® revision system therefore remains an answer that is always suitable for the treatment of bone loss from the proximal end of the femur. The publication of other series will be necessary in order to develop a valid therapeutic protocol for this type of surgery.

**Keywords:** cut-out, bipolar hip prosthesis, Revision stem.

---

Date of Submission: 04-01-2021

Date of Acceptance: 17-01-2021

---

### **I. Introduction:**

Cervical screw cut-out is a complication that concerns all means of osteosynthesis of the proximal femur, it is generally linked to several factors: poor bone quality, insufficient reduction or bad position of the cervical screw.

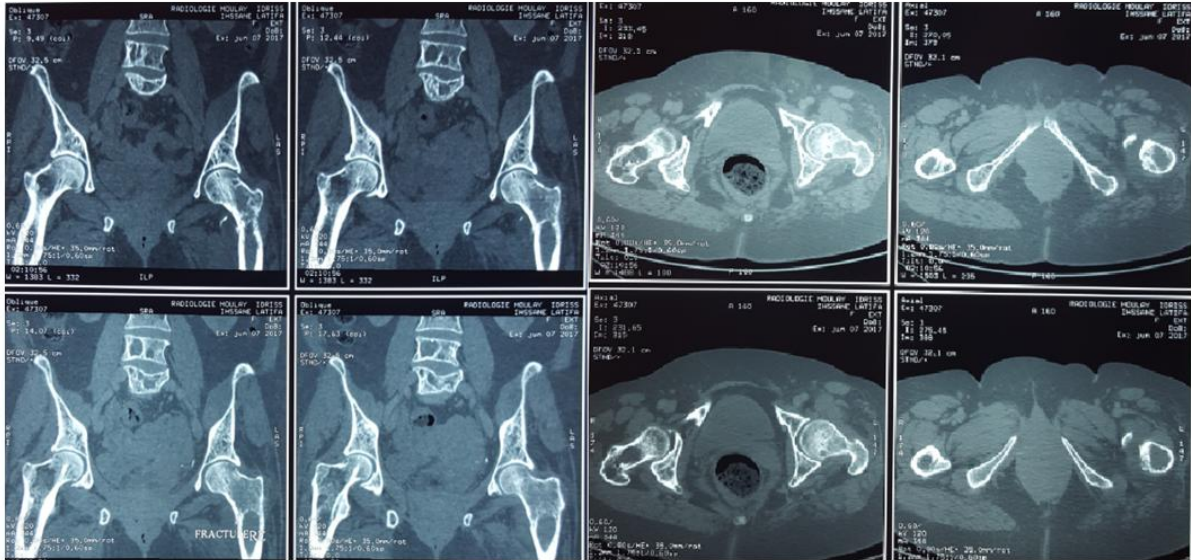
The first reconstructions used massive allografts. Their failure rate was high because these reconstructions were subject to complications from allografts, that is to say infections, bone resorptions, fractures, and non-union between the host and the graft [1,2], another therapeutic alternative is arthroplasty which can either be cuffed in an allograft (called composite reconstruction), or massive like our case [3]. Resistance mechanical implant is superior to composite systems, but this method presents a risk of loosening [4].

The purpose of this work and to report our experience in the case of an intermediate hip prosthesis with revision rod on a scan of the cervical screw on poor quality bone.

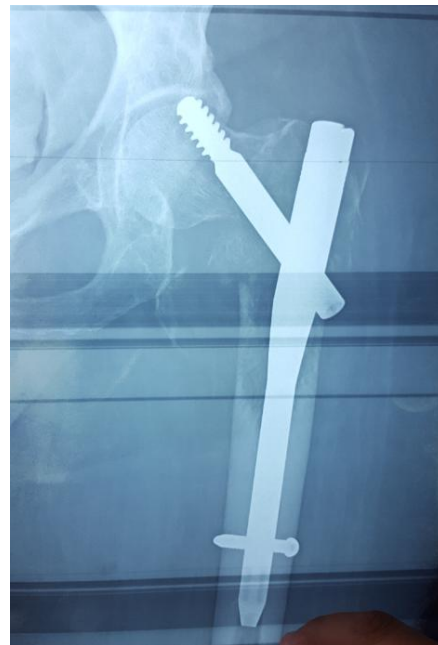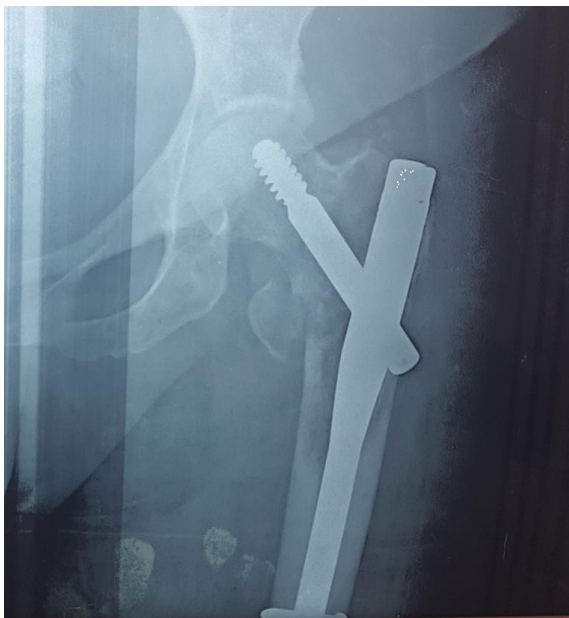### **II. Patient and observation:**

A 54-year-old housewife patient followed for multiple myeloma and undergoing chemotherapy. Following a fall in height, the patient was admitted to the emergency room for pain with total functional impotence of the left lower limb.

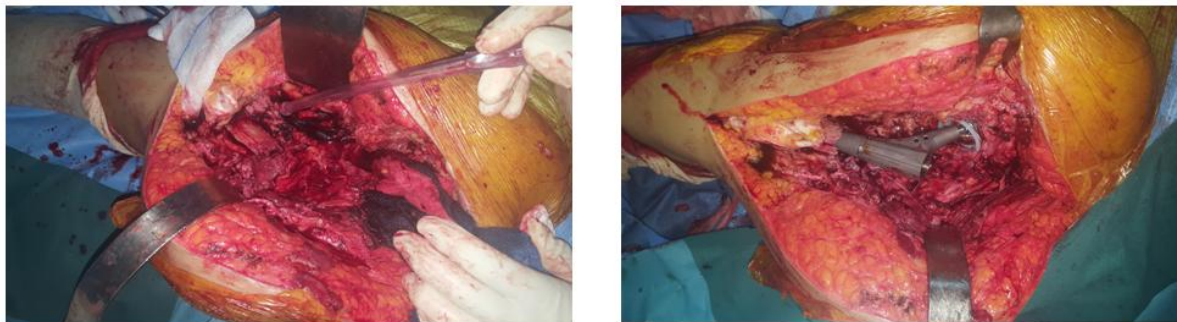
Standard radiograph of the left hip showed a petrochanteric fracture on pathological bone. CT scan objectifying the same observation and multiple bony gaps in the two iliac wings and the sacrum. (Figure 1).



The patient was admitted to the block, under general anesthesia, she underwent a biopsy with osteosynthesis by a standard cervico-medullary nail (Figure 2). The anatomico-pathological result was in favor of large foci of hemorrhagic suffusions with the presence of plasma cells but the radiological follow-up at 4 months objectified a cut-out of the cervical screw in supero-external from where the indication of a resumption surgical (Figure 3).



The patient underwent removal of the gamma nail, broad excision of the tumor and placement of an intermediate hip prosthesis with a REVITAN® type modular revision rod (Zimmer Biomet®) (Figure 4,5).



The patient was assessed clinically (satisfaction, Postel and Merle d'Aubigné functional score [PMA] and radiologically (bone – prosthesis interface, pedestal and heterotopic calcifications). Bone reconstruction was assessed using Hoffman's cortical index (IC).

The postoperative protocol includes a prolonged crutch, of which the patient must be informed before the intervention. The patient followed an early rehabilitation protocol with immediate post-operative controls and at each follow-up appointment (at 2 weeks, 6 weeks, 3 months, 6 months and 1 year).

### **III. Results And Discussion:**

The patient presented with a hemorrhagic shock state for which she spent two days in the intensive care unit and then was referred to the trauma-orthopedic service after stabilization of the hemodynamic state.

The post-operative radiological control showed an implant-bone contact surface greater than 3 cm and an IC which found a significant absolute gain of 33% at 8 cm from the prosthetic neck (Figure 6).

The functional result at 6 months post-operative was satisfactory with a PMA score which went from 7 preoperatively to 12 postoperatively. For the literature, Bertani and al. Reported a satisfactory result in his series but the results were nevertheless lower than those of Menedez and al. [5]but both were rated according to the MSTs score of Enneking et al.[6].

Major losses of bone substance from the proximal end of the femur represent difficult situations with several therapeutic solutions on the menu [2,3,7]. Femoral revision prostheses represent a choice among the rescue solutions[8].

The results of the literature at the average follow-up of 5.4 years are encouraging and seem comparable to the therapeutic alternative represented by the composite prosthesis [7].

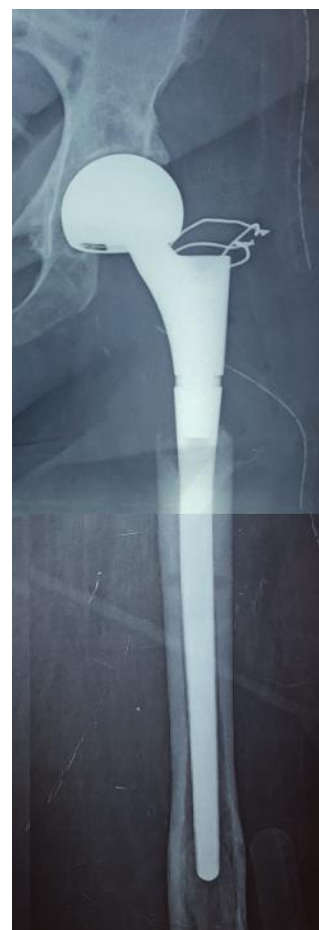There was no post-operative infection such as dislocation or early infection. Results from the literature concerning total hip replacement were different [9,10]and found rates of deep infection varying from 3% to 13%, concerning dislocation the rate in the literature was varying from 16 % to 22% depending on the series [11,12].

For the study of the longevity of the prosthesis, we requires a more distant recoil with a wider recruitment of cases.

### **IV. Conclusion:**

Loss of substance from the proximal femur either due to a tumor, traumatic or iatrogenic cause is a usual situation in orthopedics.

The REVITAN® modular revision system therefore remains a solution that is always suitable for the treatment of bone loss from the proximal end of the femur and a combination with other methods such as allograft seems reasonable but remains to be proven by larger studies.



### **References:**

- [1]. Mankin HJ, Gebhardt MC, Jennings LC, Springfield DS, Tomford WW. Long-Term Results of Allograft Replacement in the Management of Bone Tumors. *Publ Assoc Bone Jt Surg CORR®*. mars 1996;324:86–97.
- [2]. Fox EJ, Hau MA, Gebhardt MC, Hornicek FJ, Tomford WW, Mankin HJ. Long-Term Followup of Proximal Femoral Allografts. *Publ Assoc Bone Jt Surg CORR®*. avr 2002;397:106–113.

- [3]. Ahlmann ER, Menendez LR, Kermani C, Gotha H. Survivorship and clinical outcome of modular endoprosthetic reconstruction for neoplastic disease of the lower limb. *J Bone Joint Surg Br.* 1 juin 2006;88-B(6):790- 5.
- [4]. Farid Y, Lin PP, Lewis VO, Yasko AW. Endoprosthetic and Allograft-prosthetic Composite Reconstruction of the Proximal Femur for Bone Neoplasms: *Clin Orthop.* janv 2006;442(NA):223- 9.
- [5]. Menendez LR, Ahlmann ER, Kermani C, Gotha H. Endoprosthetic reconstruction for neoplasms of the proximal femur. *Clin Orthop.* sept 2006;450:46- 51.
- [6]. Enneking WF, Dunham W, Gebhardt MC, Malawar M, Pritchard DJ. A system for the functional evaluation of reconstructive procedures after surgical treatment of tumors of the musculoskeletal system. *Clin Orthop.* janv 1993;(286):241- 6.
- [7]. Farid Y, Lin PP, Lewis VO, Yasko AW. Endoprosthetic and Allograft-prosthetic Composite Reconstruction of the Proximal Femur for Bone Neoplasms: *Clin Orthop.* janv 2006;442(NA):223- 9.
- [8]. P A, J C, L V, C J, E M, B T. [Proximal femoral reconstruction with megaprosthesis versus allograft prosthesis composite. A comparative study of functional results, complications and longevity in 41 cases]. *Rev Chir Orthop Reparatrice Appar Mot.* 1 mai 2000;86(3):278- 88.
- [9]. Mittermayer F, Krepler P, Dominkus M, Schwameis E, Sluga M, Heinzl H, et al. Long-term followup of uncemented tumor endoprostheses for the lower extremity. *Clin Orthop.* juill 2001;(388):167- 77.
- [10]. Endoprosthetic Reconstruction for Neoplasms of the Proximal... : A Publication of The Association of Bone and Joint Surgeons® | CORR® [Internet]. [cité 24 avr 2020]. Disponible sur: [https://journals.lww.com/clinorthop/Fulltext/2006/09000/Endoprosthetic\\_Reconstruction\\_for\\_Neoplasms\\_of\\_the.10.aspx](https://journals.lww.com/clinorthop/Fulltext/2006/09000/Endoprosthetic_Reconstruction_for_Neoplasms_of_the.10.aspx)
- [11]. Malkani A, Settecerri J, Sim F, Chao E, Wallrichs S. Long-term results of proximal femoral replacement for non-neoplastic disorders. *J Bone Joint Surg Br.* 1 mai 1995;77-B(3):351- 6.
- [12]. Haentjens P, De Boeck H, Opdecam P. Proximal femoral replacement prosthesis for salvage of failed hip arthroplasty: complications in a 2-11 year follow-up study in 19 elderly patients. *Acta Orthop Scand.* févr 1996;67(1):37- 42.

**Origin of aid:** this work is the fruit of my own work without external aid in the form of subsidy, material, medicine or other support.

**Declaration of no conflict of interest:** I declare on my honor, and all participants in this study, that we have no affiliation (financial or otherwise) to disclose, with a for-profit or non-profit organization which can influence the results and analysis of this study.

**Contribution of the authors:**

- Mohammed Lahsika (Principal author): planning the study, exploitation of the archives, analysis of the results and writing of the manuscript
- Benchekroun Seddik and Mnina Ayoub: Exploitation of the archives, analysis of the results.
- Mohammed El Idrissi, Abdelhalim El Ibrahimy and Abdelmajid El Mrini: Critical review and final approval

**Number of figures:** 6 figures

**Figure 1:** CT of the pelvis

Bone gaps in the two iliac wings and the sacrum, osteolytic lesion of the upper extremity of the left femur with petrochanteric fracture and detachment of the lesser trochanter.

**Figure 2:** Standard radiograph of the pelvis facing

Standard gamma nail well anchored with a cervical screw at the junction of the upper third middle third of the femoral neck and an apex point distance (TAD) of 20mm on the front view.

**Figure 3:** Standard radiograph of the left hip face

Scanning of the cervical screw with breach of the femoral head in superoexternal.

**Figure 4:** Intraoperative image

Removal of the gamma nail and excision of the reworked bone tissue.

**Figure 5:** Intraoperative image

Prosthetic replacement with an intermediate hip prosthesis with revision rod.

**Figure 6:** X-ray of the left hip face

Intermediate prosthesis of the left hip with Revitan® modular revision rod.

Lahsika Mohammed, et. al. "Bipolar hip prosthesis with modular revision rod on loss of proximal substance of the femur (about a case)." *IOSR Journal of Dental and Medical Sciences (IOSR-JDMS)*, 20(01), 2021, pp. 29-32.