

Pearls, Pitfalls & Mimicks In The “Ultrasound Diagnosis” Of Ovarian Torsion

Dr Gauraw Kumar Srivastava

Senior Consultant

Department of Radiology & Imaging

Medanta, The Medicity

Gurgaon

Dr Sanjay Saran Baijal

Chairman

Deptt of Radiology & Imaging

Medanta, The Medicity

Gurgaon

Date of Submission: 25-08-2020

Date of Acceptance: 09-09-2020

List of Contents

1. Definition (of ovarian torsion).
2. Clinical features of ovarian torsion.
3. Epidemiological features.
4. Pathophysiological features.
5. Predisposition conditions (for causing Torsion).
6. Predisposition conditions (for NOT causing Torsion).
7. Diagnosis of Ovarian Torsion.
8. Mimics (and Ultrasonological Pitfalls) of Ovarian Torsion.
9. Some other conditions that can mimic torsion.
10. Normal Sonological anatomy of the Ovary.
11. Arterial supply to the Ovary.
12. Doppler imaging of the Ovarian Artery.
13. The Venous and Lymphatic drainage of the ovaries.
14. Grey Scale Ultrasound findings of Ovarian Torsion.
15. Colour Doppler Findings in Ovarian Torsion.
16. The “Whirlpool” Sign.
17. Appearance of the “Whirlpool” sign on Ultrasound.
18. Some Illustrations of cases of Ovarian Torsion & the Sonological Findings in them.
19. Some Other conditions that may mimic Ovarian Torsion.
20. The Golden Question.
21. Conclusion.

(1) Definition :-

- Ovarian torsion is the twisting of an ovary on its ligamentous supports and can result in a compromised blood supply.
- Adnexal torsion is a term that is inclusive of either the ovary, fallopian tube, or both. Concomitant ovarian and tubal torsion has been shown to occur in up to 67% of cases.

(2) Clinical Features of Ovarian Torsion:-

- Sharp abdominal pain. However, the symptoms of ovarian torsion are often nonspecific, making it difficult to differentiate from other causes of acute abdominal pain.
- The classic presentation includes sharp, localized (right or left) lower abdominal pain, tenderness with a palpable abdominal mass and peritoneal signs. Waves of nausea and vomiting as well as pyrexia have been observed. In some cases, patients experience ‘intermittent’ pain, making the diagnosis even more challenging.

(3) Epidemiological feature:-

- Ovarian torsion can occur in females of all ages; however, women in their reproductive years have the highest prevalence.

This is probably due to (1) the increased occurrence of physiologic and pathologic ovarian masses (2) therapy for infertility and (3) pregnancy itself.

(4) Pathophysiological Features:-

- Initially, the twisted vascular pedicle in the suspensory ligament of the affected ovary compromises venous and lymphatic outflow. This results in diffuse ovarian edema and enlargement, which over time cause the capsule to stretch and increase pressure on the ovary. Later, the arterial compromise, arterial thrombosis and ultimately ischemia & infarction ensue.
- With incomplete torsion, capillary hydrostatic pressure remains increased and obstructs lymphatic drainage, causing massive ovarian edema.

(5) Predisposition conditions (for causing Torsion)

- Large or heavy cysts, Cystic neoplasms (such as benign mature cystic teratomas), Hemorrhagic cysts, and Cystadenomas commonly predispose the ovary to swing on its vascular pedicle. The large cystic ovaries seen in Ovarian Hyperstimulation Syndrome (OHH) are another predisposing factor for torsion.
- It is rare to see ovarian torsion from cysts smaller than 5 cm.
- Torsion is common in adolescents. Causes include markedly mobile fallopian tubes or mesosalpinx, elongated pelvic ligaments, fallopian tube spasm, strenuous exercise, or abrupt changes in intraabdominal pressure.

(6) Predisposing conditions (for NOT causing Torsion) :-

- Ovarian torsion is uncommon after pelvic inflammatory disease, endometriosis, or malignant neoplasms. This may be due to the presence of adhesions, rendering the ovaries relatively immobile.
- Some studies have shown that the right ovary is more likely to twist because the space occupied by the sigmoid colon on the left side protects the left ovary.

(7) Diagnosis of Ovarian Torsion:-

Sonography appears to be an excellent method to evaluate patients with suspected ovarian torsion. Abnormal and absent blood flow detected by sonography is highly predictive of ovarian torsion and is therefore useful in the diagnosis of this phenomenon.

The investigation of choice include: Ultrasound-CT-MRI in that order. However in suspected conditions like Renal Colic, Diverticulitis etc. CT will be a better investigation of choice.

(8) Mimics (and Ultrasonological Pitfalls) of Ovarian Torsion:

- Common mimics of ovarian torsion are the masses that predispose the ovary to twist on its vascular pedicle. However, it is as important to correctly identify the absence of torsion to allow conservative treatment, avoiding unnecessary invasive or additional diagnostic procedures.
- Hemorrhagic ovarian cysts are called "the great imitator" owing to their multiple appearances depending on the age of the blood. They commonly result from bleeding into the corpus luteum or follicular cyst and mainly occur in premenopausal women. Patients present with sharp pelvic or lower abdominal pain. Common stages of bleeding are (i) active hemorrhage, which appears anechoic at sonography, (ii) clot formation, (iii) retraction, and (iv) resolution. The most typical finding of a hemorrhagic cyst at US is an avascular cyst with a fine reticular pattern, the so-called Fishnet appearance, representing residual fibrin strands. The retracting blood clot may also be seen as an echogenic focus within an anechoic structure. A fluid-fluid or fluid-debris level may also be visualized when blood products separate.

(9) Some other conditions that can mimic torsion -

- **Ectopic pregnancy** : which often presents as a haemorrhagic complex adnexal mass on ultrasound, is usually excluded from consideration with a negative serum Beta HCG test.
- **Necrotic ovarian metastases**: Lack of a twisted pedicle and positive parenchymal blood flow on Ultrasound should decrease the level of suspicion for underlying torsion.
- **Infarction of a pedunculated sub-serosal or broad ligament fibroid**: May mimic ovarian torsion clinically. On USG however, the ovaries will appear normal. On CT, the Infarcting fibroids typically show decreased enhancement and surrounding edema.
- Appendicitis.
- Diverticulitis.
- Renal colic

(10) Normal Sonological anatomy of the Ovary :-

An ovary is normally an ellipsoid structure with a premenopausal volume of less than 8 cm³. It is an ellipsoid structure with small, randomly distributed follicles.

Ovaries have a dual arterial supply from the ovarian artery and the adnexal branch of the uterine artery.

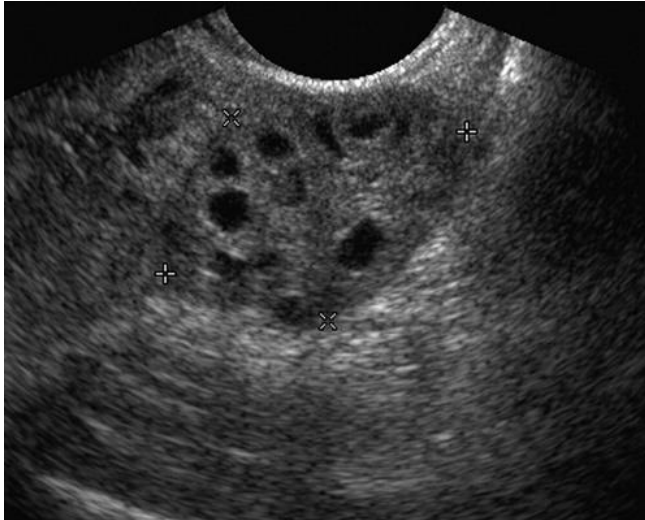


Figure 1. Sonography of a normal ovary with randomly arranged follicles

(11) Arterial supply to the Ovary

Ovaries have a dual arterial supply: (1) from the ovarian artery and (2) the adnexal branch of the uterine artery.

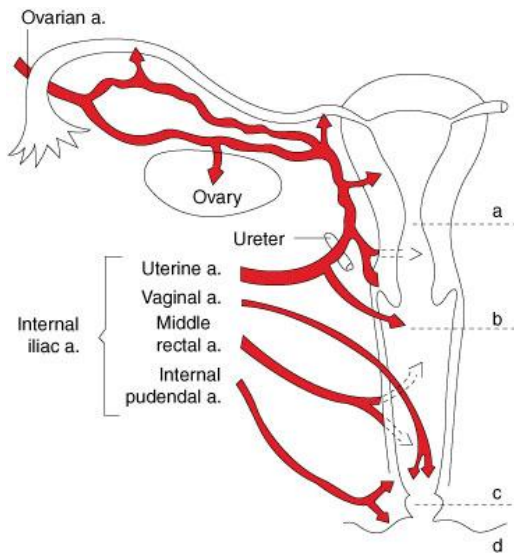
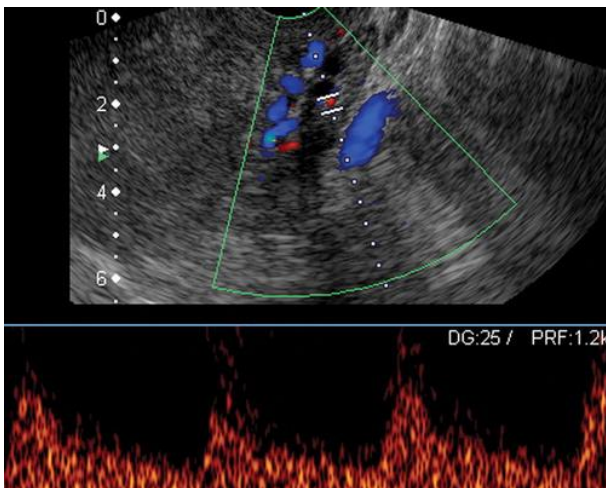


Figure # 2. Arterial supply to the ovary

(12) Doppler imaging of the Ovarian Artery :-



Ultrasound Doppler image of an ovarian artery in a normal ovary shows low-resistance flow.

Figure Number 3 : Doppler imaging of the Ovarian Artery –

US image of an ovarian artery in a normal ovary shows low-resistance flow.

(13) The Venous and Lymphatic drainage of the ovaries

- The left ovarian vein drains into the left renal vein.
- The right ovarian empties directly into the inferior vena cava.
- Lymph drainage of the ovary is primarily into the ipsilateral aortic nodes, however, the iliac nodes may also be involved.

(14) Grey Scale Ultrasound findings of Ovarian Torsion:-

- Enlarged hypo- or hyperechoic ovary
- Peripherally displaced follicles with hyperechoic central stroma
- Midline ovary
- Free pelvic fluid: may be seen in >80% of cases
- An underlying ovarian lesion may be seen (possible lead point for torsion)
- A long-standing infarcted ovary may have a more complex appearance with cystic or haemorrhagic degeneration.

(15) Colour Doppler Findings in Ovarian Torsion:-

- Doppler findings in torsion are widely variable
 - little or no intra-ovarian venous flow (common)
 - absent arterial flow (less common, sign of poor prognosis)
 - absent or reversed diastolic flow
 - normal vascularity does not rule out intermittent torsion. A normal Doppler flow can also occasionally be found due to dual supply from both the ovarian and uterine arteries
- Whirlpool sign of twisted vascular pedicle
- ovary tenderness to transducer pressure

(16) The "Whirlpool" Sign:-

- A positive Whirlpool sign in the twisted vascular pedicle of the ovary is the most definitive sign of ovarian torsion. Absence of blood flow in the twisted pedicle and non-visualization of the flow in the artery are predictive of nonviability of the ovary.

(17) Appearance of the "Whirlpool" sign on Ultrasound:-

- The appearance of the twisted pedicle is as a mass with a target appearance, either with or without a central echogenic dot.
- In few patients, the target lesion may have string of hypoechoic beads surrounding it, suggestive of dilated veins.

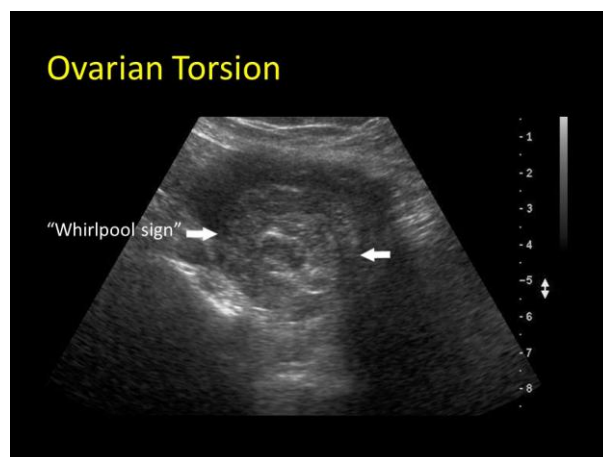


Figure # 4: The Whirlpool Sign

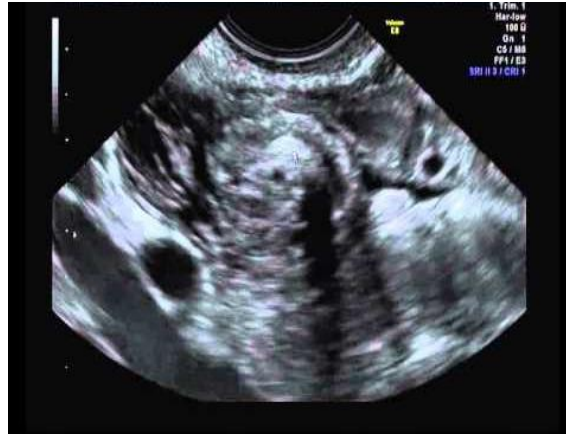

Figure # 5 - The Whirlpool Sign

(18) Some Illustrations of cases of Ovarian Torsion & the Sonological Findings in them

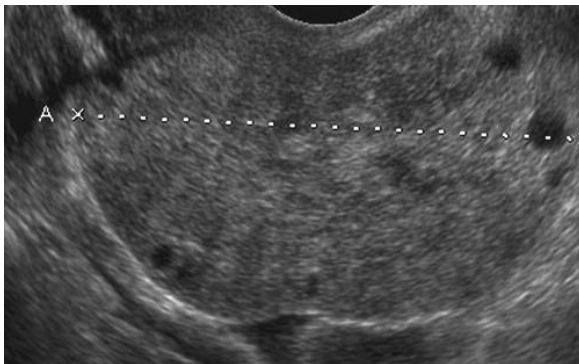


Figure # 6. Ovarian Torsion

Longitudinal sonogram shows an enlarged 7-cm ovary (between cursors labeled A) with peripheral cysts

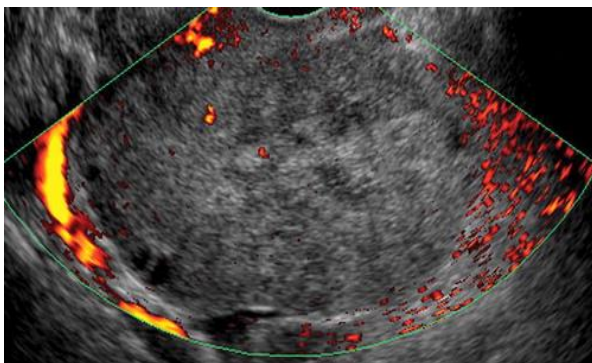


Figure # 7. Ovarian Torsion

Power Doppler sonogram shows complete absence of blood flow in the ovary. The pinpoint foci of color in the center of the ovary are secondary motion artifact.

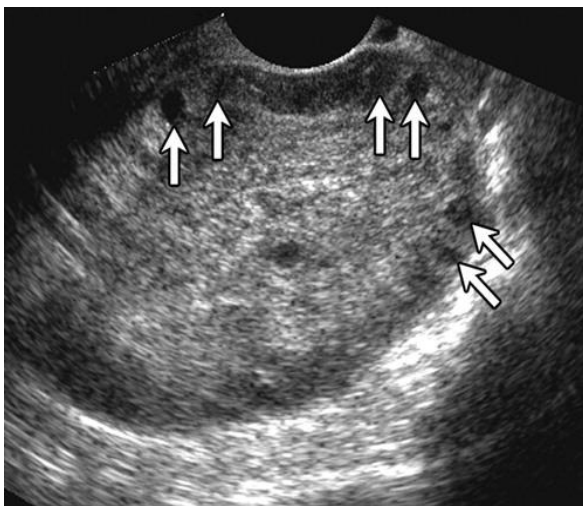


Figure # 8. Ovarian Torsion

Surgically proved ovarian torsion in a 31-year-old woman. Gray-scale US image shows an enlarged ($8 \times 7 \times 5$ -cm) ovary with multiple peripheral cystic structures? Follicles (arrows). In the normal state the follicles are arranged randomly and not at the periphery as in the pic. Please also refer to Figure # 1.

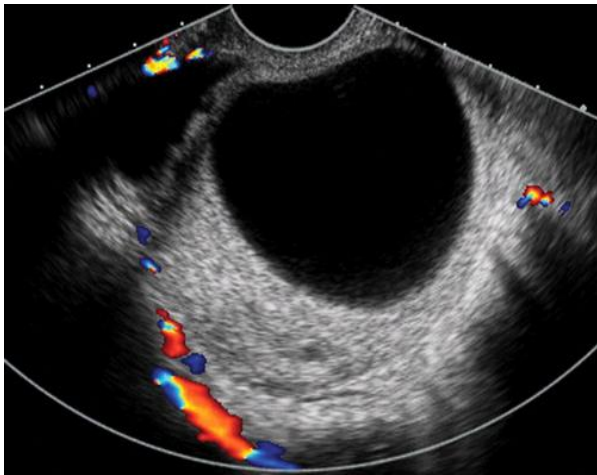


Figure # 9. Ovarian Torsion in a coexistent cystadenoma

Surgically proved torsion of ovary with a serous cystadenoma in a 20-year-old lady. Color Doppler image shows a large (7 × 6 × 5-cm) anechoic cyst surrounded by a scant amount of ovarian tissue with no evidence of blood flow in the ovarian tissue.

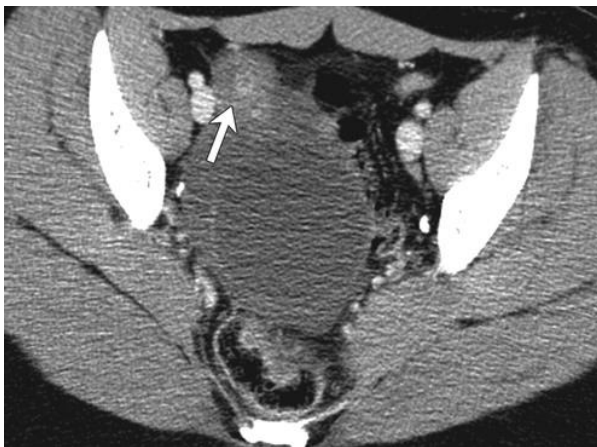

Figure # 10. CT findings of the same patient as in the figure # 9

Corresponding axial CT image shows the non-enhancing right ovary that contains the cyst in the midline, a thickened fallopian tube (arrow), and a small amount of free pelvic fluid. At surgery, the ovary was twisted & appeared purple-blue-black. Detorsion revealed initial viability of the proximal ovary, and a partial oophorectomy was done.

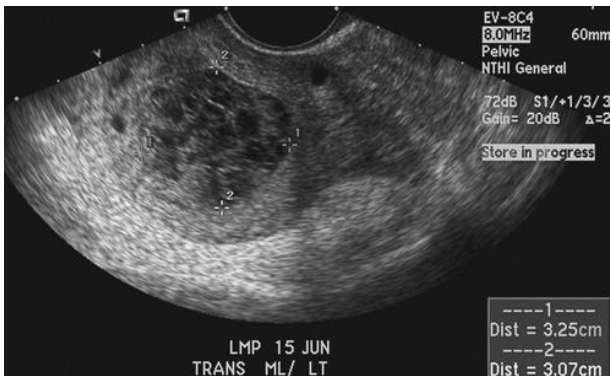

Figure # 11, Fishnet Appearance in an Ovarian Torsion

Ovarian torsion in a 32-year-old woman. Transverse sonogram of the left ovary shows a central hemorrhagic cyst (cursors) with the classic "Fishnet" appearance.

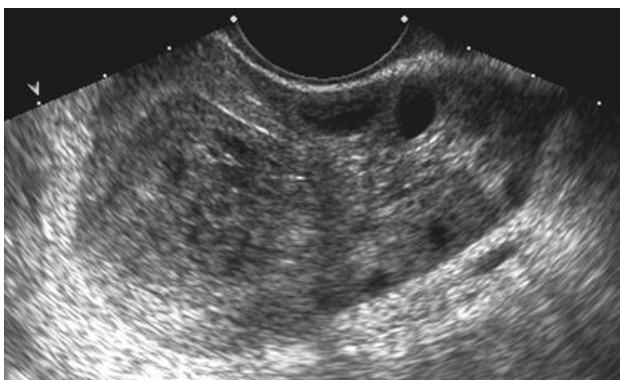

Figure # 12, Same patient as in Fig # 11

Ovarian torsion in the 32-year-old woman. Longitudinal sonogram shows peripheral cystic structures. A hemorrhagic cyst can act as a heavy point, weighing down the ovary and predisposing it to torsion.

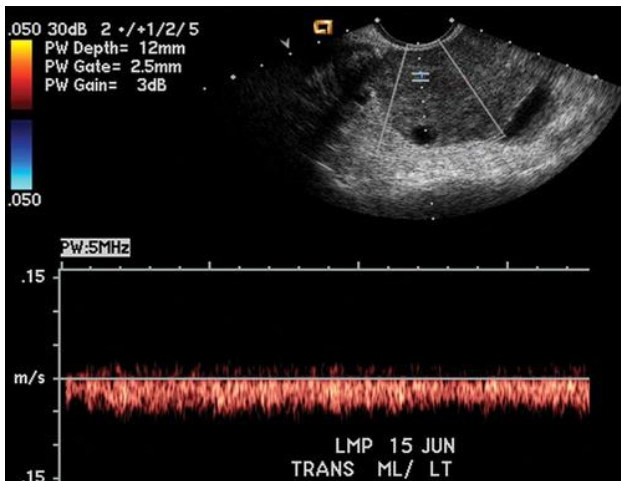


Figure # 13, Ovarian Torsion. No arterial Flow.

On a duplex US Doppler no arterial flow could be detected. There is also a small amount of pelvic free fluid.

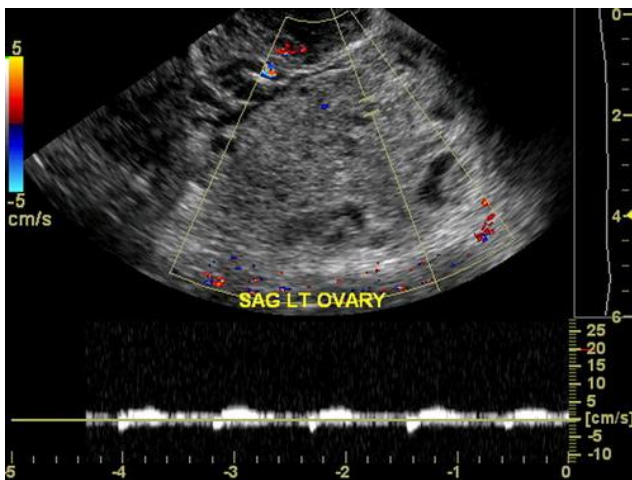


Figure # 14, Dampened arterial Flow in Ovarian Torsion.

Duplex US image shows minimal flow with damped arterial waveforms.

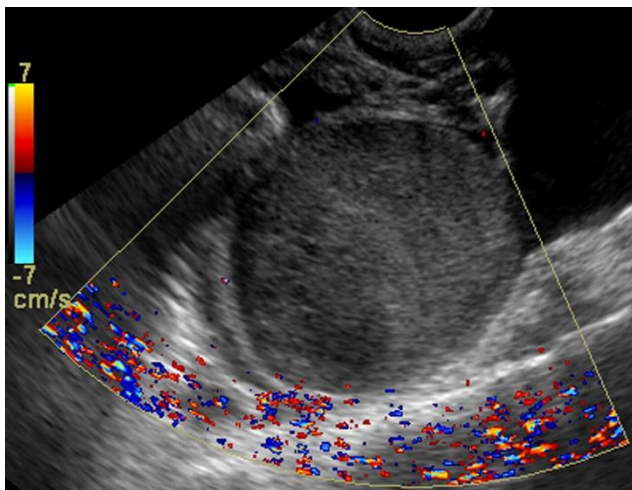


Figure # 15, Torsion Mimics – Hemorrhagic Ovarian cysts

Hemorrhagic ovarian cysts. Color Doppler image of an ovary shows an enlarged solid mass with no evidence of normal ovarian tissue or flow, an appearance suggestive of a hemorrhagic cyst. These findings could be easily confused with those of a twisted ovary.

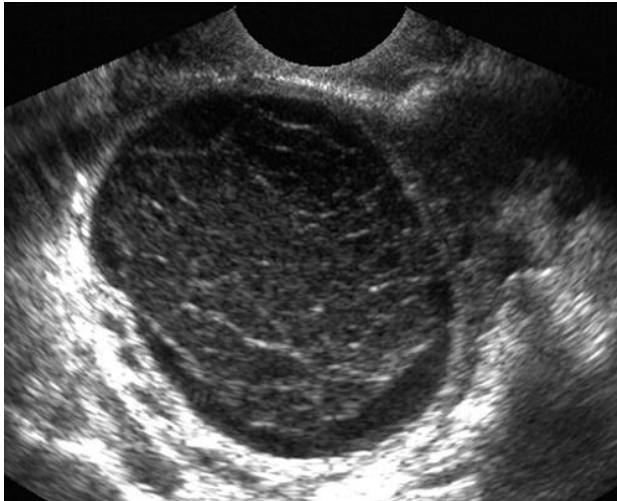


Figure # 16, Torsion Mimics – Hemorrhagic ovarian cysts

US image shows an ovarian cyst that contains multiple echogenic bands against a hypoechoic background. This “Fishnet appearance” represents residual fibrin strands

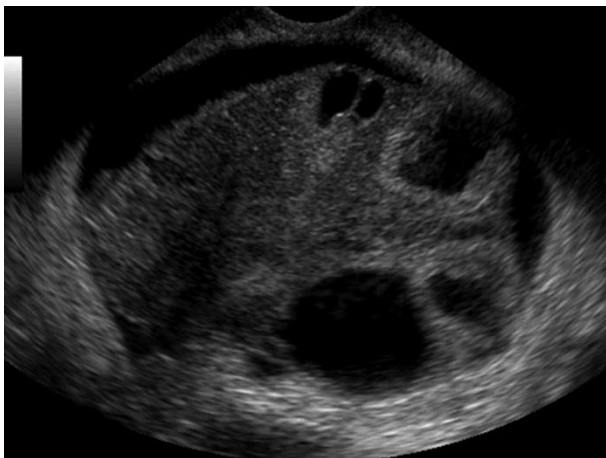


Figure # 17, Torsion Mimic – OHSS, Ovarian Hyper-Stimulation Syndrome

Ovarian hyperstimulation syndrome (OHSS) is a rare, iatrogenic complication of ovulation stimulation for the treatment of infertility commonly occurring during the luteal phase or early pregnancy. Early manifestations include mild ovarian enlargement with abdominal discomfort. This can progress to bilateral cystic ovaries with pain, scant ascites, abdominal distention, nausea, and vomiting. Imaging findings include bilaterally enlarged ovaries due to multiple distended, peripherally located corpora lutea cysts, producing the “**Spoke wheel**” appearance. We can see this in the figure # 17.

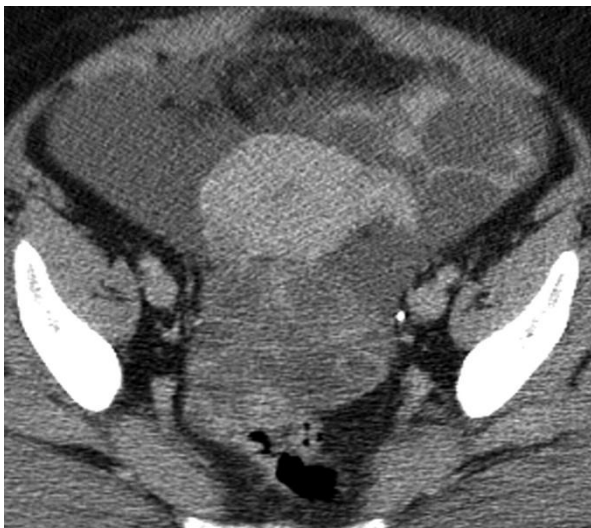

Figure # 18, OHSS, CT Findings :-

Ovarian Hyper-stimulation Syndrome
CT image shows bilateral enlarged cystic ovaries. There is a predisposition for torsion in patients with OHSS; however, a twisted ovary demonstrates a relative lack of or decreased blood flow.

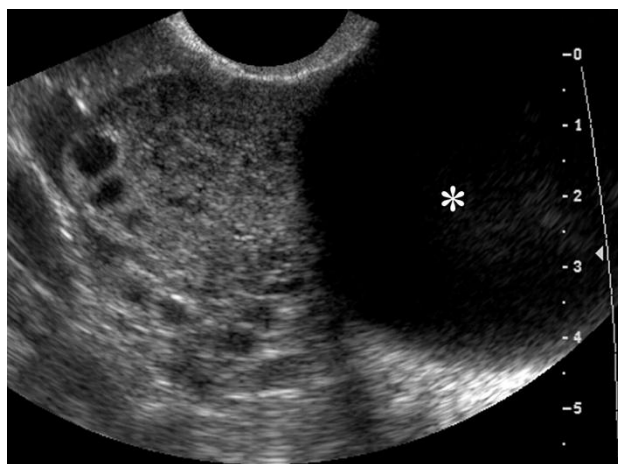

Figure # 19, Torsion Mimics – Benign Neoplasms like Serous Cystadenomas

- Commonly, serous cystadenomas are large, unilocular, thin-walled cystic lesions that may have thin septations or papillary projection. The increased bulk predisposes torsion.
- Sagittal gray-scale US image shows a large cyst arising peripherally from the right ovary

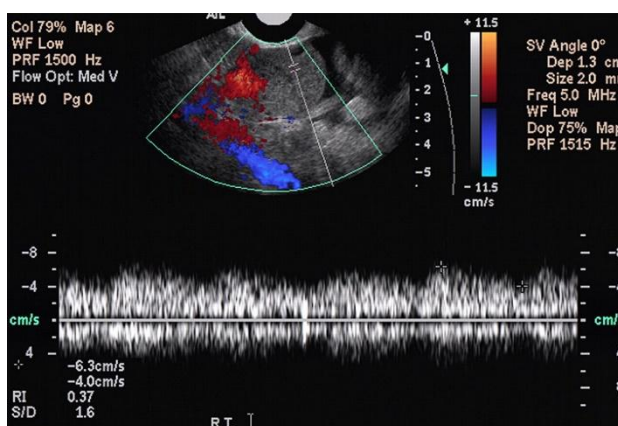


Figure # 20, (same case as figure no. 19).

Duplex US image shows that the arterial waveform is very much present and is showing the normal low resistance in the peripheral normal ovarian tissue. So this is not a case of torsion, but a mimic due to a different condition.

(19) Some Other conditions that may mimic Ovarian Torsion:

- Ectopic pregnancy
- Necrotic ovarian metastases
- Infarction of a pedunculated sub-serosal or broad ligament fibroid
- Appendicitis.
- Diverticulitis.
- Renal colic.

(20) The Golden question:-

How accurate is Ultrasound/Doppler in detection of ovarian torsion ?

- The sensitivity and specificity of sonography were near 96 % and 97%, respectively in the diagnosis of torsion. Sonography has a total accuracy of 96.5% for detection of ovarian torsion if there is an enlarged ovary and absence of arterial and venous flow.

Nizar K, Deutsch M, Filmer S, Weizman B, Beloosesky R, Weiner Z. Doppler studies of the ovarian venous blood flow in the diagnosis of adnexal torsion. Journal of clinical ultrasound 2012 : JCU. 37 (8): 436-9

Conclusion:

Sonography appears to be an excellent method to evaluate patients with suspected ovarian torsion. Abnormal and absent blood flow detected by sonography is highly predictive of ovarian torsion and is therefore useful in the diagnosis of this phenomenon.

The investigation of choice included: Ultrasound-CT-MRI in that order. However in suspected conditions like Renal Colic, Diverticulitis etc. CT will be a better investigation of choice.

Dr Gauraw Kumar Srivastava, et. al. "Pearls, Pitfalls & Mimicks In The "Ultrasound Diagnosis" Of Ovarian Torsion." *IOSR Journal of Dental and Medical Sciences (IOSR-JDMS)*, 19(9), 2020, pp. 36-44.