

## An Accidental Traumatic Pseudolipoma- A Case Report

Dr. Joel D'silva<sup>1</sup>, Dr. Athiramol. C.K<sup>2</sup>, Dr. Jency Anna Mathew<sup>3</sup>,

Dr. Ujjwal kumar Singh<sup>4</sup>

*Dr. Joel D'Silva; Master in dental surgery- Assistant Professor- AJ Institute of Dental Sciences , Dr. Athiramol.C.K; Master in Dental Surgery – Postgraduate -AJ Institute of Dental Sciences, Dr. Jency Anna Mathew; Master in Dental Surgery Postgraduate- AJ Institute of Dental Sciences.Dr. Ujjwal kumar singh, master in dental surgery postgraduate AJ institute of dental sciences  
Corresponding author – Dr. Athiramol.C.K*

**Abstract:** The incidence of maxillofacial trauma being common to the pediatric population, have variant squeale, traumatic herniation of buccal fat pad being one of the rare few. The rarity and ignorance regarding the growth in the buccal mucosa resembling a tumour in the post traumatic period is often alarming not only to the patient but also to the attending physician. The pedunculated mass after trauma to the soft tissue of buccal mucosa in traumatic herniation of buccal fat pad presents itself as an expanding growth. We present an interesting case of a two year old male patient with traumatic herniation of buccal fat pad following an accidental fall on a sharp instrument.

Date of Submission: 20-08-2020

Date of Acceptance: 06-09-2020

### I. Introduction

Lipoma is a benign neoplasm with mature adipose tissue surrounded by thin fibrous capsule of mesenchymal origin<sup>1</sup>. 4% of the lipomas occur in the oral cavity out of the 20% that occur in the head and neck region, which is considered to be most commonly occurring anatomical area in the entire human body.<sup>2</sup>

'Traumatic pseudolipoma', the term, was formulated by Brooke and Mac Gregor in the year 1969.<sup>3</sup> Adair et al described pseudolipomas as aberrant but normal adipose tissue.<sup>4</sup> The term 'traumatic pseudolipoma' describes the intra-oral herniation of the buccal fat pad resulting from trauma to the buccal mucosa and buccinator muscle causing extrusion of buccal fat pad into the oral cavity. The most common incidence is in the age group of 5 months to 5 years.<sup>5,6</sup>

'Post traumatic lipomas' (PLT) is another term used to describe lipoma formation secondary to the trauma and hematoma accumulation, owing to cytokine mediated deposition of adipocytes usually seen in the 4<sup>th</sup> to 6<sup>th</sup> decades of life.<sup>5</sup>

The purpose of this report is to describe one such unusual presentation in a male child of 2 years reported to our Department of Oral and Maxillofacial surgery.

### II. Case Report

A two year old male child reported to the Oral and Maxillofacial Surgery OPD for evaluation of an oral mass with history of an accidental fall on a sharp kitchenware on the previous night. The patient's mother provided a detailed history of the incident in which she described an accidental fall from a height of 2 feet followed by bleeding from the left buccal mucosa that stopped spontaneously. Upon immediate inspection there were no apparent or significant abnormalities present. Post traumatically, after 6-8 hours, a large extruding mass was noted from the right buccal mucosa

A detailed examination was carried out to rule out facial fractures as well as dental injuries were ruled out. On extra oral examination laceration was seen over left side of lower lip, measuring 2\*2cm. Intra orally a reddish yellow soft pedunculated mass was seen extending from a laceration of the left buccal mucosa (Figure 1) which was non tender, ovoid, smooth and freely mobile.

The oral mass was approx. 3.5 × 2.0 × 1.0 cm in size protruding in relation to maxillary and mandibular left posterior teeth towards the occlusion, provisionally diagnosed as herniation of the buccal fat pad. foreign body granuloma, hemangioma and lipoma were considered as the differential diagnosis. After all necessary clinical and investigatory workups patient was planned for an excision biopsy and primary closure of lower lip laceration under GA. An informed written consent was obtained from patient's parent after explaining the treatment procedure and possible complications. Nasotracheal intubation was carried out, following all standard aseptic protocols an intra oral infiltration of LA (lignocaine with adrenaline) was given along the buccal mucosa. A 4.0 silk suture was used to secure the pedunculated tissue and was excised enbloc from the

base of the buccal mucosa. The excised mass was lobulated and soft in consistency which was sent for histopathological examination (Figure 2).

The wound was closed primarily using resorbable 3-0 vicryl (absorbable polygalactin). General anesthesia reversed and patient was shifted to postoperative ward uneventfully. There were no associated intraoperative or postoperative complications. Patient recovered uneventfully without any cosmetic deformity.

Histopathological examination revealed well circumscribed lobules of mature adipocytes separated by thin fibro vascular septae with predominant inflammatory infiltrate of neutrophils and a histopathological impression of **Lobular Panniculitis** was given.(figure 3)

Patient was on routine follow-up and had an uneventful recovery (Figure 4).

### III. Discussion

Post-traumatic pseudolipomas (PTLs) are a poorly recognized and investigated clinical entity and were first documented in the literature in 1932. The buccal fat pad also called as Buccal fat pad of Bichat is larger and more prominent in neonates, infants and young children.<sup>1, 2</sup> It is of significance as it provides fullness to the face and in the same time aids in cushioning and suckling in neonates and children. Buccal fat pads are anatomically seen between the masseter and buccinator muscles. They are of importance in their action of guidance of masticatory muscles and their approximation to the parotid duct and the facial nerve. In infants, it provides muscular support for suckling and plays an extensive role in adults by establishing the cheek contour. They act as cushion to protect sensitive facial muscles from injury due to muscle action or external forces. The herniation into the oral cavity can result from a slight breach of the buccinator muscle in infants.<sup>4</sup> The negative intraoral pressure activated by their suckling activity may stimulate the herniation of buccal fat pad from mucosal breach and carry the risk of respiratory distress. An increased incidence of traumatic pseudolipoma in infants and children is associated with frequent habit of placing foreign objects like tooth brush pencil etc. into their mouth.<sup>6</sup> Matarasso proposed that the defect in the parotidomasseteric fascia of the region is the reason for traumatic herniation of buccal fat pad.

Treatment of traumatic pseudolipoma consists of 2 surgical procedures, either buccal fat pad replacement or excision.<sup>5</sup> The herniated tissues can be repositioned back to its place and sutured in cases with a small protruded mass that are evaluated early (approx.. time period within 4 hours). In certain circumstances where there is a delay in evaluation and treatment resulting in contamination and necrosis of the tissue. For larger mass, it is advocated to do excision from the base of the mucosa to prevent recurrence.<sup>5,6</sup> A case reported by Rathi et al have done excision of traumatic pseudolipoma mass from its base using laser diode that not only excises the soft tissue by also reduces the bacterial load in the wound. Thermal necrosis zone by using the laser diode can be achieved as little as less than 1cm<sup>6</sup>.

### IV. Conclusion

Following the above syllogism, it can be concluded that careful attention is to be given to penetrating soft tissue injuries of oral soft tissues. For an accurate diagnosis and treatment planning, it demands thorough evaluation of such injuries or lesions.

**Acknowledgment-** The authors thank all the faculty and residents from Department of Oral and Maxillofacial Surgery and Anesthesiology.

#### "Why this paper is important to paediatric dentists"

1. A rare lesion found in pediatric patients following blunt trauma
2. Less case reports on pseudolipoma in pediatric individuals found in literature

### References

- [1]. Fregnani ER, Pires FR, Falzoni R, Lopes MA, Vargas PA. Lipomas of the oral cavity: clinical findings, histological classification and proliferative activity of 46 cases. *Int J Oral Maxillofac Surg.* 2003; 32:49–53
- [2]. Kunal Sah, Sunira Chandra,<sup>1</sup> Alka Kale,<sup>2</sup> Seema Awasthi,<sup>3</sup> and Priyanka Rastogi. Traumatic pseudolipoma causing facial asymmetry: An uncommon pathology and review of its pathogenesis. *J Oral Maxillofac Patholgv.* 15(1); Jan-Apr 2011
- [3]. Brooke RI, MacGregor AJ. Traumatic pseudolipoma of the buccal mucosa. *Oral Surg.* 1969; 28: 223–5.
- [4]. Ramoutar VRN, Patel PP, Isache CL. An Unusual Presentation of Ventral Post-Traumatic Pseudolipomas in a Surfer: a case report. *European Journal of Medical Case Reports.* 2017; 1: 40-43
- [5]. K. Gadhia, K. Rehman, R. W. Williams, I. Sharp: Traumatic pseudolipoma: herniation of buccal fat pad, a report of two cases. *Int. J. Oral Maxillofac. Surg.* 2009; 38: 694– 696

FIGURE LEGENDS

FIGURE 1

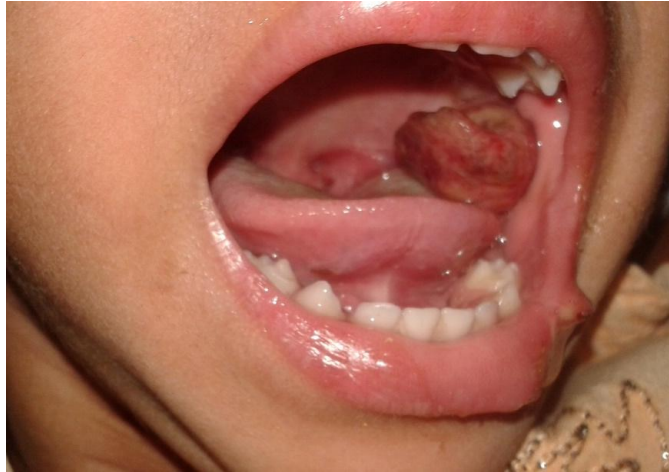

FIGURE 2

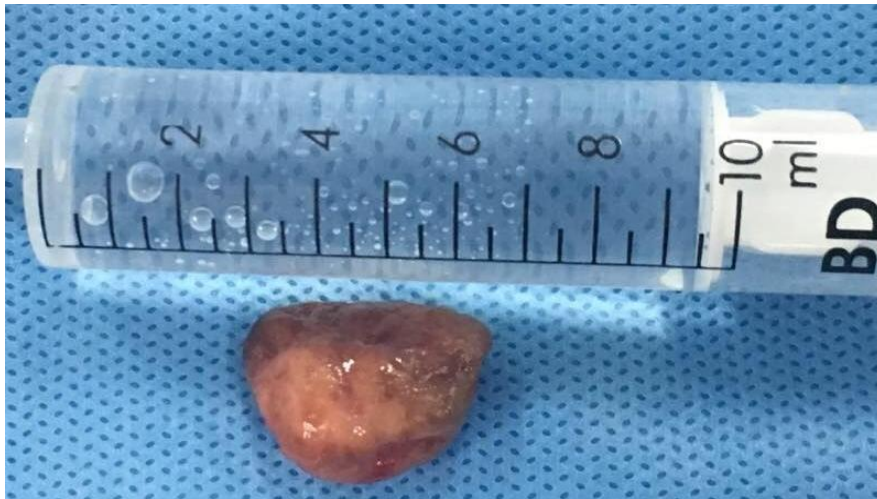
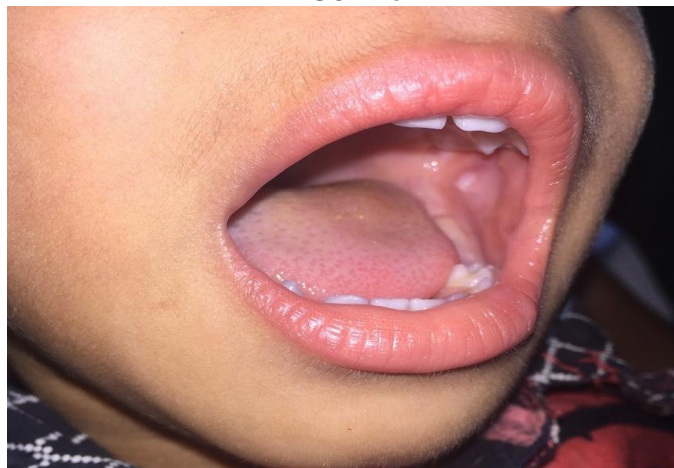

FIGURE 3



Dr. Athiramol.C.K, et. al. "An Accidental Traumatic Pseudolipoma- A Case Report." *IOSR Journal of Dental and Medical Sciences (IOSR-JDMS)*, 19(9), 2020, pp. 01-03.