

## Management of Internal Root Resorption with MTA and Thermoplasticised Gutta-Percha: A Case Report

Dr. Ruchika Gupta<sup>1</sup>, Dr. Pramod Mohite<sup>2</sup>, Dr. Anuja Hakkepatil<sup>3</sup>, Dr. Nandita Bansal, Dr. Vinod Kambli<sup>5</sup>

*1(Department of conservative dentistry and endodontics D Y Patil Dental School, Lohegaon, Pune India)*

*2(Department of conservative dentistry and endodontics VasantdadaPatil Dental College and Hospital, sangli, India)*

*3(Department of conservative dentistry and endodontics D Y Patil Dental School, Lohegaon, Pune India)*

*4(Department of conservative dentistry and endodontics D Y Patil Dental School, Lohegaon, Pune India)*

*5(Department of conservative dentistry and endodontics D Y Patil Dental School, Lohegaon, Pune India)*

### Abstract

Management of internal root resorption is a challenge to the endodontists. It may occur in cases with chronic pulpal inflammation, following caries or due to trauma in the form of an accidental blow. Most cases of internal root resorption are seen in anterior teeth, due to their susceptibility to trauma. Early detection and a correct differential diagnosis are essential for successful management of the internal resorption to prevent over weakening of remaining tooth structure and root perforations. Internal root resorption lesions present the endodontist with unique difficulties in the preparation and obturation of the affected tooth. This case report presents successful management of a case of internal resorption using MTA followed by thermoplasticised gutta-percha.

**Key words:** Internal root resorption, root canal, mineral trioxide aggregate, thermoplasticised gutta-percha

**Key Message:** Root canal treatment is the gold standard for internal resorption defect as it removes the granulation tissue and blood supply of the clastic cells. Sodium Hypochlorite, ultrasonic instrumentation and calcium hydroxide are the cornerstones of treatment of internal inflammatory root resorption. Alternative materials such as MTA offer new opportunities for the rehabilitation of resorbed teeth.

Date of Submission: 30-07-2020

Date of Acceptance: 15-08-2020

### I. Introduction

Resorption is a condition associated with either a physiologic or a pathologic process resulting in a loss of dentin, cementum, and/or bone.<sup>1</sup> It is caused by transformation of normal pulp tissue into granulomatous tissue with giant cells, which resorb dentin. Trauma and pulpal inflammation are two of the major contributory factors in the initiation of internal resorption.<sup>2</sup> For internal root resorption to occur, the outermost protective odontoblast layer and the predentin of the canal wall must be damaged, resulting in exposure of the underlying mineralized dentin to odontoclasts.<sup>3</sup> In a study of 25 teeth with internal resorption, trauma was responsible for 45% of the cases examined, followed by carious lesions (25%).<sup>4</sup> Internal resorption is a rare condition because clinically, internal root resorption is usually asymptomatic and is detected coincidentally through routine radiographs. If resorption occurs in the coronal portion of the tooth, it exhibits a pinkish hue that is classically described as the *pink tooth of Mummery* after the 19th century anatomist *James Howard Mummery*, who first reported the phenomenon.<sup>3</sup> Radiographs are mandatory for diagnosing internal resorption, which reveals a *round-to-oval* radiolucent enlargement of the pulp space.<sup>5</sup> In order to control the internal root resorption, it is necessary to treat the root canal aiming to remove all the pulp tissue and achieve a better sealing.<sup>6</sup>

**Case history:** A 25-year-old male patient reported to the Department of Conservative Dentistry & Endodontics, with a chief complaint of discolored tooth in upper left region of the jaw. Patient gave no history of pain or discomfort associated with chief complaint tooth i.e. tooth number 21. Patient had noticed the discoloration since two years. He gave history of trauma to the same region 5- 6 yrs before and he said because of trauma his upper left tooth came out and it was placed back into the jaw by some local dentist whom he reported at that time. His tooth was fine after that for 1- 2 years and then it gradually became discolored. The Patient's medical history was noncontributory. Clinical examination revealed discolored 21 [Figure 1 (a)] and temporary filling material on the lingual surface of the tooth. There was no evidence of swelling or sinus tract formation in this region. The tooth was not tender to percussion, palpation, or biting. The periodontal probing was within normal range (2-3mm). Patient's oral hygiene was fair. Radiographic examination revealed

radiopaque filling material in the pulp chamber and a *round to oval* shaped radiolucency at the middle part of root suggestive of internal root resorption [Figure 1 (b)] which was confirmed by taking multiple angulated radiographs. The electric and thermal pulp sensibility tests were both negative with tooth 21. From the clinical and radiographic findings, a diagnosis of inflammatory internal root resorption in tooth number 21 was made and endodontic treatment of tooth number 21 was suggested to the patient.

The tooth was isolated with rubber-dam (Hygienic Dental Dam, ColteneWhaledent Germany) and removal of temporary filling material was done, followed by access cavity preparation with high speed air turbine with careful attention to the direction of the Endo-Access bur. Operating microscope (Global Surgicals Corporation, St Louis, MO, US) was used throughout the procedure to facilitate visualization. Canals were thoroughly irrigated with normal saline followed by 5.25% sodium hypochlorite. The working length of the tooth was measured first manually and then by Root ZX apex locator (J. Morita Mfg. corp., Kyoto, Japan) which was confirmed radiographically [Figure 1 (c)]. Biomechanical preparation was done with stainless steel hand files until an apical stop of ISO #60 was created. Root canals were copiously irrigated with 5.25% sodium hypochlorite solution using non-traumatic plastic tips of EndoActivator (Dentsply) for achieving a complete chemo-mechanical debridement followed by a final rinse with 5ml of sterile saline. Subsequently a calcium hydroxide dressing (RC CAL, Prime Dental Products, India) was placed for a period of 30 days with change of dressing after every 7 days. A small cotton pallet was placed and the access cavity was temporarily sealed with Cavit (3M ESPE, Saint Paul, MN).

After 30-day interval, the root canal was re-entered and irrigated alternately 5.25% NaOCl and sterile saline to remove the temporary dressing; 17 % EDTA solution was left flooded in the cavity for 5 minutes which was later rinsed with 5 ml of sterile saline. Confirmation of not having perforation through the periphery of internal resorption defect during root canal instrumentation was done with dried sterile absorbent paper points. Master cone selection was done and confirmed radiographically. Then downpack (area below the resorptive cavity) was done with 5 mm of gutta-percha and AH plus using sectional method of obturation, care was taken not to fill the resorptive area with the sealer and it was confirmed radiographically. Then white MTA (MTA Angelus, Londrina, Brazil) was mixed according to manufacturer's instructions to a paste consistency with sterile water and delivered to the resorptive cavity using a nonsurgical MTA carrier (Micro Apical Placement System, ProduitsDentaires, Vevey, Switzerland) and it was condensed laterally against the walls of resorption cavity with root canal spreaders and pluggers (DentsplyMaillefer) [Figure 1(d)] to get a homogenous well sealed area of resorptive defect and it was confirmed radiographically [Figure 1(e)]. Then a sterile moist cotton pellet was placed inside for setting of MTA and access cavity was sealed with Cavit (3M ESPE, Saint Paul, MN). The patient was recalled after 24 hours, and after ensuring complete set of the material the remainder of canal was backfilled with an E& Q gun (META BIOMED) using thermoplastic gutta-percha with AH plus sealer (Dentsply). Warm gutta-percha at the orifice was vertically compacted by using appropriate sized pluggers. Immediate postoperative radiograph showed dense obturation of the canal including the resorptive defect [Figure 2 (a)]. After completion of root canal treatment, the tooth was restored using composite resin (3M Dental Products, Saint Paul, MN) [Figure 2 (b)]. After 15 days patient was recalled and crown preparation of tooth 21 was done, and rubber base impressions were received. Then impressions were sent to laboratory for fabrication of crown and then zirconia crown was cemented [Figure 2 (c)]. After six-month follow-up, the patient was asymptomatic demonstrating a functional tooth number 21. On clinical examination, there was no mobility or pain in response to percussion, palpation, or biting and the patient had a healthy gingiva and no periodontal pockets on probing. Radiographic examination revealed stoppage of resorptive process with intact dense obturation [Figure 2 (d)].

## **II. Discussion**

Internal root canal inflammatory resorption involves a progressive loss of intraradicular dentin without adjunctive deposition of hard tissues adjacent to the resorptive sites. Damage to the odontoblast layer and predentin of the canal wall is a prerequisite for the initiation of internal root resorption. However, the advancement of internal root resorption depends on bacterial stimulation of the clastic cells involved in hard tissue resorption. Without this stimulation, the resorption will be self-limiting. For internal resorption to occur, the pulp tissue apical to the resorptive lesion must have a viable blood supply to provide clastic cells and their nutrients, whereas the infected necrotic coronal pulp tissue provides stimulation for those clastic cells. Bacteria might enter the pulp canal through dentinal tubules, carious cavities, cracks, fractures, and lateral canals. In the absence of a bacterial stimulus, the resorption will be transient and might not advance to the stage that can be diagnosed clinically and radiographically. If left untreated, internal resorption might continue until the inflamed connective tissue filling the resorptive defect degenerates, advancing the lesion in an apical direction. The condition might go unnoticed until the lesion has advanced significantly, resulting in a perforation or symptoms of acute or chronic apical periodontitis after the entire pulp has undergone necrosis and the pulp space has

become infected.<sup>3</sup> Hence, root canal treatment must be initiated as soon as possible once an inflammatory resorptive lesion is detected to prevent further hard tissue loss and eventual root perforation.<sup>5</sup>

In the present case, considering the patient's age, periodontal status, resorption location, absence of perforations, and resistance of remaining root hard tissue, a nonsurgical endodontic treatment along with reinforcement by bioactive material like MTA remains the treatment of choice.

The aim of root canal treatment in the present case was to remove any remaining vital, apical tissue and the necrotic coronal portion of the pulp that might be sustaining and stimulating the resorbing cells via their blood supply, and to disinfect and obturate the root canal system.<sup>3</sup>

Access cavity preparation was done conservatively, to preserve as much tooth structure as possible, and to avoid further weakening of the already compromised tooth.<sup>7</sup> In teeth with actively resorbing lesions, bleeding from the inflamed pulpal and granulation tissues might be profuse and might impair visibility during the initial stages of chemomechanical debridement.<sup>3</sup> Therefore operating microscope was used throughout the procedure to enhance the vision.

The shape of the resorption defect usually renders it inaccessible to direct mechanical instrumentation. Therefore, the use of ultrasonic instruments to agitate the irrigant was done to improve the removal of necrotic debris and biofilms from inaccessible areas of the root canal.<sup>8</sup> Ultrasonic activation of irrigants after mechanical preparation of root canals has been shown to reduce the number of bacteria. Given the inaccessibility of internal root resorption lesions to chemomechanical debridement, ultrasonic activation of irrigants should be viewed as an essential step in the disinfection of the internal resorption defect.<sup>3</sup> EndoActivator was used to activate and facilitate the penetration of the irrigation solution of hypochlorite to all the areas of the root canal system for achieving complete chemomechanical debridement.

However, even with the use of ultrasonic instruments, bacteria might still remain in confined areas. Chemomechanical debridement of the root canal space fails to consistently render the root canal system bacteria-free.<sup>3</sup> Thus, an intracanal, antibacterial medicament was used to improve disinfection of the inaccessible root resorption defects. Calcium hydroxide is antibacterial and has been shown to effectively eradicate bacteria that persist after chemomechanical instrumentation. Calcium hydroxide has also been shown to have a synergistic effect when used in conjunction with sodium hypochlorite to remove organic debris from the root canal.<sup>9</sup> The use of calcium hydroxide as an interappointment dressing helps to control the bleeding, maximizes the effect of disinfection procedures, maintains alkalinity, and necrotizes residual pulp tissue.<sup>5</sup> Nevertheless, some case reports demonstrated the inability of calcium hydroxide to eliminate bacteria in ramifications because of its low solubility and inactivation by dentin, tissue fluids, and organic matter. Despite these limitations, the use of multiple calcium hydroxide dressings has been advocated to enhance chemomechanical debridement of the internal root resorption defect.<sup>3</sup>

In the present case root canal wall was not perforated due to resorption but still MTA was used to reinforce the thin and weakened tooth structure due to resorptive defect thereby enhancing the prognosis of the tooth. It has many beneficial properties, including good sealing characteristics, biocompatibility, bactericidal effects, radiopacity and ability to set in the presence of blood. Thus, MTA is a suitable material for the treatment of root resorption with the regenerating potential of a periodontal attachment and inducing osteogenesis and cementogenesis.<sup>10</sup>

By their very nature, internal root resorption defects can be difficult to obturate adequately. To completely seal the resorptive defect, the obturation material should be flowable. Thermoplastic gutta-percha techniques seem to give the best results when the canal walls are respected.<sup>11, 12</sup> The success or failure of therapy should be followed up clinically and by radiographic control.

### **III. Conclusion**

Success in management of a case of internal resorption depends on early detection, appropriate treatment planning, removal of inflammatory pulp tissue, reinforcement of weaker tooth structure, and a three-dimensional obturation. Modern endodontic techniques including optical aids, ultrasonic improvement of chemical debridement, and thermoplastic filling techniques should be used during the root canal treatment of internally resorbed teeth. Alternative materials such as calcium silicate cements offer new opportunities for the rehabilitation of resorbed teeth.

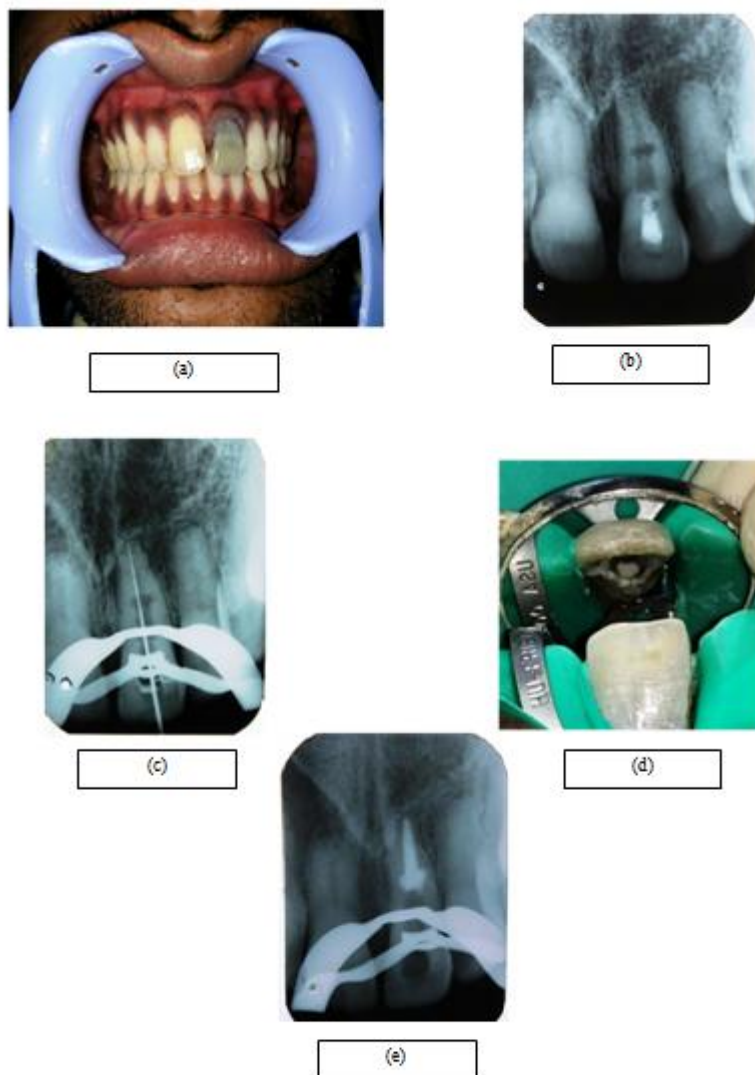### **References**

- [1]. American Association of Endodontists, "Glossary of endodontic terms," 2012, <http://www.aae.org/glossary/>.
- [2]. MaarteMeire, Roeland De Moor: Mineral Trioxide Aggregate Repair of a Perforating Internal Resorption in a Mandibular Molar. *J Endod* 2008; 34:220-23.
- [3]. S. Patel, D. Ricucci, C. Durak, and F. Tay, "Internal root resorption: a review," *J Endod* 2010; 36:1107–21.
- [4]. M. K. Caliskan and M. Turkun, "Prognosis of permanent teeth with internal resorption: a clinical review," *Endod Dent Traumatol* 1997; 13:75–81.
- [5]. M. Haapasalo and U. Endal, "Internal inflammatory root resorption: the unknown resorption of the tooth," *Endod. Topics* 2006; 14: 60–79.

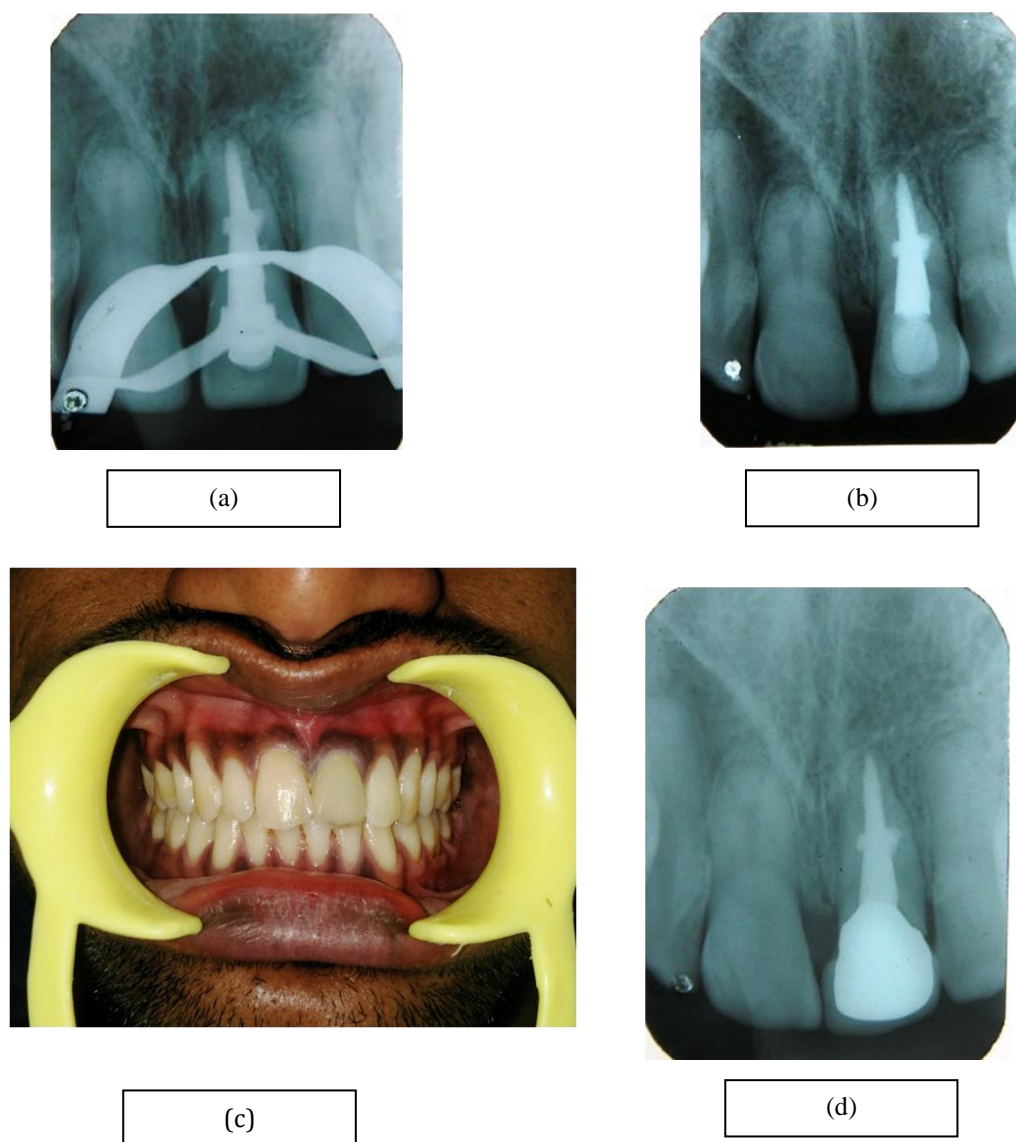
- [6]. M. Parirokh and M. Torabinejad, "Mineral trioxide aggregate: a comprehensive literature review—part III: clinical applications, drawbacks, and mechanism of action," *J Endod* 2010; 36: 400–13.
- [7]. Maja Bendyk-Szeffer, RytaŁagocka, MatyldaTrusewicz, Mariusz Lipski, and Jadwiga Buczkowska-Radlinska, "Perforating Internal Root Resorption Repaired with Mineral Trioxide Aggregate Caused Complete Resolution of Odontogenic Sinus Mucositis: A Case Report". *J Endod* 2015; 41: 274-78.
- [8]. Elisabeth Nilsson, Eric Bonte, François Bayet, and Jean-Jacques Lasfargues. Management of Internal Root Resorption on Permanent Teeth. *Int J Dent.*2013;2013:929486
- [9]. Tu" rku" n M, Cengiz T. The effects of sodium hypochlorite and calcium hydroxide on tissue dissolution and root canal cleanliness. *IntEndod J* 1997; 30:335–42.
- [10]. J. Camilleri & T.R. Pitt Ford. Mineral trioxide aggregate: a review of the constituents and biological properties of the material. *IntEndod J* 2006; 39: 747–54.
- [11]. K. A. DuLac, C. J. Nielsen, T. J. Tomazic, P. J. Ferrillo Jr., and J. F.Hatton, "Comparison of the obturation of lateral canals by six techniques," *JEndod* 1999; 25: 376–80.
- [12]. M. K. Wu, A. Kařt'akov'a, and P. R. Wesselink, "Quality of cold and warm gutta-percha fillings in oval canals in mandibular premolars," *IntEndod J* 2001; 34:485–91.

**FIGURE LEGENDS**

Figure 1: (A) Preoperative clinical view (B) Preoperative radiograph (C) Working length radiograph (D) Clinical view after MTA fill (E) Confirmatory radiograph after downpack and MTA fill in resorptive defect  
 Figure 2: (A) Immediate radiograph after backfill (B) Final radiograph after composite restoration (C) Postoperative clinical view after crown cementation (D) One year follow up radiograph



**FIGURE 1: (a) Preoperative clinical view (b) Preoperative radiograph (c) working length radiograph (d) clinical view after MTA fill (e) Confirmatory radiograph after downpack and MTA fill in resorptive defect**



**FIGURE 2:(a) Immediate radiograph after backfill (b) Final radiograph after composite restoration (c)Postoperative clinical view after crown cementation (d) one year follow up radiograph**

Dr. Ruchika Gupta, et. al. "Management of Internal Root Resorption with MTA and Thermoplasticised Gutta-Percha: A Case Report." *IOSR Journal of Dental and Medical Sciences (IOSR-JDMS)*, 19(8), 2020, pp. 38-42.