

Evaluation of the Integrity of the Distal Radioulnar Joint in Fractures of Both Bone of Forearm

R. Jayganesh , Krishna. G, Mathan Kumar.S

Abstract:

Background: Study was done to know the integrity of the distal radioulnar joint after the fracture of both bones of forearm, also know the possible association between the level of fractures and instability of distal radioulnar joint.

METHODS: 65 patients of fracture of both bone forearm were treated in our hospital over the period of 2 years.

Results: Of the 37 preoperative distal radioulnar joint dislocations, 10 (27.02%) were associated with fracture of both bones of forearm in the distal third and 27(72.97%) were associated with middle third fractures. There were no distal radioulnar joint dislocations associated with the proximal third fractures. Of the immediate postoperative distal radioulnar joint dislocations, 12(30.77%) were associated with fracture of both bones of forearm in the lower third and 27(69.23%) were associated with middle third fractures. There were no distal radioulnar joint dislocations in the proximal third fractures.

Conclusion: Most of the fractures of both bone forearm at distal 3rd and middle 3rd were associated with instability of distal radioulnar joint. Also dislocation rate is significantly higher in proximal radial and distal ulnar fracture pattern.

Date of Submission: 30-07-2020

Date of Acceptance: 15-08-2020

I. Introduction

The distal radioulnar joint has been the forgotten joint of the forearm. The distal radioulnar joint, which developed as an adaptive change to brachiation and terminal branch feeding, was an excellent adaptive mechanism for the ultimate development of bipedalism. It was first brought to clinical attention by William Darrach in his article in the Annals of Surgery in 1912 in which he described the resection of the distal ulna for irreducible dislocation of the distal ulnar head. "In the present age of mechanization and active life, fractures of the forearm bones are on the rise due to rise in road traffic accidents. Dislocation of the distal radioulnar joint in association with fractures of both bones of the forearm has received relatively little attention in the literature. Mikic, in his series of 125 patients with Galeazzi fracture-dislocations, noted that 20% has fractures of the shafts of both bones of the forearm; not just the radius. Aim of this study is to assess the integrity of distal radioulnar joint following fracture of both bones of the forearm in adults.

II. Materials And Methods

Study Design: Prospective Study

Study Centre: Government Royapettah Hospital, chennai.

Study period: Jan 2018 to Jan 2020

Inclusion criteria :

1. Fractures of both bones of forearm
2. Patients aged more than 15 years.
3. Internal fixation done for both radius and ulna.
4. A minimum of 6 months follow-up.
6. There should be no malunion, nonunion and cross union.

Of the available 102 cases, both pre-operative and post-operative X-rays were not available in 16 cases and 21 cases were treated conservatively or by external fixation. The remaining 65 cases were evaluated radiologically according to the proforma which takes into consideration:

1. Level of fracture,
2. Whether fracture radius is proximal or fracture ulna is proximal,
3. Types of fractures of radius and ulna,
4. Relation of fracture lines to the direction of the interosseous membrane,
5. Type of fixation and post-operative immobilization,
6. Pre-operative subluxation or dislocation of the distal radioulnar joint,

7. Post-operative subluxation or dislocation of the distal radioulnar joint.

There were 8 malunions, 13 nonunions and 2 cross unions. The remaining 42 patients were called for followup. 28 patients who came for follow-up were evaluated as follows:

Clinically:

1. 'Piano key sign.
2. Springing of the forearm.
3. Pronation and supination.

Radiologically: Standard x-rays were taken in P.A and lateral views.

Functionally:

1. Grip strength and
2. Pinch to pinch

"Piano key' sign: Holding the lower end of the forearm with both the hands of the examiner, keeping both the thumbs on the lower end of the radius and the ulnar head, ballottement of the displaced (dislocated or subluxation) ulnar head can be elicited. Springing: Squeezing the forearm at the proximal 1/3 eliciting pain at the distal radioulnar joint or at the fracture sites of both the bones.

Pronation and supination:

These movements were measured with the Goniometer from the midprone position of the forearm with elbow flexed to 90° and arm close to the body. Normal range of movement is taken as pronation – 85°, supination -90° and compared accordingly.

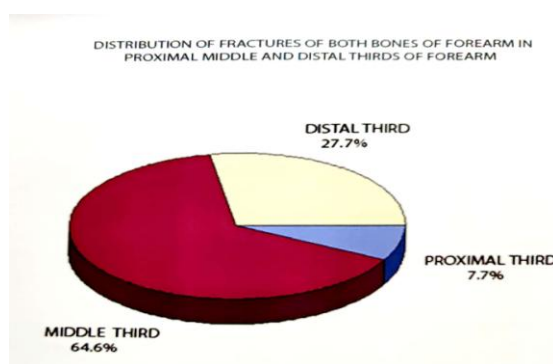
Standardized x-rays:

Standardized P.A view is taken in 90° of abduction of shoulder, 90° of flexion of the elbow, full pronation of the forearm and ulnar deviated wrist on the cassette. Standardized lateral view is taken with arm by side of the body (no abduction at the shoulder), 90° flexion at the elbow, pronated forearm with neutral wrist and ulnar border of the hand touching the cassette. Grip and pinch strengths were assessed in the occupational therapy department with the Jamar dynamometer for grip strength. The grip and pinch strengths were compared with the opposite side.

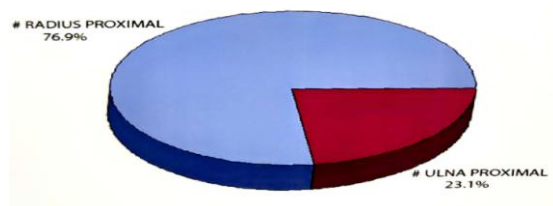
III. Results

Study period was from Jan 2018 to Jan 2020. All the cases of fractures of both bones of forearm in the above mentioned period were taken up for the study. There were 102 cases available for the study of which only 65 cases fulfilled our criteria for selection. There were 47 males and 18 females in our study group. Youngest patient in our study group was 15 years old patient and oldest patient was 72 years old, with a mean age of 34.42 years. In 27 cases (41.5%) right forearm bones were fractured and in 38 cases (58.5%) left forearm was involved. 52 fractures were closed fractures and 13 were open fractures. According to the level 18 forearm fractures (27.7%) were in the distal third, 42 (64.6%) in the middle third and 5 (7.7%) were in the proximal third. In 50 cases (76.9%) fracture of radius was proximal to that of ulna and in 15 cases (23.1%) fracture of ulna is proximal to that of radius. In other words in 50 cases fractures were in the direction of interosseous membrane which is proximoradial to distal ulnar. In 15 cases fractures were in the direction opposite to the fibers of the interosseous membrane. In 30 cases fractures were comminuted and in 35 cases there were only two fragments of each bone. On preoperative evaluation of x-rays there were 37 cases with distal radioulnar joint dislocations and 28 cases had no dislocation i.e., 56.9% of cases of fractures of both bones of forearm in our study group had distal radioulnar joint dislocations. Of the 65 cases of fractures of both bones of forearm taken up for the study, in 43 cases (66.1%) both radial and ulnar fractures were fixed by plates, in 17 cases (26.2%) intramedullary nailing was done and in 5 cases (7.7%) fracture radius was fixed with plate and fracture ulna with Square or Rush nail. In 41 cases postoperative immobilization was done by above elbow posterior slab. In 24 cases above elbow posterior slab was maintained till suture removal followed by above elbow cast for six weeks. Of the 37 preoperative distal radioulnar joint dislocations, 10 (27.02%) were associated with fractures of both bones of forearm in the lower third and 27 (72.97%) were associated with middle third fractures. There were no distal radioulnar joint dislocations associated with the proximal third fractures. Chi square value of this was 7.55 and p value was 0.022 which is significant. Of the 39 immediate postoperative distal radioulnar joint dislocations, 12 (30.77%) were associated with fractures of both bones of forearm in the lower third and 27 (69.23%) were associated with middle third fractures. There were no distal radioulnar joint dislocations in the proximal third fractures. Chi square value was 8.15 and p value was 0.016 which is significant. Out of 37 preoperative distal radioulnar joint dislocations, 30 (81.08%) were associated with fractures in the direction of interosseous membrane and 7 (18.92%) with fractures opposite to the direction of interosseous membrane. In fractures in the direction of the interosseous membrane, radial fracture will be proximal and in fractures opposite to the direction of Interosseous membrane, ulnar fractures will be proximal. Chi square value was found to be

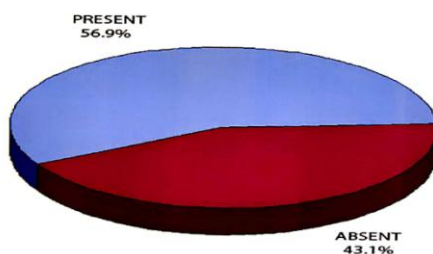
7.28 and p value was 0.006 which is very significant. Out of 39 postoperative distal radioulnar joint dislocations, 31 (79.49%) were associated with fractures in the direction of interosseous membrane i.e., with radial fractures proximal and 8 (20.51%) were associated with fractures opposite the direction of interosseous membrane i.e., with ulnar fracture proximal. Out of the 39 cases with post operative distal radioulnar joint dislocations, in 27 cases both fractures of radius and ulna were fixed by plates, in 9 cases fracture of radius were fixed by plate and fracture of ulna by nail, and in 3 cases both fractures were fixed by nails. Though 37 cases had preoperative distal radioulnar joint dislocations, on immediate post operative evaluation 39 cases showed distal radioulnar joint dislocations. Only 30 cases with preoperative distal radioulnar joint dislocations showed postoperative distal radioulnar joint dislocations. In 9 cases there were postoperative distal radioulnar joint dislocations even in the absence of preoperative distal radioulnar joint dislocations. Chi square value was 15.9, p value was 0.00007 which is very highly significant. On evaluating the 28 patients who came for follow-up only 3 patients had significant symptoms like positive piano key sign and positive springing of the forearm. On comparing the pronation and supination of injured forearm with that of normal side, 7 patients had restrictions of pronation (less than 50% of normal side) and 8 patients had restriction of supination (less than 50% of normal side). On calculating the grip strengths of the normal and injured side measured by Jamar dynamometer, 8 cases showed significant reduction in the grip strength.



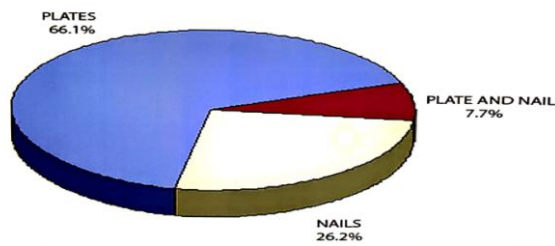
PROXIMITY OF ONE BONE FRACTURE AGAINST THE OTHER




PREOPERATIVE DISTAL RADIOULNAR JOINT DISLOCATIONS



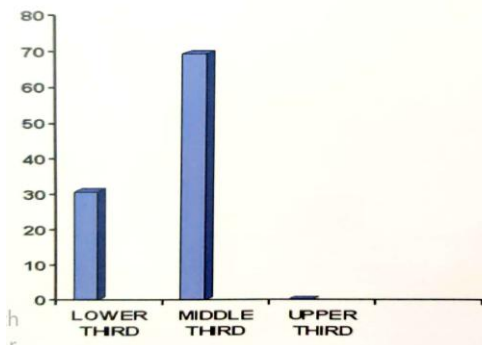
TYPE OF INTERNAL FIXATION OF FRACTURES OF BOTH BONES OF FOREARM



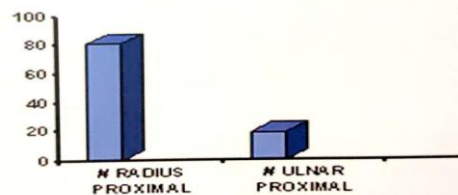
DISTRIBUTION OF PREOPERATIVE DISTAL RADIOULNAR JOINT DISLOCATIONS ACCORDING TO LEVEL OF FRACTURES



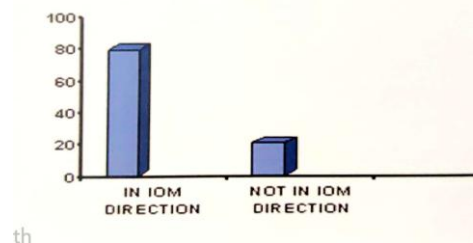
DISTRIBUTION OF POSTOPERATIVE DISTAL RADIOULNAR JOINT DISLOCATIONS ACCORDING TO LEVEL OF FRACTURES

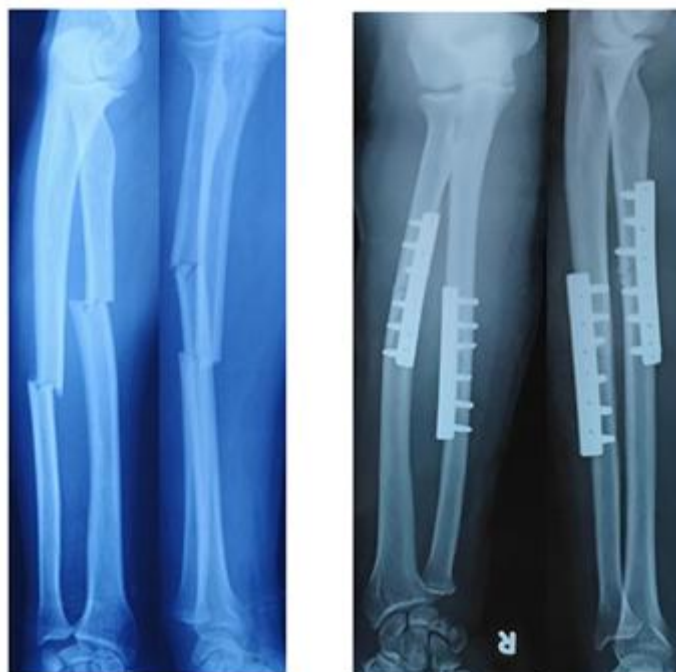

RELATIONSHIP BETWEEN PROXIMITY OF RADIAL AND ULNAR FRACTURES AND PREOPERATIVE DISTAL RADIOULNAR JOINT DISLOCATIONS

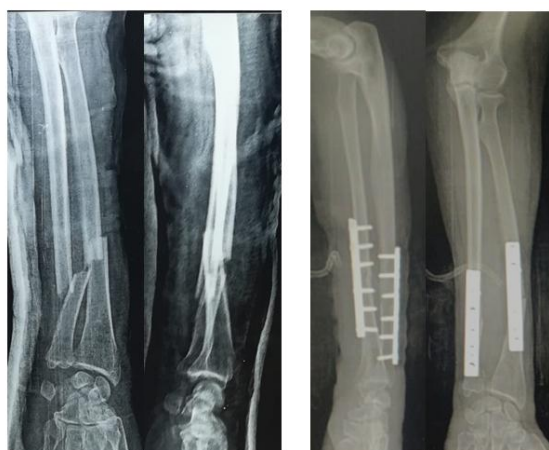


RELATIONSHIP BETWEEN FRACTURE LINE AND I.O.M DIRECTION IN POSTOPERATIVE DISTAL RADIOULNAR JOINT DISLOCATIONS





Fracture of the radius proximal to that of ulna; distal radioulnar joint dislocation present pre and postoperatively.



Fracture of the radius proximal to that of ulna; distal radioulnar joint dislocation present pre and postoperatively.

IV. Discussion:

By focusing our attention on the often forgotten distal radioulnar joint, perhaps we can place it in proper perspective in view of its importance in the upper extremity function and understand the need for its accurate evaluation and management. Dislocation of the distal radioulnar joint is well known with isolated fractures of lower third of radius which has been described by Ricardo Galeazzi, and hence this injury is associated with his name.

Much of literature is not available about the involvement of distal radioulnar joint fractures of both bones of forearm. Mikic in 1975 published a paper titled "Galeazzi fracture-dislocations" in which he included cases of fractures of both bones of forearm at its lower third associated with distal radioulnar joint dislocations. He mentioned this as a particular type of Galeazzi fracture-dislocation which formed 20% of the total number of cases. However, no attempt has been made to focus one's attention on the distal radioulnar joint with fractures of both bones of forearm at various levels. Hence we thought of having a look at the often forgotten distal radioulnar joint in these cases. From Jan 2018 to Jan 2020 we had a total of 102 cases of fractures of both bones of forearm treated at our hospital. Those cases treated by open reduction and internal fixation alone were taken up for the study. Hence we had a total of 65 cases for critical evaluation. On preoperative evaluation of x-rays of these 65 patients, there were 37 cases with distal radioulnar joint dislocations. In other words 56.9% of cases of fractures of both bones of forearm were associated with distal radioulnar joint dislocation.

Level of fractures and its association with distal radioulnar joint dislocations:

On analyzing the relationship between levels of fractures of both bones of forearm and distal radioulnar joint dislocation, it was observed that the fractures in the lower third and middle third were associated with distal radioulnar joint dislocations. On the contrary, there has been no case of distal radioulnar joint dislocation in the fractures of both bones of forearm in the proximal third. P value (0.022) for this relation was statistically significant. This can be explained by the fact that the distal radioulnar Joint being away from the proximal third, it is possible that the forces are less likely to be transmitted to distal radioulnar Joint from the proximal third forearm injuries. However, the number of cases of fractures of both bones of forearm at the proximal third in our series was very few numbering only 5. This can be one of the reasons why there were no distal radioulnar joint dislocations in fracture of both bones of forearm in the proximal third. Hence to say confidently one has to look at many fractures of both bones of forearm at proximal third before making a firm conclusion.

Direction of interosseous membrane and its relationship with the distal radioulnar joint dislocations:

The interosseous membrane has an obliquity in its course, the direction being proximoradial to distoulnar. An attempt to know the relationship between the proximity of one bone fracture against the other and the distal radioulnar joint dislocation was made. There were totally 50 fractures of both bones of forearm with fracture of radius being proximal and fracture of ulna being distal, and only 15 cases with proximal ulnar fracture. The incidence of distal radioulnar joint dislocation was found to be significantly higher in individuals with proximal radial fractures, i.e., the injuries in the direction of interosseous membrane which runs proximoradial to distoulnar. Mikic in 1975 puts forward a postulation that in the particular type of Galeazzi fracture-dislocation involving the fracture of ulna, the direction of forces run from radius, then injury distal radioulnar joint and lastly as they proceed, they injure the ulna. Information is not available in his article regarding proximity of one bone fracture against the other. We are of the opinion that when proximity is in radius, the forces running being in the direction of interosseous membrane, it is likely that the injury fractures radius first, then disrupts distal radioulnar joint and lastly fractures ulna. To substantiate our view is the finding of very low incidence of distal radioulnar joint dislocation (n=7) in cases with proximal ulnar fracture with distal radial fracture pattern. To strengthen this view, a futuristic biomechanical study of proximity of fractures and distal radioulnar joint dislocation is worth undertaking.

Post operative dislocation of distal radioulnar joint:

An attempt was made to correlate the preoperative and Immediate postoperative distal radioulnar joint dislocations in fractures of both bones of forearm. Out of 37 cases with preoperative distal radioulnar joint dislocation only 30 cases had persistent postoperative distal radioulnar joint dislocations. In other words, the 7 cases which had no distal radioulnar joint dislocation postoperatively would have got reduced after Internal fixation. But 9 more cases which appeared normal on preoperative evaluation showed distal radioulnar joint dislocations in the postoperative X-rays. This can be explained by the fact that the distal radioulnar joint though injured initially, dislocation was not seen on preoperative x-ray because of displacement of fragments of forearm bones, keeping the ulnar head in the sigmoid notch of radius. Once the radius and ulna were fixed, the lengths regained and angulation and displacement were corrected, then distal radioulnar joint dislocation became obvious. This brings us to the point that x-ray alone will not help in knowing the integrity of distal radioulnar joint. A good clinical examination of the distal radioulnar joint at the time of injury is worthwhile.

Complex distal radioulnar joint dislocation:

Interposition of soft tissues make the distal radioulnar joint dislocations irreducible. These are called complex dislocations. these cases differ from the simple dislocations that even after adequate amount of rest, distal radioulnar joint shows dislocation. To know the incidence of complex distal radioulnar joint in our series, we called our patients for review after a minimum period of 6 months following open reduction and internal fixation of forearm fracture. Out of the initial 65 cases of study group, only 42 patients were called up for follow-up, as 8 cases were diagnosed as malunions and 13 cases as nonunions. 2 cases of cross unions were also deleted from the study for the fear of difficulty in assessing the rotations of forearm. Of the 42 patients called, only 28 came for follow-up. These patients were evaluated clinically, radiologically and functionally. After these evaluations only 3 patients showed persistent distal radioulnar joint dislocation on x-rays with positive piano key sign and gross restriction of affected forearm rotation and gross reduction in the grip strength on affected side when compared with the normal side. These 3 patients were taken by us as complex dislocations of distal radioulnar joint. But, ideally we should take CT Scan or interposed soft tissue should be identified at an open operation to brand these cases as complex dislocations, but none of our patients agreed for CT scan or operation because of financial constraints. Other than these 3 patients, 8 patients on follow-up showed minimal restriction of forearm rotations or slight reduction in the grip strength, but not leading to difficulty persuading their activities of daily living. These patients were branded as simple dislocations along with those in whom there

were no problems on review.

V. Conclusion

1.It is not unusual to observe instability of distal radioulnar Joint in fractures of both bones of the forearm. 2. Most of the fractures of both bones of forearm at distal and middle thirds were associated with dislocations of distal radioulnar joint. 3. The incidence of distal radioulnar joint dislocations was significantly higher in individuals with proximal radial and distal ulnar fracture pattern. 4. The recognition of distal radioulnar joint dislocations, postoperatively, focused our attention to the inadequacies of x-rays in evaluating this joint. 5. Patients who had persistent dislocations at 6 months postoperative follow-up with positive 'piano key' sign, gross restriction of forearm rotations and gross reduction of grip strength were presumed to be complex dislocation of distal radioulnar joint.

References:

- [1]. Bush, M.E., Lovejoy, C.O., Johanson, D.C., and Coppens, Y.: Hominid carpal, metacarpal, and phalangeal bones recovered from the Hadar formation. 1974/1977 collections. *Am. J. Phys. Anthropol.* 56: 651, 1982
- [2]. Lewis, O.J.: Evolutionary change in the primate wrist and inferior radioulnar joint. *Anat. Rec.* 151: 275, 1965
- [3]. Lewis, O.J.: The hominoid wrist joint. *Am. J. Phys. Anthropol.* 30: 251, 1969
- [4]. Lewis, O.J.: The development of the human wrist joint during the fetal period. *Anat. Rec.* 166: 499, 1970
- [5]. Marzke, M.W.: Origin of the human hand. *Am. J. Phys. Anthropol.* 34:61, 1971.
- [6]. af Ekenstam, F.: Anatomy of the distal radioulnar joint. *Clin. Orthop.*, 275: 1418, 1992
- [7]. Almquist, E.E.: Evolution of the distal radioulnar joint. *Clin. Orthop.*, 275: 513, 1992
- [8]. Anderson, L.D., and Meyer, F.N.: Fractures of the shaft of the radius and ulna. In Rockwood, C.A.Jr, Green, D.P., and Buchholz, Red): *Rockwood and Green's fractures in adults*. Ed.3, vol. 1. Philadelphia, J.B. Lippincott Company, 1991, pp. 679.
- [9]. Bowers, W.H.: The distal radioulnar joint. In Green, D.P. (ed): *Operative Hand Surgery*. Ed.2, vol.2. New York, Churchill Livingstone, 1988, pp. 939.
- [10]. Bruckner, J.D., Alexander, A.H., and Lichtman, D.M.: Acute dislocations of the distal radioulnar joint. *J. Bone and Joint Surg.* 77A: 958, 1995
- [11]. Bruckner, J.D., Lichtman, D.M., and Alexander, A.H.: Complex dislocations of the distal radioulnar joint. *nition and management. Clin. Orthop.* 275:90-103, 1992.
- [12]. Charnley, J. (ed): *The closed treatment of common fractures*. Ed.3. New York, Churchill Livingstone, 1981, pp.116.
- [13]. Czitrom, A.A., Dobyns, J.H., and Linscheid, R.L.: Ulnar variance in carpal instability. *J. Hand Surg.* 12A: 205, 1987
- [14]. Darrow, J.C., Jr., Linscheid, R.L., Dobyns, J.H., Mann, J.M., M, Wood, M.B., and Beckenbaugh, R.D. : Distal ulnar recession for disorders of the distal radioulnar joint. *J. Hand Surg.* 10A: 482, 1985
- [15]. Epner, R.A., Bowers, W.H., Guilford, W.B. : Ulnar variance: The effect of wrist positioning and roentgen filming technique. *J. Hand Surg.* 7: 298-305, 1982
- [16]. Hagert, C.G.: The distal radioulnar joint in relation to the whole forearm. *Clin. Orthop.*, 275: 566, 1992
- [17]. Johnson, R.K., and Shrewsbury, M.M.: The pronator quadratus in motion and in stabilization of the radius and ulna at the distal radioulnar joint. *J. Hand Surg.*, 1: 205, 1976

R. Jayganesh, et. al. "Evaluation of the Integrity of the Distal Radioulnar Joint in Fractures of Both Bone of Forearm." *IOSR Journal of Dental and Medical Sciences (IOSR-JDMS)*, 19(8), 2020, pp. 38-44.